

A case of fulminant myocarditis due to COVID-19 in an adolescent patient successfully treated with venous arterial ECMO as a bridge to recovery

Daniel H. Buitrago MD, MPH¹ | Jennifer Munoz MD² | Emily R. Finkelstein BS^{1,3}  | Leonardo Mulinari MD, PhD¹ 

¹Pediatric and Congenital Cardiac Surgery, Jackson Memorial Hospital/University of Miami Hospital System, Miami, Florida, USA

²Pediatric Critical Care Medicine, Children's Heart Center, University of Miami Hospital System, Miami, Florida, USA

³Ross University School of Medicine, Barbados

Correspondence

Emily R. Finkelstein, 1865 Brickell Ave Apt A1604 Miami, FL 33129, USA.

Email: Emilyfinkelstein@mail.rossmed.edu

Abstract

Emerging data suggest an association between severe acute respiratory syndrome coronavirus 2 and the development of acute myocarditis, with children and older adults being most at risk. We describe the clinical course of a previously healthy 12-year-old female who rapidly deteriorated into cardiogenic shock and arrest due to coronavirus disease 2019 induced fulminant myocarditis, necessitating venous-arterial extracorporeal membrane oxygenation as a bridge to full recovery. This case highlights the importance of early clinical recognition of myocardial involvement, and the benefits of taking a multidisciplinary approach in treating these patients.

KEYWORDS

adolescent, COVID-19, ECMO, extracorporeal membrane oxygenation, myocarditis, pediatric, SARS-CoV-2

1 | INTRODUCTION

The incidence of acute myocarditis with coronavirus disease 2019 (COVID-19) infection for all ages is still under investigation, with current estimates being below two percent.^{1,2} This report, detailing the successful treatment course of an adolescent patient, may guide providers in future identification and management of pediatric cases of COVID-19 induced fulminant myocarditis using venous-arterial extracorporeal membrane oxygenation (VA ECMO).

A recent publication by the Center of Disease Control (CDC) utilizing a database of over 900 hospitals reported 16 times higher risk of acute myocarditis for those who were infected with COVID-19 compared with those who are not.³ This risk was found to be 37 times higher in children less than 16 years old, suggesting that COVID-19 is a strong and significant risk factor for myocarditis, with the risk varying by age group.³

Patients with acute myocarditis from COVID-19 infection can present initially with nonspecific symptoms such as fever, shortness of breath, or chest pain, making the diagnosis difficult

to recognize within the early stages of the disease.⁴⁻⁶ Fulminant myocarditis, defined as heart failure within two to three weeks of contracting the virus, may also be a primary presentation of COVID-19 infection.⁷ In some instances, patients may exhibit features that highly resemble septic shock, creating yet another diagnostic challenge.⁷ The two main pathophysiological mechanisms thought to be behind COVID-19 acute myocarditis include an intrinsic process commenced when the virus binds receptors in the myocardium and a hyperimmune response characterized by a cytokine storm.^{7,8}

There is an overall paucity of literature detailing the management of COVID-19 fulminant myocarditis with VA ECMO.^{2,3,6,9-12} This number is even more finite when looking for data in the pediatric population.¹² We present the clinical course of a previously healthy, nonvaccinated adolescent female who rapidly developed fulminant myocarditis linked to COVID-19 infection, treated with VA ECMO as a bridge to full recovery.

2 | CASE PRESENTATION

Informed consent was obtained from the patient and their guardian for this case report. The patient is a 12-year-old previously healthy female who presented to the emergency department with two days of headache, neck pain, nausea, diarrhea, and overall lethargy. Upon examination, she was found to be febrile, tachycardic, and hypotensive, leading providers to administer 20 ml/kg bolus of 0.9% normal saline. Following this administration of saline, the patient experienced oxygen desaturations into the high 80's and low 90's.

Labs were remarkable for elevated aspartate aminotransferase (371 U/L), C-reactive protein (1.6 mg/dL), and troponin (59.6 ng/ml). Chest X-ray (CXR) revealed pulmonary edema and a normal cardiac

silhouette (Figure 1A). Electrocardiogram (ECG) was significant for ST-segment elevations in the inferior leads, II, III, and AVF (Figure 1B). Images from a transthoracic echocardiogram (TTE) demonstrated reduced left ventricular systolic function with normal right ventricular dimensions and systolic function. These constellations were highly suspicious for acute myocarditis, which led to patient admission into the cardiac intensive care unit (CICU) for further management. At this time, the patient's care team decided that she would benefit from VA ECMO as temporary mechanical circulatory support.

Following admission, central and peripheral access lines were placed, with subsequent development of hypotension necessitating an epinephrine infusion. This infusion triggered a run of premature

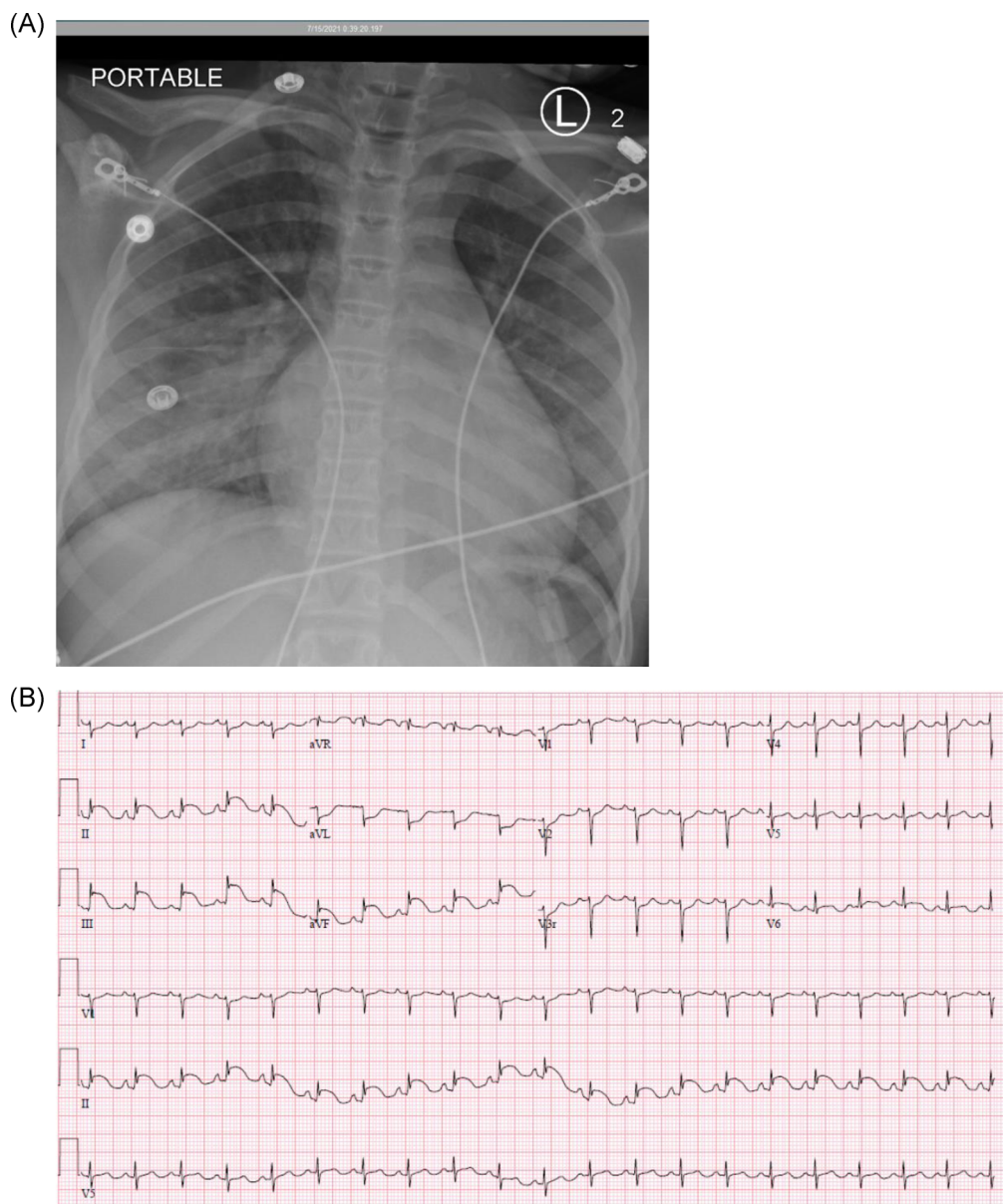


FIGURE 1 (A) and (B). (A) CXR on admission showed pulmonary edema with a normal-sized cardiac silhouette. (B) ECG on admission significant for ST-segment elevations in the inferior leads, II, III, and AVF. CXR, chest X-ray; ECG, electrocardiogram

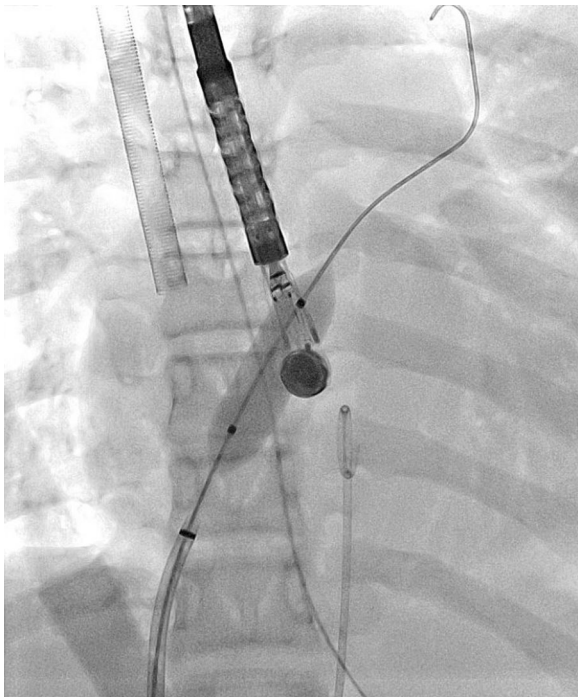

FIGURE 2 Cardiac catheterization demonstrating balloon atrial septostomy

ventricular contractions (PVC's) that ultimately led to sustained ventricular tachycardia and cardiac arrest. Extracorporeal cardiopulmonary resuscitation (ECPR) was then initiated. Femoral cannulation was performed at the bedside, using the Seldinger technique. The femoral artery and vein were cannulated using a 15 Fr and 19Fr. The flow was established at 2.5 L/min, resulting in a mean arterial pressure (MAP) greater than 65 mmHg. Nipride was initiated to manipulate systolic vascular resistance (SVR) and support forward flow (Figure 2).

Once the patient stabilized, the decision was made to proceed to the operating room and change the femoral cannulation site to the carotid and internal jugular vessels of the neck. A 5 mm Gore-Tex conduit was anastomosed to the right carotid artery and tunnel subcutaneously. The arterial cannula was advanced through the conduit and secured to the skin using multiple silk ties and several 3-0 Prolene. Utilizing the Seldinger technique, the jugular cannula was inserted into the jugular vein two centimeters superior to the surgical incision. Transesophageal echocardiogram (TEE) confirmed adequate placement of the cannulas, although it identified low bi-ventricular contractility and lack of aortic valve opening concerning for left atrial hypertension.

The patient was then taken to the cath lab to perform an atrial septostomy. An 8 Fr transeptal sheath was advanced into the innominate vein, followed by the advancement of a transeptal needle. Under imaging guidance, the transeptal needle and sheath were then advanced to the left atrium (Figure 2). Cutting balloon was positioned across the septum, inflated to 6 atm \times 2 then to 10 atm. The balloon was removed, and the atrial septal defect was assessed.

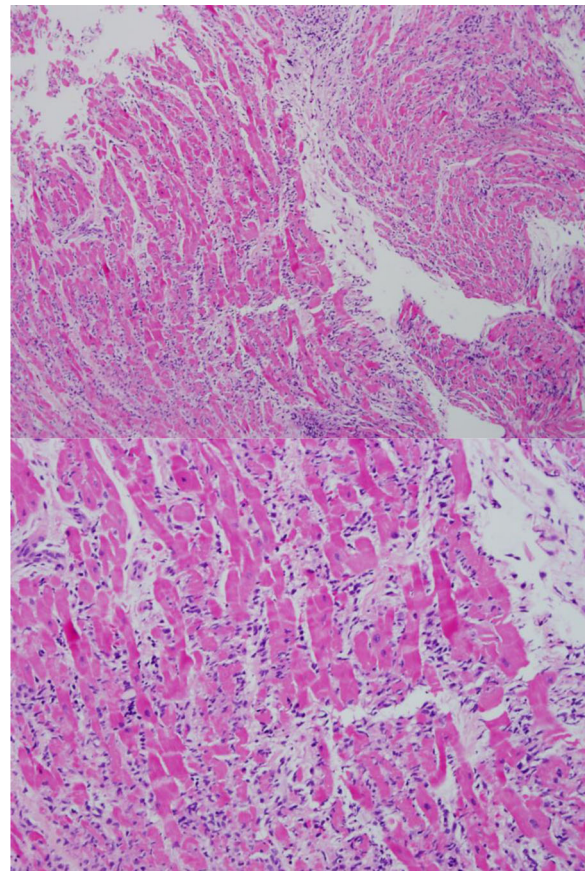


FIGURE 3 Biopsy of the ventricles showing acute myocarditis without signs of viral infection; 100X magnification (top) and 200X magnification (bottom)

Biopsies of the ventricles were taken at this time to confirm the initial diagnosis.

Pathology reports of the myocardial tissue revealed severe myocarditis without signs of viral infection (Figure 3). Two-color immunohistochemistry of CD3 and CD20 markers revealed a severe, diffuse accumulation of CD3 positive T-cells throughout the interstitium with no significant number of CD20 positive B-cells (Figure 4). Initial infectious labs indicated elevated COVID-19 antibodies (369 U/ml) and total IgG (3.4 U/ml). Adenovirus, CMV, and EBV serum polymerase chain reactions (PCRs) were all negative.

The patient was then started on empiric vancomycin and cefepime, with methylprednisone 2 mg/kg once daily for 2 days, followed by 1 g daily for 3 days. TTE conducted in recovery from the operating room and catheter lab showed minimal wall motion, with an ejection fraction (EF) at 11%. The aortic valve demonstrated normal motion, indicating effectiveness of the atrial septal shunt. Her V-A ECMO flows at this point to maintain hemodynamic stability were at 2.7 L/min. CXR still showed pulmonary edema, but otherwise, the patient clinically improved.

On days three and four after admission, the patient remained under resting ventilator settings with appropriate gas exchange and pulmonary mechanics. Kidney function was preserved, and the liver

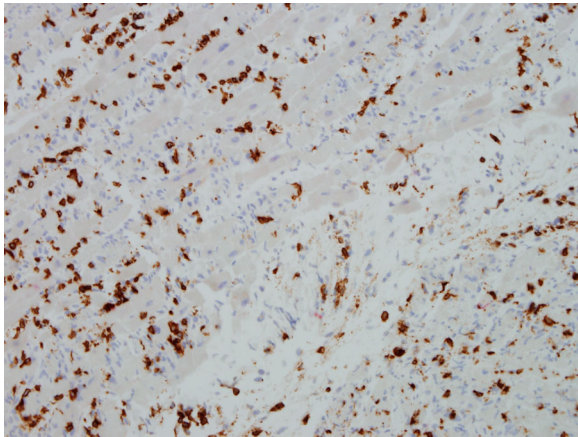


FIGURE 4 Two-color immunohistochemistry to CD3/CD20 shows a severe, diffuse accumulation of CD3 positive T-cells throughout the interstitium with no significant number of CD20 positive B-cells

function tests were continuing to trend down. The plan was to start weaning off ECMO slowly while increasing milrinone and adding back epinephrine to improve native cardiac output. By days five and six, TTE was displaying improvement in her left ventricle systolic function. On Day 7, the patient was tolerating low flows of ECMO without any significant clinical change. When the ECMO cannula was clamped for a trial, while increasing the dose of epinephrine, her left ventricular systolic function improved slightly from 22% to 33%. The patient was then successfully weaned off ECMO.

Day 7 after decannulation from ECMO, the patient displayed remarkable improvement. She had stable cardiac and pulmonary function maintained on carvedilol and enalapril, with therapeutic anticoagulation with lovenox for a right femoral vein deep venous thrombus. With offers of inpatient rehabilitation along with physical and occupational therapy, the patient was ambulatory and spending more time out of bed.

3 | DISCUSSION

To the best of our knowledge, this is the first report of COVID-19 induced acute fulminant myocarditis presenting as early cardiogenic shock in a 12-year-old female, successfully treated with VA ECMO as a bridge to full recovery. Our hospital serves as one of the main ECMO referral centers in southern Florida, allowing us to have the capability and resources to offer heroic interventions such as the one presented in this case.

Although the exact mechanisms behind acute myocarditis due to COVID-19 are still under investigation, infection is reported to be both a strong and significant risk factor in the development of myocarditis.³ Among all persons with a diagnosis of acute myocarditis linked to COVID-19, it is likely that a handful represents cases of multisystem inflammatory syndrome (MIS), particularly in children less than 16 years of age.^{13,14} Since the implementation of the mRNA

COVID-19 vaccines in December of 2020, studies report an elevated risk of myocarditis among vaccine recipients, predominantly in males aged 12–29 years.^{15,16} However, the COVID-19 infection itself is found to pose a greater risk for myocarditis, with the benefits of vaccination deemed to outweigh this possible risk.^{15,16}

Experts currently believe the pathophysiology behind COVID-19 induced acute myocarditis is likely similar to that of other viruses.^{3,17} The proposed mechanisms of direct myocardial injury inflicted by COVID-19 include (i) acute myocarditis defined by an amplified lymphocytic immune response (as observed in our case) and (ii) direct viral damage putatively mediated by activated macrophages.^{18,19} The acute presentation observed in this case report highly suggests a mechanism of direct viral injury to the myocardium, triggering an exaggerated innate immune response.

A diagnosis of cardiogenic shock carries a high risk of mortality, especially without definitive intervention.²⁰ The specific role of ECMO support for patients with cardiopulmonary failure due to COVID-19 infection is continuously evolving.² Our case serves as an example of early initiation of VA ECMO for cardiogenic shock in a COVID-19 patient. We believe that this rapid initiation of mechanical circulatory support played a significant role in the survival of our patients. Although outcome data for patients on VA ECMO for COVID-19 related complications is limited, the literature indicates survival until hospital discharge for VA ECMO patients is generally between 40% and 45%. Risk factors such as younger age, lower BMI, and reversible diagnoses such as acute myocarditis have better-reported outcomes.^{20,21} The decision to implement VA ECMO in a patient with fulminant myocarditis linked to COVID-19 should be made using a multidisciplinary approach on a case-by-case basis, with the careful balance of resource allocations.

The complexities of COVID-19 infection are continuously evolving with time. Now that adolescents are returning to school and resuming extracurricular activities, it is important to recognize the shortage of available data on COVID-19 acute myocarditis in the pediatric population. Our hope is that this report, detailing the successful treatment course of an adolescent patient, may guide providers in future identification and management of pediatric COVID-19 induced fulminant myocarditis using VA ECMO.

CONFLICT OF INTERESTS

The authors declare no conflict of interest.

ETHICS AND LEGAL

IRB approval, clinical trial statement, and registration details are N/A. Informed consent was obtained from both the patient and their legal guardian for this case report.

AUTHOR CONTRIBUTIONS

Daniel H. Buitrago – Concept/Design, critical review of draft, case analysis, and interpretation. **Jennifer Munoz** – Concept/Design, critical review of draft. **Emily R. Finkelstein** – Case analysis and interpretation, report drafting, and revisions. **Leonardo Mulinari** – Concept/Design, critical review of draft.

ORCID

Emily R. Finkelstein  <http://orcid.org/0000-0003-4666-0912>

Leonardo Mulinari  <http://orcid.org/0000-0001-7138-9912>

REFERENCES

1. Murk W, Gierada M, Fralick M, Weckstein A, Klesh R, Rassen JA. Diagnosis-wide analysis of COVID-19 complications: an exposure-crossover study. *CMAJ*. 2020;193(1):10-18.
2. Badulak J, Antonini MV, Stead CM, et al. ELSO COVID-19 working group members extracorporeal membrane oxygenation for COVID-19: updated 2021 Guidelines from the Extracorporeal Life Support Organization. *ASAIO J*. 2021;67(5):485-495.
3. Boehmer TK, Kompaniyets L, Lavery AM, et al. Association between COVID-19 and myocarditis using hospital-based administrative data – United States, March 2020–January 2021. *MMWR Morb Mortal Wkly Rep*. 2021;70:1228-1232.
4. Rathore SS, Rojas GA, Sondhi M, et al. Myocarditis associated with COVID-19 disease: a systematic review of published case reports and case series. *Int J Clin Pract*. 2021;75:e14470.
5. Çınar T, Hayiroğlu Mİ, Çiçek V, Uzun M, Orhan AL. COVID-19 and acute myocarditis: current literature review and diagnostic challenges. *Rev Assoc Med Bras (1992)*. 2020;66(Suppl 2):48-54.
6. Ho JS, Sia CH, Chan MY, Lin W, Wong RC. Coronavirus-induced myocarditis: a meta-summary of cases. *Heart Lung*. 2020;49(6):681-685.
7. Siripanthong B, Nazarian S, Muser D, et al. Recognizing COVID-19-related myocarditis: the possible pathophysiology and proposed guideline for diagnosis and management. *Heart Rhythm*. 2020;17(9):1463-1471.
8. Castiello T, Georgiopoulos G, Finocchiaro G, et al. COVID-19 and myocarditis: a systematic review and overview of current challenges. *Heart Fail Rev*. 2021;27:1-11.
9. Irabien-Ortiz Á, Carreras-Mora J, Sionis A, Pàmies J, Montiel J, Tauron M. Fulminant myocarditis due to COVID-19. *Rev Esp Cardiol (English ed.)*. 2020;73(6):503-504.
10. Salamanca J, Diez-Villanueva P, Martinez P, et al. COVID-19 “Fulminant Myocarditis” successfully treated with temporary mechanical circulatory support. *JACC Cardiovascular imaging*. 2020;13(11):2457-2459.
11. Papageorgiou JM, Almroth H, Törnudd M, Van der Wal H, Varelogianni G, Lawesson SS. Fulminant myocarditis in a COVID-19 positive patient treated with mechanical circulatory support: a case report. *Eur Heart J - Case Rep*. 2021;5(2):523.
12. Kesici S, Aykan HH, Orhan D, Bayrakci B. Fulminant COVID-19-related myocarditis in an infant. *Eur Heart J*. 2020;41(31):3021.
13. Most ZM, Hendren N, Drazner MH, Perl TM. Striking similarities of multisystem inflammatory syndrome in children and a myocarditis-like syndrome in adults. *Circulation*. 2021;143:4-6.
14. McMurray JC, May JW, Cunningham MW, Jones OY. Multisystem Inflammatory Syndrome in Children (MIS-C), a post-viral myocarditis and systemic vasculitis—a critical review of its pathogenesis and treatment. *Front Pediatr*. 2020;8:626182.
15. Barda N, Dagan N, Ben-Shlomo Y, et al. Safety of the BNT162b2 mRNA COVID-19 vaccine in a nationwide setting. *N Engl J Med*. 2021;385:1078-1090.
16. Gargano JW, Wallace M, Hadler SC, et al. Use of mRNA COVID-19 vaccine after reports of myocarditis among vaccine recipients: update from the Advisory Committee on Immunization Practices—United States, June 2021. *MMWR Morb Mortal Wkly Rep*. 2021;70:977-982.
17. Pollack A, Kontorovich AR, Fuster V, Dec GW. Viral myocarditis—diagnosis, treatment options, and current controversies. *Nat Rev Cardiol*. 2015;12:670-680.
18. Gay HC, Sinha A, Michel E, et al. Fulminant myocarditis in a patient with coronavirus disease 2019 and rapid myocardial recovery following treatment. *ESC Heart Fail*. 2020;7(6):4367-4370.
19. Guzik TJ, Mohiddin SA, Dimarco A, et al. COVID-19 and the cardiovascular system: implications for risk assessment, diagnosis, and treatment options. *Cardiovasc Res*. 2020;116(10):1666-1687.
20. Harjola VP, Lassus J, Sionis A, et al. CardShock Study Investigators; GREAT network. Clinical picture and risk prediction of short-term mortality in cardiogenic shock. *Eur J Heart Fail*. 2015;17(5):501-509.
21. Combes A, Leprince P, Luyt CE, et al. Outcomes and long-term quality-of-life of patients supported by extracorporeal membrane oxygenation for refractory cardiogenic shock. *Crit Care Med*. 2008;36(5):1404-1411.

How to cite this article: Buitrago DH, Munoz J, Finkelstein ER, Mulinari L. A case of fulminant myocarditis due to COVID-19 in an adolescent patient successfully treated with venous arterial ECMO as a bridge to recovery. *J Card Surg*. 2022;37:1439-1443. doi:10.1111/jocs.16313