

# Traumatic rupture of the corpus cavernosum: surgical management and clinical outcomes. A 30 years review

Juan Gómez Rivas, Jose Maria Alonso Dorrego, Mario Martín Hernández, Pamela Fontana Portella, Sonia Pérez González, Jose Antonio Moreno Valle, Jesús Javier de la Peña Barthel

Department of Urology, Hospital Universitario La Paz, Madrid, Spain

## Article history

Submitted: Sept. 30, 2013

Accepted: Dec. 8, 2013

## Correspondence

Juan Gómez Rivas

Hospital Universitario

La Paz

261, Paseo La Castellana

28034 Madrid, Spain

phone: +34 661 190 028

juangomezr@gmail.com

**Introduction** Penile trauma (PT) with associated rupture of the corpus cavernosum, also called penile fracture, is a urological emergency and surgical treatment is usually the choice of management. Our objective is to report our experience after 30 years in the diagnosis and therapeutic options of PT and evaluate the clinical outcomes after the treatment.

**Material and methods** From January 1983 to January 2013, 27 patients were identified. Data was analyzed and is presented in absolute numbers, range, percentage and mean.

**Results** Mean age of patients was 30.7 years, range from 19 to 37. All the patients came complaining of penile swelling and hematoma, and more than half of them (60.7%) reported hearing a snap sound. Some rare causes were identified in our series such as self-mutilation, avulsion, firearm and electrocution. Clinical presentation was diagnostic in all the patients, and the diagnosis was verified by penile ultrasonography in most cases (60.7%). Mean surgery time: 94 minutes. Urethral repair was required in 2 patients. Mean hospital stay was 2 days. Good functional results are shown during follow up.

**Conclusions** Rupture of the corpus cavernosum is a rare condition and is generally diagnosed by clinical findings. Emergency surgical exploration and treatment is the best guarantee of good functional and cosmetic results.

**Key Words:** penile trauma ◊ rupture of the corpus cavernosum ◊ clinical outcomes

## INTRODUCTION

Penile trauma (PT) with associated rupture of the corpus cavernosum, also called penile fracture, is a urological emergency which is caused by the rupture of the tunica albuginea of the corpus cavernosum following a blunt trauma to the erect penis [1]. Traumatic injuries of the penis often occur in the erected state during sexual intercourse or masturbation. There are other causes such as direct injuries, but they are less frequent [1, 2].

Patients commonly report hearing a “crack”, followed by pain, detumescence, penile deformity and hematoma (Figure 1). Hematoma extravasation into the perineum may occur in case of rupture of Buck’s fascia. The penis remains flaccid and deviated toward the opposite side of the fracture. Penile fracture is

an uncommon but probably under reported urological emergency, due to the possible embarrassment of the patients. The true incidence of penile fracture is perhaps much higher than that reported in literature [3].

Ultrasound (US), cavernosography and magnetic resonance imaging are used as diagnostic modalities [4, 5], but there is no consensus or any standard protocol regarding the best diagnostic tool technique.

The treatment is usually surgical [3], and this entity truly represents a urological emergency. Closure of the tunica albuginea is used to prevent sequelae [3] such as fibrous scarring which causes the penis to bend, produces painful erections and even urethral stenosis. Early surgery reduces the duration of hospitalization and is associated with faster functional recovery and lower risk of complications.

Our objective is to report our experience after 30 years in the diagnosis and treatment of PT and also to evaluate the clinical outcomes.

## MATERIAL AND METHODS

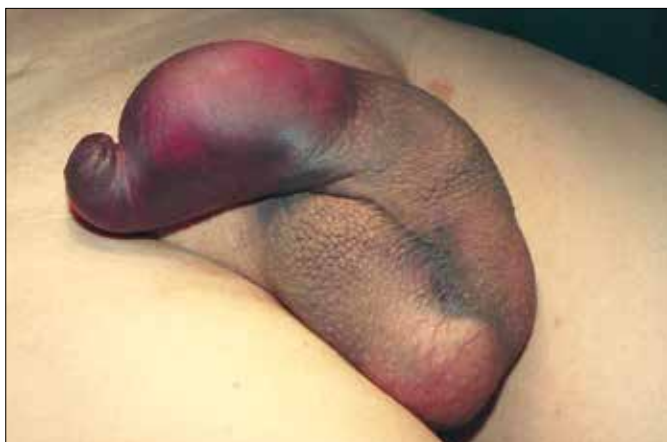The records at our hospital were reviewed to identify patients who had PT with associated rupture of the corpus cavernosum in the last 30 years. From January 1983 to January 2013, 28 patients were identified and 27 of them underwent surgical repair. Data was analyzed and is expressed in absolute numbers, range, percentage and mean. Clinical presentation, diagnosis, operative and postoperative details were reviewed from the patients charts.

Immediate surgical repair was performed in 27 patients. Technique depended on the associated lesions, but basically consisted of penile degloving (Figure 2) through subcoronal incision with debridement, and synthesis of the albuginea of the corpora cavernosa with interrupted polyglactin 3-0 sutures (Figure 2). Circumcision was routinely performed on all uncircumcised patients who underwent surgical exploration to facilitate hygiene and dressings and to provide better immediate aesthetic results.

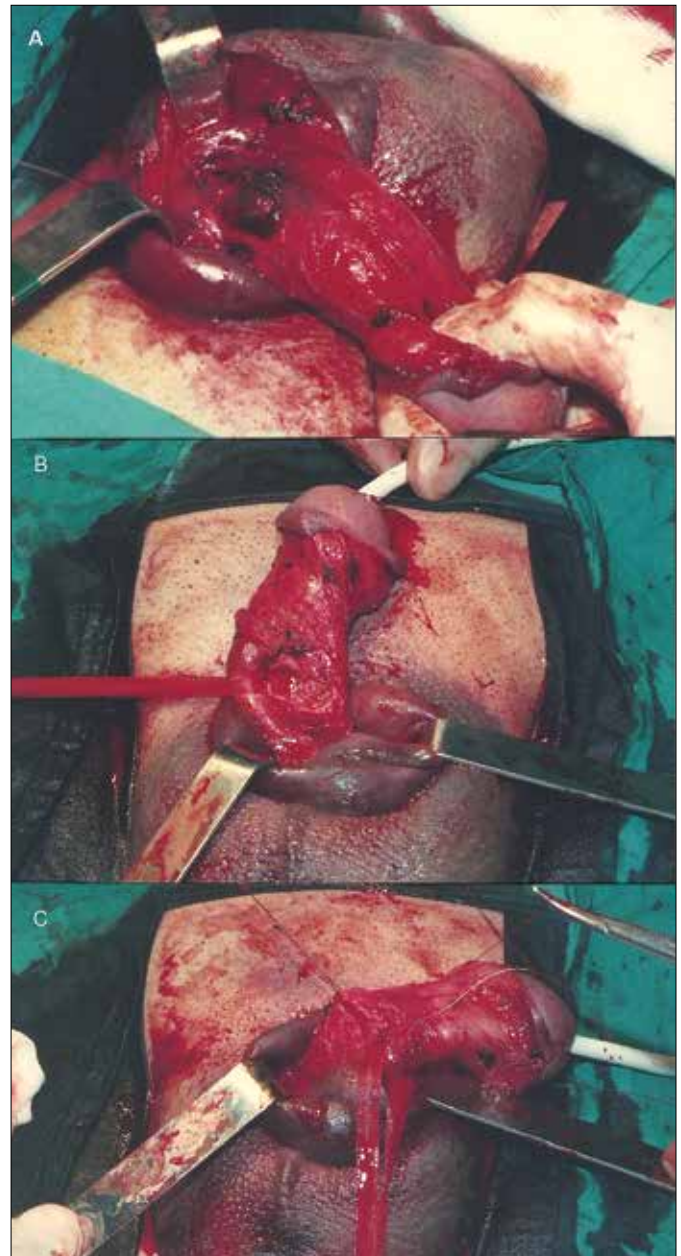
The patients were followed up during outpatient clinic visits for 6 months after the traumatic event and yearly thereafter. The patients were clinically evaluated for the presence of erectile dysfunction and penile deformity.

## RESULTS

The mean age of patients was 30.7 years, range from 19 to 37. All the patients came complaining of penile swelling and hematoma, and more than half of them (60.7%) reported hearing a snap sound. The summa-



**Figure 1.** Penile hematoma.

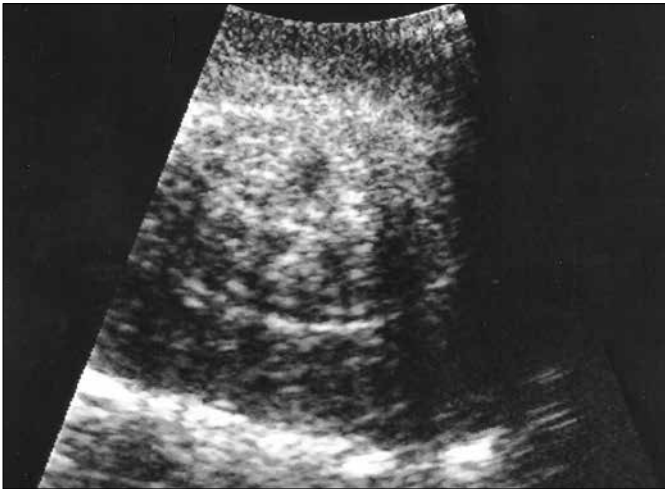

**Figure 2.** Surgical repair: penile degloving (A). Identification of the urethra (B). Repair of the albuginea of the corpora cavernosa with interrupted polyglactin 3-0 sutures (C).

ry of the penile trauma causes, diagnosis tools, and management of the patients are shown in Table 1. A total of 7 patients (25%) had associated urethral bleeding and 3 (10.7%) had urine retention.

We want to emphasize some rare causes seen in our series such as self-mutilation, avulsion, firearm and electrocution.

Characteristic clinical presentation was diagnostic in all the patients, and we verified the diagnosis by penile US (Figure 3) in most of them (60.7%).



**Figure 3.** Ultrasound of the corpus cavernosum.

Mean surgery time: 94 minutes, range from 70 to 150 minutes. Urethral repair was required in 2 patients and they did not have any urinary problem after 1 year of follow up. The hospital length stay was 2 days, ranging from 1 to 5 days.

A total of 8 (28.5%) of the 28 patients were lost between 6 months to 1 year of follow-up, and so long term results (>12 months) were available for 20 patients, with a mean follow up of 28.7 months. We divided the clinical outcomes depending on the mechanism of injury.

### Sexual intercourse–masturbation (22 patients)

There is only 1 case (4.5%) with erectile dysfunction and 6 patients (27.2%) with painful erection or penile deviation. Two cases had associated urethral injuries, so we performed a direct repair of the tear. There were no complete sections of the urethra so primary suture of the defect with 3/0 or 4/0 absorbable suture and bladder catheter placement for 3

weeks was performed. Cystourethrography was done at the time of bladder catheter removal, and during long term follow up none of these patients had urethral stricture. Satisfactory results were archived in 16 patients (72.7%). There were 5 patients lost in follow up. We want to highlight that one of these patients rejected surgical treatment so we offered him medical treatment instead. At six months of follow-up, the functional and cosmetic results were satisfactory.

### Electrocution, Avulsion and Self-mutilation (5 patients)

The results in all of them were not satisfactory, and most of them were lost in the follow up.

### Firearm (1 patient)

He reported good erectile function with successful sexual intercourse, but with painful erection in some cases and a palpable scar. We offered surgical repair but the patient refused, and he was lost in the follow-up after 24 months.

## DISCUSSION

Rupture of the corpus cavernosum usually occurs during an erection as a result of direct blunt trauma to the penis that bends it in an unphysiological manner. The diagnosis of rupture of the corpus cavernosum is usually fairly straightforward because of their clinical presentation. It has been reported that its annual incidence is 0.29 to 1.36 per 100 000 [6]. Some authors suggested that the cause for rupture of corpus cavernosum is largely related to geographic area of report. Vigorous sexual intercourse accompanied with a hit from the female pubis was found to be the main cause of cases<sup>2</sup> in the West as shown in our series. In those from the Middle East, injury

**Table 1.** Patients data

Mechanism	Number	Associated Lesions	Diagnosis	Management
Sexual intercourse	22		Clinical. US in 16 patients	Primary suture Urethral repair (2 patients) Surveillance (1 patient)
Masturbation	1	None	Clinical	Primary suture
Electrocution	1	Coagulative necrosis of all penis	Clinical	Urinary diversion
Avulsion	2	Penis root and scrotal lesion in both patients	Clinical	Perineal urethrostomy
Self-mutilation	1	Absence of the distal 1/3 of the penis	Clinical	Reimplantation (microsurgery)
Firearm	1	Both corpus cavernosum	Clinical. CT	Primary suture

resulted mainly from penile manipulations at masturbation [7, 8].

The penis may take on a bizarre shape, with deviation of the penile shaft, usually opposite to the tear site secondary to the mass effect of the hematoma. When Buck's fascia is damaged (less frequent and painless), the blood can extravasate around Colles fascia, forming ecchymosis in the perineum, scrotum, and lower abdominal wall. The presence of bloodstained urethral meatus, gross hematuria, or inability to urinate should alert to the possibility of concomitant urethral injury. We find that the classic clinical findings of rupture are enough for surgical exploration; however, the high sensitivity and specificity of US in the identification of disruption of the tunica albuginea renders it a useful technique for confirmation of clinically suspected corpus cavernosum ruptures [9]. We used US as tool of diagnosis in 60.7% of cases, however noninvasive US depends on the observer's skill as the site of the tunical tear can be missed if it is too small or is filled with a clot that renders it indistinguishable from the surrounding normal tunica albuginea [10].

Until the early 1980s, the management of penile lesions had been highly controversial. Many conservative treatments have been employed, such as pressure dressing, cold compress, Foley catheterization, anti-inflammatory drugs, antibiotics, antiandrogens, or sedatives. The drawbacks of conservative treatments include expanded pulsatile hematoma, infected hematoma, abscess formation, severe penile angulation, arteriovenous fistulas, and impotence [11]. Immediate surgical repair is now the standard care with fewer complications, short hospital stays as shown in our series, better outcome, and increased patient satisfaction compared with other therapies. It can avoid infections from short-term as well as long-term complications such as urethral stricture. We performed subcoronal circumferential incision described before in almost all cases because of the excellent exposure of the 3 corpora, which avoids

accidental missing of a urethral injury or multiple injuries of the tunica. Management of associated urethral injuries is variable in literature, ranging from repair of the lesion when there is no complete section, like we did in the 2 cases reported, to complex cases where a total rupture and an anastomosis should be performed with a suprapubic cystostomy or bladder catheter placement.

Long-term complications following penile fracture repair may be painful erection, painful intercourse, skin necrosis, sensory loss, penile deviation, urethral stricture, and priapism [12]. After more than one year of follow-up our series showed satisfactory functional results in terms of maintained normal sexual function and absent penile curvature or scarring in most of cases.

There are also "false" penile fractures in which differential diagnose have to be done. They are usually characterized by gradual detumescence and absence of the cracking sound typically heard in penile fractures. Rupture of the dorsal vein or dorsal artery is the most commonly reported cause, and the consequent condition is indistinguishable from true corporal fracture except by cavernosography. Ruptured dorsal vein should be ligated when encountered during operation but can also be managed conservatively if diagnosed clinically [13].

## CONCLUSIONS

Rupture of the corpus cavernosum is a rare condition and is generally diagnosed by clinical findings. US is a useful technique for confirmation of clinically suspected corpus cavernosum rupture. Emergency surgical exploration and treatment is the best guarantee of good functional and cosmetic results.

## ABBREVIATIONS

PT – penile trauma  
US – ultrasonography  
CT – computerized tomography

## References

- McAninch JW, Santucci RA. Genitourinary trauma. In: Walsh PC, Retik AB, Vaughan ED, et al, eds. *Campbell's Urology*, vol 4; 10th ed. Philadelphia, PA: WB Saunders; 2012.
- Elke N. Fracture of the penis. *Br J Surg*. 2002; 89: 555–565.
- Ibrahiem el-HI, el-Tholoth HS, Mohsen T, Hekal IA, el-Assmy A. Penile Fracture: Long-term Outcome of Immediate Surgical Intervention. *Urology*. 2010; 108–111: 75.
- Koga S, Saito Y, Arakaki Y, Nakamura N, Matsuoka M, Saita H, et al. Sonography in fracture of the penis. *Br J Urol*. 1993; 72: 228–229.
- Rahmouni A, Hoznek A, Duron A, Colombel M, Chopin DK, Mathieu D, Vasile N. Magnetic resonance imaging of penile rupture: aid to diagnosis. *J Urol*. 1995; 153: 1927–1928.
- Chung CH, Szeto YK, Lai KK. "Fracture" of the penis: a case series. *Hong Kong Med J*. 2006; 12: 197–200.
- Pandyan GVS, Zaharani A, Al Rashid M. Fracture penis: analysis of 26 cases. *TSW. Urology*. 2006; 1: 32–38.
- el-Sherif AE, Dauleh M, Allowneh N, Vijayan P. Management of fracture of the penis in Qatar. *Br J Urol*. 1991; 68: 622–625.
- Martí de Gracia M, Muñiz Iriondo I, García Fresnadillo JP, Rodríguez Requena H, Matos A, Pinilla I. Corpus cavernosum fracture: The

- ultrasound in the emergency diagnosis. *Radiología*. 2013; 55: 154–159.
10. Koga S, Saito Y, Arakaki Y, Nakamura N, Matsuoka M, Saita H, et al. Sonography in fracture of the penis. *Br J Urol*. 1993; 72: 228–229.
11. Masarani M, Dinneen M. Penile fracture: diagnosis and management. *Trends Urol Gynaecol Sex Health*. 2007; 12: 20–24.
12. Muentener M, Suter S, Hauri D, Sulser T. Long-term experience with surgical and conservative treatment of penile fracture. *J Urol*. 2004; 172: 576–579.
13. Feki W, Derouiche A, Belhaj K, Ouni A, Ben Mouelhi S, Ben Slama MR, et al. False penile fracture: report of 16 cases. *Int J Impot Res*. 2007; 19: 471–473. ■