

# EFFICACY OF INHALED ILOPROST IN COR PULMONALE AND SEVERE PULMONARY HYPERTENSION ASSOCIATED WITH TUBERCULOUS DESTROYED LUNG

YAE MIN PARK, MD<sup>1,2</sup>, WOOK-JIN CHUNG, MD<sup>1,2</sup>, SANG PYO LEE, MD<sup>3</sup>, DEOK YOUNG CHOI, MD<sup>2,4</sup>, HAN JOO BAEK, MD<sup>5</sup>, SUNG HWAN JUNG, MD<sup>3</sup>, IN SUCK CHOI, MD<sup>1,2</sup>, AND EAK KYUN SHIN, MD<sup>1,2</sup>

<sup>1</sup>DIVISION OF CARDIOLOGY, HEART CENTER, <sup>2</sup>GACHON CARDIOVASCULAR RESEARCH INSTITUTE, <sup>3</sup>DIVISION OF PULMONOLOGY, <sup>4</sup>DEPARTMENT OF PEDIATRIC CARDIOLOGY, <sup>5</sup>DIVISION OF RHEUMATOLOGY, GACHON UNIVERSITY GIL MEDICAL CENTER, INCHEON, KOREA

Chronic obstructive pulmonary disease (COPD) is one of the causes of cor pulmonale. Cor pulmonale patients with pulmonary hypertension have a significant lower survival rate than patients without. However, there is no conclusive treatment options in cor pulmonale and pulmonary hypertension associated with COPD until now. We report a patient with cor pulmonale and pulmonary hypertension associated with severe form of COPD and tuberculous destroyed lung who achieved marked clinical, functional and echocardiographic hemodynamic improvements with inhaled iloprost for six months.

**KEY WORDS:** Cor pulmonale · Pulmonary hypertension · Tuberculous destroyed lung · Chronic obstructive pulmonary disease · Iloprost.

## INTRODUCTION

New molecular targeted drugs have rarely been used in cor pulmonale and there is no large randomized study evaluating the efficacy of inhaled iloprost in cor pulmonale and pulmonary hypertension associated with chronic obstructive pulmonary disease (COPD).

## CASE

A 51-year-old female patient with tuberculous destroyed lung was admitted to pulmonology department. The patient had been diagnosed COPD due to tuberculous destroyed lung for 10 years and she complained worsening dyspnea for several months. Her WHO/NYHA functional class was IV and 6-min walk test distance showed as 105 m. There was no evidence of other conditions associated with pulmonary hypertension. Chest radiography and a computed tomography revealed severely reduced volume of left lung due to tuberculous destroyed lung and bronchiectatic, emphysematous changes of right lung without evidence of pulmonary embolism (Fig. 1). Transthoracic echocardiography revealed massive right ven-

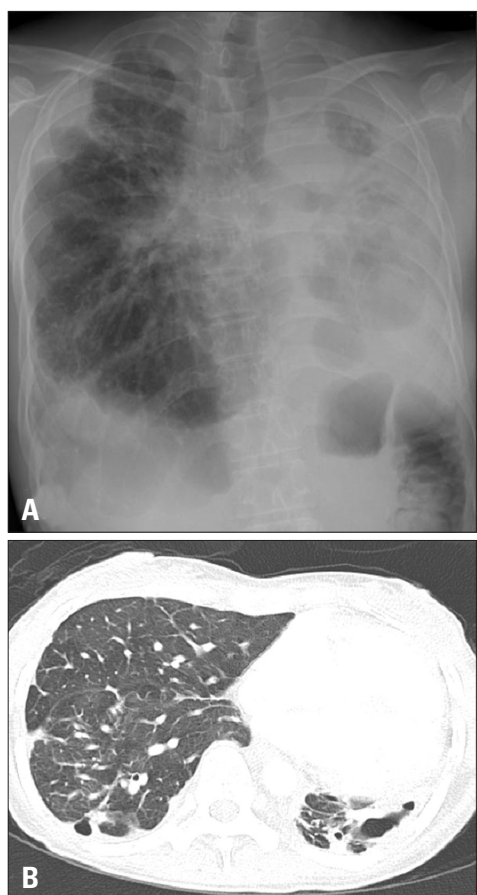
tricular and right atrial enlargement with moderate pulmonary hypertension, showing systolic pulmonary arterial pressure as 64 mmHg using the simplified Bernoulli formula and grade III of tricuspid regurgitation. Right ventricular hypertrophy was not shown. Left ventricular ejection fraction was normal but showed marked D-shaped left ventricle. Echocardiographic findings were compatible with cor pulmonale (Fig. 2). Pulmonary function studies demonstrated very severe airway obstruction with FEV<sub>1</sub>/FVC of 61% and FEV<sub>1</sub> of 0.48 L (21% of predicted), and severely reduced diffusing capacity of the lung for carbon monoxide at 6.5 mL/mmHg/min (40% of predicted). Arterial blood gas analysis on room air revealed pH 7.4; PaCO<sub>2</sub>, 50 mmHg; and PaO<sub>2</sub>, 45 mmHg with O<sub>2</sub> saturation of 81%.

She was on conventional medical therapy with bronchodilator, digoxin and oxygen therapy continuously for more than six months but symptoms and echographic hemodynamics did not improve. Therefore, inhaled iloprost was started and increased to a maintenance dose of 10 µg four times per day. She tolerated iloprost well without complications. After six

• Received: November 24, 2013 • Revised: April 2, 2014 • Accepted: May 15, 2014

• Address for Correspondence: Wook-Jin Chung, Division of Cardiology, Gachon University Gil Medical Center, 21 Namdong-daero 774beon-gil, Namdong-gu, Incheon 405-760, Korea Tel: +82-32-460-8305, Fax: +82-32-469-1906, E-mail: heart@gilhospital.com

• This is an Open Access article distributed under the terms of the Creative Commons Attribution Non-Commercial License (<http://creativecommons.org/licenses/by-nc/3.0>) which permits unrestricted non-commercial use, distribution, and reproduction in any medium, provided the original work is properly cited.

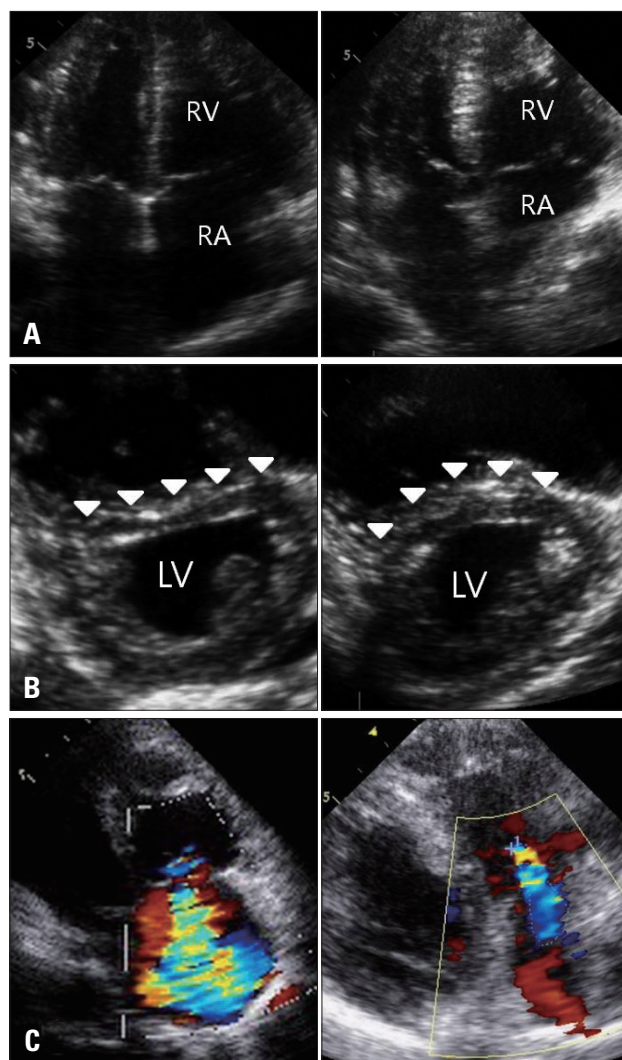


**Fig. 1.** Chest radiography (A) and a computed tomography (B) reveals severely reduced volume of left lung due to tuberculous destroyed lung and bronchiectatic, emphysematous changes of both lungs.

months from starting iloprost, the patient reported less breathlessness and her WHO/NYHA functional class improved to III. And her 6-min walk test distance improved to 264 m. Follow-up echocardiography showed improvement in hemodynamic variables; right ventricular and right atrial dimensions were decreased, systolic pulmonary arterial pressure was decreased as 45 mmHg, the degree of tricuspid regurgitation was decreased as only trivial and slight D-shaped left ventricle (Fig. 2).

## DISCUSSION

Advanced lung disease can result pulmonary hypertension and potential progression to cor pulmonale and right heart failure. Pulmonary hypertension is an important complication of COPD and a prognostic factor of survival. COPD patients with pulmonary hypertension have significant worse 5-year survival rate (36%) compared with COPD patients without pulmonary hypertension (62%).<sup>1)</sup> Management of cor pulmonale with pulmonary hypertension associated includes treating the underlying lung disease, providing supplemental oxygen and treating the right heart failure. Long-term supplemental oxygen and optimal bronchodilator therapy are the primary



**Fig. 2.** Initial (left panels) and follow-up echocardiogram (right panels) after receiving iloprost shows improvements in echocardiographic hemodynamic variable. A: Massive right ventricular and right atrial enlargement (left) and decreased right ventricular and right atrial dimensions (right). B: Flattened interventricular septum (arrowheads) and D-shaped left ventricle (left) and slightly improved septal flattening and D-shaped left ventricle (right). C: Grade III of tricuspid regurgitation (left) and trivial tricuspid regurgitation (right). LV: left ventricle, RA: right atrium, RV: right ventricle.

therapies for pulmonary hypertension associated with COPD, however, they have limitations in patients with cor pulmonale and pulmonary hypertension due to tuberculous destroyed lung. Our patient worsened despite continuous oxygen and proper bronchodilator therapy. Pulmonary arterial hypertension-specific molecular targeted therapies include prostanoids, endothelin receptor antagonists, and phosphodiesterase-5 inhibitors but there are limited studies evaluating the efficacies of these drugs in COPD, particularly cor pulmonale and pulmonary hypertension associated with severe form of COPD patients who are refractory to conventional medical therapy.

There are several studies showing the efficacy of inhaled iloprost in different categories of pulmonary hypertension pa-

tients. Daily dose of 100 or 150 µg of inhaled iloprost more than one year improved symptom, hemodynamics and exercise capacity significantly in patients with pulmonary arterial hypertension.<sup>2)</sup> However, conflicting long-term clinical efficacy as the first line vasodilator monotherapy in idiopathic pulmonary arterial hypertension patients was reported. In this study, overall survival at 5 years was 49% (95% confidence interval; 33–65), event free survival (defined as death, transplantation or switch to other drug) at 5 years was only 13% and only 5% continued iloprost at five year. This study concluded only a minority of patients could be stabilized and chronic inhaled iloprost as a monotherapy has a limited role.<sup>3)</sup> New molecular targeted drugs have rarely been used in cor pulmonale and there is only one small randomized study evaluating the efficacy of inhaled iloprost in cor pulmonale and pulmonary hypertension associated with COPD subjects. Acute effects of aerosolized iloprost in COPD related pulmonary hypertension was evaluated in small number of randomized controlled crossover study. Both low dose (10 µg) and high dose (20 µg) of iloprost failed to improve exercise capacity measured in six-minute walking distance.<sup>4)</sup> Only one case of COPD patient who showed beneficial effect of iloprost was reported.<sup>5)</sup> Our patient showed more severe form of COPD and had already progressed to cor pulmonale. Inhaled iloprost resulted in improvement of clinical, functional and echocardiographic hemodynamics in our patient.

The use of molecular targeted therapy in COPD patients with pulmonary hypertension is discouraged because of the potential detrimental effect on gas exchange.<sup>6)</sup> However, inhaled iloprost has potential to act preferentially in ventilated regions of the lung and recently, it was confirmed that improves ventilation/perfusion mismatch, thereby improves gas exchange and exercise tolerance and reducing pulmonary hypertension.<sup>7)</sup> Moreover, it has a selective vasodilator effect on pulmonary vasculature thus reducing the adverse systemic effects peculiar to epoprostenol. Its action is not limited to the relaxation of pulmonary vascular smooth muscle, but also improves the pulmonary clearance of endothelin 1 and inhibits platelet aggregation, vascular remodeling, and vascular cell proliferation and migration.<sup>8,9)</sup>

We report a patient with cor pulmonale and pulmonary hy-

pertension associated with severe form of COPD and tuberculous destroyed lung who achieved marked clinical, functional and hemodynamic improvements with inhaled iloprost for six months. Especially inhaled iloprost among molecular targeted therapy can be considered as an alternative treatment option in selective patients with cor pulmonale and pulmonary hypertension who are refractory to conventional medical therapy. Long term efficacy and effective proper dose of inhaled iloprost remains to be further evaluated through randomized controlled study.

## REFERENCES

1. Oswald-Mammosser M, Weitzenblum E, Quoix E, Moser G, Chaouat A, Charpentier C, Kessler R. *Prognostic factors in COPD patients receiving long-term oxygen therapy. Importance of pulmonary artery pressure. Chest* 1995;107:1193-8.
2. Hoepfer MM, Schwarze M, Ehlerding S, Adler-Schuermeier A, Spiekerkoetter E, Niedermeyer J, Hamm M, Fabel H. *Long-term treatment of primary pulmonary hypertension with aerosolized iloprost, a prostacyclin analogue. N Engl J Med* 2000;342:1866-70.
3. Opitz CF, Wensel R, Winkler J, Halank M, Bruch L, Kleber FX, Höffken G, Anker SD, Negassa A, Felix SB, Hetzer R, Ewert R. *Clinical efficacy and survival with first-line inhaled iloprost therapy in patients with idiopathic pulmonary arterial hypertension. Eur Heart J* 2005; 26:1895-902.
4. Boeck L, Tamm M, Grendelmeier P, Stolz D. *Acute effects of aerosolized iloprost in COPD related pulmonary hypertension - a randomized controlled crossover trial. PLoS One* 2012;7:e52248.
5. Hegewald MJ, Elliott CG. *Sustained improvement with iloprost in a COPD patient with severe pulmonary hypertension. Chest* 2009;135:536-7.
6. Barberà JA, Blanco I. *Pulmonary hypertension in patients with chronic obstructive pulmonary disease: advances in pathophysiology and management. Drugs* 2009;69:1153-71.
7. Dernaika TA, Beavin M, Kinasewitz GT. *Iloprost improves gas exchange and exercise tolerance in patients with pulmonary hypertension and chronic obstructive pulmonary disease. Respiration* 2010;79:377-82.
8. Wilkens H, Bauer M, Forestier N, König J, Eichler A, Schneider S, Schäfers HJ, Sybrecht GW. *Influence of inhaled iloprost on transpulmonary gradient of big endothelin in patients with pulmonary hypertension. Circulation* 2003;107:1509-13.
9. Opitz CF, Wensel R, Bettmann M, Schaffarczyk R, Linscheid M, Hetzer R, Ewert R. *Assessment of the vasodilator response in primary pulmonary hypertension. Comparing prostacyclin and iloprost administered by either infusion or inhalation. Eur Heart J* 2003;24:356-65.