

Received: 2011.08.15  
Accepted: 2012.01.17  
Published: 2012.09.01

## Ketamine, propofol and low dose remifentanil versus propofol and remifentanil for ERCP outside the operating room: Is ketamine not only a “rescue drug”?

### Authors' Contribution:

- A** Study Design
- B** Data Collection
- C** Statistical Analysis
- D** Data Interpretation
- E** Manuscript Preparation
- F** Literature Search
- G** Funds Collection

Lea Paola Fabbri<sup>1ACDEF</sup>, Maria Nucera<sup>1ABF</sup>, Massimo Marsili<sup>1EG</sup>,  
Mohamed Al Malyan<sup>2GDEF</sup>, Chiara Becchi<sup>1ACDEF</sup>

<sup>1</sup> Anaesthesia and Intensive Care, Departmen. of Medical and Surgical Specialties, AOUC Careggi, Florence, Italy

<sup>2</sup> Anesthesia Unit, Villa Donatello, Florence, Italy

**Source of support:** Departmental sources

### Summary

#### Background:

Endoscopic retrograde cholangiopancreatography ERCP is a painful and long procedure requiring transient deep analgesia and conscious sedation. An ideal anaesthetic that guarantees a rapid and smooth induction, good quality of maintenance, lack of adverse effects and rapid recovery is still lacking.

This study aimed to compare safety and efficacy of a continuous infusion of low dose remifentanil plus ketamine combined with propofol in comparison to the standard regimen dose of remifentanil plus propofol continuous infusion during ERCP.

#### Material/Methods:

322 ASAI-III patients, 18–85 years old and scheduled for planned ERCP were randomized. Exclusion criteria were a predictable difficult airway, drug allergy, and ASA IV-V patients.

We evaluated Propofol 1 mg/kg/h plus Remifentanil 0.25 µg/kg/min (GR) *vs.* Propofol 1 mg/kg/h plus Ketamine 5 µg/kg/min and Remifentanil 0.1 µg/kg/min (GK).

Main outcome measures were respiratory depression, nausea/vomiting, quality of intraoperative conditions, and discharge time.  $P < 0.05$  was statistically significant (95% CI).

#### Results:

Respiratory depression was observed in 25 patients in the GR group compared to 9 patients in the GK group ( $p = 0.0035$ ). ERCP was interrupted in 9 cases of GR *vs.* no cases in GK; patients ventilated without any complication. Mean discharge time was  $20 \pm 5$  min in GK and  $35 \pm 6$  min in GR ( $p = 0.0078$ ) and transfer to the ward delayed because of nausea and vomiting in 30 patients in GR *vs.* 5 patients in GK ( $p = 0.0024$ ). Quality of intraoperative conditions was rated highly satisfactory in 92% of GK *vs.* 67% of GR ( $p = 0.028$ ).

#### Conclusions:

The drug combination used in GK confers clinical advantages because it avoids deep sedation, maintains adequate analgesia with conscious sedation, and achieves lower incidence of postprocedural nausea and vomiting with shorter discharge times.

#### key words:

conscious sedation for ERCP • ketamine • sedation outside the operating room

#### Full-text PDF:

<http://www.medscimonit.com/fulltxt.php?ICID=883354>

#### Word count:

2307

#### Tables:

2

#### Figures:

1

#### References:

38

#### Author's address:

Chiara Becchi, Anaesthesia and Intensive Care, Department of Medical and Surgical Specialties, AOUC Careggi, Viale Pieraccini, 6, I-50100 Florence, Italy, e-mail: chiarabecchi@hotmail.com

## BACKGROUND

Procedural sedation and monitored anaesthesia care for several endoscopic procedures have become increasingly common in locations outside the operating room. Among these, endoscopic retrograde cholangiopancreatography (ERCP) is a painful and long procedure that requires transient deep analgesia associated with a conscious sedation to guarantee the maintenance of cough reflex, spontaneous breathing and cardiovascular stability [1].

An ideal anaesthetic that guarantees a rapid and smooth induction, good quality of maintenance, lack of adverse effects and rapid recovery is still lacking.

Propofol is widely used for sedation because of its pharmacological characteristics and rapid recovery profile. Unfortunately, it is not an analgesic, and high doses are often required during painful procedures [2]. Interventional endoscopy under propofol sedation is not risk-free in terms of respiratory adverse effects, particularly when undertaking long-duration interventions [3].

Remifentanyl, an ultra-short-acting opioid, has advantages over other opioids because of its rapid onset and offset times, making it suitable for administration by continuous infusion during procedures. Many studies have compared the effective analgesic, sedative and amnesic doses, recovery profiles, adverse effects and safety of remifentanyl and propofol infusions, with or without other sedatives, in monitored care anaesthesia [4,5]. However, remifentanyl infusion may cause respiratory depression and nausea/vomiting.

Ketamine's ability to produce sedation-analgesia without clinically significant respiratory depression might offer an advantage over techniques using only opioid drugs [6]. Although ketamine, also combined with propofol infusion, has been proved to be safe and effective in pediatric patients [7,8] and in the emergency department [9,10] its use in adult advanced endoscopy is not yet widely accepted.

The present study aimed to compare the administration of ketamine/propofol/low dose remifentanyl versus propofol/normal dose remifentanyl drug combinations during ERCP procedures in terms of respiratory depression, post-procedural incidence of nausea/vomiting, quality of intra-operative conditions, and discharge time.

## MATERIAL AND METHODS

After obtaining written informed consent from patients, 330 consecutive ASA I-III patients, between 18 and 85 years of age and scheduled for planned ERCP outside the operating room were assessed for eligibility at Careggi Florence Hospital during the period between January 2006 and December 2007. Exclusion criteria were patients with a predictable difficult airway, with drugs allergy, and ASA physical status IV-V.

All patients had a pre-endoscopic assessment that included a complete blood count, serum liver chemistries, coagulation studies, and abdominal ultrasound or other appropriate imaging studies. Intravascular access was established with an 18 gauge canula in a vein of the dorsum of the hand.

Patients were monitored with ECG, non-invasive blood pressure, SpO<sub>2</sub>, and impedance pneumography for respiratory rate. Patients were given supplemental oxygen intranasally (4 liters/min), and premedicated with 0.01 mg/kg i.v. of atropine and 1 mg i.v. of midazolam.

According to a computer-generated randomization sequence table, patients were allocated to Group R (GR: Remifentanyl + Propofol) or to Group K (GK: Ketamine + Remifentanyl + Propofol) by a nurse not involved in the procedure. To ensure the blindness of the study, the same infusing pumps and syringes were prepared and covered for both groups. All parameters were collected by the same physician, who was blinded to group allocation. All the nurses involved in the procedure and all the endoscopists were blinded to group allocation.

Four min before starting the procedure, GR patients received Remifentanyl 0.25 µg/kg/min and GK patients received Ketamine 5 µg/kg/min and Remifentanyl 0.1 µg/kg/min. Thereafter, both groups received Propofol 1 mg/kg as a bolus dose over 30 sec.

The level of sedation during the procedure was targeted towards a conscious sedation plus a deep analgesia as a bridge between the second and third degree of ASA classification [11].

The maintenance was performed with a continuous infusion of propofol 1mg/kg/h plus remifentanyl infusion 0.25 µg/kg/min in GR, or plus Ketamine 5 µg/kg/min and remifentanyl 0.1 µg/kg/min infusion in GK, respectively.

Hypnotic supplementation with propofol 0.25 mg/kg was given when required as indicated by patient movement, tachycardia, hypertension or manifested discomfort.

All drug infusions were stopped at the end of the procedure.

Physiologic parameters such as heart rate, respiratory rate and oxygen saturation were monitored continuously and non-invasive blood pressure, at the beginning of procedure, on the first, fifth minute and every 5 minutes until transfer of the patient to the postanesthetic recovery room (PARR). After completion of ERCP, patients were transferred to the PARR where blood pressure, heart rate, SpO<sub>2</sub>, respiratory rate, level of consciousness and adverse effects such as nausea, vomiting and respiratory depression were evaluated at 5-min intervals. Respiratory depression was defined as oxygen saturation of less than 92% at any time during the procedure, or airway obstruction with apnea at any time.

Adverse effects were defined as cough, vomit, discomfort during the procedure, interruption of the procedure and assisted manual ventilation.

"Emergence reactions" were defined as vivid dreaming, extracorporeal experiences (sense of floating out of one's body) and illusions (misinterpretation of a real and external sensory experience) [12].

The entire length of analgosedation was recorded, as well as time to respond appropriately to verbal command and to establish alertness (orientation, simple addition and date

**Table 1.** Post-Anesthetic Recovery (PAR) score [11].

Score	Motor performance
2	Able to move four extremities voluntarily or on command
1	Able to move two extremities voluntarily or on command
0	Able to move no extremities voluntarily or on command
Breathing	
2	Able to breath deeply and cough freely
1	Dyspnoea or limited breathing
0	Apnoea
Consciousness	
2	Fully awake
1	Arousable on calling
0	Not responding
Pain claimed by patient	
3	None
2	Uncomfortable
1	Moderate
0	Severe

of birth). A PAR score (post-anaesthetic recovery) was completed for all patients at 1, 5, 10, 15 min after arrival in the recovery room [13]. We considered a PAR score (Table 1) of 9 as indicating a fully alert patient without any pain. Patients were considered ready for discharge when they had stable vital signs, were oriented and showed no adverse-effects. Discharge time was defined as time from the end of drug infusion until transfer to the ward. Quality of intraoperative conditions, referred to analgesia, sedation, amnesia and overall level of comfort, was evaluated by a blinded endoscopist with a 4-point rating scale as follows: 1 – highly satisfactory; 2 – satisfactory; 3 – somewhat satisfactory; and 4 – unsatisfactory [14].

The study was been carried out according to the ethical standards of the responsible regional committee on human experimentation and the Helsinki Declaration principles [15] and was been approved by the Internal Review Board of our Department.

**Statistical analysis**

The calculation of sample size for this study was based on previous literature [2,7,8,11]. It was computed that a sample of 35 patients per group would detect a difference in SpO2 values of more than 7%, and in discharge time of more than 1.5 times with a power of 90% and a 2-tailed significance level of 5% ( $\beta=0.1$ ,  $\alpha=0.05$ ). The Kruskal-Wallis test was used for the analysis of demographic parameters. Data are expressed as mean  $\pm$ SD or ratio. The difference

**Table 2.** Patient characteristics. Data are expressed as mean  $\pm$  SD or ratio.

	GK (n=160) Ketamine + Remifentanyl + Propofol	GR (n=162) Remifentanyl + Propofol
Age (yrs)	73 $\pm$ 5.6	72 $\pm$ 8.6
Gender (male/female)	75/85	73/89
ASA Status (I/II/III)	7/123/30	9/117/36
Plastic biliary stent/ wall-stent/pancreatic balloon or catheter dilation /biliary stone extraction with sphincterectomy/ duodenal ampullectomy	26/17/6/110/4	24/13/4/112/6
ERCP duration (min)	75 $\pm$ 30	65 $\pm$ 25

n – number of patients; ASA – American Society of Anesthesiologists.

between groups was evaluated by the Mann-Whitney test for non-parametric data. A value of  $P \leq 0.05$  was considered statistically significant. A 95% confidence interval was applied. STATA software 8.0 for Windows (Stata Corporation, College Station, TX) was used for the statistical analysis.

**RESULTS**

Among 330 consecutive patients assessed for eligibility, 322 patients were randomized in this prospective randomized-controlled study between January 2006 and December 2007. No differences between groups were found in terms of mean age, sex, ASA physical status, type of procedure, and ERCP duration (Table 2).

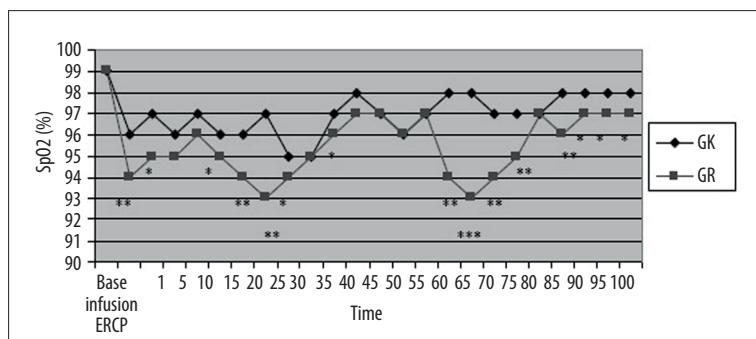
Quality of intraoperative conditions was rated highly satisfactory in 92% GK and in 67% of GR ( $p=0.028$ ).

During all the procedure SpO2 values were lower in GR and statistically different from those in GK (Figure 1). In particular, respiratory depression was observed in 25 GR patients, as opposed to 9 GK patients ( $p=0.0035$ ). In 9 GR cases *vs.* no GK cases, ERCP was interrupted, and the patient was aroused and manually ventilated without any cardiopulmonary complications.

The total amount of propofol dose administered ranged between 122–192 mg in GK and 117–175 mg in GR in relation to procedure duration. In 3 GK patients and in 5 GR patients, 2 propofol boluses per patient were required as hypnotic supplementation, without any significant difference between groups.

No differences in cardiovascular parameters were found between groups.

Time to reach PAR score of 9 was 3 $\pm$ 1 min in GK and 8 $\pm$ 2 in GR ( $p=0.0063$ ) and mean discharge time to the ward was 20 $\pm$ 5 min in GK as opposed to 35 $\pm$ 6 min in GR ( $p=0.0078$ ). Transfer to the ward of 30 GR patients *vs.* 5 GK patients



**Figure 1.** Mean values of oxygen saturation (SpO<sub>2</sub>) in patients receiving remifentanyl infusion (GR) or remifentanyl plus ketamine infusion (GK) at baseline (base), after 4 min of drug administration (infusion), after the beginning of procedure (ERCP), at 1<sup>st</sup>, 5<sup>th</sup> min and every 5 minutes up to 100 min. \* p<0.05, \*\* p<0.001, \*\*\* p<0.0001.

was delayed because of nausea and vomiting ( $p=0.0024$ ). No “emergence reactions” were observed.

## DISCUSSION

Endoscopic procedures have to meet several requirements, such as satisfactory but safe sedation, while also allowing complete examination and rapid discharge time. Several studies have tried to compare different drug combinations [12,16,17]; however, a major cornerstone of anaesthesia for ERCP procedures should be the achievement of conscious sedation combined with deep analgesia. This allows the patient to respond to verbal stimuli and to maintain both cardiovascular and respiratory balance.

This study demonstrates that combined continuous infusion of ketamine and remifentanyl plus propofol is able to maintain conscious sedation and deep analgesia in patients undergoing ERCP, thus reducing the risk for respiratory depression and need for airway support.

Propofol is an anaesthetic drug widely used to perform ERCP [18–22]. However, because of its narrow therapeutic window, close patient monitoring is recommended to avoid over-sedation, particularly if combined with other drugs such as opioids [3,23]. This is particularly true in ASA II-III patients, usually undergoing ERCP procedures and possibly affected by cardiovascular, respiratory and metabolic co-morbidities.

Remifentanyl, a  $\mu$ -opioid receptor agonist, has been successfully used as the analgesic component of sedation techniques for endoscopic procedures [24,25]. Remifentanyl is predominantly metabolized by non-specific esterases, with extremely rapid clearance and offset of effect. The half-life of remifentanyl is very short, ranging between 3-5 min, and it is frequently used alone or combined with propofol. However, an expected adverse effect of remifentanyl administration, well known among opioids, is respiratory depression. This is more frequently observed with rates of infusion above 0.2  $\mu\text{g}/\text{kg}/\text{min}$  [22] and remains an important clinical and safety drawback. Therefore, to minimize risk of respiratory depression, in our study no bolus dose of remifentanyl was administered. Nevertheless, we observed 9 cases of deep respiratory depression in GR that required interruption of the procedure and manual ventilation over a few minutes.

To minimize adverse effects of remifentanyl on respiratory drive while also maintaining a good level of analgesia, ketamine was added.

Ketamine is a phencyclidine analogue, and acts as a non-competitive inhibitor of the N-methyl-D-aspartate (NMDA) receptor in the central nervous system by binding to the phencyclidine recognition site in the NMDA receptor ion-channel complex [26]. Analgesic doses of ketamine appear to be mediated by this non-opioid phencyclidine receptor mechanism in both experimental and postoperative pain. Additionally, laboratory studies have found the primary metabolite of ketamine, norketamine, also to have antinociceptive properties and to inhibit NMDA receptor function stereoselectively at the spinal and the supraspinal levels [27,28]. In this way, use of ketamine has been reported to reduce opioid requirements for its synergistic pharmacodynamic effects [29,30]. Moreover, the wide safety margins of ketamine allow its use in procedures where protection of airway reflexes is mandatory. Another useful characteristic of ketamine is its efficacy in maintaining cardiovascular balance. However, no significant differences in cardiovascular parameters have been found between groups. Nevertheless, until now ketamine was used only as a “rescue drug” to achieve an effective and safe sedation in adult and pediatric patients characterized by inadequate sedation undergoing advanced endoscopic procedures or for procedures in the emergency department [7–10].

In our prospective randomized study we propose the routine use of continuous infusion of subanesthetic doses of Ketamine. Its combination with low doses of remifentanyl plus propofol infusion has been demonstrated to be a safe and effective technique to achieve conscious sedation and deep analgesia, which is very desirable for all endoscopic procedures performed outside the operating room. In this setting it is mandatory to avoid deep sedation because this could inadvertently progress to general anaesthesia with loss of protective airway reflexes [31,32]. In a study involving 80 healthy outpatients undergoing various endoscopic procedures who were given midazolam and remifentanyl to achieve moderate sedation, deep sedation occurred in 68% of all patients, but varied with procedure type – 45% colonoscopy, 60% EGDS, 80% endoscopic ultrasound and 85% ERCP [17].

Several concerns have been raised regarding routine use of ketamine in endoscopic procedures. Among these, the risk of “emergence reactions” during waking has been reported [33]. These adverse effects are reported more frequently when large and rapid doses are administered. In our study no cases of emergence reactions were reported. This is probably due to the relatively small and slow doses of Ketamine (5  $\text{mcg}/\text{kg}/\text{min}$ ) used in our protocol in comparison to “standard” doses [12].



One of the main problems inherent in sedation technique when using propofol is the difficulty in adequately monitoring depth of respiration [34,35]. Capnography is considered to be a useful adjunct in the assessment of ventilator states of patients undergoing sedation and analgesia [36]. In our setting, capnographic monitoring has not been used, even though respiratory rate has been measured by impedance pneumography. However, capnography has been reported to be a more precise measure of ventilation [37]. This is undoubtedly a limitation of our study. However, we used low doses of propofol, ensuring deep analgesia coupled with conscious sedation to maintain continuous verbal contact between the patient and anesthesiologist. Moreover, patient safety and comfort were ensured by left lateral decubitus, avoiding the more dangerous semi-prone position. Until now no data have been available regarding clinical endpoints (e.g., severe hypoventilation with clinical consequences) when capnography is not used in gastrointestinal endoscopy [38].

## CONCLUSIONS

Subanesthetic doses of Ketamine combined with a standard infusion regimen of low dose remifentanyl with continuous propofol infusion should be widely used in ERCP procedures for its safe and convenient profile. This combination confers clinical advantages. In fact, it effectively avoids deep sedation, maintains adequate analgesia with conscious sedation, and results in less incidence of post-procedural nausea and vomiting, with shorter discharge times. Therefore, our “take home” message is that ketamine has to be considered to be not only a “rescue drug”, but also as a strongly advisable drug for use in settings outside the operating room.

## REFERENCES:

- Jamieson J: Anesthesia and sedation in the endoscopy suite? (Influences and opinions). *Curr Opin Anesthesiol*, 1999; 12: 417–23
- Ackaboy ZN, Ackaboy EY, Albayrak D et al: Can remifentanyl be a better choice than propofol for colonoscopy during monitored anesthesia care? *Acta Anaesthesiol Scand*, 2006; 50: 736–41
- Wehrmann T, Riphaut A: Sedation with propofol for interventional endoscopic procedures: a risk factor analysis. *Scand J Gastroenterol*, 2008; 43: 368–74
- Rosow C: Remifentanyl: a unique opioids analgesic. *Anesthesiology*, 1993; 78: 875–76
- Medina HJ, Galvin EM, Dirckx M et al: Remifentanyl as a single drug for extracorporeal shock wave lithotripsy: a comparison of infusion doses in terms of analgesic potency and side effects. *Anesth Analg*, 2005; 101: 365–70
- Fabbri LP, Batacchi S, Linden M et al: Anaesthesia for urologic endoscopic procedures in adult outpatients. *Eur J Anaesthesiol*, 1995; 12: 319–24
- van Beek EJ, Leroy PL: Safe and Effective Procedural Sedation For Gastro-Intestinal Endoscopy In Children: A Systematic Review. *J Pediatr Gastroenterol Nutr*, 2011
- Chiaretti A, Ruggiero A, Barbi E et al: Comparison of propofol versus propofol-ketamine combination in pediatric oncologic procedures performed by non-anesthesiologists. *Pediatr Blood Cancer*. 2011; 57(7): 1163–67
- Nejati A, Moharari RS, Ashraf H et al: Ketamine/propofol versus midazolam/fentanyl for procedural sedation and analgesia in the emergency department: a randomized, prospective, double-blind trial. *Acad Emerg Med*, 2011; 18(8): 800–6
- Smally AJ, Nowicki TA, Simelton BH: Procedural sedation and analgesia in the emergency department. *Curr Opin Crit Care*, 2011; 17(4): 317–22
- American Society of Anesthesiologists Task Force on Sedation and Analgesia by Non-Anesthesiologists: Practice guidelines for sedation and analgesia by non-anesthesiologists. *Anesthesiology*, 2002; 96: 1004–17
- Varadarajulu S, Eloubedi MA, Tamhane A et al: Prospective randomized trial evaluating ketamine for advanced endoscopic procedures in difficult to sedate patients. *Aliment Pharmacol Ther*, 2007; 25: 987–97
- Aldrete JA: A post-anesthesia recovery score revisited. *J Clin Anesth*, 1995; 7: 89–91
- Abu-Shahwan I, Mack D: Propofol and remifentanyl for deep sedation in children undergoing gastrointestinal endoscopy. *Pediatric Anesthesia*, 2007; 17: 460–63
- World Medical Association: Ethical principles for medical research involving human subjects. *Eur J Emerg Med*, 2001; 8: 221–24
- El-Bitar N, Sfeir S: Evaluation of remifentanyl in endoscopic retrograde cholangiopancreatography. *Middle East J Anesthesiol*, 2006; 18: 1209–16
- Trummel J: Sedation for gastrointestinal endoscopy: the changing landscape. *Curr Opin Anaesthesiol*, 2007; 20: 359–64
- Jung M, Hofman C, Kiesslich R et al: Improved sedation in diagnostic and therapeutic ERCP: propofol is an alternative to midazolam. *Endoscopy*, 2000; 32: 233–38
- Wehrmann T, Grotkamp J, Stergiou N et al: Electroencephalogram monitoring facilitates sedation with propofol for routine ERCP: a randomized, controlled trial. *Gastrointest Endosc*, 2002; 56: 817–24
- Seifert H, Schmitt TH, Gultekin T et al: Sedation with propofol plus midazolam versus propofol alone for interventional endoscopic procedures: a prospective randomized study. *Aliment Pharmacol Ther*, 2000; 14: 1207–14
- Van Natta ME, Rex DK: Propofol alone titrated to deep sedation versus propofol in combination with opioids and/or benzodiazepines and titrated to moderate sedation for colonoscopy. *Am J Gastroenterol*, 2006; 101: 2209–17
- Moerman AT, Foubert LA, Herregods LL et al: Propofol versus remifentanyl for monitored anesthesia care during colonoscopy. *Eur J Anaesthesiol*, 2003; 20: 461–66
- Rudner R, Jalowiecki JM, Kawecki P et al: Conscious analgesia/sedation with remifentanyl and propofol versus total intravenous anaesthesia with fentanyl, midazolam and propofol for outpatient colonoscopy. *Gastrointest Endosc*, 2003; 57: 657–63
- Bouvet L, Allaouchiche B, Duflo F et al: Remifentanyl is an effective alternative to propofol for patient-controlled analgesia during digestive endoscopic procedures. *Can J Anesth*, 2004; 51: 122–25
- Glass PS, Gan TJ, Howell S: A review of the pharmacokinetics and pharmacodynamics of remifentanyl. *Anaesth Analg*, 1999; 89: S7–14
- Church L, Lodge D: N-methyl-D-aspartate antagonism is central to the actions of ketamine and other phencyclidine receptor ligands. In: Domino EF (ed.). *Status of ketamine in Anesthesiology*. Ann Arbor: NPP Books, 1990; 501–19
- Maurset A, Skoglund LA, Hustveit O, Oye I: Comparison of ketamine and pethidine in experimental and postoperative pain. *Pain*, 1989; 36: 37–41
- Oye I, Paulsen O, Maurset A: Effects of ketamine on sensory perception: Evidence for a role of NMDA receptors. *J Pharmacol Exp Ther*, 1992; 260: 1209–60
- Menigaux C, Fletcher D, Dupont X et al: The benefits of intraoperative small-dose Ketamine on postoperative pain after anterior cruciate ligament repair. *Anesth Analg*, 2000; 90: 129–35
- Guignard B, Coste C, Costes H et al: Supplementing desflurane-remifentanyl anesthesia with small-dose Ketamine reduces perioperative opioid analgesic requirements. *Anesth Analg*, 2002; 95: 103–8
- Patel S, Vargo JJ, Khandwala F et al: Deep sedation occurs frequently during endoscopy with meperidine and midazolam. *Am J Gastroenterol*, 2005; 100: 2689–95
- Pino RM: The nature of anesthesia and procedural sedation outside of the operating room. *Curr Opin Anaesthesiol*, 2007; 20: 347–51
- Garfield JM, Garfield FB, Stone JG et al: A comparison of psychologic responses to ketamine and thiopental – nitrous oxide – halothane anesthesia. *Anesthesiology*, 1972; 36: 329–38
- Wilson S, McCluskey A: Use of capnography during endoscopic retrograde cholangio-pancreatography. *Anaesthesia*, 2008; 63: 1016–17
- Cacho G, Pérez-Calle JL, Barbado A et al: Capnography is superior to pulse oximetry for the detection of respiratory depression during colonoscopy. *Rev Esp Enferm Dig*, 2010; 102: 86–89
- Yarchi D, Cohen A, Umansky T et al: Assessment of end-tidal carbon dioxide during pediatric and adult sedation for endoscopic procedures. *Gastrointest Endosc*, 2009; 69: 877–82

37. Qadeer MA, Vargo JJ, Dumot JA et al: Capnographic monitoring of respiratory activity improves safety of sedation for endoscopic cholangiopancreatography and ultrasonography. *Gastroenterology*, 2009; 136: 1568-76
38. Riphaus A, Wehrmann T, Weber B et al: S3 Guideline: Sedation for gastrointestinal endoscopy 2008. *Endoscopy*, 2009; 41: 787-815