



Since January 2020 Elsevier has created a COVID-19 resource centre with free information in English and Mandarin on the novel coronavirus COVID-19. The COVID-19 resource centre is hosted on Elsevier Connect, the company's public news and information website.


Elsevier hereby grants permission to make all its COVID-19-related research that is available on the COVID-19 resource centre - including this research content - immediately available in PubMed Central and other publicly funded repositories, such as the WHO COVID database with rights for unrestricted research re-use and analyses in any form or by any means with acknowledgement of the original source. These permissions are granted for free by Elsevier for as long as the COVID-19 resource centre remains active.



ACADEMIA ESPAÑOLA
DE DERMATOLOGÍA
Y VENEREOLOGÍA

ACTAS Dermo-Sifiliográficas

Full English text available at
www.actasdermo.org



CASE AND RESEARCH LETTER

Auricular Pseudocysts After Prolonged Protective Mask Wearing for SARS-CoV2

Pseudoquistes auriculares tras el uso prolongado de mascarillas como protección para el SARS-CoV2

Dear Editor,

Auricular pseudocyst is a rare benign condition clinically manifested as a painless, fluctuant cystic nodule secondary to intracartilagenous fluid accumulation on the lateral or anterior surface of the ear, usually in the scaphoid or triangular fossa. The etiology is unknown, although chronic low-grade trauma and congenital embryonic dysplasia of the auricular cartilage have been postulated as predisposing factors. We report the case of a patient with bilateral and synchronous auricular pseudocysts that appeared after prolonged wearing of protective masks during the COVID-19 pandemic.

A 35-year-old man presented with slightly tender lesions in both ears that had appeared two months after prolonged wearing (more than 8 h per day) non-approved protective masks against SARS-CoV2. The patient denied any local major trauma. Physical examination revealed 5–10 mm, elastic, erythematous nodules, located in both left and right upper helix, antihelix and scaphoid fossas of both ears (Fig. 1A). Ultrasounds revealed a hypoechoic cystic lesion with anechoic content and posterior reinforcement with increased cartilage thickness (Fig. 1B). No increased intralesional or perilesional blood flow in the Doppler images were noted. Fine needle aspiration showed a viscous straw-yellow fluid that was sterile after culture. A 3 mm punch showed an intracartilaginous cleft devoid of epithelial lining and focal eosinophilic hyaline degeneration of the cartilage along the internal border of the cystic space. The overlying dermis showed a perivascular lymphocytic infiltrate (Fig. 1C). Considering the diagnosis of bilateral auricular pseudocysts, the patient was recommended to wear approved protective masks with a non-tight device in order to avoid local

pressure from the ears to the occipital area. Two months later, the lesions had resolved and no relapses were noted after six months of follow-up.

Auricular pseudocyst, also known as benign idiopathic cystic chondromalacia, is a rare and probably underreported condition. Clinically is manifested as a localized oval-shaped swelling arising on the lateral surface of pinna. It usually affects an auricle, but rare cases of bilateral involvement have also been reported.¹ Development of auricular pseudocysts has occasionally been related to chronic, repeated and often mild traumatic events (rubbing, ear pulling, sleeping on hard pillows, wearing helmets, earphones or headphones). In our patient, the lesions were bilateral and resolved two months after releasing both ears of the pressure that was being applied by the protective mask. No recurrences were observed during the follow-up. A potential role of mask-induced pressure microtraumas could be postulated as a predisposing factor for the bilateral and symmetrical development of these lesions.

During the pandemic, personal protective equipments have been responsible for some skin-related adverse events, specially if prolonged worn.² Mask usage may have increased the probability of acne flare-ups, commonly called "maskne", pruritus, worsening of pre-existing dermatoses, irritant contact dermatitis or abrasions.³ Bilateral auricular pseudocysts could probably be added to the list of potential mask-induced skin related side effects.

Pseudocysts of the auricle are usually diagnosed by anamnesis (non-acute painless swelling, usually present metachronously, but can also occur synchronously) and examination (absence of inflammatory signs), although a punch biopsy may help to confirm diagnosis. Ultrasounds is also a technique that may aid in the differential diagnoses that include subperichondrial hematoma caused by accumulation of blood secondary to trauma, relapsing polychondritis, chondrodermatitis nodularis helices, cellulitis and otoseroma.^{4,5}

In conclusion, we describe auricular pseudocysts as a new complication caused by long time wearing protective masks that should be taken into account due to a worldwide widespread wearing of these as part of personal protective equipment against SARS-CoV2.

<https://doi.org/10.1016/j.ad.2022.01.027>

0001-7310/© 2022 AEDV. Published by Elsevier España, S.L.U. This is an open access article under the CC BY-NC-ND license (<http://creativecommons.org/licenses/by-nc-nd/4.0/>).

Please cite this article as: A. Lobato-Berezo, M.T.F. Figueras and R.M. Pujol, Auricular Pseudocysts After Prolonged Protective Mask Wearing for SARS-CoV2, ACTAS Dermo-Sifiliográficas, <https://doi.org/10.1016/j.ad.2022.01.027>

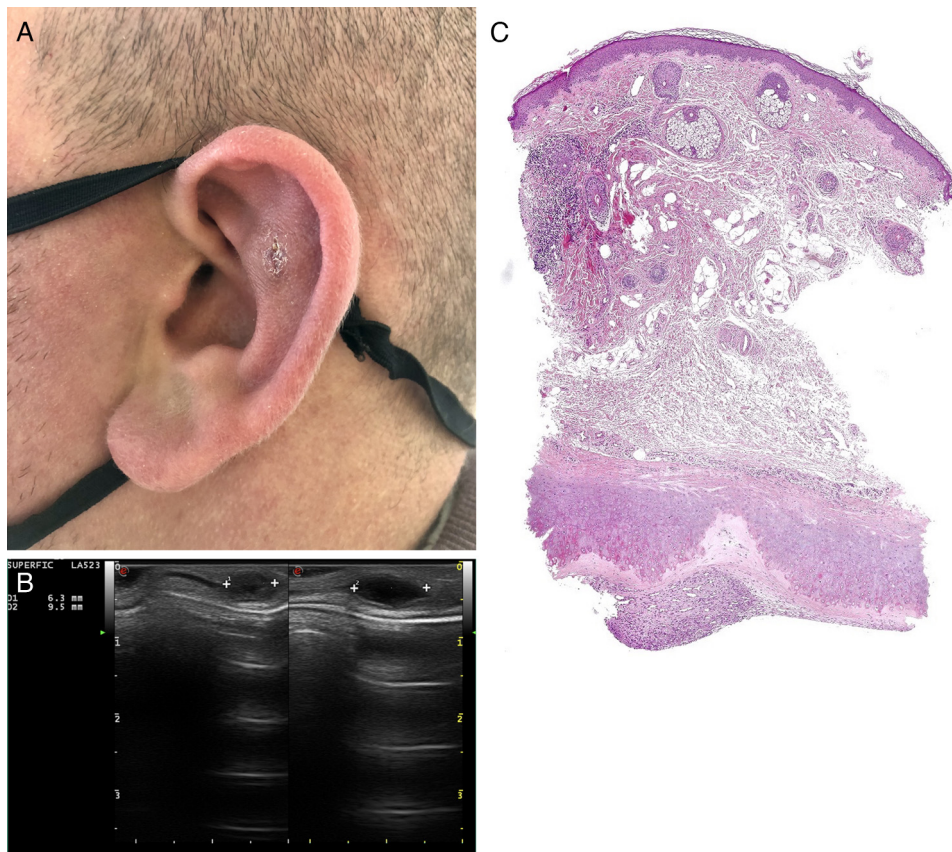


Figure 1 (A) Well-defined non-inflammatory nodules located in the upper helix (small) and scaphoid fossa (biopsy). (B) Ultrasound examination: hypoechoic cystic lesions with anechoic content and posterior reinforcement with increased cartilage thickness in the ultrasounds. (C) Hematoxylin–eosin 10×: intracartilaginous space lacking an epithelial lining with thinning cartilage and hyalinising degeneration along the internal border of the cystic space.

Conflict of interests

The authors declare that they have no conflict of interest.

References

1. Ballan A, Zogheib S, Hanna C, Daou B, Nasr M, Jabbour S. Auricular pseudocysts: a systematic review of the literature. *Int J Dermatol.* 2021.
2. Montero-Vilchez T, Cuenca-Barrales C, Martinez-Lopez A, Molina-Leyva A, Arias-Santiago S. Skin adverse events related to personal protective equipment: a systematic review and meta-analysis. *J Eur Acad Dermatol Venereol.* 2021.
3. Chaiyabutr C, Sukakul T, Pruksaeakanan C, Thumrongtharadol J, Boonchai W. Adverse skin reactions following different types of mask usage during the COVID-19 pandemic. *J Eur Acad Dermatol Venereol.* 2021;35:e176–8.

4. Whittle C, Castro A, Pereira MJ, Cabrera R. Auricular pseudocyst: sonographic appearance in 17 patients. *Ultrasound Q.* 2020.
5. Laschen J, Datema FR, Koot VC, Lohuis PJ. Bilateral auricular pseudocyst: recognizing and treating. *Facial Plast Surg.* 2014;30:690–3.

A. Lobato-Berezo^{a,*}, M.T.F. Figueras^b, R.M. Pujol^a

^a *Department of Dermatology, Hospital del Mar-Parc de Salut Mar, Barcelona, Spain*

^b *Department of Pathology, Hospital Universitari General de Catalunya, Sant Cugat del Vallès, Barcelona, Spain*

*Corresponding author.

E-mail address: alobe@hotmail.es (A. Lobato-Berezo).