

POSTER PRESENTATION

Open Access

Improved motion correction for T_1 mapping

Sébastien Roujol^{1*}, Murilo Foppa¹, Keigo Kawaji¹, Kraig V Kissinger¹, Beth Goddu¹, Warren J Manning^{1,2}, Reza Nezafat¹

From 17th Annual SCMR Scientific Sessions
New Orleans, LA, USA. 16-19 January 2014

Background

Quantitative myocardial T_1 mapping is commonly performed using a breath-hold ECG-triggered acquisition. Despite breath-hold instructions, motion is observed in

~50% of patients due to diaphragmatic drift and their limited breath-holding capability [1]. Registration of each T_1 -weighted (T_1w) image can be performed to reduce motion artifacts in T_1 maps but remains

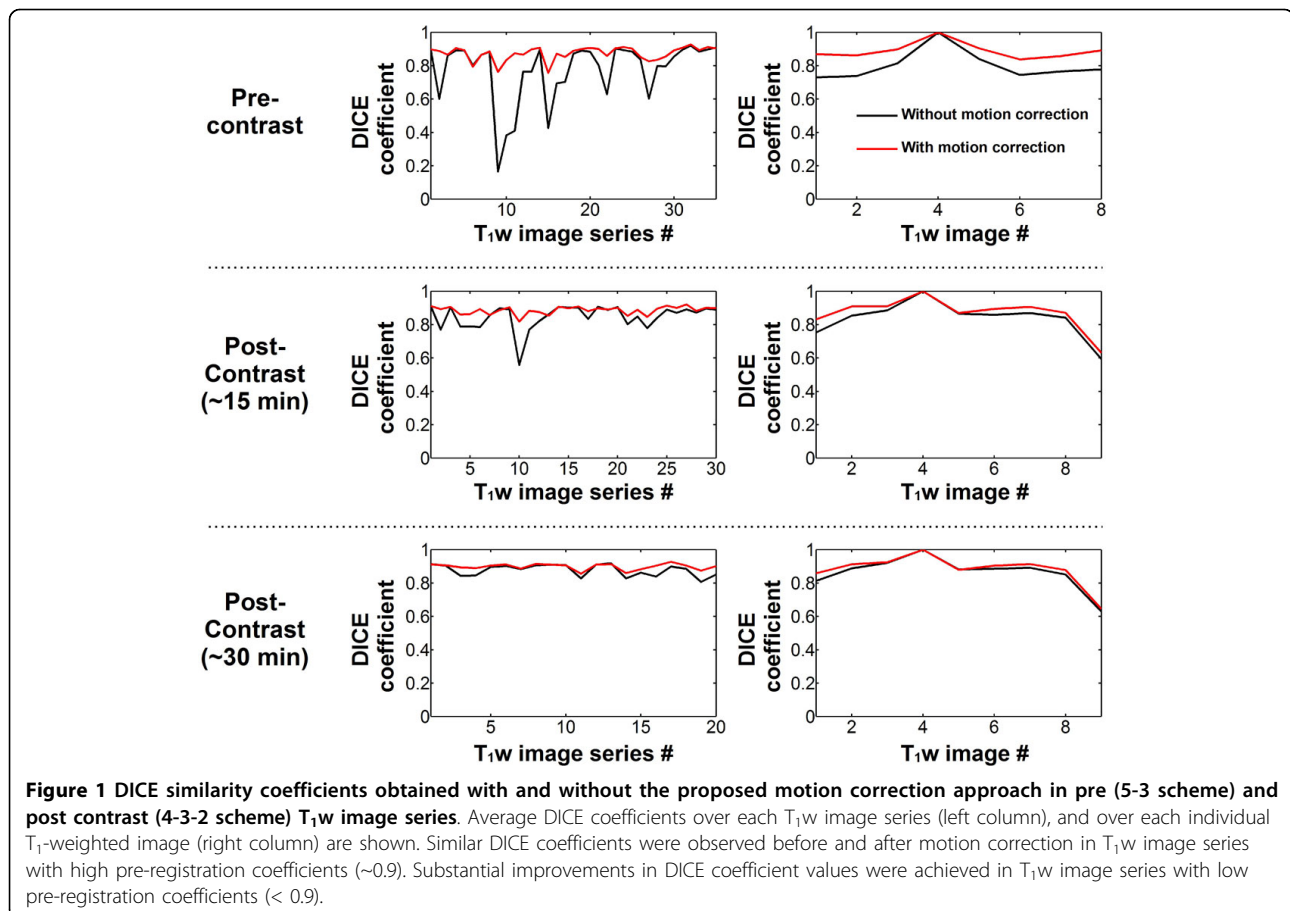


Figure 1 DICE similarity coefficients obtained with and without the proposed motion correction approach in pre (5-3 scheme) and post contrast (4-3-2 scheme) T_1w image series. Average DICE coefficients over each T_1w image series (left column), and over each individual T_1 -weighted image (right column) are shown. Similar DICE coefficients were observed before and after motion correction in T_1w image series with high pre-registration coefficients (~0.9). Substantial improvements in DICE coefficient values were achieved in T_1w image series with low pre-registration coefficients (< 0.9).

¹Medicine, BIDMC/Harvard Medical School, Boston, Massachusetts, USA
Full list of author information is available at the end of the article

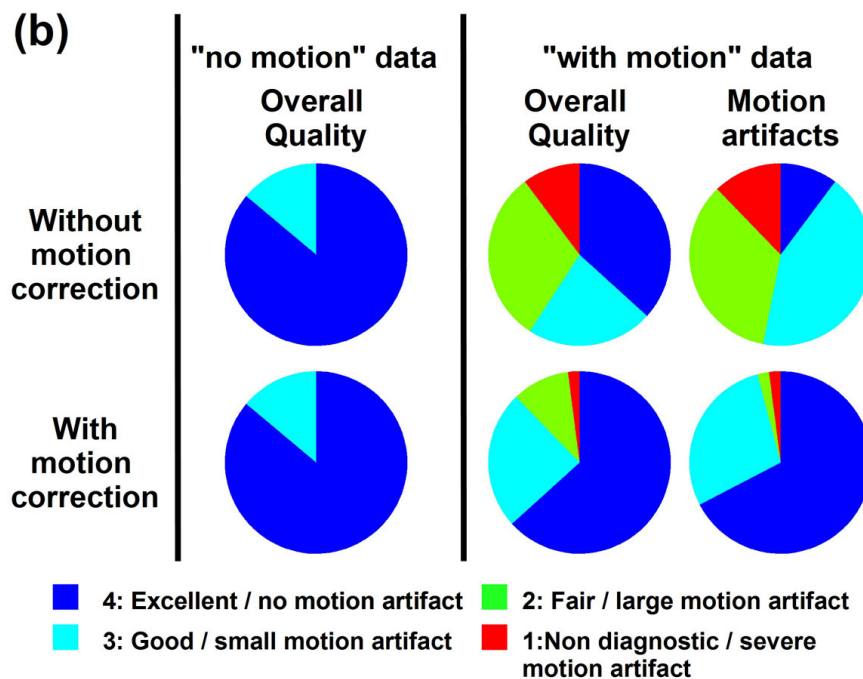
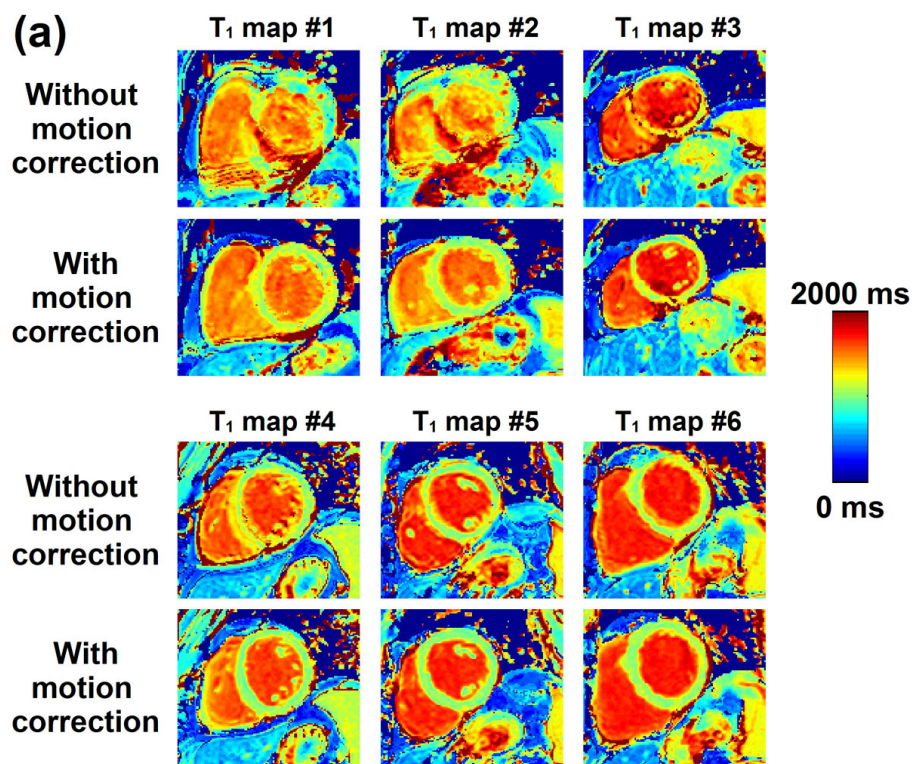


Figure 2 Analysis of T₁ maps before and after motion correction. Examples of 6 T₁ maps reconstructed before and after motion correction are shown in (a). Moderate to severe motion artifacts are visible in all shown T₁ maps reconstructed without motion correction. After motion correction, the quality of all T₁ maps significantly improved and motion artifacts were substantially reduced. Subjective quantitative analysis are shown in (b). Similar T₁ map quality is observed before and after motion correction in data identified as "no motion". Improved image quality and reduced motion artifacts were observed after motion correction in data identified as "with motion".

challenging due to the high intensity variations among T_1w images [1]. In this study we propose a novel non-rigid T_1w image registration approach.

Methods

Our proposed method uses an extended formulation of the optical flow problem, where both motion field and intensity variation are estimated simultaneously within a unified variational framework [2]. An additional term was introduced to constrain the deformation field using automatic feature point tracking [3]. Each T_1w image is registered to the 4th image of the series (reference), on which a region of interest is manually drawn around the left ventricle (LV-ROI). All remaining steps are performed automatically, where affine motion parameters are first estimated by maximization of the mutual information between the reference image and each T_1w image over the LV-ROI, and is followed by our proposed non rigid motion estimation step. Twenty patients (57 ± 14 y, 12 m) referred for clinical CMR exams were scanned before and after administration of contrast agent. T_1 mapping was performed in 1-3 slices with a 5-(3)-3 scheme for pre-contrast and 4-(1)-3-(1)-2 scheme for two post-contrast scans at ~ 15 and ~ 30 min post-injection. 85 total T_1 maps were acquired and were visually assessed for the presence of motion. To quantify the registration step, the myocardium was manually segmented in all T_1w images and the DICE coefficients were computed between each registered T_1w image and the reference image (1: ideal match, 0: none). Overall T_1 map quality and motion artifacts were assessed by a blinded reader using a 4-point scale (0: non diagnostic/severe motion artifact, 4: excellent/no motion artifact).

Results

57% of the T_1w image series were visually identified as “with motion”. After motion correction, DICE coefficients (Figure 1) were slightly improved in “no motion” series (0.90 ± 0.02 vs. 0.91 ± 0.02 , $p < 0.002$) and greatly improved in “with motion” series (0.80 ± 0.14 vs. 0.89 ± 0.03 , $p < 0.001$). Figure 2 shows T_1 maps reconstructed with and without motion correction. No statistical difference was found in term of overall T_1 map quality before and after correction in “no motion” series. After motion correction, improved overall T_1 map quality (2.86 ± 1.04 to 3.49 ± 0.77 , $p < 0.001$) and reduced motion artifacts (2.51 ± 0.84 to 3.61 ± 0.64 , $p < 0.001$) were obtained in “with motion” series.

Conclusions

The proposed non-rigid registration approach reduces the respiratory-induced motion occurring during breath-hold T_1 mapping and significantly improves the quality of T_1 maps.

Funding

NIH R01EB008743-01A2.

Authors' details

¹Medicine, BIDMC/Harvard Medical School, Boston, Massachusetts, USA.

²Radiology, BIDMC/Harvard Medical School, Boston, Massachusetts, USA.

Published: 16 January 2014

References

1. Xue: *MRM* 2012.
2. Cornelius: *ACM-Siggraph* 1983.
3. Roujol: *IEEE-TITB* 2012.

doi:10.1186/1532-429X-16-S1-P45

Cite this article as: Roujol et al.: Improved motion correction for T_1 mapping. *Journal of Cardiovascular Magnetic Resonance* 2014 **16**(Suppl 1):P45.

Submit your next manuscript to BioMed Central and take full advantage of:

- Convenient online submission
- Thorough peer review
- No space constraints or color figure charges
- Immediate publication on acceptance
- Inclusion in PubMed, CAS, Scopus and Google Scholar
- Research which is freely available for redistribution

Submit your manuscript at
www.biomedcentral.com/submit

