

Number of Foci of Functioning Thyroid Tissue Remaining after Thyroidectomy for Differentiated Thyroid Cancer: Institutional Experience

Kanchan Kulkarni, Gauri Khorjekar¹, Mihriye Mete², Douglas Van Nostrand

Division of Nuclear Medicine, MedStar Washington Hospital Center, ¹Department of Radiology, George Washington University Hospital, Washington DC, ²Department of Biostatistics and Epidemiology, MedStar Health Research Institute, Hyattsville, Maryland, USA

Abstract

Radioiodine imaging of the neck with a pinhole collimator (PinC) is frequently performed in differentiated thyroid cancer (DTC) patients for visualizing individual, and a total number of foci (NOF) of functioning residual thyroid tissue (FRTT) within the thyroid bed in postthyroidectomy patients. The objective of this study was to determine our experience regarding the NOF of FRTT visualized on pretherapy radioiodine PinC images. We performed a retrospective review of radioiodine PinC images of the neck of patients with very low-risk DTC and who had thyroidectomy performed by selected surgeons at MedStar Washington Hospital Center. For each patient's image, the NOF of FRTT was determined by two blind readers. Statistical analysis was performed. One hundred and twenty-six patients met the criteria. Surgeon (S1, S2, S3, and S4) performed 17, 10, 86, and 13 thyroidectomies, respectively. The analysis (mean, range, and standard deviation) of NOF of FRTT was: S1: (2.2, 0-5, 1.3); S2: (1.6, 1-3, 0.8); S3: (2.6, 0-7, 1.5); S4: (3.3, 1-5, 1.3). The percentages of <2, ≤3, ≤4, and <5 foci remaining were 4.9%, 21.5%, 77.0%, and 91.3%, respectively. For the selected surgeons, the NOF of FRTT in the thyroid bed or neck in postthyroidectomy patients never exceeded 7, rarely exceeded 5 (2.4%), and infrequently exceeded 4 (8.7%). Based on these data, our thresholds of the NOF for which we perform further workup for possible locoregional disease are ≥5. Each facility is encouraged to establish their own criteria for their facility and preferably for each of their surgeons.

Keywords: Differentiated thyroid cancer, number of foci, pinhole imaging, postthyroidectomy, thyroid tissue

Introduction

Radioiodine scans for the evaluation of patients with differentiated thyroid cancer (DTC) are often performed postoperatively and before I-131 therapy to identify factors that may potentially alter the patient's management before the therapy or alter the prescribed activity for the patient's I-131 therapy.^[1] For these pretherapy images, pinhole collimators (PinCs) or

parallel-hole collimators (ParC) may be used, and PinC images have been shown to be superior to ParC images for identification of individual foci of radioiodine uptake in the thyroid bed and neck.^[2] The superiority of PinC images is due to higher spatial resolution than ParC images and the elimination of any "star" artifact that may be present when using a ParC.^[3] The "star" artifact may significantly limit one's ability to identify individual foci of radioiodine uptake, which is true regardless of whether one is performing a whole body scan or obtaining an individual image with a ParC.

This is an open access article distributed under the terms of the Creative Commons Attribution-NonCommercial-ShareAlike 3.0 License, which allows others to remix, tweak, and build upon the work non-commercially, as long as the author is credited and the new creations are licensed under the identical terms.

For reprints contact: reprints@medknow.com

How to cite this article: Kulkarni K, Khorjekar G, Mete M, Van Nostrand D. Number of foci of functioning thyroid tissue remaining after thyroidectomy for differentiated thyroid cancer: Institutional experience. *World J Nucl Med* 2017;16:122-5.

Address for correspondence:

Dr. Kanchan Kulkarni, Division of Nuclear Medicine, MedStar Washington Hospital Center, 110 Irving Street, NW, Suite GB1, Washington, DC 20010, USA.
E-mail: kanchan.kulkarni@medstar.net

Access this article online

Quick Response Code:



Website:
www.wjnm.org

DOI:
10.4103/1450-1147.203066

However, to the best of our knowledge, no one has published their experience regarding the spectrum of the number of foci (NOF) of functional residual thyroid tissue (FRTT) identified in the thyroid bed or neck after near total or total thyroidectomy (NTT) for their surgeons with PinC images.

The objective of this study was to determine the NOF of FRTT visualized on PinC images after an NTT for each of our key surgeons at MedStar Washington Hospital Center (MWHC) patients with DTC.

Materials and Methods

Subjects

An Institutional Review Board approved, retrospective study was conducted at MWHC from 2006 to 2011. Patients were included who had, (1) a NTT with or without central or lateral cervical nodal dissection for DTC performed by one of the four selected surgeons at MWHC, (2) a postoperative preablation PinC image of the thyroid bed obtained, (3) a risk stratification of very low as defined by the American Thyroid Association guidelines for DTC including the following: No evidence of lymph node metastases or distant metastases by imaging (e.g., ultrasound, pretherapy radioiodine scan, posttherapy radioiodine scan, computed tomography (CT), and/or magnetic resonance imaging), primary tumor <2 cm, and no marginal involvement, extrathyroidal involvement, capsular involvement, perineural or lymphovascular invasion, and/or aggressive histology (e.g., tall cell, columnar, squamous cell, poorly differentiated, Hürthle cell, etc).^[4]

Based on the clinical order from the referring endocrinologist, the patient was prepared by either thyroid hormone withdrawal (THW) or recombinant thyroid-stimulating hormone (rhTSH) for the pretherapy radioiodine imaging at approximately 4–8 weeks after NTT. Those patients referred for THW discontinued their long acting thyroid hormone medication for 4–6 weeks at which time they were initiated on short-acting thyroid hormone. The latter was continued for 2–3 weeks and discontinued 10 days to 2 weeks before dosing with I-123 for the postoperative radioiodine imaging. Patients were also instructed to adhere to a low iodine diet for 2 weeks before the radioiodine scan. A serum TSH level >30 uIU/ml was required for those patients who were prepared with THW. Those patients referred for rhTSH stimulation received 0.9 mg rhTSH injected intramuscularly on two consecutive days before the day of administration of the diagnostic prescribed activity of radioiodine for imaging. Imaging was performed 24 h after the oral administration of 74–144 MBq (2–4 mCi) of I-123 for patients prepared by THW and 148 MBq (4 mCi) of I-123 for those who were prepared using rhTSH stimulation.

Methods

Standard imaging included a whole body image using a ParC, individual images of the chest and neck using a ParC, and an individual image of the thyroid bed and neck using a PinC. Additional single photon emission CT (SPECT) images were performed at the request of the reading physician. Only the PinC images were used for this study.

Using the PinC images, the number of discrete foci of radioiodine uptake for each patient was identified by two experienced blind readers. If there was a discrepancy, the two readers reviewed the images together to reach a consensus.

Statistics

Continuous variables were summarized using means and standard deviations and categorical variables were summarized using frequencies and percentages. Two-sample *t*-tests and nonparametric tests were used to test the differences between the means of the groups. Analysis of variance (ANOVA) and nonparametric Kruskal–Wallis tests were used to test the differences in the mean and ranks of NOF between surgeons. Poisson regression model with robust standard errors was used to model the differences in the NOF across surgeons. The Poisson regression model was also adjusted for age, gender, and preparation type to account for potential confounders.

Results

From a total of 1550 patients, 126 met the above criteria and were reviewed. Twenty-one were male (17%) and 105 (83%) were female. The mean, standard deviation, and range of patients' ages were 49, 14, and 17–79, respectively. Forty-five (36%) were prepared by THW and 81 (64%) were prepared with rhTSH stimulation.

The data for the NOF of FRTT for the PinC images of the 126 patients are noted in Table 1. The number of patients for each surgeon (S1, S2, S3, and S4) were: 17, 10, 86, and 13, respectively. The analysis (mean, range, standard deviation) of NOF of FRTT for each surgeon was: S1: (2.2, 0–5, 1.3); S2: (1.6, 1–3, 0.8); S3: (2.6, 0–7, 1.5); S4: (3.3, 1–5, 1.3). The percentages of <2, ≤3, ≤4, and <5 foci remaining for all patients of the four surgeons

Table 1: Total number of foci in the thyroid bed

Surgeon	Number of cases reviewed	Number of foci in the thyroid bed							
		0	1	2	3	4	5	6	7
1	17	1	4	5	5	1	1	0	0
2	10	0	6	2	2	0	0	0	0
3	86	7	8	27	24	12	5	1	2
4	13	0	1	3	2	5	2	0	0
Total percentage		4.9	14.8	30.5	25.8	14.1	6.3	0.8	1.6

were 50.2%, 76%, 90.1%, and 96.4%, respectively. There was a statistically significant difference in the mean NOF of FRTT only between surgeon 2 and surgeon 4 (Bonferroni adjusted, ANOVA F -test, $P = 0.02$, for ranks: Kruskal-Wallis $P = 0.01$). Poisson regression analysis (with robust standard errors) of the count outcome of NOF showed that the NOF left behind by surgeons 3 and 4 were significantly higher compared to those left behind by the surgeon 2 with an incidence rate ratio (IRR) of 0.7, $P = 0.003$, 95% CI: 1.2-2.3 and an IRR of 2.1, $P < 0.001$, 95% CI: 1.4-3.0, respectively. The difference in the means between surgeons 1 and 2 was not significant different (IRR = 1.4, $P = 0.11$, 95% CI: 0.93-2.1). The results did not change when the model was adjusted for the method of patient preparation, age, or gender, which were not significantly related to the NOF in the adjusted model.

The spectrums of findings of NOF are illustrated in Figure 1.

Discussion

For four surgeons at our facility, this study evaluated the spectrum of the NOF of FRTT remaining in the thyroid bed and neck as identified on PinC I-123 images after NTT in patients who had DTC and a very low likelihood of locoregional disease.

The value of this study is four-fold. First, this study again calls attention to the value of PinC images in demonstrating the NOF of FRTT in the thyroid bed

and neck relative to ParC images. Foci on ParC images are demonstrated frequently by only a "star" artifact.^[2] Second, this study also calls attention to the use of the parameter of the NOF of FRTT in the thyroid bed and neck as potentially identifying patients who may have a higher likelihood of locoregional disease than initially suggested by that patient's low-risk stratification. Third, this study encourages nuclear medicine physician and nuclear radiologist to determine the NOF of FRTT for each of their high-frequency surgeons to better determine who should be evaluated further for locoregional disease. Fourth, this study establishes an initial threshold of the NOF that may warrant further evaluation for locoregional disease before proceeding with the I-131 remnant ablation.

However, this study has significant limitations. First, the number of patients included for surgeon 1, 2, and 4 are low, and thus, significantly more data are needed. Second, the data apply to only the four surgeons at our institution. One cannot confidently extrapolate these results to other surgeons in our facility or other facilities. Each facility should evaluate each one of their surgeons, and although this may appear to be time consuming, it is not. Likewise, although fewer and fewer very low-risk patients are receiving radioiodine scans and remnant ablation, it is still possible to identify low-risk patients and tabulate the foci of radioiodine uptake in the thyroid bed and neck. Third, this study assessed neither the utility of various thresholds of the NOF of FRTT in identifying patients, who were proven to have locoregional disease nor changes in outcomes due to any further evaluation and/or alteration of

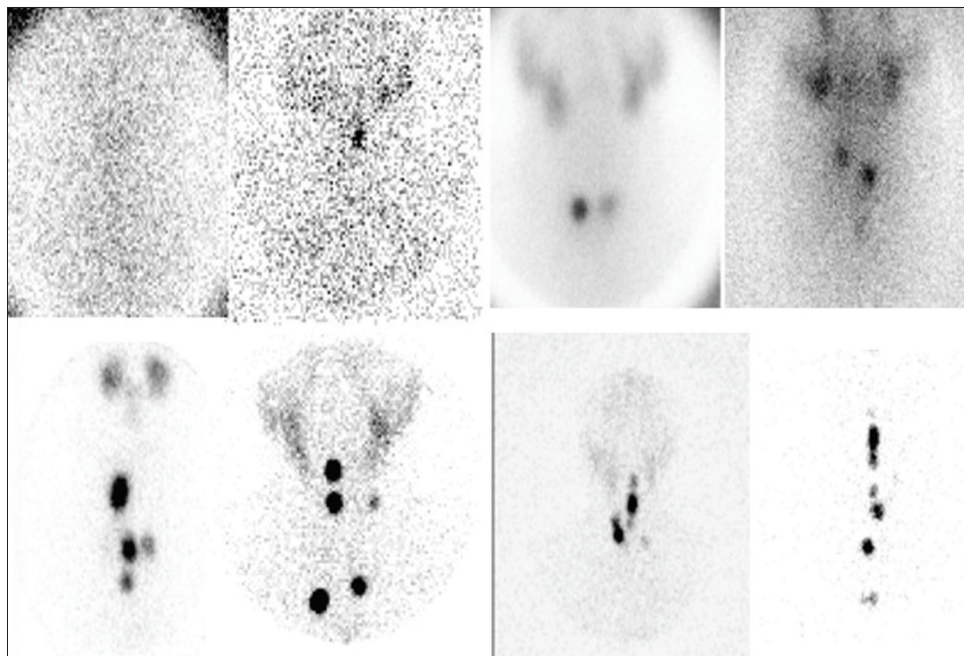


Figure 1: Spectrum of radioiodine avid foci within the thyroid bed ranging from none to multiple is demonstrated

management. Another limitation of the study was that although SPECT-CT was performed in many patients and although SPECT-CT has been shown to be very useful in distinguishing whether or not a focus of uptake in the thyroid bed or neck localizes to normal tissue or a lymph node,^[5-9] we did not compare the utility of PinC images to SPECT-CT images. However, many institutions do not have SPECT-CT, and although SPECT-CT has improved contrast resolution, SPECT-CT has reduced spatial resolution that is inferior to the spatial resolution of most PinC images.^[10] It would have been useful to correlate the amount of residual thyroidal tissue with surgical side effects such as blood loss, hypocalcemia, or recurrent laryngeal nerve damage. It is often speculated that the rate of these side effects is reduced when a large amount of residual thyroidal tissue remains but studying this correlation was beyond the scope of the study and was not performed. However, despite these limitations, the NOF of FRTT has the potential to be an additional useful parameter for identifying patients, who may have locoregional disease despite a risk stratification of low.

Conclusion

For the surgeons at MWHC, the NOF of FRTT in the thyroid bed or neck in patients who had NTT never exceeded 7 foci, rarely exceeded 5 (2.4%) foci, and infrequently exceeded four (8.7%) foci. Based on these data, our thresholds of the NOF of FRTT in the thyroid bed or neck for which we perform further evaluation for the possible locoregional disease are >4 for three of our surgeons and >5 for one of our surgeons. Each facility is encouraged to establish their own criteria for their facility and preferably for each of their surgeons. As demonstrated herein, obtaining these data was not difficult. Although we would expect the number of patients who will exceed our threshold to be low in patients categorized as initially low risk, further study of the utility of assessing the number of functioning foci in the thyroid bed and neck in these patients is warranted, and this study should ideally include the evaluation of the frequency of identification of locoregional disease that had not been previously detected as well as the frequency and tabulation of how management and outcomes were altered. Until then, each facility must empirically decide the thresholds for the number of functioning foci in the thyroid bed and neck that warrant further evaluation.

Financial support and sponsorship

Biostatistical support for this project has been funded in whole or in part with Federal funds (Grant # UL1RR031975) from the National Center for Research Resources (NCRR), National Institutes of Health (NIH), through the Clinical and Translational Science Awards Program (CTSA), a trademark of DHHS, part of the Roadmap Initiative, "Re-Engineering the Clinical Research Enterprise."

Conflicts of interest

There are no conflicts of interest.

References

1. Van Nostrand D, Aiken M, Atkins F, Moreau S, Garcia C, Acio E, *et al.* The utility of radioiodine scans prior to iodine 131 ablation in patients with well-differentiated thyroid cancer. *Thyroid* 2009;19:849-55.
2. Kulkarni K, Van Nostrand D, Mete M, Burman K, Wartofsky L. Detectability of foci of radioiodine uptake in the thyroid bed and neck comparing pinhole with parallel-hole collimators. *Nucl Med Commun* 2011;32:369-74.
3. Van Nostrand D, Bakthula R, Atkins F. Primer and atlas for the interpretation of radioiodine whole body scintigraphy. In: Wartofsky L, Van Nostrand D, editors. *Thyroid Cancer: A Comprehensive Guide to Clinical Management*. Totowa, New Jersey: Humana Press; 2006. p. 151-78.
4. American Thyroid Association (ATA) Guidelines Taskforce on Thyroid Nodules and Differentiated Thyroid Cancer, Cooper DS, Doherty GM, Haugen BR, Kloos RT, Lee SL, *et al.* Revised American Thyroid Association management guidelines for patients with thyroid nodules and differentiated thyroid cancer. *Thyroid* 2009;19:1167-214.
5. Wong KK, Zarzhevsky N, Cahill JM, Frey KA, Avram AM. Incremental value of diagnostic 131I SPECT/CT fusion imaging in the evaluation of differentiated thyroid carcinoma. *AJR Am J Roentgenol* 2008;191:1785-94.
6. Wong KK, Sisson JC, Koral KF, Frey KA, Avram AM. Staging of differentiated thyroid carcinoma using diagnostic 131I SPECT/CT. *AJR Am J Roentgenol* 2010;195:730-6.
7. Schmidt D, Szikszai A, Linke R, Bautz W, Kuwert T. Impact of 131I SPECT/spiral CT on nodal staging of differentiated thyroid carcinoma at the first radioablation. *J Nucl Med* 2009;50:18-23.
8. Kohlfuerst S, Igerc I, Lobnig M, Gallowitsch HJ, Gomez-Segovia I, Matschnig S, *et al.* Posttherapeutic (131I) I SPECT-CT offers high diagnostic accuracy when the findings on conventional planar imaging are inconclusive and allows a tailored patient treatment regimen. *Eur J Nucl Med Mol Imaging* 2009;36:886-93.
9. Mustafa M, Kuwert T, Weber K, Knesewitsch P, Negele T, Haug A, *et al.* Regional lymph node involvement in T1 papillary thyroid carcinoma: A bicentric prospective SPECT/CT study. *Eur J Nucl Med Mol Imaging* 2010;37:1462-6.
10. Ho Shon IA, Yan W, Roach PJ, Bernard EJ, Shields M, Sywak M, *et al.* Comparison of pinhole and SPECT 99mTc-MIBI imaging in primary hyperparathyroidism. *Nucl Med Commun* 2008;29:949-55.