

Langerhans Cell Sarcoma Arising from Chronic Lymphocytic Lymphoma/Small Lymphocytic Leukemia: Lineage Analysis and BRAF V600E Mutation Study

Weiwei Chen, Ronald Jaffe¹, Linsheng Zhang², Charlie Hill², Anne Marie Block³, Sheila Sait³, Buer Song, Yunguang Liu, Donghong Cai

Department of Pathology, Buffalo General Hospital, State University of New York at Buffalo, Buffalo, NY 14214, ¹Children's Hospital of Pittsburgh of UPMC, Pittsburgh, PA 15224, ²Department of Pathology and Laboratory Medicine, Molecular Diagnostic Laboratory, Emory University, Atlanta, GA 30322, ³Cytogenetics Division, Department of Pathology, Roswell Park Cancer Institute, Buffalo, NY 14263, USA

Abstract

Background: the phenomenon that histiocytic/dendritic cell sarcomas may be transformed from lymphoproliferative diseases is dubbed 'transdifferentiation'. Langerhans cell sarcoma (LCS) transdifferentiated from chronic lymphocytic leukemia/small cell lymphoma (CLL/SLL) is extremely rare. The underlying mechanisms of LCS tumorigenesis and its transdifferentiation from CLL/SLL are largely unknown. **Aims:** the authors strive to further characterize LCS, to understand the potential molecular changes in LCS and the underlying mechanisms of CLL/SLL transformation to LCS. **Materials and Methods:** a progressively enlarging right inguinal lymph node from a 68-year-old female patient with a history of CLL was biopsied and submitted for flow cytometry analysis, routine hematoxylin, and eosin (H and E) stain and immunohistochemical study. Furthermore, clonality study (fluorescent *in situ* hybridization (FISH) analysis with a CLL panel probes) and BRAF V600E mutation study (pyrosequencing and immunostain) were performed. **Results:** two different neoplasms, LCS and CLL/SLL, were discovered to occur simultaneously in the same lymph node. These two entities were shown to be clonally related. More importantly, for the first time, BRAF V600E mutation was detected in LCS. **Conclusions:** LCS can be transdifferentiated from CLL/SLL and BRAF V600E mutation may provide the foundation for alternative therapy of LCS.

Keywords: BRAF V600E mutation, clonality, Langerhans cell sarcoma, transdifferentiation

Address for correspondence: Dr. Donghong Cai, Department of Pathology, Buffalo General Hospital, 100 High Street, Buffalo, NY 14203, USA. E-mail: dcaiz@hotmail.com

Introduction

Both interdigitating dendritic sarcoma (IDCS) and Langerhans cell sarcoma (LCS) are derived from myeloid progenitor cells, which are different from precursors for lymphoid neoplasms. However, recent studies have

shown that histiocytic/dendritic cell sarcomas and some lymphoproliferative diseases, such as follicular lymphoma, chronic lymphocytic leukemia/small lymphocytic lymphoma (CLL/SLL) and hairy cell leukemia, may occur in the same individual and interestingly, these neoplasms are clonally related. This phenomenon is dubbed "transdifferentiation".^[1-8] There have been several reports showing synchronous IDCS and CLL/SLL; however, only one case of concurrent LCS and CLL/SLL has been documented in the English literature.^[9] Here we present a case in which LCS arose from CLL/SLL and the two diseases appeared to share the same clonality.

The BRAF V600E mutation (T1799A) has been shown to be a molecular change underlying the pathogenesis

Access this article online

Quick Response Code:



Website:
www.najms.org

DOI:
10.4103/1947-2714.114172

of many malignancies, the most notable one being melanoma. A recently developed monoclonal antibody vemurafenib that targets BRAF V600E mutant has been approved to treat late-stage or unresectable melanomas and the outcome is very encouraging.^[9] Considering the effectiveness of this drug in melanoma treatment, it would be interesting to look into its potential effect on other cancers bearing the same mutation. Recent studies have demonstrated that 38-57% of Langerhans cell histiocytosis (LCH) harbor the BRAF V600E mutation.^[10,11] However, whether LCS shares the same molecular defect remains to be addressed. Here we present the first LCS case that carries BRAF V600E mutation.

Materials, Methods, and Results

The patient was a 68-year-old female with a past medical history significant for papillary thyroid carcinoma status post-thyroidectomy. Six years ago, she was diagnosed with CLL and followed with watchful waiting. Four years ago the patient received eight cycles of Rituxan and fludarabine due to disease progression. The treatment brought down the WBC count to $5.9 \times 10^9/L$ with 9% lymphocytes. However, 1 year ago her CLL relapsed and three doses of Rituxan were administered. Unfortunately she developed deep vein thrombosis and pulmonary embolism after chemotherapy and was put on anticoagulation therapy since. On the most recent admission, she complained about general malaise, poor appetite, shortness of breath, and progressively enlarging right inguinal lymph nodes. Blood workup showed a WBC count of $12.6 \times 10^9/L$ with 1% of lymphocytes. One lymph node from her right groin was biopsied. The flow cytometry results (data not shown), histologic examination, and immunohistochemistry confirmed CLL/SLL in this lymph node with atypical lymphocytes positive for CD20, CD5, and CD23 [Figure 1d, e and f]. Surprisingly, population of large epithelioid cells was also noted [Figure 1a, b]. These epithelioid cells formed sheets and manifested characteristic reniform nuclei and voluminous cytoplasm resembling Langerhans cells. Besides, these cells showed higher mitotic activity [Figure 1b] and had a higher proliferation index (MIB-1, Figure 1c), suggesting a different malignancy other than the background CLL/SLL. To confirm this distinct population of cells was indeed of Langerhans cell origin, an immunohistochemistry study was performed with a panel of tumor markers. As predicted, these cells were positive for both CD1a and S100 (Figure 1g, h), and negative for thyroid markers (TTF-1, thyroglobin), cytokeratin, melanoma markers (HMB45 and Mart-1), and myoid markers (myo-D, desmin) (data not shown). Therefore, LCS was highly favored. To rule out other remote possibilities such as IDCS and indeterminate dendritic cell neoplasm, an immunostain for langerin,

a specific marker for Langerhans cells, was carried out. The positivity for langerin [Figure 1i] convincingly supported the LCS diagnosis. Accordingly, two different entities, CLL/SLL and LCS, were found to co-exist in one lymph node. It was estimated that the LCS and CLL/SLL accounted for 50% each of tumor cells, based on the distinct microscopic features of the LCS and CLL/SLL cells.

Once the two diagnoses were confirmed, the next question was whether the LCS and the CLL/SLL were two independent diseases that happened to occur at the same anatomic site or they were related. To address this question, we performed a fluorescence *in situ* hybridization (FISH) analysis using a CLL panel probes (centromere6, 6q23, 11q23, 13q14, 13q34, centromere12, IGH, and 17p13; Vysis CLL FISH probe kit, Abbott Laboratories, Abbott Park, Illinois, USA). The results showed that both the CLL/SLL [Figure 1j] and the LCS cells [Figure 1k] lost the 6q23 signal, suggestive of same clonality of these two populations.

To further understand the genetic changes in LCS cells, we investigated whether the LCS cells carry a BRAF V600E mutation. This was prompted by recent studies showing this mutation in up to 38–57% in LCH.^[10,11] DNA was extracted from the formalin fixed paraffin embedded tissue. The BRAF gene was amplified by PCR with forward primer 5'- TGA AGA CCT CAC AGT AAA AAT AGG -3' and reverse primer 5'- /5Biosg/TCC AGA CAA CTG TTC AAA CTG AT -3' (Integrated DNA Technologies, Inc, Coralville, Iowa). The PCR product was sequenced with primer 5'- TGA TTT TGG TCT AGC TAC A -3' on Pyromark Q96 (Qiagen) according to manufacturer's instructions. Nucleotides were dispensed with the following sequence: ACGTACGATC. The V600E mutation was identified by a peak at the fifth adenosine position and the mutation was harbored in 25% of total DNA (T to A point mutation, 25%, Figure 2d), suggestive of a heterozygous mutation (LCS was about 50% of the total lymph node). The result, for the first time, confirmed the BRAF V600E mutation in LCS. Furthermore, although the gold standard for detection of BRAF V600E mutation is PCR, a recently developed monoclonal antibody VE1 shows high sensitivity and specificity for this mutation, and has been widely used in replace of PCR for research purpose.^[12,13] Therefore, we also performed an immunostain with the VE1 antibody (Spring Bioscience, Pleasanton, CA 94566) in this lymph node. Again, the LCS cells, but not in the CLL/SLL cells, showed positivity for VE1 [Figure 2c], suggesting BRAF V600E mutation in LCS. A negative control [Figure 2a] and a PCR confirmed positive melanoma control [Figure 2b] for this antibody are also shown. This result was consistent with the

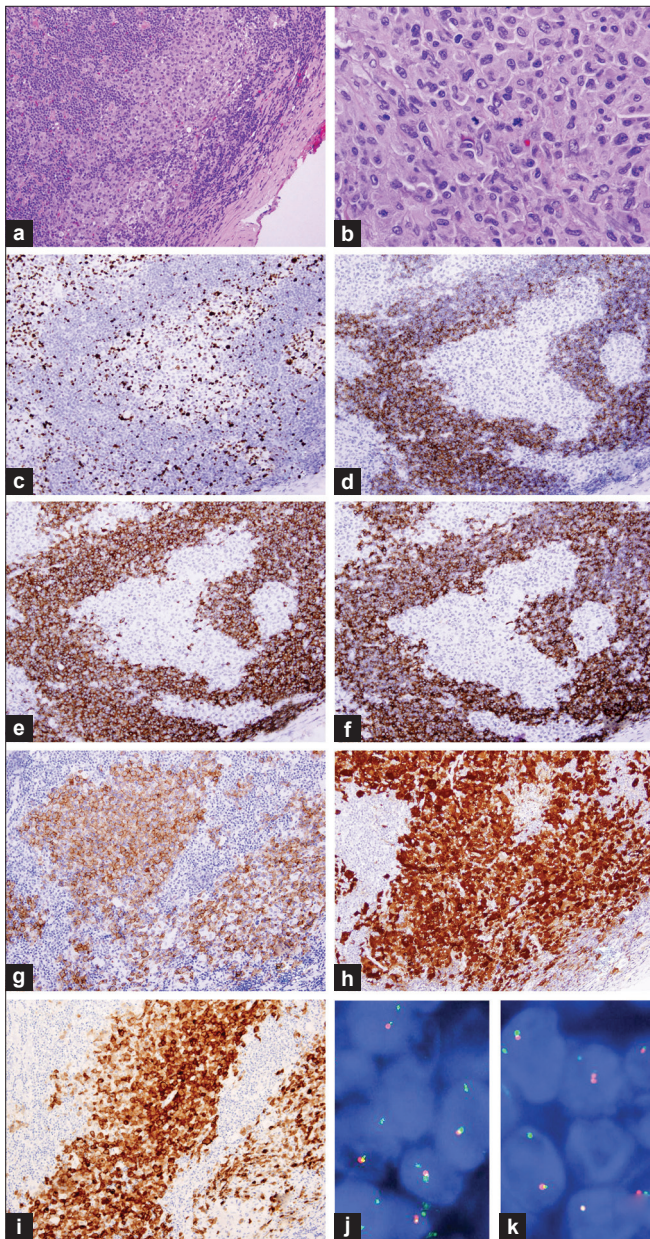


Figure 1: Synchronous and clonally related LCS and CLL/SLL in a lymph node. (a) Sheets of small SLL/CLL cells admixed with large LCS cells in clusters (100 \times). (b) The LCS cells show high mitotic activity (400 \times). (c) The LCS cells demonstrate a much higher proliferation index (MIB-1, 40%) than that of CLL/SLL cells (20%). (d–i) The CLL/SLL cells show immunoreactivity for CD20 (D), CD5 (E) and CD23 (F) while the LCS cells are positive for CD1a (G), S100 (H) and langerin (I). (j) and (k) A FISH analysis using probes for centromere6 (green) and 6q23 (red) revealed the CLL/SLL (J) and the LCS cells (K) both lost the 6q23 signal

molecular study, in which only 25% of DNA carried mutation (heterozygous mutation for LCS, negative for CLL/SLL).

Following of the diagnosis, the patient received one cycle of salvage chemotherapy with DHAC (Dexamethasone, Doxorubicin, ARA-C, and Carboplatin) but failed to

respond. She complained increasing abdominal pressure and girth and a diagnostic laparoscopy revealed multiple nodules (presumed to be CLL/SLL) scattered throughout the small bowel causing adhesions and obstruction. The large mass in the right inguinal region kept growing. The patient decided to check into hospice and received palliative care since then.

Discussion

Feldman *et al.* provided the first evidence of clonal evolution or transdifferentiation of B-cell lymphoma into histiocytic/ dendritic cell sarcoma, in which both neoplasms shared a common IGH gene rearrangement and carried the same BCL2/IGH translocation.^[8] In the following years, the list of B-cell malignancies capable of transdifferentiation had been expanded to extranodal marginal zone lymphoma (MALT lymphoma), splenic marginal zone lymphoma, hairy cell leukemia and CLL/SLL, etc.^[8,9,14] This phenomenon is most likely attributed to the lineage plasticity of the B-cell neoplasms. Although the exact mechanisms are not fully elucidated, several hypotheses have been proposed. The first possibility is of the direct transdifferentiation of neoplastic B-cells into malignant dendritic cells. This is supported by the experimental data showing that enforced expression of some transcription factors such as C/EBP α and C/EBP β can lead to direct transdifferentiation of mature B-cells into macrophages.^[15] A second hypothesis is that this transformation is achieved through multiple steps, which mainly involve de-differentiation of neoplastic lymphocytes to early progenitors, followed by re-differentiation of progenitor cells to dendritic cells. The potential for de-differentiation and re-differentiation of B-cells has been well evidenced. For example, *in vitro* deletion of PAX-5, an important regulator for B-cell development, can lead to de-differentiation of mature B-cells into progenitor cells, which subsequently differentiate to T-cells.^[16,17] Furthermore, it has been found that, in the case of LCS arising from B lymphoblastic leukemia, the LCS cells seem to express ID2 (a key factor in dendritic cell development) much more strongly than PAX-5. The ebbing of PAX-5 and the concurrent rising of ID2 may underlie this de-differentiation.^[18]

Although the role of BRAF mutation in LCS oncogenesis has never been studied, it is well known that BRAF mutation is associated with activation of the mitogen-activated protein kinase (MAPK) pathway in melanoma. As discussed earlier, enhanced expression of transcription factors C/EBP α and C/EBP β may lead to transdifferentiation of lymphocytes to dendritic/Langerhans cells. A recent study by Ignatova *et al.* suggests that there may be crosstalk between C/EBP α and C/EBP β and the MAPK pathway.^[19] These authors demonstrated that C/EBP α and C/EBP β control basal transcription through the

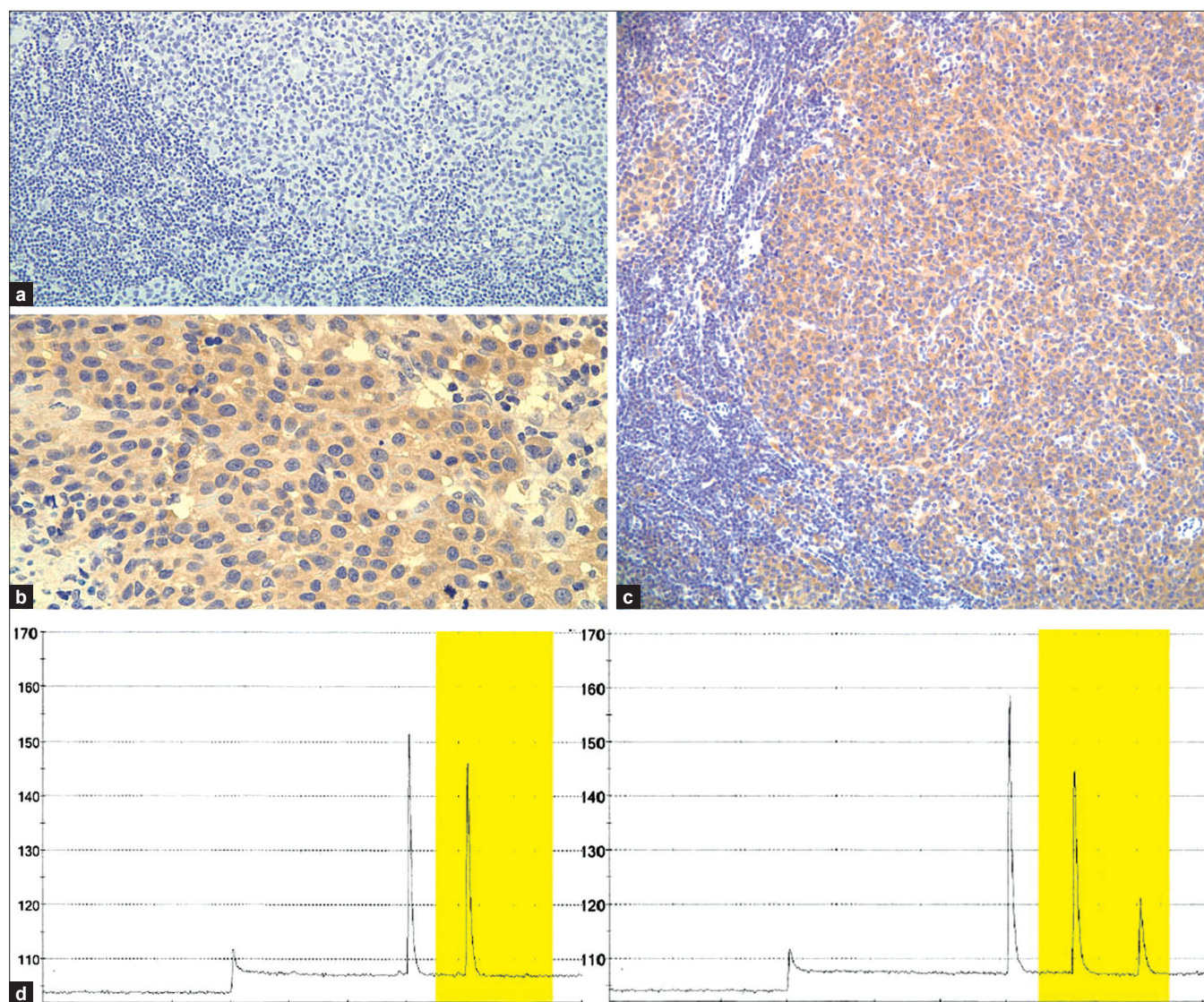


Figure 2: BRAF V600E mutation in LCS. The monoclonal antibody VE1 is able to detect BRAF V600E mutation in PCR-confirmed melanoma (B: as a positive control) using immunohistochemistry (A: negative control). The LCS cells, but not the CLL/SLL cells, in the present case show positivity for VE1 (C), suggesting BRAF V600E mutation in the LCS. The BRAF V600E mutation is confirmed by pyrosequencing of the tumor DNA (D). A wild type control is displayed on the left (D, left), and the patient result is displayed on the right (D, right). A T to A mutation at the codon 600 of BRAF is present in approximately 25% of the DNA (D, right)

p38 MAPK-mediated pathway *in vitro*. Whether similar mechanism is responsible for the potential role of BRAF mutation in the transformation of CLL/SLL to LCS needs to be addressed by further investigation.

To date, there has been only one documented synchronous CLL/SLL and LCS case.^[9] In the present case, The LCS component was identified when sheets of large epithelioid cells distinctly different from the background CLL cells were found and showed positivity for Langerhans cell antigen markers, that is, CD1a, S100 and langerin. LCH or Langerhans cell hyperplasia were ruled out by the high mitotic count, the high proliferation index (MIB-1) and focal necrosis in these epithelioid cells. Of note, CD1a

immunostain only showed partial positivity. It is uncertain whether the extent of CD1a positivity is reversely proportional to the aggressiveness of LCS, although the published LCS cases seem strongly positive for CD1a.^[9]

The FISH analysis with CLL panel showed that among six sets of probes, five of them (11q23, 13q14, and 13q34, centromere12, IGH, 17p13) showed normal signals both in CLL/SLL and LCS, but the sixth set (centromere6 and 6q23) showed loss of 6q23 signal in both CLL/SLL and LCS, which suggested that the LCS shared the same clonality with the CLL/SLL. So far there is only one publication that investigated cytogenetic changes of histiocytic/dendritic cell sarcomas arising from

SLL/CLL.^[9] In that study, all six cases of histiocytic/dendritic sarcomas (including one LCS) showed 17p abnormalities but only two cases of corresponding SLL/CLL had the same change. The authors proposed that the high frequency of 17p abnormalities (contains TP53 gene) might be a potential risk factor for transformation of CLL/SLL. In this case, 6q23 deletion, but not 17p abnormalities, was detected in both the CLL/SLL and the LCS components. Studies showed that 6q23 deletion was found in 5% of CLL patient.^[20] The gene in this region, c-MYB, controls the proliferation and differentiation of hematopoietic stem and progenitor cells. Loss-of-function study on c-MYB shows that there is a ten-fold increase in the number of hematopoietic stem cells.^[21,22] The exact role of c-MYB in leukemogenesis and transdifferentiation is not clear.

BRAF V600E mutation has been shown in many types of malignancy and the best known ones are melanoma and papillary thyroid carcinoma. Interestingly, recent studies showed that BRAF V600E mutation occurred in 38% to 57% of LCH and 54% of Erdheim-Chester disease, but not in Rosai-Dorfman disease, juvenile xanthogranuloma, histiocytic sarcoma, xanthoma disseminatum, IDCS, and necrobiotic xanthogranuloma.^[10,23] Our result demonstrates, for the first time, that LCS can bear the BRAF V600E mutation. It would be immature to predict the significance of such a molecular defect in LCS with only one case, but our finding certainly opens an opportunity to expand our knowledge of the genetics and tumorigenesis of LCS. Notably, a BRAF V600E mutant inhibitor vemurafenib has been approved for treating advanced melanoma. This novel drug is able to improve the progression-free survival of unresectable melanomas drastically.^[24] Dramatic efficacies of this drug in both multisystemic and refractory Erdheim-Chester disease and LCH that harbor BRAF V600E mutation have also been reported recently.^[23] Therefore, it is reasonable to deduce that similar treatment would be applicable in the management of LCS harboring the same mutation.

Conclusion

Taken together, we reported a case of synchronous and clonally related LCS arising from CLL/SLL. More importantly, for the first time, BRAF V600E mutation was detected in LCS, which opened the door for potential clinical trial of the BRAF V600E mutant inhibitor vemurafenib on LCS with this mutation. Larger case series, of course, would be needed in order to achieve this goal.

References

1. Wang E, Hutchinson CB, Huang Q, Sebastian S, Rehder C, Kanaly A, *et al.* Histiocytic sarcoma arising in indolent small b-cell lymphoma: Report of two cases with molecular/genetic evidence suggestive of a 'transdifferentiation' during the clonal evolution. *Leuk Lymphoma* 2010;51:802-12.
2. Zhang D, McGuirk J, Ganguly S, Persons DL. Histiocytic/dendritic cell sarcoma arising from follicular lymphoma involving the bone: A case report and review of literature. *Int J Hematol* 2009;89:529-32.
3. Baer MR, Krantz SB, Cousar JB, Glick AD, Collins RD. Malignant histiocytoses developing in patients with b-cell lymphomas. Report of two cases. *Cancer* 1986;57:2175-84.
4. Vasef MA, Zaatari GS, Chan WC, Sun NC, Weiss LM, Brynes RK. Dendritic cell tumors associated with low-grade b-cell malignancies. Report of three cases. *Am J Clin Pathol* 1995;104:696-701.
5. Wetzler M, Kurzrock R, Goodacre AM, McLaughlin P, Ku S, Talpaz M. Transformation of chronic lymphocytic leukemia to lymphoma of true histiocytic type. *Cancer* 1995;76:609-17.
6. Cossu A, Deiana A, Lissia A, Dedola MF, Cocco L, Palmieri G, *et al.* Synchronous interdigitating dendritic cell sarcoma and b-cell small lymphocytic lymphoma in a lymph node. *Arch Pathol Lab Med* 2006;130:544-7.
7. Fraser CR, Wang W, Gomez M, Zhang T, Mathew S, Furman RR, *et al.* Transformation of chronic lymphocytic leukemia/small lymphocytic lymphoma to interdigitating dendritic cell sarcoma: Evidence for transdifferentiation of the lymphoma clone. *Am J Clin Pathol* 2009;132:928-39.
8. Feldman AL, Arber DA, Pittaluga S, Martinez A, Burke JS, Raffeld M, *et al.* Clonally related follicular lymphomas and histiocytic/dendritic cell sarcomas: Evidence for transdifferentiation of the follicular lymphoma clone. *Blood* 2008;111:5433-9.
9. Shao H, Xi L, Raffeld M, Feldman AL, Ketterling RP, Knudson R, *et al.* Clonally related histiocytic/dendritic cell sarcoma and chronic lymphocytic leukemia/small lymphocytic lymphoma: A study of seven cases. *Mod Pathol* 2011;24:1421-32.
10. Badalian-Very G, Vergilio JA, Degar BA, MacConaill LE, Brandner B, Calicchio ML, *et al.* Recurrent braf mutations in langerhans cell histiocytosis. *Blood* 2010;116:1919-23.
11. Sahm F, Capper D, Preusser M, Meyer J, Stenzinger A, Lasitschka F, *et al.* Brafv600e mutant protein is expressed in cells of variable maturation in langerhans cell histiocytosis. *Blood* 2012;120:e28-34.
12. Long GV, Wilmott JS, Capper D, Preusser M, Zhang YE, Thompson JF, *et al.* Immunohistochemistry is highly sensitive and specific for the detection of v600e braf mutation in melanoma. *Am J Surg Pathol* 2013;37:61-5.
13. Bosmuller H, Fischer A, Pham DL, Fehm T, Capper D, von Deimling A, *et al.* Detection of the braf v600e mutation in serous ovarian tumors: A comparative analysis of immunohistochemistry with a mutation-specific monoclonal antibody and allele-specific pcr. *Hum Pathol* 2013;44:329-35.
14. Wang E, Papalas J, Hutchinson CB, Kulbacki E, Huang Q, Sebastian S, *et al.* Sequential development of histiocytic sarcoma and diffuse large b-cell lymphoma in a patient with a remote history of follicular lymphoma with genotypic evidence of a clonal relationship: A divergent (bilineal) neoplastic transformation of an indolent b-cell lymphoma in a single individual. *Am J Surg Pathol* 2011;35:457-463.
15. Xie H, Ye M, Feng R, Graf T. Stepwise reprogramming of b cells into macrophages. *Cell* 2004;117:663-76.
16. Cobaleda C, Jochum W, Busslinger M. Conversion of mature b cells into t cells by dedifferentiation to uncommitted progenitors. *Nature* 2007;449:473-7.

17. Carotta S, Nutt SL. Losing b cell identity. *Bioessays* 2008;30:203-7.
18. Ratei R, Hummel M, Anagnostopoulos I, Jahne D, Arnold R, Dorken B, *et al.* Common clonal origin of an acute b-lymphoblastic leukemia and a langerhans' cell sarcoma: Evidence for hematopoietic plasticity. *Haematologica* 2010;95:1461-6.
19. Ignatova ID, Kostadinova RM, Goldring CE, Nawrocki AR, Frey FJ, Frey BM. Tumor necrosis factor-alpha upregulates 11beta-hydroxysteroid dehydrogenase type 1 expression by CCAAT/enhancer binding protein-beta in HepG2 cells. *Am J Physiol Endocrinol Metab* 2009;296:E367-77.
20. Qiu HX, Xu W, Cao XS, Zhou M, Shen YF, Xu YL, *et al.* Cytogenetic characterisation in chinese patients with chronic lymphocytic leukemia: A prospective, multicenter study on 143 cases analysed with interphase fluorescence *in situ* hybridisation. *Leuk Lymphoma* 2008;49:1887-92.
21. Sandberg ML, Sutton SE, Pletcher MT, Wiltshire T, Tarantino LM, Hogenesch JB, *et al.* C-myb and p300 regulate hematopoietic stem cell proliferation and differentiation. *Dev Cell* 2005;8:153-66.
22. Zhang Y, Jin H, Li L, Qin FX, Wen Z. Cmyb regulates hematopoietic stem/progenitor cell mobilization during zebrafish hematopoiesis. *Blood* 2011;118:4093-101.
23. Haroche J, Cohen-Aubart F, Emile JF, Arnaud L, Maksud P, Charlotte F, *et al.* Dramatic efficacy of vemurafenib in both multisystemic and refractory erdheim-chester disease and langerhans cell histiocytosis harboring the braf v600e mutation. *Blood* 2013;121:1495-500.
24. Chapman PB, Hauschild A, Robert C, Haanen JB, Ascierto P, Larkin J, *et al.* Improved survival with vemurafenib in melanoma with braf v600e mutation. *N Engl J Med* 2011;364:2507-16.

How to cite this article: Chen W, Jaffe R, Zhang L, Hill C, Block AM, Sait S, *et al.* Langerhans cell sarcoma arising from chronic lymphocytic lymphoma/small lymphocytic leukemia: lineage analysis and braf v600e mutation study. *North Am J Med Sci* 2013;5:386-91.

Source of Support: Nil. **Conflict of Interest:** None declared.