




Since January 2020 Elsevier has created a COVID-19 resource centre with free information in English and Mandarin on the novel coronavirus COVID-19. The COVID-19 resource centre is hosted on Elsevier Connect, the company's public news and information website.

Elsevier hereby grants permission to make all its COVID-19-related research that is available on the COVID-19 resource centre - including this research content - immediately available in PubMed Central and other publicly funded repositories, such as the WHO COVID database with rights for unrestricted research re-use and analyses in any form or by any means with acknowledgement of the original source. These permissions are granted for free by Elsevier for as long as the COVID-19 resource centre remains active.



## Adjunctive homeopathic treatment of hospitalized COVID-19 patients (COVIHOM): A retrospective case series

Michael Takacs<sup>a</sup>, Michael Frass<sup>b,c,d,e,\*</sup>, Gernot Walder<sup>f</sup>, Philippa Fibert<sup>g</sup>, Maria Rottensteiner<sup>c</sup>, Walter Glück<sup>c</sup>, Peter Lechleitner<sup>a</sup>, Menachem Oberbaum<sup>h</sup>, Ilse Leisser<sup>i</sup>, Kavita Chandak<sup>j</sup>, Peter Panhofer<sup>c,d,k,l</sup>, Petra Weiermayer<sup>b</sup>

<sup>a</sup> Hospital of Lienz, Lienz, Austria

<sup>b</sup> WissHom: Scientific Society for Homeopathy, Koethen, Germany

<sup>c</sup> Umbrella Organization for Medical Holistic Medicine, Vienna, Austria

<sup>d</sup> Vienna International Academy for Holistic Medicine (GAMED), Otto Wagner Hospital Vienna, Austria

<sup>e</sup> Professor Emeritus, Medical University of Vienna, Department of Medicine I, Vienna, Austria

<sup>f</sup> Resident Specialist in Hygiene, Medical Microbiology and Infectious Diseases, Außervillgraten, Austria

<sup>g</sup> St Mary's University, London, UK

<sup>h</sup> Shaare Zedek Medical Center, The Center for Integrative Complementary Medicine, Jerusalem, Israel

<sup>i</sup> Apotheke Zum Weißen Engel – Homeocur, Retz, Austria

<sup>j</sup> Reeshabh Homeo Consultancy, Nagpur, India

<sup>k</sup> Chair of Complementary Medicine, Medical Faculty, Sigmund Freud University Vienna, Austria

<sup>l</sup> KLITM: Karl Landsteiner Institute for Traditional Medicine and Medical Anthropology, Vienna, Austria

### ARTICLE INFO

#### Keywords:

Complementary therapies  
COVID-19  
Homeopathy  
Intensive care unit  
SARS-CoV-2

### ABSTRACT

**Background:** and purpose. COVID-19 is a novel viral disease causing worldwide pandemia. The aim of this study was to describe the effect of adjunctive individualized homeopathic treatment delivered to hospitalized patients with confirmed symptomatic SARS-CoV-2 infection.

**Patient presentation:** Thirteen patients with COVID-19 were admitted. Mean age was  $73.4 \pm 15.0$  (SD) years. Twelve (92.3%) were speedily discharged without relevant sequelae after  $14.4 \pm 8.9$  days. A single patient admitted in an advanced stage of septic disease died in hospital. A time-dependent improvement of relevant clinical symptoms was observed in the 12 surviving patients. Six (46.2%) were critically ill and treated in the intensive care unit (ICU). Mean stay at the ICU of the 5 surviving patients was  $18.8 \pm 6.8$  days. In six patients (46.2%) gastrointestinal disorders accompanied COVID-19.

**Conclusion:** The observations suggest that adjunctive homeopathic treatment may be helpful to treat patients with confirmed COVID-19 even in high – risk patients especially since there is no conventional treatment of COVID-19 available at present.

### 1. Introduction

The novel coronavirus SARS-CoV-2 has spread worldwide and infected more than 111,4 million people to date (February 20, 2021) [1]. Recovery from a SARS-CoV-2 infection occurred in 86,269,184 (77.4%) people [1]. An interactive web-based dashboard at the Coronavirus Resource Center at Johns Hopkins University kept track of the progress of SARS-CoV-2 since December 2019 [2].

In Austria, the total number of people infected with SARS-CoV-2 is 439,879 (February 20, 2021). Out of 15,885 active infections, 261

patients are treated in intensive care units (ICU). Most active cases are registered in Carinthia and Styria. 8247 confirmed deaths of 439,879 SARS-CoV-2 infections (1.9%) were recorded by the Austrian Ministry of Health since February 26, 2020 [3].

Homeopathy has been used for over 200 years to treat patients suffering from a variety of diseases and disorders. There is evidence for the effectiveness of homeopathy in methodologically high-quality trials, meta-analyses [4] and systematic reviews [5] and homeopathy has a long-standing history of managing epidemic diseases effectively through both prevention and treatment [6].

\* Corresponding author. Institute for Homeopathic Research, Gaudenzdorfer Guertel 63, 1120, Vienna, Austria.

E-mail address: [office@ordination-frass.at](mailto:office@ordination-frass.at) (M. Frass).

<https://doi.org/10.1016/j.ctcp.2021.101415>

Received 18 October 2020; Received in revised form 4 May 2021; Accepted 5 May 2021

Available online 11 May 2021

1744-3881/© 2021 Elsevier Ltd. All rights reserved.

Existing trials of relevance to treatment of the current pandemic include a prospective, randomized, double-blind, placebo-controlled study of the effectiveness of homeopathic treatment of in patients suffering from severe sepsis [7], where individualized homeopathy significantly improved long-term survival. A recent prospective observational trial confirmed that homeopathic medication use during influenza-exposure significantly reduced number and duration of viral and bacterial upper respiratory tract infections in chronic obstructive pulmonary disease (COPD) patients and number of COPD exacerbations in patients with the exacerbator phenotype [8]. A randomized, placebo-controlled study of treatment of influenza like illness was published, where significant effects of individualized homeopathic medicinal products were found [9].

Conventional medicine has no preventative treatment yet, apart from public health measures such as social distancing, hand washing, face covering and quarantine [10]. A variety of preventative homeopathic strategies are being employed in a number of countries. The Indian Ministry of AYUSH (Ayurveda, Yoga and Naturopathy, Unani, Siddha and Homeopathy) advises use of the homeopathic medicinal product *Arsenicum album* [10]. In Brazil and Romania the homeopathic medicinal product *Camphora* is being deployed prophylactically. In Hong Kong, *Bryonia alba* and *Gelsemium sempervirens* are being deployed prophylactically following an observational Case series of 18 COVID-19 patients which assessed clinical symptoms from a homeopathic point of view and identified the homeopathic symptom pictures of these two homeopathic medicinal products [11]. Regarding treatment, the homeopathic community is currently recommending the collection of cases to assess and validate optimal homeopathic treatment for COVID-19 pandemic prior to more rigorous, systematic studies being conducted [12,13]. Study protocols exploring individualized homeopathy [14] for treatment of SARS CoV-2 are ongoing [15]. There are several promising case collection projects: Vithoulkas Compass COVID-19 Case Collection Project led by the Liga Medicorum Homoeopathica Internationalis (LMHI); CLIFICOL COVID-19 Case Collection Project led by the European Committee for Homeopathy (ECH).

Case series documenting individualized homeopathic treatment are beginning to emerge. A Tuscan Homeopathy outpatient clinic has prescribed homeopathic medicinal products for COVID-19 patients with mild presentation in domestic quarantine, and documented their clinical outcomes within the Clinical Files Collection (CLIFICOL) project [16]. A case series of 138 patients admitted to Nehru Homeopathic Hospital, New Delhi with COVID-19 has identified a group of appropriate homeopathic medicinal products [17].

The aim of this study was to present clinical experience with homeopathic treatment of COVID-19 patients presenting consecutively at the Hospital of Lienz, Austria, to contribute to this preliminary evidence for homeopathic treatment of COVID-19.

## 2. Materials and methods

### 2.1. Ethics

The authors confirm that the work described has been carried out in accordance with The Code of Ethics of the World Medical Association (Declaration of Helsinki) for studies involving humans. The manuscript is in line with the Recommendations for the Conduct, Reporting, Editing and Publication of Scholarly Work in Medical Journals and aimed for the inclusion of representative human populations (sex, age and ethnicity) as per those recommendations. Informed consent and assent were obtained from the patient or caregiver, respectively, before commencing retrospective study procedures.

### 2.2. Patients

All patients, females and males, admitted to the Hospital of Lienz, Austria, between March 20 and April 20, 2020 were included in this

retrospective Case series. Patients with a score  $\geq 3$  according to the Triage COVID-19 Hospital of Lienz Checklist (Table 1), were admitted to the general inpatient ward and the intensive care unit (ICU) of the hospital infection clinic. Data were derived from the hospital, and the treating homeopathic doctor, who has a homeopathic diploma from the Austrian Medical Association, and 30-years' experience (M.T.).

### 2.3. Physicians

The treating homeopathic doctor was instructed by the hospital on March 27, 2020, to adjunctively treat all inpatient COVID-19 patients homeopathically. He contacted two experienced colleagues for professional support: M.R., a medical doctor (MD) with a diploma for homeopathy from the Austrian Medical Association with a private practice in Lienz, and W.G., a MD with a diploma for homeopathy from the Austrian Medical Association, his former teacher.

It was decided to first identify a manageable list of the most important homeopathic medicinal products. Repertorization of the symptoms of the current pandemic and a search in the current homeopathic literature on COVID-19 was performed using computer program (Mac repertory MR 8.5.3.4 Professional, February 2018, Synergy Homeopathic Head Office: Hahnemann Clinic 1220 Brickyard Cove Road #101, Richmond, CA 94801, USA). 19 homeopathic medicinal products were identified (Table 2).

*Potencies.* Patients received a prescription according to the principles of the "Law of Similars" [14]. They received a homeopathic medicinal product selected by matching the patients' symptoms with those of a homeopathic medicinal product described in the textbook "Materia Medica" [18]. Homeopathic medicinal products were manufactured by Spagyra, Groedig, Salzburg, Austria, except for the nosodes [19,20] which were manufactured by the Pharmacy Homeocur, Retz, Lower Austria, Austria. All homeopathic medicinal products are registered according to the EU Directive 2001/83 and prepared according to the instructions of the European Pharmacopoeia. During this preparation, homeopathic medicinal products are highly diluted and succussed, resulting in so-called homeopathic "potencies." All homeopathic medicinal products were ordered as globules in potency CH200 except Influenzinum which was additionally ordered in potency CH10,000. For "CH-potencies" the original substance is diluted 1:100, followed by 10 succussions per step of dilution.

### 2.4. Prescription of treatments using the algorithm

An easy to use algorithm for prescription by other doctors according to the most prominent symptoms was developed since the treating homeopathic doctor (M.T.) was not available around the clock, in order that patients received immediate, comprehensive treatment. For ease of use, the homeopathic medicinal products were numbered. When the trained homeopathic doctor was on site, he could deviate from the algorithm according to his professional assessment and make prescription changes which better corresponded to the patient's symptoms in accordance with homeopathic principles [14].

One algorithm was developed for the general inpatient ward (Fig. 1), and another one for the ICU (Fig. 2). The algorithms were adapted weekly according to experience gained on the wards with regards to the observed clinical success of the homeopathic medicinal products.

At the start of treatment, each patient received *Influenzinum*, either in CH200 potency or in case of very bad condition, in CH10,000 potency on day one. It was prescribed due to the common presence of flu symptoms including pain of the limbs and joints, fever, as well as weakness in fever.

In the general inpatient ward algorithm (Fig. 1), patients were divided into six groups on day two according to the following symptoms, each of which was attached to an appropriate, numbered homeopathic medicinal product (numbers in parenthesis refer to the homeopathic medicinal products described in Table 2): throat symptoms accompanied with dry cough to *Anas barbariae hepatis et cordis* (2); dry deep

**Table 1**  
Checklist triage COVID-19, version 6, March 15, 2020.

Parameter	Points	Points
Fever	>38 °C	2
Cough and/or sore throat	Yes	1
Difficulties with breathing	Yes	1
Positive environmental Case history	Positive environmental history in the last 14 days (cases in the environment with the same symptoms) or contamination with material that contains pathogens	2
Score	Stay during the last 14 days in areas with more than 1 Case per 2000 inhabitants: Austria: Virgen, Heiligenblut, Landeck district, Innsbruck; Italy; Germany: Nordrhein- Westfalen, Baden-Wuerttemberg; Switzerland: Ticino; China; Hong Kong; Iran; Japan; Singapore; South Korea; or contact with a healed case	3

Checklist was applied to all patients submitted to the infection clinic. Points were added. Patients with a score  $\geq 3$  were admitted to the infection clinic.

**Table 2**  
Homeopathic medicinal products used in Case of COVID-19 related symptoms in accordance to Material Medica [13].

1	<i>Aconitum napellus</i> : dry cough, sore throat, fever
2	<i>Anas barbariae hepatis et cordis extractum</i> (Oscillococtinum®): dry cough, sore throat, fever, given in case of no symptoms
3	<i>Bryonia alba</i> : dry deep cough, unilateral pneumonia, fever, dyspnea
4	<i>Phosphorus</i> : dry deep cough, bilateral pneumonia, fever
5	<i>Lycopodium clavatum</i> : upper abdominal symptoms including pain, fever
6	<i>Antimonium tartaricum</i> : wet cough, cannot cough up, rapidly decreasing pneumonia, shortness of breath, fever
7	<i>Arsenicum album</i> : debilitating diarrhea, weakness, organic psychosyndrome, restlessness, fever
8	<i>Carbo vegetabilis</i> *: wet cough, cannot cough up, rapidly decreasing pneumonia, shortness of breath, fever
9	<i>Sulphur</i> ***: irritability, and selfishness, loose putrid cough, gastrointestinal symptoms; important follow-up to many acute homeopathic medicinal products to bring about further improvement
10	<i>Kalium carbonicum</i> ***: down-to-earth, simple, peasant character, very irritable, full of fear and imaginations, and hypersensitive to pain, noise, touch
11	<i>Camphora</i> : debilitating diarrhea, fever
12	<i>Nux vomica</i> : upper abdominal symptoms including pain, nausea, fever
13	<i>Gelsemium sempervirens</i> ***: trembling with fever, apathy, vertigo, head pain extending from temple to ear, muscle weakness
14	<i>Ipecacuanha</i> : dry cough with nausea/vomiting, rapidly descending infection/bronchitis, shortness of breath
N1	<i>Influenzinum</i> : frequent colds, catarrhs, influenza, weakness, tiredness, headache, joint pain and body aches, pharyngitis, laryngitis, gastroenteritis, nerve and muscle diseases after flu, consequences of flu ("never well since"), given in Case of no symptoms
N1X	<i>Influenzinum</i> CH10,000 (=CHXM)
N2	<i>Tuberculinum Koch</i> ***: weakness in fever; respiratory symptoms with cough; shortness of breath; and low type fever
N3	<i>Pyrogenium</i> ***: septic fever, offensive discharges, frequent pulse, palpitation, bed appears too hard

Numbers of the homeopathic medicinal products refer to the numbers in the circles of Figs. 1 and 2.

\*Not used in presented Case reports \*\*, not included into the algorithms.

N: Nosode.

All homeopathic medicinal products were ordered in potency CH200, except Influenzinum, which was additionally ordered in potency CH10,000.

cough to *Bryonia alba* (3); dry cough with nausea to *Ipecacuanha* (14); wet cough cannot expectorate to *Antimonium tartaricum* (6); upper abdomen symptoms to *Nux vomica* (12); diarrhea to *Arsenicum album* (7). All homeopathic medicinal products were administered three times a day.

In case of symptom improvement, homeopathic medicinal products were continued three times daily until complete recovery of the patient. Otherwise, homeopathic medicinal products were changed after 48 h to the following selection (numbers in parenthesis refer to the homeopathic medicinal products described in Table 2, sequence corresponding to the one mentioned above): *Aconitum napellus* (1), *Phosphorus* (4), consultation, *Carbo vegetabilis* (8), *Lycopodium clavatum* (5), *Camphora*

(11). If symptoms improved, the homeopathic regimen was continued three times daily until complete recovery of the patients. If there was deterioration or no improvement after four days, consultation with the homeopathic specialist was requested (see Fig. 1).

In the intensive care unit, on day two, patients were divided into four groups (Fig. 2) according to the following symptoms (numbers in parenthesis refer to the homeopathic medicinal products described in Table 2): dry cough to *Bryonia alba* (3), wet cough cannot expectorate to *Antimonium tartaricum* (6), upper abdomen symptoms or diarrhea to *Nux vomica* (12) or to *Camphora* (11), administered three times a day. In case of symptom amelioration the regimen was continued twice daily. If symptoms did not change within 48 h, homeopathic medicinal products were switched to *Phosphorus* (4), *Carbo vegetabilis* (8), *Lycopodium clavatum* (5), *Arsenicum album* (7), respectively (numbers in parenthesis refer to the homeopathic medicinal products described in Table 2, sequence corresponding to the one mentioned above) (Fig. 2). In case of organic psychosyndrome, *Arsenicum album* (7) was given.

Apart from the algorithm the frequency of follow-up visits and treatment changes were flexible and personalized. The therapeutic strategy was discussed with all colleagues and the nursing team in detail.

### 2.5. Administration of homeopathic medication

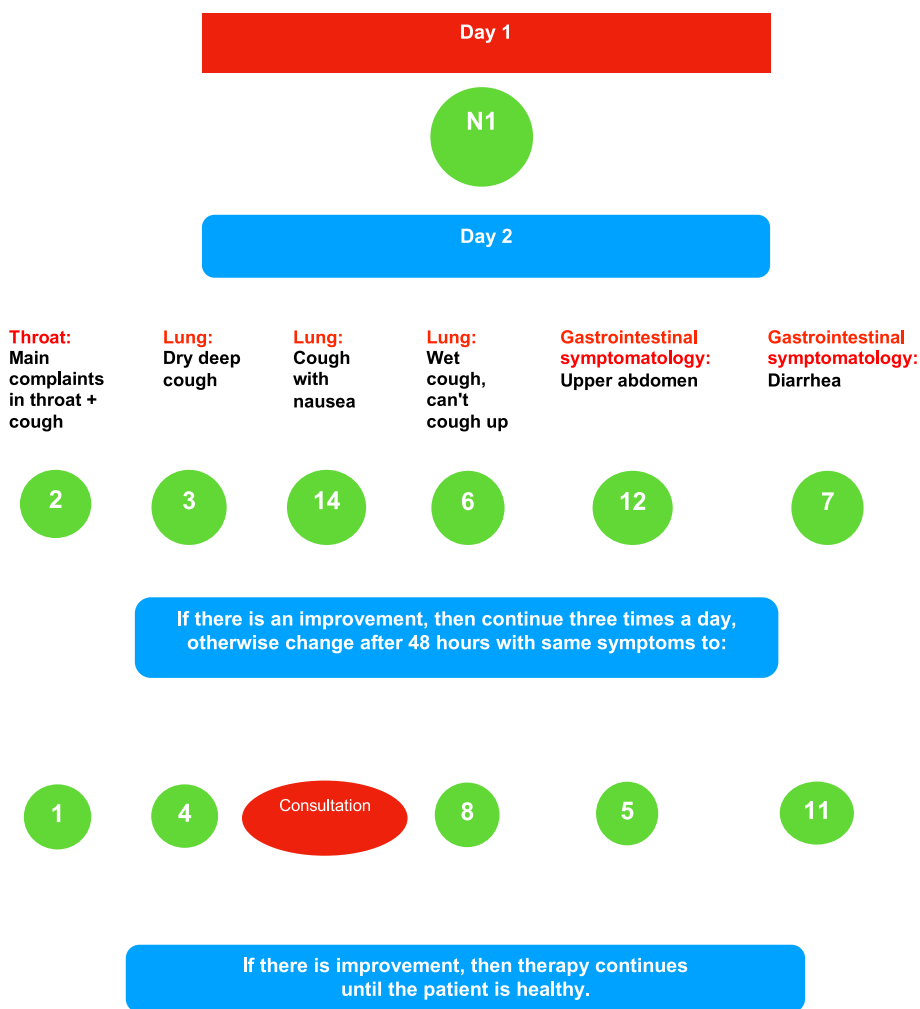
The homeopathic medicinal products were administered orally. Five globules were administered sublingually where they dissolved, three times a day. In ventilated patients in the ICU, medication was administered as a sip from a water beaker or 1 ml three times a day using a syringe (see Fig. 2).

### 2.6. Diagnostic procedures for COVID-19

The following testing methods were carried out in each patient to analyze a SARS-CoV-2 infection: polymerase chain reaction (PCR) E-Gen; PCR RdRP-Gen; PCR N-Gen (kits manufactured by TIB-Molbiol, Berlin, Germany) [21]; positive results were confirmed by a commercial assay targeting the S-Gen (Altona-Diagnostics, Hamburg, Germany) and an in-house PCR targeting the ORF-8. For a confirmed infection, at least 3 out of these 5 tests had to be positive. Tests for the orthomyxoviruses influenza A and B, human metapneumovirus (hMPV) and paramyxoviruses were negative unless stated otherwise.

## 3. Case reports

We report on the course of 13 patients who received homeopathic treatment in addition to conventional therapy. All patients except for Case 12 were informed about the homeopathic therapy. All surviving patients agreed to retrospective analysis. Case reporting follows HOM-CASE guidelines. Modified MONARCH criteria were assessed post hoc by all authors. Deviations were solved by discussion in person. Clinical outcome of case reports were evaluated using the "Modified Naranjo



**Figure 1.** Algorithm used in the general inpatient ward.

As always, the homeopathic doctor will be in the house at noon on Tuesday and Thursday. If you have any questions, the homeopathic doctor is available by phone at any time. Telephone visits are on Mondays and Fridays at 3 p.m. If there is deterioration or no improvement after four days, please ask for a consultation. 1: *Aconitum napellus*, 2: *Anas barbariae hepatis et cordis extractum* (Oscillocochin®), 3: *Bryonia alba*, 4: *Phosphorus*, 5: *Lycopodium clavatum*, 6: *Antimonium tartaricum*, 7: *Arsenicum album*, 8: *Carbo vegetabilis*, 11: *Camphora*, 12: *Nux vomica*, 14: *Ipecacuanha*. The numbers in the circles refer to the homeopathic medicinal products listed in Table 2.

As always, the homeopathic doctor will be in the house at noon on Tuesday and Thursday. If you have any questions, the homeopathic doctor is available by phone at any time. Telephone visits are on Mondays and Fridays at 3 p.m. If there is deterioration or no improvement after four days, please ask for a consultation. 1: *Aconitum napellus*, 2: *Anas barbariae hepatis et cordis extractum* (Oscillocochin®), 3: *Bryonia alba*, 4: *Phosphorus*, 5: *Lycopodium clavatum*, 6: *Antimonium tartaricum*, 7: *Arsenicum album*, 8: *Carbo vegetabilis*, 11: *Camphora*, 12: *Nux vomica*, 14: *Ipecacuanha*. The numbers in the circles refer to the homeopathic medicinal products listed in Table 2.

Criteria for Homeopathy-Causal Attribution Inventory” [22].

3.1. Case 1

A 72-year-old female patient had as underlying diseases mesangio-proliferative dialysis-related IgA nephritis with renal anemia and renal hypertension, hyperphosphatemia, secondary renal hyperparathyroidism, diabetes mellitus type II, a condition after gastrointestinal bleeding and uterine fibroids.

When admitted on March 20th, 2020, the patient reported that she had a fever since the previous day, accompanied by slight cough. The laboratory chemical examination confirmed a COVID-19 infection. She had no shortness of breath, no nausea, no vomiting, no diarrhea, and no fever. She was a well-known dialysis patient, and several patients and nurses in contact with the patient also had positive SARS-CoV-2 tests. Lung X-rays showed an enlarged heart, moderate cardiopulmonary signs of congestion, but no pneumonic infiltrate. The patient received antibiotic therapy with piperacillin/tazobactam (Tazonam®, Wyeth - Lederle Pharma, Vienna, Austria). During hospitalization, there was an increase of procalcitonin, C-reactive protein (CRP) and lactate-

dehydrogenase (LDH), whereby an infiltration area on the left could not be excluded retrocardially in the X-ray. On April 3rd, 2020, at the beginning of homeopathic therapy, the patient only had subfebrile temperatures and complained about moderate shortness of breath, sore throat, and dry cough. She received *Influenzinum* CH200, followed by *Anas barbariae hepatis et cordis* (Oscillocochin®, Lyon, France) CH200. Within 48 h, procalcitonin, CRP and LDH decreased, the shortness of breath improved. After two negative throat swabs, the patient could be discharged into home care on April 5th, 2020.

3.2. Case 2

A 77-year-old male patient was intubated and ventilated at the ICU on March 24th, 2020. He was transferred from South Tyrol, Italy, because of a shortage of hospital beds due to the pandemic, and tested positive for SARS-CoV-2. Previous illnesses included paroxysmal atrial fibrillation, arterial hypertension, chronic obstructive pulmonary disease (COPD), depression and hyperuricaemia. The ICU stay was uncomplicated; the patient exhibited tachycardial atrial fibrillation with a low blood pressure. Chest X-ray showed progressive infiltration areas.

### Application of the globules at the intensive care unit

Place five globules three times a day in the mouth. They melt there or dissolve five globules in a beaker, take a sip three times a day or pour 1 ml into the mouth with a syringe.

#### Day 1



If the general condition is very bad: N 1 X

#### Day 2

Dry cough	Wet cough, can't cough up	Upper abdominal symptoms	Diarrhea	Organic Psychosyndrome
3	6	12	11	7

If there is an improvement, then continue twice a day, otherwise change after 48 hours with the same symptoms to:

4	8	5	7
---	---	---	---

If there is improvement then the therapy continues until the patient is healthy.

Telephone visits are Monday, Tuesday, and Thursday at 2 p.m. If you have any questions, call the homeopathic doctor at any time. 3: Bryonia alba, 4: Phosphorus, 5: Lycopodium clavatum, 6: Antimonium tartaricum, 7: Arsenicum album, 8: Carbo vegetabilis, 11: Camphora, 12: Nux vomica. The numbers in the circles refer to the homeopathic medicinal products listed in Table 2.

**Figure 2.** Algorithm used in the intensive care unit. Telephone visits are Monday, Tuesday, and Thursday at 2 p.m. If you have any questions, call the homeopathic doctor at any time. 3: Bryonia alba, 4: Phosphorus, 5: Lycopodium clavatum, 6: Antimonium tartaricum, 7: Arsenicum album, 8: Carbo vegetabilis, 11: Camphora, 12: Nux vomica. The numbers in the circles refer to the homeopathic medicinal products listed in Table 2.

The patient received antibiotic therapy with piperacillin/tazobactam, in addition enoxaparin (two times 80 mg per day, Lovenox®, EurimPharm Arzneimittel GmbH, Saaldorf-Surheim, Germany) and bisoprolol (5 mg per day, Concor®, Merck, Vienna, Austria). The patient displayed regular frequency under this therapy. He was ventilated for 12 days, mostly with Biphasic Positive Airway Pressure (BIPAP). The patient was then transferred to the general inpatient ward on April 6th, 2020, where he developed delirium and dyspnea.

Homeopathic therapy started on April 6th, directly after extubation at the ICU. He was weak, shaky and arterial oxygen tension was low when lying down. He was given *Influenzinum* CH200 on the first day. Due to diarrhea, weakness, shortness of breath, *Camphora* CH200 was

added at day two. Development of psychosomatic syndrome with anxiety and restlessness led to a switch to *Arsenicum album* CH200 on April 8th and he was re-admitted to the ICU. The following day, an improvement in chest X-ray, psychosomatic and gastrointestinal symptoms was reported. This therapy continued until April 12th. On April 13th, the patient was given *Tuberculinum Koch* CH200 three times, because of pneumonia. On April 14th, the patient improved substantially regarding his pulmonary and psychological as well as gastrointestinal conditions and was transferred to the general inpatient ward. He was released in good general condition on April 16th, 2020.

### 3.3. Case 3

A 44-year-old male patient suffered from fever and pain. A SARS-CoV-2 positive swab and a symptomatic bilateral pneumonia were found during home quarantine. Due to increasing shortness of breath, the patient was admitted to the hospital on March 25th, 2020. The test for SARS-CoV-2 was again positive. No previous illnesses were known.

When admitted, the patient had 40 °C fever. Due to increasing dyspnea he was transferred to the ICU. The patient had pneumonic infiltration areas on both sides with an emphasis on the right upper lobe, and was treated with pressure-assisted ventilation using a CPAP helmet (Continuous Positive Airway Pressure). The patient received antibiotic therapy with piperacillin/tazobactam. As oxygen saturation continued to drop, the patient had to be endotracheally intubated on March 27th. He was hemodynamically stable during sedation.

Homeopathic therapy started on April 6th. The ventilated patient showed no symptoms useful for homeopathic repertorization. Therefore, the initial symptoms before intubation were considered. Symptoms started with a dry cough and high fever, then the patient became asphyctic. *Influenzinum* CH200 was administered on April 7th. On the next day, *Bryonia alba* CH200 was given due to dry cough, pneumonia, shortness of breath, and amelioration after rest. Within three days there was a clear regression of the pulmonary infiltrates and an increasing improvement of the pulmonary situation and the fever. That amelioration of the clinical course and the fall of temperature to 37.2 °C was attributed to homeopathic therapy by the ICU therapists. During spontaneous breathing, the patient extubated himself on April 7th. After extubation, the patient developed an organic psycho-syndrome, treated with diazepam (Psychopax®, Sigmapharm, Vienna, Austria) and haloperidol (Haldol®, Janssen-Cilag, Neuss, Germany). *Bryonia alba* CH200 was given until April 10th. As the combined organic psycho-syndrome and respiratory symptoms did not improve sufficiently, the switch to *Arsenicum album* CH200 was performed on April 12th. *Influenzinum* CH200 and *Tuberculinum Koch* CH200 were added on April 12th and April 13th, respectively. On April 14th, the patient reported a substantial improvement. He was transferred to the general inpatient ward and now received *Kalium carbonicum* CH200 as a constitutional homeopathic therapy with special emphasis on dry cough and pneumonia. X-ray findings showed infiltrates had completely vanished and after two negative pharyngeal swab results, the patient was released without symptoms on April 16th, 2020.

### 3.4. Case 4

Infection with SARS-CoV-2 was confirmed in a 59-year-old male patient on March 19th, 2020. The patient presented with a headache, irritable cough, aching limbs and fever. Previous illnesses include diabetes mellitus type II, arterial hypertension, left ventricular hypertrophy, hyperlipidemia, transient ischemic attack, left hemicolectomy due to a perforated diverticulitis in 2003, facial herpes simplex, and a cyst on the left submandibular side. During home quarantine the patient had no symptom improvement, so due to increasing shortness of breath and cough, persistent headaches and aching limbs, the patient was admitted to hospital on March 25th, 2020. The sense of taste was severely impaired. As his respiratory situation deteriorated over the course of time, he was transferred to the ICU on March 29th, 2020. After the Horovitz quotient ( $\text{paO}_2/\text{FiO}_2$ ) had dropped to 170 mmHg on March 30th, the patient was intubated endotracheally by videolaryngoscopy and ventilated with BIPAP. The following day, the patient received antibiotic therapy with piperacillin/tazobactam and levofloxacin (Levofloxacin-ratiopharm®, Ulm, Germany). On April 1st, there was a brief improvement in the Horovitz quotient. On April 5th, chest X-ray revealed progressive infiltration areas. Homeopathic therapy started on April 6th with *Influenzinum* CH200 for one day. A progressive weaning from the respirator was implemented on April 7th. In addition, the patient received *Ipecacuanha* CH200 due to the dry cough and the rapidly

descending bronchial infection with shortness of breath. As no relevant improvement was reported, the therapy was switched to *Bryonia alba* CH200 on April 9th. From that moment on, a substantial amelioration of dyspnea with a significant decrease of the pulmonary infiltrates was found, so *Bryonia alba* CH200 was continued until April 14th. The patient could be extubated on April 11th. After extubation, the patient became agitated with restlessness, fear, weakness, and erosions of the oral mucosa. He was supported with a CPAP helmet. A switch to *Arsenicum album* CH200 was carried out on April 14th for another 2 days. Since there was no further improvement with *Arsenicum album* from April 16th on, *Influenzinum* CH200 was administered on April 17th and *Tuberculinum Koch* CH200 on April 18th. That therapeutic strategy resulted in a significant psychological improvement. The patient could be transferred to the general inpatient ward on April 18th. As he was very irritable, full of fear and imaginations, and hypersensitive to pain, noise, touch, with a concomitant pneumonia including dry cough he received *Kalium carbonicum* CH200 twice daily starting on April 20th. The further clinical course remained uncomplicated. The patient was discharged home after two negative SARS-CoV-2 swabs on April 22nd, 2020.

### 3.5. Case 5

An 87-year-old female patient was admitted to the hospital on March 26th, 2020. Arterial hypertension and dementia were known from previous illnesses. Three days before admission, the patient had a fever of over 38 °C, dry cough, sore throat, and an increasing reduction in her general condition. She had eaten and drunk almost nothing during the last three days.

At the hospital, her medical history was difficult to obtain due to dementia. The patient reported no subjective complaints, the chest X-ray was unremarkable, she was respiratory stable with an oxygen saturation of 92%. Due to dehydration, infusion therapy was carried out. The PCR diagnosis was SARS-CoV-2 positive on March 26th. Lung X-rays showed clear infiltrations in both lungs on April 2nd; SARS-CoV-2 positive PCR with no bacterial growth verified in the sputum. The patient received antibiotic therapy with amoxicillin and clavulanic acid (Curam®, Sandoz GmbH, Kundl, Austria). In addition, the patient was treated homeopathically starting on April 3rd. Initially the one-time *Influenzinum* CH200 algorithm was used, after which the pulmonary findings improved significantly within the next 3 days (as pneumonia caused by SARS-CoV-2 had a viral genesis and negative bacterial growth, antibiotic effects may be excluded). Due to a dry cough and sore throat, *Anas barbariae hepatis and cordis* CH200 (Oscillococtinum®, Boiron, Lyon, France) was administered until the patient's dismissal. The cough and sore throat improved significantly within a few hours of *Anas barbariae hepatis and cordis* CH200.

The first SARS-CoV-2 swab was already negative on April 4th. After another negative finding, the patient was discharged on April 6th, 2020.

### 3.6. Case 6

A 50-year-old male patient was admitted to hospital on March 28th, 2020. Symptoms included shortness of breath within COVID-19 pneumonia. A pre-existing obstructive sleep apnea syndrome (OSAS) required nightly CPAP therapy. Pronounced infiltration areas were seen on both lungs in the X-ray. On the same day, the patient had to be transferred to the ICU due to worsening respiratory conditions. Homeopathic treatment was started with *Influenzinum* CH200 on April 6th. *Bryonia alba* CH200 was added for the treatment of the dry cough, pneumonia and shortness of breath for the next two days. Due to insufficient success, the homeopathic regimen was switched to *Phosphorus* CH200 on April 9th, with focus on the dry cough and pneumonia. An immediate respiratory improvement was confirmed by chest X-ray. *Phosphorus* CH200 was continued until discharge. Continuous CPAP therapy using a CaStar helmet reinforced the respiratory improvement,

so that a Horovitz quotient of 250 mmHg was achieved under ambient air. The patient was transferred to the general inpatient ward on April 14th, and discharged to home care after two negative swab findings on April 15th, 2020.

### 3.7. Case 7

A 70-year-old male patient was admitted to the isolation ward on March 30th, 2020. The patient suffered from cramp-like pain in the left lower abdomen accompanied by intermittent nausea and diarrhea for 2 days before hospital admission. There was no lack of appetite, intermittent loss of taste and smell, and no respiratory symptoms. His previous diseases included arterial hypertension with a cor hypertonicum, paroxysmal atrial fibrillation, a DDD pacemaker due to a carotid sinus syndrome, a right renal artery stent with pronounced arteriosclerosis, hyperthyroidism, and stage III renal insufficiency.

The patient's daughter, who lived in the same household, had been diagnosed with suspected COVID-19 respiratory symptoms including taste and smell loss, but a swab result was not yet available. His main symptom was abdominal pain; his respiratory situation remained stable, with arterial oxygen saturation 99%, heart rate 85/minute, temperature 39.5 °C. A positive diagnosis of COVID-19 was made on the day of admission. Intestinal sounds could be clearly heard above the left lower abdomen. The ultrasound of the abdomen was normal, but the X-ray showed emphysema and inflammatory round spots in the upper field of the right lung. Computed tomography of the thorax showed milk-glass-like infiltrations in both hemithoraces as in interstitial pneumonia, and increased lymphatic tissue on both sides. Due to persistent abdominal pain and ongoing fever despite antibiotic therapy with amoxicillin and clavulanic acid (Curam®, Sandoz GmbH, Kundl, Austria), a computed tomography (CT) of the chest, abdomen and pelvis was performed. CT showed left sided pyelonephritis and the pronounced pulmonary changes listed above. Bacterial superinfection with an unclear focus was diagnosed, with possible bacterial pneumonia or pyelonephritis. Homeopathic therapy started on April 3rd in the isolation ward. The focus was on his subfebrile temperatures (37.0–37.5 °C), nausea and upper abdominal pain. The patient received *Influenzinum* CH200 because of the flu-like symptoms. *Nux vomica* CH200 was added from April 4th until discharge due to nausea, abdominal pain and wailing during fever. There was a clear time-dependent improvement in fever, pulmonary X-ray, both abdominal symptoms, and the sense of smell and taste from April 6th on. A switch to ciprofloxacin (Cipro Basics®; Basics GmbH, Leverkusen, Germany) on the same day might have had another beneficial effect on his bacterial superinfection. On April 6th, the patient received *Sulphur* CH200 as a constitutional homeopathic medicinal product due to his childish peevishness, irritability, and selfishness. In addition, *Sulphur* also follows well after *Nux vomica*. Two tests for SARS-CoV-2 on April 6th and 7th, 2020 were negative and the patient was discharged home free of fever and any other symptoms on April 7th, 2020.

### 3.8. Case 8

A 91-year-old female patient was admitted to hospital on April 2nd, 2020 due to persistent diarrhea. Her respiration was unremarkable. Previous conditions included arterial hypertension and artificial knee joint implants. For a week, the patient had been suffering from diarrhea and nausea after eating. She had no fever, no cough, little appetite, and some weight loss. The sense of smell and taste were reduced, and there was a constant feeling of thirst. The SARS-CoV-2 swab at the family doctor was positive (only PCR N-gene negative). The examination of the stool for germs was negative. In the chest X-ray there were signs of congestion grade I to II, and a small round focus in the right midfield and a small infiltration in the left midfield. The patient started homeopathic therapy on April 3rd. She received *Influenzinum* CH200 on the first day. The next day her chest X-ray returned to normal except for the focus in

the right midfield. She received *Arsenicum album* CH200 from April 4th due to weakness during diarrhea and fever, loss of smell and taste. The diarrhea as well as the smell and taste symptoms improved rapidly within one day and subsequently ceased. Two further SARS-CoV-2 examinations were negative, so that the patient was discharged in a healthy state on April 8th, 2020.

### 3.9. Case 9

A 70-year-old female patient was admitted to the hospital on April 7th, 2020. SARS-CoV-2 infection had been confirmed on March 27th. The admission was due to deterioration in her general condition and increased inflammation parameters. The patient had no fever, cough, sore throat, subjective dyspnea, smell or taste disorder. She had a history of spinal ataxia after transverse myelitis in 2014, breast cancer, right sided psoas abscess, median disc prolapse L2/L3 and L3/L4, nodular hyperplasia of the left adrenal gland and right adrenal adenoma, as well as a central dizziness. C-reactive protein was elevated to 12 mg/dL (upper reference value: 0.5 mg/dL). Pronounced pulmonary infiltration areas were impressed on both sides in the chest X-ray. The patient received the antibiotic combination of clarithromycin (Klacid®, Mylan Healthcare GmbH, Bad Homburg, Germany) and doxycycline (Doxybene®, Merckle GmbH, Blaubeuren, Germany) starting on April 7th. SARS-CoV-2 testing from expectoration was positive at this time. The oxygen saturation in indoor air fluctuated between 80% and 94%. The patient received homeopathic therapy during the entire inpatient stay. There were few clinical symptoms, only a slight dry cough was noticeable: after *Influenzinum* CH200 on the first day, the patient received *Anas barbariae hepatis and cordis* CH200. The criteria for choosing the homeopathic medicinal products were lack of symptoms, dry cough, fever, and aching limbs. After *Influenzinum*, C-reactive protein dropped to normal values and pulmonary process improved (antibiotics were not responsible due to the viral cause of the pneumonia as assessed by PCR of expectoration and negative bacterial growth). Her symptoms and condition improved quickly, so she could be transferred back to her nursing home after two negative tests for SARS-CoV-2, on April 11th, 2020.

### 3.10. Case 10

An 80-year-old patient was admitted to the hospital on April 10th, 2020 because of fever up to 38.2 °C; there were no further complaints except extreme weakness. The patient had been positive for SARS-CoV-2 since April 6th. She had recently fallen, injured her left hip, and has been suffering from pain when walking. Her disease history included type II diabetes mellitus, paroxysmal atrial fibrillation, arterial hypertension, hyperuricaemia and penicillin allergy. Due to increasing respiratory insufficiency with pulmonary infiltrates, the patient was transferred to the ICU on April 13th. In addition to the respiratory CPAP support she was treated with additive homeopathy until her discharge starting with *Influenzinum* CH200 for one day due to dry cough and high fever, with *Bryonia alba* CH200 added due to dry cough and pneumonia. After three days without major improvement *Bryonia alba* was replaced by *Antimonium tartaricum* CH200, because the initial cough was wet and she could not cough up, accompanied by pneumonia. There was still no improvement so on further evaluation a switch to *Phosphorus* CH200 due to dry, deep cough as well as pneumonia was performed. After three days of a stable disease status *Influenzinum* CH200 was given twice a day for 2 days. A drop of temperature below 37 °C and marked improvement of cough as well as of pulmonary infiltrates was noted and she began to cough up loose putrid sputum. Due to cessation of treatment and pneumonia, *Tuberculinum Koch* CH200 was then administered for 2 days. The cough became less and she coughed up less sputum. The loose putrid cough together with pneumonia led to the switch to *Sulphur* CH200, which follows well after Phosphorus. She immediately felt much better with that regimen. On April 24th she was transferred back to the general



inpatient ward. Antibiotic therapy continued with clarithromycin (Klacid®) and imipenem/cilastatin (Zienam®, MSD Sharp and Dohme GmbH, Haar, Germany) to prevent bacterial superinfection. After two negative swabs on SARS-CoV-2, the patient was discharged home on April 27th, 2020.

### 3.11. Case 11

An 86-year-old female was admitted with the symptoms fever, cough, loss of appetite, fatigue and diarrhea in a significantly reduced general condition on April 13th, 2020. With COVID-19 positive swab, left basal pneumonia was conspicuous. The patient was desiccated, but respiratory function was not noticeably reduced. She had a history of an apoplectic insult of the left internal capsule in April 2019, hypercholesterolemia, left ventricular hypertrophy, compensated heart failure, left bundle branch block, depression, and allergies to some medications. Homeopathic treatment started on the day of admission and continued until discharge. *Influenzinum* CH200 was routinely given on day 1, followed by *Arsenicum album* CH200 for 2 days due to weakness and diarrhea. The diarrhea disappeared, but the patient was still very weak, very dry and coughed slightly. Due to the lack of symptoms and dry cough, *Influenzinum* CH200 and *Anas barbariae hepatis and cordis* CH200 were given alternately for four days. After two days fever, cough, loss of appetite, fatigue and diarrhea improved significantly. *Anas barbariae hepatis and cordis* CH200 were then given twice daily until discharge after two negative swabs on April 21st, 2020.

### 3.12. Case 12

A 76-year-old patient was admitted to hospital on April 15th, 2020 after being found on his left side in his apartment with an armchair on his feet for 4 days. The patient was awake with clear airways but he exhibited tachypnea without palpable pulse and had a fever of 38 °C. Septic shock was suspected. A necrotizing ulcer on the left thigh was assumed to be the reason for his sepsis. The peritrochanteric gangrene parts on the left side were surgically debrided. His disease history revealed arterial hypertension, coronary artery disease with stent care, type II diabetes mellitus, peripheral arterial disease and incomplete paraplegia due to polytrauma in 1987. The patient suffered cardiovascular arrest and was brought to the ICU after cardiopulmonary resuscitation under controlled ventilation. Nevertheless, the patient remained hemodynamically unstable, and tested positive for SARS-CoV-2. The patient was treated with piperacillin/tazobactam and levofloxacin (Tavanic®, Sanofi-Aventis Deutschland GmbH, Frankfurt/Main, Germany). At the ICU he received *Influenzinum* XM every hour, diluted in 1 ml of water, applied to the mouth. *Influenzinum* was chosen because of flu-like, septic symptoms together with a lack of symptoms. Subsequently, the patient required high doses of catecholamines, but septic shock was not manageable, and the patient died at the ICU on April 17th, 2020.

### 3.13. Case 13

A 92-year-old male patient was admitted to hospital on April 20th, 2020 because of aspiration pneumonia in the left midfield and left basal with a small pleural effusion on the left. On April 13th, he had tested positive for SARS-CoV-2. The patient had a history of post bronchopneumonia, a juxta-papillary duodenal diverticulum, a condition after endoscopic papillotomy in 2010, a cholecystectomy, neurogenic swallowing disorders and cachexia. CRP was slightly increased to 2.88 mg/dL (reference value below 0.5 mg/dL). Antibiotic therapy with doxycycline had already been started by the family doctor. The following day, the antibiotic regimen was changed to moxifloxacin (Avelox®, Bayer AG, Leverkusen, Germany) to avoid bacterial superinfection. The patient showed no signs of respiratory distress. Percutaneous endoscopic gastrostomy (PEG) was used for nutrition. Homeopathic treatment was

carried out over the entire inpatient stay: The patient had no clinical symptoms apart from pneumonia, fever and aching limbs. Treatment with *Influenzinum* CH200 was started on the day of admission, three times daily 1 ml were administered via a syringe orally on the first day, then *Tuberculinum Koch* CH200 in the same way, followed by repeated application of *Influenzinum* CH200. On April 22nd, another SARS-CoV-2 positive test from expectoration confirmed a viral cause of pneumonia, while bacterial superinfection was excluded. The patient's condition as well as pneumonia quickly improved immediately after start of homeopathic therapy as shown by chest X-ray. After a fast transfer to the general inpatient ward and two further negative SARS-CoV-2 tests, he was released home three days later on April 26th, 2020.

### 3.14. Comments on patient HISTORIES DESCRIBING decisions and LIMITATIONS

#### 3.14.1. Cases 3 and 4

The response to homeopathic therapy is spectacular and clear. It is underpinned by the choice of the initially unsuitable homeopathic medicinal product (*Ipecacuanha*) in patient 4. The further course with intermittent administration of a nosode at the right time was very satisfactory.

#### 3.14.2. Case 6

*Bryonia alba* is known to display unilateral pneumonia in the center image, opposite to *Phosphorus* with bilateral pneumonia. The strategy was chosen strictly according to the developed guidelines.

#### 3.14.3. Case 10

Some wrong decisions were made: the initial switch to *Antimonium tartaricum* was due to erroneous third-party information. A radiological verified pneumonia with dry cough and a relatively low level of symptoms was found, therefore, *Phosphorus* was administered afterwards. The wrong choice of homeopathic medicinal product worsened the initially positive response to *Influenzinum*, but a repetition of *Influenzinum* led again to marked amelioration with a drop of fever to normal temperature. Fortunately, the final constitutional homeopathic medicinal product was chosen more carefully.

#### 3.14.4. Case 11

The striking feature is the lack of symptoms. What is striking is the extreme dehydration. The treating homeopathic doctor was probably restrictive in administering nosodes. *Influenzinum* for four days could have helped more. This Case underlines the importance of nosodes similar to Case 13.

#### 3.14.5. Case 13

This was the first patient treated with nosodes only demonstrating their benefits in patients with few symptoms. Within the European Union (EU), the registration of homeopathic medicinal products without indication and the approval of homeopathic medicinal products with indication are stipulated in the EU Directive 2001/83 (Directive 2001/83/EC of the European Parliament and of the Council of November 6, 2001 on the creation of a Community code for medicinal products for human use) [23].

## 4. Results

### 4.1. Patients

13 patients with COVID-19 symptoms were admitted and stayed from 3 to 35 days in hospital between March 20th and April 20th. All patients were older than 18 years, mean age 73.4 ± 15.0 (SD) years. Homeopathic treatment started in the general inpatient ward on April 3rd, and in the ICU on April 6th, 2020. The time lag was due to the need to prepare the algorithms for homeopathic treatment and inform the

doctors and nurses. Some patients were transferred from one ward to the other and back again during their inpatient stay, with 6 out of 13 patients (46.2%) transferred to the ICU for 2–30 days. Mean stay at the ICU of the 5 surviving patients was  $18.8 \pm 6.8$  days (13–30 days). All patients were treated with conventional medicine. All 13 patients were treated with additional homeopathic medicinal products and 12 out of 13 patients (92.3%) were speedily discharged without relevant sequelae after  $14.4 \pm 8.9$  days. In all surviving patients, a time-dependent improvement of relevant clinical symptoms was observed. The non-survivor had been admitted to the hospital ICU with prolonged septic shock which was not manageable by conventional or homeopathic medicine. In 6 out of 13 patients (46.2%), gastrointestinal disorders accompanied the COVID-19 disease, including more than one symptom: diarrhea in 5, abdominal pain in 1, loss of taste in 3 or smell in 2, and reduction of appetite in 2 patients.

#### 4.2. Use of algorithms

All patients were given a first prescription of *Influenzinum*. The following homeopathic medicinal products were prescribed as second prescriptions to those in the general inpatient ward (numbers following homeopathic medicinal products refer to Table 2, List of provided homeopathic medicinal products): *Anas barbariae hepatis et cordis* (2), *Bryonia alba* (3), *Ipecacuanha* (14), *Antimonium tartaricum* (6), *Nux vomica* (12) or *Arsenicum album* (7). Third prescriptions (no change after 48 h) were: *Aconitum napellus* (1), *Phosphorus* (4), *consultation*, *Carbo vegetabilis* (8), *Lycopodium clavatum* (5), *Camphora* (11) (Fig. 1).

In the ICU on day two, second prescriptions were *Bryonia alba* (3), *Antimonium tartaricum* (6), *Nux vomica* (12), *Camphora* (11) or *Arsenicum album* (7). Third prescriptions (no change within 48 h) were: *Phosphorus* (4), *Carbo vegetabilis* (8), *Lycopodium clavatum* (5), *Arsenicum album* (7) (Fig. 2).

The algorithm was adjusted to take account of clinical experience: *Camphora* slipped to 2nd position in favor of *Arsenicum album*; a block of diffuse symptoms was deleted from the algorithm; and gastrointestinal symptoms were differentiated into upper abdominal complaints and diarrhea. In the intensive care unit, the block “organic psychosyndrome” was added to the algorithm due to three patients.

#### 4.3. Naranjo assessment

The additional modified Naranjo assessment (Table 3) as part of the HOM-Case-CARE guidelines revealed between +7 and +8 points in 11 patients (84.6%), except for one patient with a score of +3 and the non-survivor with a score of –3 points (range –6 to +13 points for each patient; Table 4). Six points was assumed as the limit for potential correlation between homeopathic therapy and amelioration of the symptoms or healing in acute cases in our study, while eight points was assumed as the limit in chronic cases [22].

### 5. Discussion

The encouraging results showed that 12 of 13 patients (92.3%) survived without sequelae. 6 patients were critically ill (46.2%) and being treated in the ICU. One patient admitted to the hospital ICU in an advanced stage of septic disease died. Interestingly, nearly half of the patients (46.2%) reported gastrointestinal symptoms accompanying COVID-19. While it is not possible to attribute the positive outcomes of this Case series to homeopathic therapy, other studies are emerging also suggesting that additive homeopathy can be helpful in the treatment of COVID-19 patients [9,16].

Paragraph 153 from the Organon of the founder of Homeopathy, Hahnemann, states [14]: “In this search for a homeopathic specific remedy ... .., the more striking, singular, uncommon and peculiar (characteristic) signs and symptoms of the Case of disease are chiefly and most solely to be kept in view; for it is more particularly these that

**Table 3**

MONARCH causality attribution criteria.

Questions are to be answered for each Case. Points need to be calculated for each case.			
	Yes	No	Not Sure or N/A
1. Was there an improvement in the main symptom or condition for which the homeopathic medicine was prescribed?	+2	–1	0
2. Did the clinical improvement occur within a plausible timeframe relative to the drug intake?	+1	–2	0
3. Was there a homeopathic aggravation* of symptoms?	+1	0	0
4. Did the effect encompass more than the main symptom or condition (i.e., were other symptoms, not related to the main presenting complaint, improved or changed)?	+1	0	0
5. Did overall well-being improve? (Suggest using a validated scale or mention about changes in physical, emotional, and behavioral elements)	+1	0	0
6 (A) <i>Direction of cure</i> : did some symptoms improve in the opposite order of the development of symptoms of the disease?	+1	0	0
6 (B) <i>Direction of cure</i> : did at least one of the following aspects apply to the order of improvement of symptoms: - from organs of more importance to those of less importance - from deeper to more superficial aspects of the individual - from the top downwards	+1	0	0
7. Did “old symptoms” (defined as non-seasonal and non-cyclical symptoms that were previously thought to have resolved) reappear temporarily during the course of improvement?	+1	0	0
8. Are there alternative causes (other than the medicine) that –with a high probability- could have produced the improvement? (Consider known course of disease, other forms of treatment, and other clinically relevant interventions.)	–3	+1	0
9. Was the health improvement confirmed by any objective evidence**? (e.g., investigations, clinical examination, etc.)	+2	0	0
10. Did repeat dosing, if conducted, create similar clinical improvement?	+1	0	0
<b>TOTAL SCORE</b>	<b>(range -6 to +13)</b>		

\*Homeopathic aggravation: A temporary worsening of pre-existing symptom(s) within a plausible timeframe after the administration a homeopathic medicine, followed by an improvement in the patient’s condition.

\*\*Objective evidence: Findings that reflect expert external observation of any measurement of the patient. Objective evidence includes lab tests, X-ray reports, health care provider examination or observation, or other similar data.

very similar ones in the list of symptoms of the selected medicine must correspond to, in order to constitute it the most suitable for effecting the cure. The more general and undefined symptoms: loss of appetite, headache, debility, restless sleep, discomfort, and so forth, demand but little attention.” The § 153 symptoms were: reduction in smell and taste in several patients; all complaints coming during fever and not during chill; low type fever in many patients; it was also striking that about half of the patients showed gastrointestinal symptoms.

All ventilated patients exhibited dry cough resulting in respiratory failure. They were given *Influenzinum*, as were the patients at the general inpatient ward. *Influenzinum* is characterized by frequent colds, catarrhs, influenza, weakness, tiredness, headache, joint pain and aching limbs, pharyngitis, laryngitis, gastroenteritis, nerve and muscle diseases after flu, consequences of flu (“never well since”) [18].

The ongoing COVID-19 pandemic was initially represented as a severe acute respiratory illness, with eventual dramatic complications. However, over time it revealed to be a complex systemic disease with manifestations derived from viral-induced inflammation and hypercoagulability, thus liable to affect any body organ or system. As a result, clinical presentation is variable, and additional variations are associated

**Table 4**

MONARCH Causality Attribution Criteria for the 13 patients.

Pat.: Patient No.; Total: Total Score.

Pat.	1	2	3	4	5	6	7	8	9	10	11	12	13
1	+2	+2	+2	+2	+2	+2	+2	+2	+2	+2	+2	-1	+2
2	+1	+1	+1	+1	+1	+1	+1	+1	+1	+1	+1	-2	+1
3	0	0	0	0	0	0	0	0	0	0	0	0	0
4	0	+1	0	0	0	0	0	0	0	0	0	0	0
5	+1	+1	+1	+1	+1	+1	+1	+1	+1	+1	+1	0	+1
6 A	0	0	0	0	0	0	0	0	0	0	0	0	0
6 B	0	0	0	0	0	0	0	0	0	0	0	0	0
7	0	0	0	0	0	0	0	0	0	0	0	0	0
8	+1	+1	+1	+1	+1	+1	-3	+1	+1	+1	+1	0	+1
9	+2	+2	+2	+2	+2	+2	+2	+2	+2	+2	+2	0	+2
10	0	0	0	0	0	0	0	0	0	0	0	0	0
Total	+7	+8	+7	+7	+7	+7	+3	+7	+7	+7	+7	-3	+7

with individual and collective risk factors [24]. Given the extreme variability of pathology and clinical manifestations, a single universal preventive homeopathic medicinal product does not seem feasible. Yet homeopathy may have a relevant role to play precisely because of the number and diversity of its homeopathic medicinal products which can be matched with the diversity of the presentations. Patients with mild forms of disease can use homeopathic medicinal products at home using our simple algorithm. As this Case series suggests, adjunctive homeopathic treatment can play a valuable role in more serious presentations. For future pandemics, homeopathy agencies should be prepared by establishing rapid-response teams and efficacious lines of communication [24].

As conventional medicine has no evidence-based proven or available therapeutic option or guidelines for the treatment of COVID-19 there is no reasonable explanation why a physicist and a specialist in physical medicine (without clinical experience of viral epidemics and lacking any COVID-19 expertise), and some others have tried to vehemently prevent scientific homeopathic efforts in the field of the COVID-19 viral pandemic, without offering any constructive or therapeutic input themselves [25].

## 6. Conclusion

In conclusion, additive classical homeopathy may be helpful to treat patients with confirmed COVID-19 disease. To allow homeopathic treatment by a team of physicians with different levels of knowledge about homeopathy, the use of algorithms appears to be feasible. The combination of conventional medicine and homeopathy in COVID-19 patients seems to be a promising way forward in terms of integrative medicine to optimize patient treatment. Further prospective, randomized, double-blind, placebo-controlled studies are warranted.

## Funding information

There was no funding for the homeopathic treatment or the preparation and writing of the manuscript.

## CRediT authorship contribution statement

**Michael Takacs:** Conceptualization, Methodology, Software, Writing – original draft, Writing – review & editing, Project administration. **Michael Frass:** Conceptualization, Investigation, Data curation, Writing – original draft, Writing – review & editing, Supervision. **Gernot Walder:** Resources. **Philippa Fibert:** Methodology, Writing – review & editing, Supervision. **Maria Rottensteiner:** Methodology. **Walter Glück:** Methodology. **Peter Lechleitner:** Validation. **Menachem Oberbaum:** Validation, Writing – original draft, Supervision. **Ilse Leisser:** Resources. **Kavita Chandak:** Methodology, Writing – review & editing. **Peter Panhofer:** Investigation, Writing – original draft. **Petra**

**Weiermayer:** Conceptualization, Writing – original draft, Writing – review & editing, Supervision.

## Declaration of competing interest

The authors declare that they have no conflicts of interest.

## Acknowledgement

We thank DDR. Hedda Sützl-Klein, European Society for Integrative Health Research, for encouraging publication as well as for valuable discussion of the manuscript.

## References

- [1] Worldometer Covid-19 Info, Coronavirus update (live) [cited February 20, 2021], Available from: <https://www.worldometers.info/coronavirus/>.
- [2] Interactive web-based dashboard at the coronavirus Resource center at Johns Hopkins university [cited February 20, 2021], Available from: <https://coronavirus.jhu.edu/map.html>.
- [3] Gesundheitsministerium Austria, Amtliches dashboard (Ministry of health Austria. Official dashboard) COVID-19 [Internet]. [cited February 20, 2021], Available from: [https://info.gesundheitsministerium.at/dashboard\\_Epidem.html?l=de](https://info.gesundheitsministerium.at/dashboard_Epidem.html?l=de).
- [4] R.T. Mathie, S.M. Lloyd, L.A. Legg, J. Clausen, S. Moss, J.R. Davidson, et al., Randomised placebo-controlled trials of individualised homeopathic treatment: systematic review and meta-analysis, *Syst. Rev.* 3 (2014) 142, <https://doi.org/10.1186/2046-4053-3-142>.
- [5] P. Weiermayer, M. Frass, T. Peinbauer, L. Ellinger, Evidence-based homeopathy and veterinary homeopathy, and its potential to help overcome the anti-microbial resistance problem - an overview, *Schweiz. Arch. Tierheilkd.* 162 (2020) 597–615, <https://doi.org/10.17236/sat00273.2020>.
- [6] J. Jacobs, Homeopathic prevention and management of epidemic diseases, *Homeopathy* 107 (2018) 157–160, <https://doi.org/10.1055/s-0038-1649487>.
- [7] M. Frass, M. Linkesch, S. Banyai, G. Resch, C. Dielacher, T. Löbl, et al., Adjunctive homeopathic treatment in patients with severe sepsis: a randomized, double-blind, placebo-controlled trial in an intensive care unit, *Homeopathy* 94 (2005) 75–80, <https://doi.org/10.1016/j.homp.2005.01.002>.
- [8] S. Conde Diez, A. Viejo Casas, J.L. Garcia Rivero, J.C. Lopez Caro, F. Ortiz Portal, G. Diaz Saez, Impact of a homeopathic medication on upper respiratory tract infections in COPD patients: results of an observational, prospective study (EPOXIL), *Respir. Med.* 146 (2019) 96–105, <https://doi.org/10.1016/j.rmed.2018.11.011>.
- [9] P.S. Chakraborty, C.D. Lamba, D. Nayak, M.D. John, D.B. Sarkar, A. Poddar, et al., Effect of individualized homeopathic treatment in influenza like illness: a multicenter, single blind, randomized, placebo-controlled study, *IJRH* 7 (2013) 22–30.
- [10] S. Prajapati, M. Sharma, A. Kumar, P. Gupta, G.V. Narasimha Kumar, An update on novel COVID-19 pandemic: a battle between humans and virus, *Eur. Rev. Med. Pharmacol. Sci.* 24 (2020) 5819–5829, [https://doi.org/10.26355/eurrev\\_202005\\_21377](https://doi.org/10.26355/eurrev_202005_21377).
- [11] K.L.A. To, Y.Y.Y. Fok, Homeopathic clinical features of 18 patients in COVID-19 outbreaks in Hong Kong, *Homeopathy* 109 (2020) 146–162, <https://doi.org/10.1055/s-0040-1710545>. Epub 2020 Jun 5.
- [12] M. Oberbaum, Will we miss the opportunity again? *Homeopathy* 109 (2020) 176–178, <https://doi.org/10.1055/s-0040-1713082>. Epub 2020 Jun 5.
- [13] N. Basu, B.C. Das, S. Tandon, Interim management of COVID-19 by repurposed homeopathic medicines, *Homeopathy* 109 (2020) 182–183, <https://doi.org/10.1055/s-0040-1713004>. Epub 2020 Jun 9.
- [14] S. Hahnemann, *Organon of Medicine*, sixth ed., B. Jain Publishers Ltd., New Delhi, 1994.

- [15] M.Z. Teixeira, Clinical research protocol to evaluate the effectiveness and safety of individualized homeopathic medicine in the treatment and prevention of the COVID-19 epidemic, *Rev. Assoc. Med. Bras.* 66 (2020) 405–406, <https://doi.org/10.1590/1806-9282.66.4.405>.
- [16] E.G. Rossi, The experience of an Italian public homeopathy clinic during the COVID-19 epidemic, *March-May 2020, Homeopathy 109* (2020) 167–168, <https://doi.org/10.1055/s-0040-1713618>. Epub 2020 Jul 8.
- [17] B. Jethani, M. Gupta, P. Wadhvani, R. Thomas, T. Balakrishnan, G. Mathew, et al., Clinical characteristics and remedy profiles of patients with COVID-19: a retrospective cohort study, *Homeopathy* (2021 Feb 10), <https://doi.org/10.1055/s-0040-1718584> (Online ahead of print).
- [18] W. Boericke W, *Pocket Manual of Homoeopathic Materia Medica Comprising the Characteristic and Guiding Symptoms of All Remedies*, ninth ed., Boericke and Runyon, Boericke and Tafel, Inc., Philadelphia, PA, 1927.
- [19] A. Hofmann, Nosoden – status und Verfügbarkeit. (Nosodes - status and availability), *Allg. Homöopathische Ztg.* 259 (2014) 7–9.
- [20] *Homöopathisches Arzneibuch, Vorschriften 43 und 44. Deutscher Apotheker Verlag, Stuttgart, Deutschland (Homeopathic Pharmacopoeia 2019, Regulations 43 and 44, Deutscher Apotheker Verlag, Stuttgart, Germany, 2019.*
- [21] V.M. Corman, O. Landt, M. Kaiser, R. Molenkamp, A. Meijer, D.K. Chu, et al., Detection of 2019 novel coronavirus (2019-nCoV) by real-time RT-PCR, *Euro Surveill.* 25 (2020) 2000045, <https://doi.org/10.2807/1560-7917.ES.2020.25.3.2000045>.
- [22] C.D. Lamba, V.K. Gupta, R. van Haselen, L. Rutten, N. Mahajan, A.M. Molla, et al., Evaluation of the modified Naranjo criteria for assessing causal attribution of clinical outcome to homeopathic intervention as presented in Case reports, *Homeopathy 109* (2020) 191–197, <https://doi.org/10.1055/s-0040-1701251>. Epub 2020 Mar 25.
- [23] Directive 2001/83/EC of the European parliament and of the Council of 6 november 2001 on the community code relating to medicinal products for human use, Brüssel, Belgium, [https://www.ema.europa.eu/en/documents/regulatory-procedural-guideline/directive-2001/83/ec-european-parliament-council-6-november-2001-community-code-relating-medicinal-products-human-use\\_en.pdf](https://www.ema.europa.eu/en/documents/regulatory-procedural-guideline/directive-2001/83/ec-european-parliament-council-6-november-2001-community-code-relating-medicinal-products-human-use_en.pdf) (cited 2020 July 20).
- [24] S. Waisse, M. Oberbaum, M. Frass, The hydra-headed coronaviruses: implications of COVID-19 for homeopathy, *Homeopathy 109* (2020) 169–175, <https://doi.org/10.1055/s-0040-1714053>. Epub 2020 Jul 22. PMID: 32698230.
- [25] I. Ali, O.M.L. Alharbi, COVID-19: disease, management, treatment, and social impact, *Sci. Total Environ.* 728 (2020) 138861, <https://doi.org/10.1016/j.scitotenv.2020.138861>. Epub 2020 Apr 22.