

Isolated neurosarcoidosis mimicking multifocal meningiomas: a diagnosis pitfall

A case report

Kun Wang, MD^a, Xiaoying He, MB^b, Wei Wang, MB^c, Huanjiang Niu, MD^b, Yirong Wang, MM^b, Xiujun Cai, MD, PhD^d, Shuxu Yang, MD^b*

Abstract

Introduction: Neurosarcoidosis accounts for approximately 5% of the sarcoidosis, which develops exclusively in the nervous system and is always difficult to diagnose. We describe a rare case of isolated neurosarcoidosis mimicking as multifocal meningiomas. A 27-year-old male was admitted to our hospital with a history of unconsciousness and convulsion 1 month ago, which was suspected as a seizure. The results showed no abnormalities in complete blood count; serum electrolytes; erythrocyte sedimentation rate and ultrasonography of the liver, pancreas, spleen, kidney and parotid gland, and so on. Chest radiograph and electroencephalogram were also normal. Serum-angiotensin-converting enzyme slightly increased. Normal opening pressure was shown in cerebrospinal fluid sampling, which includes 8/μL white blood cells, 0.93 g/L protein, and 3.03 mmol/L glucose. Enhanced magnetic resonance imaging revealed multifocal enhancement lesions, including left sphenoid wing region, left temporal and bilateral occipitoparietal region, which were suspected as multiple “meningioma”. A left frontotemporal craniotomy was further performed. Both necrotizing and non-necrotizing granulomas were revealed in the pathological specimen, most of which were associated with multinucleated giant cells and macrophages. We could also see the fibrosis and inflammatory reaction in the sample composed of lymphocytes, histiocytes, and plasma cells. Histopathological examination showed that the cells were positive for human CD68 (KP1), CD68 (PGM1), and CD163; however, they were negative for the AF, epithelial membrane antigen, and glial fibrillary acidic protein. Tuberculosis-deoxyribonucleic acid test and special stains for acid-fast bacilli and fungi were negative. The diagnosis was finally made as isolated neurosarcoidosis. Then the patient was treated with additional corticosteroid therapy. Serial imaging examination 4 months later revealed that the lesions extremely decreased.

Conclusion: The diagnosis of isolated central nervous system sarcoidosis was still difficult because of limitations of available diagnostic tests. So neurosarcoidosis in the clinical work should never be neglected.

Abbreviations: ACE = angiotensin-converting enzyme, CSF = cerebrospinal fluid, EEG = electroencephalogram, GFAP = glial fibrillary acidic protein, MRI = magnetic resonance imaging.

Keywords: diagnosis, neurosarcoidosis, treatment

Editor: Yufang Ma.

Signed informed consent was obtained from the patient.

Funding/support: The work was supported by the National Natural Science Foundation of China (81402044) and the Natural Science Foundation of Zhejiang Province of China (LY14H160017).

The authors have no conflicts of interest to disclose.

^a Department of Neurosurgery, Hangzhou Xiasha Hospital, ^b Department of Neurosurgery, ^c Department of Pharmacy, Hangzhou Xiasha Hospital,

^d Department of General Surgery, Sir Run Run Shaw Hospital, Medical College, Zhejiang University, Hangzhou, People's Republic of China.

* Correspondence: Shuxu Yang, Department of Neurosurgery, Sir Run Run Shaw Hospital, Medical College, Zhejiang University, Hangzhou 310016, People's Republic of China (e-mail: Yang.sx@163.com); Co-correspondence: Xiujun Cai, Department of Neurosurgery, Sir Run Run Shaw Hospital, Medical College, Zhejiang University, Hangzhou 310016, People's Republic of China (e-mail: cxjzu@hotmail.com).

Copyright © 2016 the Author(s). Published by Wolters Kluwer Health, Inc. All rights reserved.

This is an open access article distributed under the terms of the Creative Commons Attribution-NonCommercial-ShareAlike 4.0 License, which allows others to remix, tweak, and build upon the work non-commercially, as long as the author is credited and the new creations are licensed under the identical terms.

Medicine (2016) 95:46(e4994)

Received: 21 April 2016 / Received in final form: 5 September 2016 / Accepted: 7 September 2016

<http://dx.doi.org/10.1097/MD.0000000000004994>

1. Introduction

Sarcoidosis is a multisystem granulomatous disorder of unknown etiology, usually diagnosed between 20 and 40 years of age.^[1] Neurosarcoidosis occurs in the central or peripheral nervous system and is usually associated with other sarcoidosis organ involvement. The prevalence of sarcoidosis is estimated at about 5 to 50 per 100,000, with the highest prevalence in northern Europe.^[2]

Neurosarcoidosis can mimic more common disease processes, such as meningioma, glioma, or metastases. Involvement of the nervous system is rare but can result in serious complications.^[3] Neurosarcoidosis is often suspected in patients with systemic sarcoidosis who develop neurological disorders.^[4] However, when sarcoidosis develops exclusively in the nervous system (isolated neurosarcoidosis), diagnosing neurosarcoidosis may be difficult because of the nonspecific clinical features.^[5] Furthermore, definite neurosarcoidosis requires histological confirmation, which is often not performed in patients with isolated central nervous system localization of sarcoidosis.

We present here an unusual case of isolated neurosarcoidosis manifesting as multiple meningiomas.

2. Clinical details

A 27-year-old male was admitted to our hospital with a history of unconsciousness and convulsion 1 month ago, which was

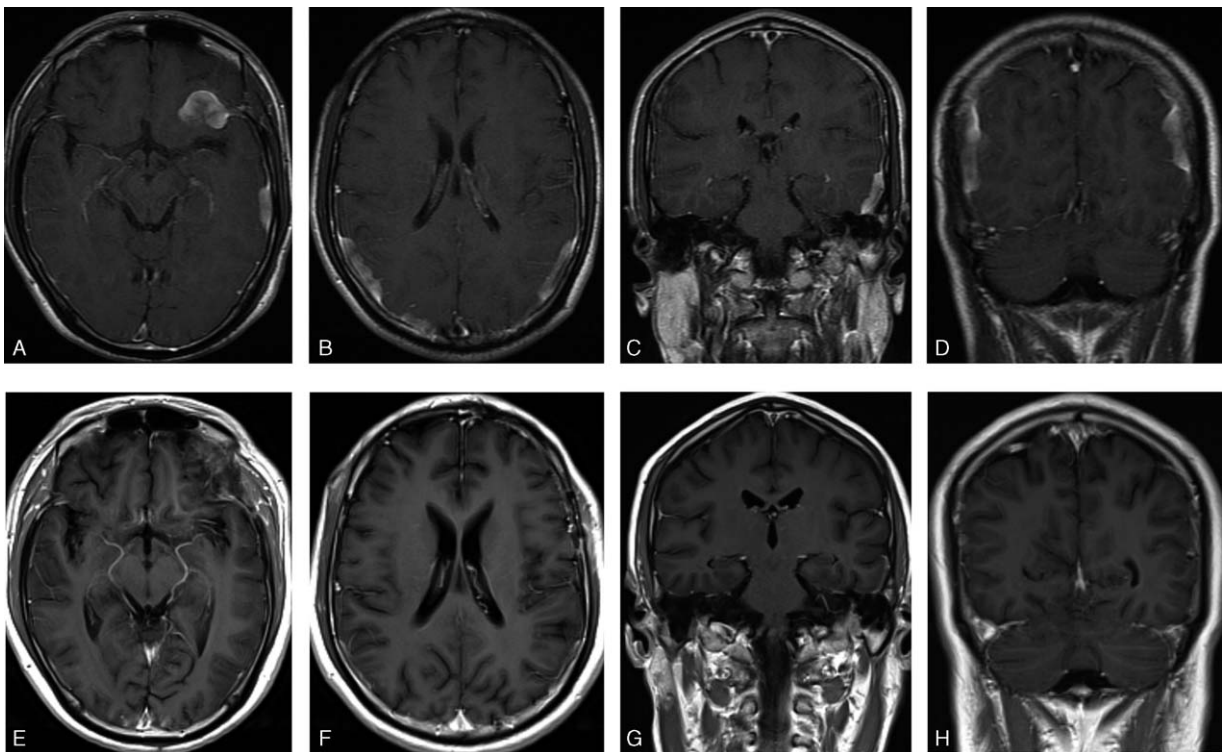


Figure 1. (A–D) Enhanced magnetic resonance imaging (MRI) revealed multifocal enhancement lesions, including left sphenoid wing region, left temporal and bilateral occipitoparietal region; (E–H) serial MRI 4 months later revealed extremely decreasing tumor size.

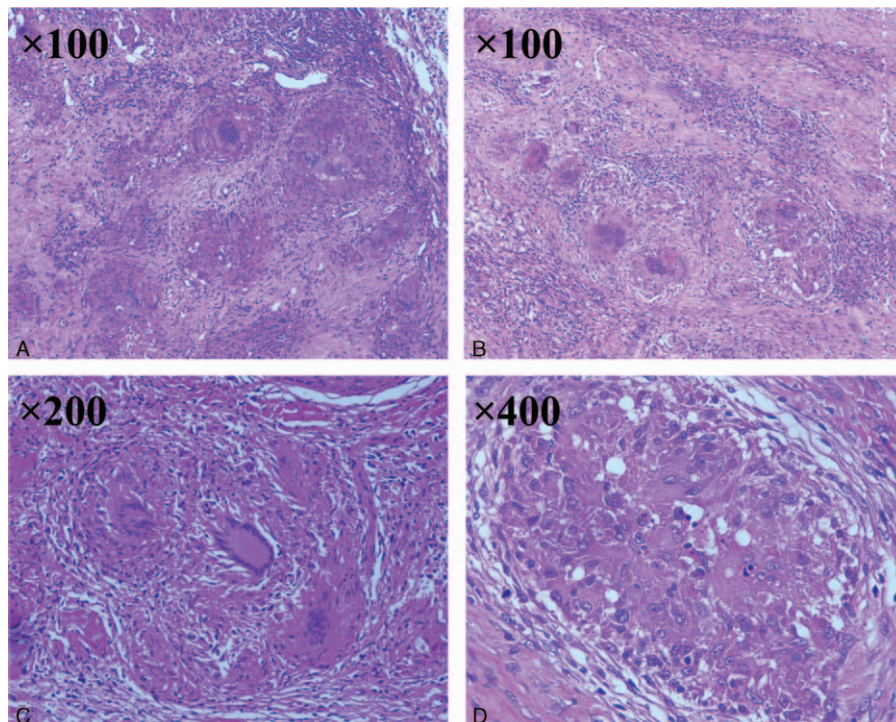


Figure 2. Histology of the pathological specimen reveals the presence of both necrotizing and non-necrotizing granulomas, many of which were associated with multinucleated giant cells and macrophages surrounded by fibrosis and an inflammatory reaction composed of lymphocytes, histiocytes, and plasma cells.

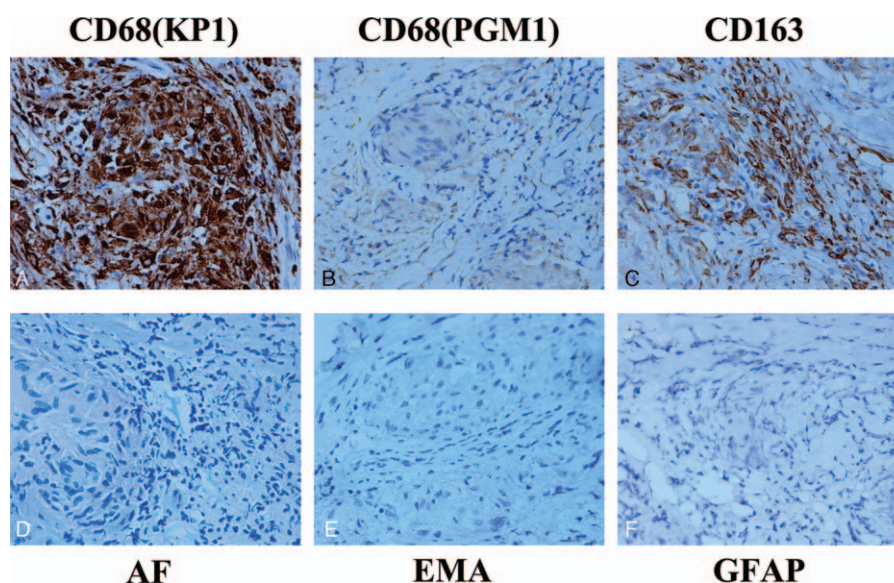


Figure 3. The cells were positive for human CD68 (KP1) (A), CD68 (PGM1) (B), and CD163 (C); however, they were negative for AF (D), epithelial membrane antigen (E), and glial fibrillary acidic protein (F).

suspected as a seizure. The seizure that lasted for 30 seconds was generalized and tonic clonic, followed by loss of consciousness for about 15 minutes. Physical examination was normal. The results showed no abnormalities in complete blood count, serum electrolytes, erythrocyte sedimentation rate, and ultrasonography of the liver, pancreas, spleen, kidney, and parotid gland, and so on. Chest radiograph and EEG (electroencephalogram) were also normal. Serum-ACE (angiotensin-converting enzyme) slightly increased (48 IU/L). Normal opening pressure was shown in CSF (cerebrospinal fluid) sampling, which includes 8/ μ L white blood cells, 0.93 g/L protein, and 3.03 mmol/L glucose. Enhanced MRI (magnetic resonance imaging) revealed multifocal enhancement lesions, including left sphenoid wing region, left temporal and bilateral occipitoparietal region, including the largest mass ($1.5 \times 1.5 \times 3 \text{ cm}^3$), which were isointense on T1-weighted images, hyperintense on T2-weighted images, and enhanced homogeneously, and were suspected as multiple “meningioma” (Fig. 1A–D). Then, we performed the left frontotemporal craniotomy. Both necrotizing and non-necrotizing granulomas (Fig. 2) were revealed in the pathological specimen, most of which were associated with multinucleated giant cells and macrophages (Fig. 2). We could also see the fibrosis and inflammatory reaction in the sample composed of lymphocytes, histiocytes, and plasma cells (Fig. 2). Histopathological examination showed that the cells were positive for human CD68 (KP1), CD68 (PGM1) (CD68 expresses in monocytes, macrophages, and epithelioid cells), and CD163 (a marker of sarcoidosis); however, they were negative for the AF, epithelial membrane antigen (marker of meningioma) and GFAP (glial fibrillary acidic protein, glial cells in the central nervous system contain GFAP) (Fig. 3). Tuberculosis-deoxyribonucleic acid test and special stains for acid-fast bacilli and fungi were negative. The diagnosis was finally made as isolated neurosarcoidosis. Then the patient was treated with long-term, high-dose corticosteroid (CS) therapy, and serial imaging examination 4 months later revealed that the lesions extremely decreased (Fig. 1E–H).

3. Discussion

Neurosarcoidosis is the neurologic manifestation of sarcoidosis, a granulomatous inflammatory disease, which although most often affects the lungs, can also affect the eyes, skin, liver, spleen, and nervous system.^[6] Nervous system involvement has been reported in 5% to 15% of patients and can involve any part of the nervous system, ranging from brain parenchyma, cranial nerves, to peripheral nerves.^[7–9]

Neurologic symptoms were reported to be the first clinical manifestation of neurosarcoidosis in more than half of the cases.^[10] The previous study has shown that limb sensory disturbance and other symptoms involving the peripheral nervous system were the major clinical presentation.^[5,10–13] Diagnostic evaluation of patients with suspected neurosarcoidosis usually includes imaging examination, laboratory tests, and histopathologic identification. Multiple white matter lesions followed by meningeal enhancement is always found in the MRI of the neurosarcoidosis patient. Gallium scintigraphy is reported by Marangoni et al^[14] for the use of diagnosis of probable sarcoidosis owing to high sensitivity of the test. A recent study suggests that fluorodeoxyglucose-positron emission tomography computed tomography could be applied as a valid alternative imaging test, for it leads to better uptake in central nervous system sites.^[15] The usefulness of CSF ACE levels for the diagnosis of neurosarcoidosis is controversial. CSF abnormalities in neurosarcoidosis are usually nonspecific and can also be found in multiple sclerosis, Guillain–Barre syndrome, Behcet disease, brain tumors, and neurodegenerative diseases.^[16] When no extraneural organ is identified as possibly being involved with sarcoidosis, biopsy of the lesion in CNS is needed for the last diagnosis.

CS therapy remains first-line treatment for neurosarcoidosis with second-line therapy being other immunosuppressive agents, such as azathioprine and methotrexate.^[2] For severe manifestations, steroids are started at 1 mg/kg or as a pulse of methylprednisolone 1000 mg/d for 3 days, followed by taper-

ing.^[17] Neurosurgery is only advised when medications fail or intracranial pressure is extremely high, which threaten life.

In our patient, enhanced MRI revealed multifocal enhancement lesions, including left sphenoid wing region, left temporal and bilateral occipitoparietal region, giving the appearance of multiple “meningioma”. Our patient’s serum ACE level slightly increased before the surgery and did not vary significantly postoperatively. Surgery was performed with a preoperative diagnosis of “meningioma”. The final diagnosis is made by the histopathological specimens which showed necrotizing, non-necrotizing granulomas, multinucleated giant cells, and macrophages. Long-term and high-dose CS therapy was instituted.

In conclusion, the diagnosis and management of neurosarcoidosis remain difficult because of limitations of available diagnostic tests. So, it is important to keep neurosarcoidosis in mind, both preoperatively and intraoperatively, which leads to the appropriate treatment. There is a need in the future for a multicenter prospective study in order to develop diagnostic and therapeutic standards of neurosarcoidosis.

References

- [1] Joseph FG, Scolding NJ. Neurosarcoidosis: a study of 30 new cases. *J Neurol Neurosurg Psychiatry* 2009;80:297–304.
- [2] Hoitsma E, Faber CG, Drent M, et al. Neurosarcoidosis: a clinical dilemma. *Lancet Neurol* 2004;3:397–407.
- [3] Terushkin V, Stern BJ, Judson MA, et al. Neurosarcoidosis: presentations and management. *Neurologist* 2010;16:2–15.
- [4] Stern BJ, Krumholz A, Johns C, et al. Sarcoidosis and its neurological manifestations. *Arch Neurol* 1985;42:909–17.
- [5] Leonhard SE, Fritz D, Eftimov F, et al. Neurosarcoidosis in a tertiary referral center: a cross-sectional cohort study. *Medicine (Baltimore)* 2016;95:e3277.
- [6] Ahn SW, Kim KT, Youn YC, et al. Isolated spinal cord neurosarcoidosis diagnosed by cord biopsy and thalidomide trial. *J Korean Med Sci* 2011;26:154–7.
- [7] James DG, Sharma OP. Neurosarcoidosis. *Proc R Soc Med* 1967;60:1169–70.
- [8] Hoitsma E, Drent M, Sharma OP. A pragmatic approach to diagnosing and treating neurosarcoidosis in the 21st century. *Curr Opin Pulm Med* 2010;16:472–9.
- [9] Chapelon C, Ziza JM, Piette JC, et al. Neurosarcoidosis: signs, course and treatment in 35 confirmed cases. *Medicine (Baltimore)* 1990;69:261–76.
- [10] Allen RK, Sellars RE, Sandstrom PA. A prospective study of 32 patients with neurosarcoidosis. *Sarcoidosis Vasc Diffuse Lung Dis* 2003;20:118–25.
- [11] Wegener S, Linnebank M, Martin R, et al. Clinically isolated neurosarcoidosis: a recommended diagnostic path. *Eur Neurol* 2015;73:71–7.
- [12] Nozaki K, Scott TF, Sohn M, et al. Isolated neurosarcoidosis: case series in 2 sarcoidosis centers. *Neurologist* 2012;18:373–7.
- [13] Pawate S, Moses H, Sriram S. Presentations and outcomes of neurosarcoidosis: a study of 54 cases. *QJM* 2009;102:449–60.
- [14] Marangoni S, Argentiero V, Tavolato B. Neurosarcoidosis. Clinical description of 7 cases with a proposal for a new diagnostic strategy. *J Neurol* 2006;253:488–95.
- [15] Nishiyama Y, Yamamoto Y, Fukunaga K, et al. Comparative evaluation of 18F-FDG PET and 67Ga scintigraphy in patients with sarcoidosis. *J Nucl Med* 2006;47:1571–6.
- [16] Sharma OP. Neurosarcoidosis: a personal perspective based on the study of 37 patients. *Chest* 1997;112:220–8.
- [17] Dutra LA1, Braga-Neto P, Oliveira RA, et al. Neurosarcoidosis: guidance for the general neurologist. *Arq Neuropsiquiatr* 2012;70:293–9.