



Ulcerative Colitis Following Orthotopic Cardiac Transplantation

Anahita Sadeghi¹, Pouya Bastani², Mehdi Mohamadnejad^{3,*}

1. Digestive Disease Research Center, Digestive Disease Research Institute, Tehran University of Medical Sciences, Tehran, Iran
2. Department of Internal Medicine, Shariati Hospital, Tehran University of Medical Sciences, Tehran, Iran
3. Liver and Pancreatobiliary Research Center, Digestive Disease Research Institute, Tehran University of Medical Sciences, Tehran, Iran

ABSTRACT

Inflammatory bowel disease following a solid organ transplantation while the patient is receiving immunosuppressive therapy is a rare phenomenon. Here we present a 48-year-old man who underwent cardiac transplantation 9 years earlier and was receiving cyclosporine as immunosuppressive therapy since then, presenting with complaints of rectorrhagia and diarrhea. In follow-up, he was diagnosed as having ulcerative colitis. We also reviewed the literature for similar cases, which yielded very few similar ones.

KEYWORDS:

Pancreas; Tuberculosis; Biopsy; Fine-Needle; Endosonography

Please cite this paper as:

Sadeghi A, Bastani P, Mohamadnejad M. Ulcerative Colitis Following Orthotopic Cardiac Transplantation. *Middle East J Dig Dis* 2017;9:235-238. doi: 10.15171/mejdd.2017.79.

INTRODUCTION

Inflammatory bowel disease (IBD), consists of two relatively different diseases, ulcerative colitis (UC) and Crohn's disease (CD) both of which have an underlying immune dysregulation. Recent studies unveil the role of specific components of cell-mediated immunity such as Th-17 in the pathogenesis of IBD regarding their role in preserving the integrity of intestinal barrier.¹ Cyclosporine is an immunosuppressive agent used in a range of medical conditions notably for immunosuppressive therapy after solid organ transplantation. Whether or not cyclosporine in combination with mycophenolate mofetil (MMF) is the best combination for the patients after cardiac transplantation has been questioned in some literature suggesting the benefits of tacrolimus plus MMF over the former combination.² Cyclosporine acts by inhibiting calcineurin, a phosphatase enzyme, which is needed for proliferation and activation of T-cells.³ Thus it would be safe to presume patients receiving cyclosporine would demonstrate lower T-cell activity. As mentioned earlier T-cells play central role in the pathogenesis of IBD, therefore for a patient receiving a combination of T-cell inhibiting agents to present with IBD would be a remote consideration.

CASE REPORT

A 48-year-old man with a history of heart transplantation 9 years earlier due to dilated cardiomyopathy was admitted with the chief complaint of chronic diarrhea with episodes of rectal bleeding for the past 3 months. He also complained of nocturnal symptoms of diarrhea and loose bloody stool. His medical history revealed a cataract surgery

* Corresponding Author:

Mehdi Mohamadnejad, MD
Liver and Pancreatobiliary Center,
Digestive Disease Research Institute,
Tehran University of Medical Sciences,
Tehran, Iran.
Telefax: + 98 21 82415104
Email: mehdi.nejad@gmail.com

Received: 29 May 2017
Accepted: 30 Aug. 2017

Table 1: Initial lab evaluation

Test	Result	Unit	Reference value
WBC	6420	1/mm ³	4000 - 10,000
PMN	66	Percent	40 - 80
Lymphocytes	24	Percent	20 - 40
Monocytes	7	Percent	2 - 10
Eosinophils	3	Percent	1 - 6
RBC	3.85	Million/mm ³	4.4 - 6.1
Hb	11.3	g/dl	14 - 18
Hct	34	Percent	42 - 52
MCV	88.3	Femtoliter	80 - 100
MCH	29.4	Picogram	26 - 34
MCHC	33.2	Percent	31 - 36
Platelets	145,000	1/mm ³	150,000 - 450,000
RDW	12.6	Percent	11.5 - 14.5
Cyclosporine	247.1	ng/ml	100 - 300
Urine culture	No growth		
Stool culture	No salmonella and shigella isolated		

PMN: polymorphonuclear leukocytes, Hg: hemoglobin, HCT: hematocrit, MCH: mean corpuscular hemoglobin
MCHC: mean corpuscular hemoglobin concentration RDW: Red Cell Distribution Width

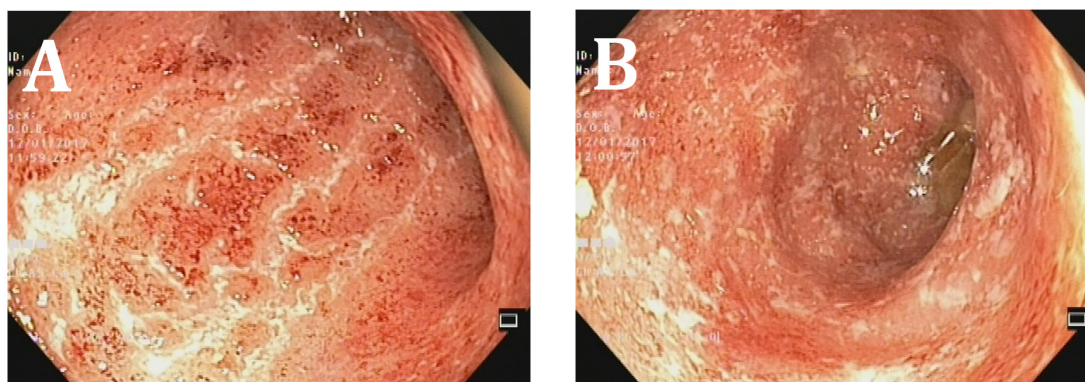


Fig.1: Colonoscopic evaluation of the rectum (A) and sigmoid colon (B) revealing edema, erythema, mucosal friability and loss of vascular pattern.

of the left eye, 15 years ago. He had been taking cyclosporine, initially 100 mg daily and titrated with measuring cyclosporine level, MMF 1000 mg twice a day, and prednisolone 5 mg daily since his transplantation. His other medications included: diltiazem, Inderal® (propranolol), valsartan, and atorvastatin. Initial lab data of the patient is summarized in table 1 revealing a normochromic normocytic anemia and otherwise normal results. An ileocolonoscopy was performed. Although the bowel preparation was suboptimal, the visual field was improved with frequent washing and suction,

thus providing adequate quality for the procedure. The colonoscopic examination revealed edema, erythema, mucosal friability, erosions, and superficial ulcerations in rectum and sigmoid (figure 1). The descending colon, splenic flexure, transverse colon, ascending colon, cecum, and 10 cm of terminal ileum were all visualized with normal appearing mucosa. Several biopsy samples were taken by using biopsy forceps from the mucosa of the rectum, sigmoid colon, ascending colon, cecum, and terminal ileum and sent for pathological examination in separate containers. The pathological features of the

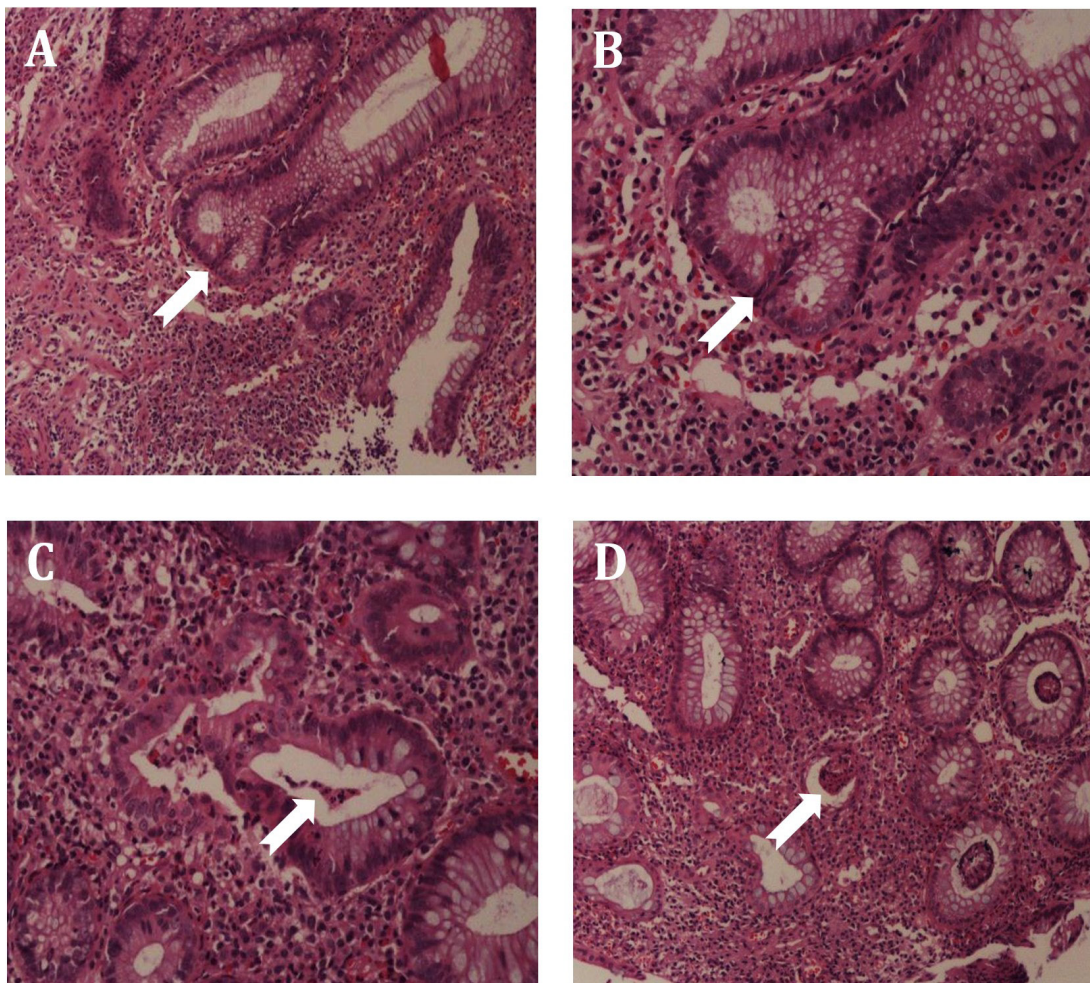


Fig.2: Sections from colonic mucosa reveal irregular sized glandular structure with branching (white arrows in figures A, and B). Lamina propria is infiltrated by acute and chronic inflammatory cells with invasion into glandular structures (crypt abscess formation as shown by white arrows in figures C, and D).

specimens including branching, loss of glandular architecture, and crypt abscess (figure 2) along with a negative test result for immunohistochemical (IHC) examination for CMV, confirmed the diagnosis of ulcerative colitis. The patient was given mesalamine suppository, mesalamine enema, sulfasalazine, and folic acid. He responded well to the medications.

DISCUSSION

Our literature review revealed that based on studies, de novo IBD has a higher frequency in organ recipients and a more aggressive course among the mentioned population.⁴ Some other cases of UC flare after solid organ transplantation were noted. In one report a 53-year-old patient developed UC following heart transplantation de-

spite receiving cyclosporine and prednisone. Surprisingly his disease deteriorated on prednisolone, advancing from a distal colitis to a pancolitis resulting in total colectomy, which was finally controlled.⁵

There was also a patient with renal transplantation who was receiving azathioprine and prednisone. He had discontinued cyclosporine due to financial constraints and developed diarrhea, which was firstly believed to be due to immunosuppressive medication but later it was found to be a result of UC.⁶ In a number of patients who received orthotropic liver transplantation specially those who received transplant due to primary sclerosing cholangitis (PSC), UC was observed to be more common and more severe than other cases. This article also showed that the prevalence of UC occurring after a solid

organ transplantation is the highest in the case of liver transplantation.⁷ A recent yet to be published case report, presented a patient with CD following cardiac transplantation who was receiving MMF. Similarly it was a remote diagnosis on the presentation considering more common causes of colitis in a patient after transplantation. It is also noted a dramatic response to treatment with anti TNF-alpha agent, infliximab, which could be promising data though some further studies are needed to confirm the efficacy and safety of infliximab in this group of patients as they pose a more complex course of disease and pathogenesis and require a multidisciplinary approach.^{4,8} There are also some studies, suggesting prophylactic colectomy as prevention for colorectal cancers (CRC) in selected patients with IBD/PSC who developed their disease after solid organ transplantation and pose a higher risk of CRC development.⁴ The case we presented along with some other cases that we reviewed, all yield a new aspect to how a disease with an immune system background can be developed during immunosuppressive therapy. These data on UC along with the development of CD in immunosuppressed patients after transplantation⁹ guide us to a different approach to evaluate the pathogenesis and possible etiologies. As these patients require a more complex approach to diagnosis and treatment, further studies are needed to confirm the efficacy of some novel treatments and present a clear approach to post-transplant patients with IBD.

CONFLICT OF INTEREST

The authors declare no conflict of interest related to this work.

REFERENCES

1. Da Silva BC, Lyra AC, Rocha R, Santana GO. Epidemiology, demographic characteristics and prognostic predictors of ulcerative colitis. *World J Gastroenterol* 2014;**20**:9458-67. doi: 10.3748/wjg.v20.i28.9458.
2. Guethoff S, Meiser BM, Groetzner J, Eifert S, Grinninger C, Ueberfuhr P, et al. Ten-Year Results of a Randomized Trial Comparing Tacrolimus Versus Cyclosporine A in Combination With Mycophenolate Mofetil After Heart Transplantation. *Transplantation* 2013;**95**:629-34. doi: 10.1097/TP.0b013e318277e378.
3. Matsuda S, Koyasu S. Mechanisms of action of cyclosporine. *Immunopharmacology* 2000;**47**:119-25. doi:10.1016/S0162-3109(00)00192-2.
4. Indriolo A, Ravelli P. Clinical management of inflammatory bowel disease in the organ recipient. *World J Gastroenterol* 2014;**20**:3525-33. doi: 10.3748/wjg.v20.i13.3525.
5. Jüngling B, Kindermann I, Moser C, Püschel W, Ecker KW, Schäfers HJ, et al. Development of Ulcerative Colitis after Heart Transplantation During Immunosuppressive Therapy. *Z Gastroenterol* 2005;**43**:195-9. doi: 10.1055/s-2004-813743.
6. Parameswaran S, Singh K, Nada R, Rathi M, Kohli H, Jha V, et al. Ulcerative colitis after renal transplantation: A case report and review of literature. *Indian J Nephrol* 2011;**21**:120-2. doi: 10.4103/0971-4065.78063.
7. Wörns MA, Lohse AW, Neurath MF, Croxford A, Otto G, Kreft A, et al. Five Cases of De Novo Inflammatory Bowel Disease After Orthotopic Liver Transplantation. *Am J Gastroenterol* 2006;**101**:1931-7. doi:10.1111/j.1572-0241.2006.00624.x.
8. Noel G, Diamond B, Auerbach S, Zoeten ED, Hofenberg E. Colonic Crohn's Disease after Cardiac Transplantation: Case Report and Literature Review. *J Pediatr Gastroenterol Nutr* 2017;**65**:e45-e46. doi: 10.1097/MPG.0000000000001069.
9. Halim MA, Said T, Nair P, Schmidt I, Hassan A, Johnny KV, et al. De Novo Crohn's Disease in a Renal Transplant Recipient. *Transplant Proc* 2007;**39**:1278-9. doi:10.1016/j.transproceed.2007.03.045.