

Techniques for management and avoidance of ventriculoatrial shunt disconnection: illustrative cases

*Thomas M. Zervos, MD,¹ Kenneth Kutschman, BS,² Tiberio Frisoli, MD,³ Tarek R. Mansour, MD,¹ and Jason M. Schwalb, MD¹

Departments of ¹Neurosurgery and ³Cardiology, Henry Ford Hospital, Detroit, Michigan; and ²Wayne State University School of Medicine, Detroit, Michigan

BACKGROUND Ventriculoatrial (VA) shunt disconnection can result in distal catheter migration into the cardiopulmonary vasculature. There is little guidance in the current literature on how to prevent and manage this uncommon yet potentially serious complication. The authors reviewed the existing literature and described three instances of distal shunt migration VA shunts and offered insight on methods to mitigate such complications.

OBSERVATIONS Eighteen patients were identified with VA shunts. Of these patients, seven were identified as having a connector in the neck, three of which were associated with distal disconnection and migration. In all three cases, the distal catheter was retrieved via an endovascular approach in conjunction with transesophageal echocardiography to assess for retrieval feasibility.

LESSONS The authors recommended the avoidance of a straight connector when performing VA shunt placement. When distal catheter migration occurs, collaboration with interventional cardiology is advisable when possible.

<https://thejns.org/doi/abs/10.3171/CASE21654>

KEYWORDS case series; hydrocephalus; interventional cardiology; ventriculoatrial shunt disconnection

Minimizing the risk of distal ventriculoatrial (VA) shunt disconnection is particularly important due to the risk of catheter embolization. This rare event occurs in approximately 1.56% of implanted VA shunts.¹ There are no clear treatment guidelines in the literature to help prevent and manage this complication.

The use of a connector in the neck has been implicated in mechanical failures of ventriculoperitoneal shunts.² Although it is reasonable to consider exposure to motion a risk factor for disconnection, to the best of our knowledge, no literature has described disconnection and migration of distal VA shunt catheters due to use of a connector in the neck. We describe a series of three patients in whom use of a distal connector resulted in shearing and subsequent migration of distal tubing into the cardiopulmonary vasculature. We review the pertinent literature and discuss the management of this complication. We hypothesize that over time the combination of downward tension and shearing forces against

the rigid connector due to neck motion compromise the catheter; thus, connector-less techniques should be used.

Illustrative Cases

Case 1

A 72-year-old woman with a history of idiopathic normal pressure hydrocephalus (NPH) presented 7 years after VA shunt placement with recurrence of prior symptoms. Radiographs revealed disconnection of the distal catheter at the level of the cervical connector. Computed tomography (CT) images of the chest demonstrated the dislodged catheter projecting from the azygos vein through the superior vena cava into the right atrium (Fig. 1).

She was evaluated by interventional cardiology and received successful retrieval of the detached catheter using an Ensnare endovascular snare system (Merit Medical, Jordan, UT) introduced through the right femoral vein via a renal double curve guide catheter (Video 1).

ABBREVIATIONS CT = computed tomography; ICE = intracardiac echocardiography; IVC = inferior vena cava; NPH = normal pressure hydrocephalus; TEE = transesophageal echocardiogram; VA = ventriculoatrial.

INCLUDE WHEN CITING Published May 30, 2022; DOI: 10.3171/CASE21654.

SUBMITTED November 17, 2021. **ACCEPTED** February 18, 2022.

* T.M.Z. and K.K. contributed equally to this work.

© 2022 The authors, CC BY-NC-ND 4.0 (<http://creativecommons.org/licenses/by-nc-nd/4.0/>).

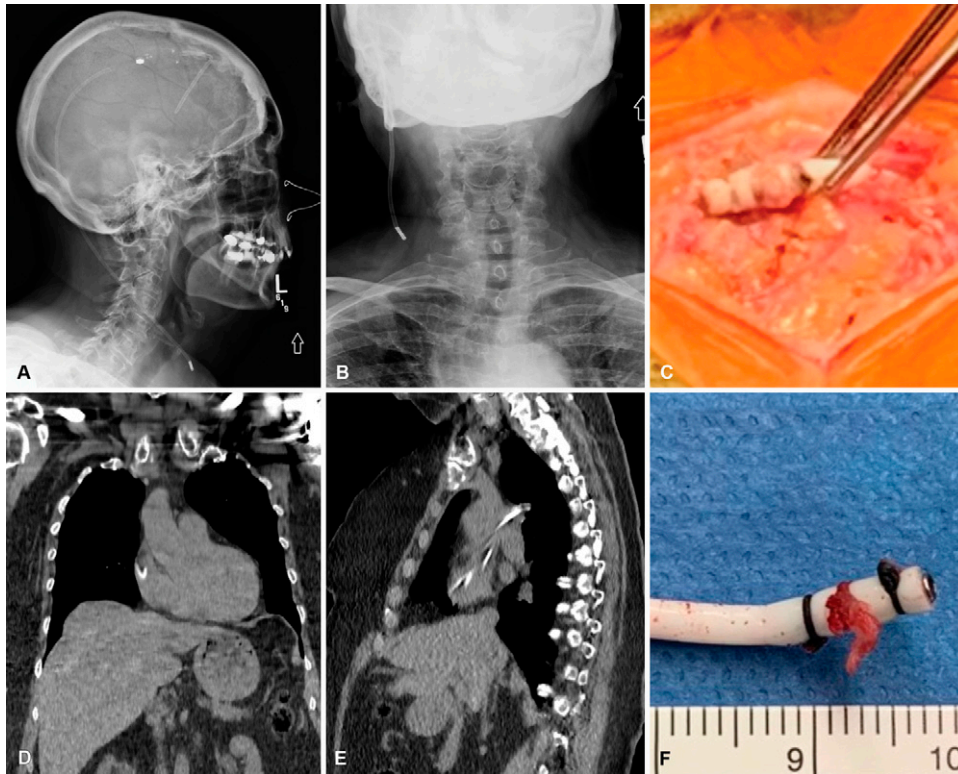


FIG. 1. Case 1. Shunt disconnection radiographs with intraoperative images. **A and B:** Disconnection and migration of the catheter distal to the connector. **C:** Intraoperative correlation with preoperative radiographs. **D and E:** CT of the chest showing the detached shunt tubing segment projecting from the azygos vein through the superior vena cava into the right atrium. **F:** Explanted proximal tubing demonstrating shearing of the distal tubing due to hardware failure.

VIDEO 1. Clip showing endovascular retrieval of distal tubing. In this fluoroscopic video, corresponding with the patient described in Case 1, an endovascular snare system (Merit Medical, Jordan, UT) introduced through the right femoral vein was used to extract the distal catheter from the right atrium uneventfully. [Click here to view.](#)

She subsequently received VA shunt revision. Intraoperatively, it was found that ~2 mm portion of the distal catheter remained tied to the connector but was sheared distally at the level of the connector edge (Fig. 1). During this revision, a connector-less technique was implemented: after a transverse incision was made in the neck, the intravascular portion of the catheter was placed into the internal jugular vein via the Seldinger technique. Fluoroscopy was used to make sure that the tip was within the right atrium. The proximal end of the catheter was then tunneled and connected directly to the valve.

Case 2

A 79-year-old man with a history of NPH presented 4 years after VA shunt placement with recurrence of his prior symptoms. Shunt series revealed a distal catheter disconnection at the level of the straight connector in the neck with migration into the right atrium (Fig. 2).

A transesophageal echocardiogram (TEE) demonstrated that the distal catheter was free-floating in the right atrium. The patient subsequently had successful retrieval of a 20-cm distal catheter via a 6-Fr Ensnare delivered through its own delivery catheter; no

intraprocedural cardiac imaging (TEE or intracardiac echocardiography [ICE]) was used for retrieval.

To avoid further risk of vascular migration, revision to a pleural terminus was performed. Similar to case 1, a small portion of catheter remained tied to the connector, with shearing occurring at the edge of the rigid connector.

Case 3

A 32-year-old woman with a history of communicating hydrocephalus from a prior gunshot wound presented several years after VA shunt placement with progressive headaches. Cardiac CT demonstrated a fractured distal catheter looped within the right atrium (Fig. 3). Considering the subacute nature of her symptoms, it was suspected that she was no longer shunt dependent.

She had retrieval of the distal catheter with interventional cardiology. Because it was unknown how long the distal catheter had been residing in the right atrium and to better visualize any thrombus that may have resided on and embolized from the catheter, retrieval was performed with TEE. A 7-Fr MPA1 guide catheter was advanced over a standard J wire into the right atrium across a prior inferior vena cava (IVC) filter. The retained VA catheter was engaged with a cardiac Ensnare device and removed. After retrieval, an independently mobile, filamentous structure was seen at the level of the Eustachian valve in proximity to where the catheter had resided. This was believed to represent fibrin cast or thrombus; therefore, the patient was anticoagulated

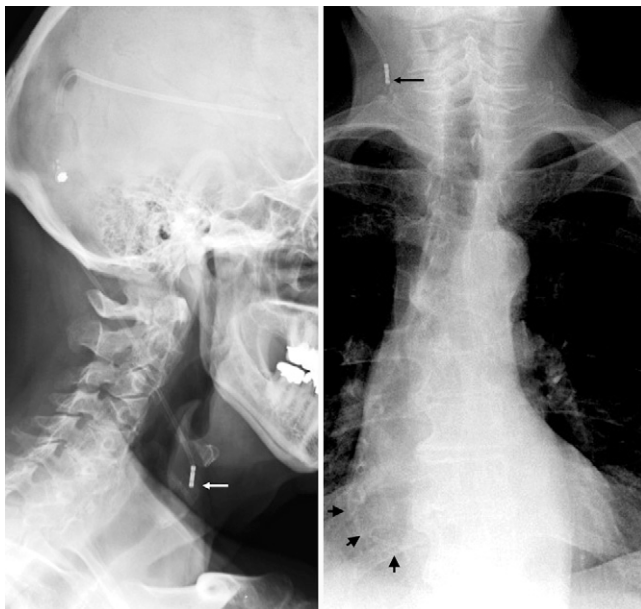


FIG. 2. Case 2. Shunt disconnection with distal catheter in the right atrium. **A:** Lateral radiograph demonstrating a disconnection at the level of the straight connector (*white arrow*). **B:** Chest radiograph demonstrating disconnection proximally (*long arrow*) and distal catheter within the right atrium (*short arrows*).

for 3 months thereafter. The IVC filter did not render endovascular catheter snaring and retrieval more challenging.

With the lack of progressive neurological symptoms but persistent headaches, it was suspected that the patient was no longer shunt dependent. An ICP monitor was placed, and she was monitored without elevation in ICP. Therefore, her shunt was not replaced.

Methods

This retrospective single-center case series was carried out for patients who received VA shunt placement at our institution between 2010 and 2021. Medical records and imaging studies were reviewed. Using the SlicerDicer function of Epic, charts from 3,237,852 patients within our health system were queried for a diagnosis related to the presence or history of a VA shunt. This resulted in 54 patients matching the search criteria. Of these patients, data were available for 18 patients regarding the approximate date of implantation, use of a connector, level of the connector, and revision history (Table 1).

PubMed was queried using the following search term: [(connector) (VA or ventriculoperitoneal)]. These search parameters resulted in 20 peer-reviewed publications. References were reviewed and three additional articles were included. This case series has been reported in line with the PROCESS guideline.³

Discussion

Given the potentially serious consequences of distal VA shunt catheter migration, it is important to identify risk factors that may increase the incidence of such an outcome. One of the issues that can lead to distal catheter disconnection from a straight connector is repeated cervical motion.⁴ The downward and shearing forces create mechanical stress that, over time, lead to degradation in the structural integrity of the shunt.⁵ Angular forces applied at the

proximal end of the shunt create a significant amount of tension that is communicated to the straight connector.

Of the publications included in our literature search, one discusses disconnection secondary to use of a straight connector in a ventriculoperitoneal shunt,² and no articles mention disconnection secondary to the use of a straight connector in a VA shunt.

Migration of the distal catheter into the heart can lead to serious complications such as pulmonary artery obstruction/insufficiency or cardiac tamponade.^{6–9} The general mechanism thought to surround the development of distal migration into cardiac structures is that the negative pressures produced by the right atrium encourage further migration of the shunt. Once disconnected, there is no opposing force to the negative pressures created and migration occurs.

Another potential complication of VA shunting is adherence of the catheter to intracardiac structures,^{7,8,10} which can act as a nidus for thrombus formation. Because patients do not always develop symptoms of hydrocephalus quickly after shunt malfunction, it is sometimes unclear how long ago the disconnection and migration occurred. In such cases, the question of whether a potentially adherent catheter should be abandoned must be considered. The risk of leaving the catheter, which results in the patient requiring lifelong anticoagulation, should be weighed against the risk of dislodging a thrombus associated with the catheter. In our cardiac endovascular experience, the risk of cardiac perforation during this procedure was believed to be negligible. In our anecdotal experience, unrelated procedures requiring high-force aspiration of chronic mural thrombi in thin-walled atria can be safely performed, which would theoretically have a higher risk of perforation. Safe retrieval involves appropriate preoperative imaging and consultation with interventional cardiology.

We describe three cases of distal catheter shearing and subsequent distal migration, presumably due to repetitive mechanical forces. When endovascular retrieval is not possible or available, open surgical approaches have been described for cases in which obstructive symptomatology occurs.⁸ However, with the use of rapidly evolving interventional cardiology techniques, the retrieval of distal migrated catheters can often be performed with minimal morbidity and favorable benefit versus potential harm caused by leaving the catheter in place.

Additional technical pearls for the endovascular procedure can be considered regarding sedation, adjunctive imaging, and venous access. When there is concern regarding associated thrombus or other cardiac pathology such as valvular disease, TEE may be indicated; however, it requires general anesthesia. Retrieval can be more conveniently performed with conscious sedation and the use of ICE or fluoroscopic imaging alone. Another consideration is that while our cases were performed via the femoral vein, retrieval could also be done via the jugular vein if needed.

Observations

In this series, image-guided, percutaneous placement of the atrial catheter using a peel-away sheath was performed as previously described.^{11,12} The use of intraoperative ultrasonography for vessel cannulation and confirmatory fluoroscopy improves accuracy, thereby decreasing the incidence of shunt failure.¹² By tunneling the distal catheter up to the valve, the use of a connector can be avoided altogether. In our experience, the use of a connector at or below the level of the clavicle or above the skull base is best to reduce exposure to motion. As a result of these complications, we have transitioned to complete avoidance of straight connectors in any tubing beyond the valve connection.

TABLE 1. Patients with VA shunt

Catheter Status	Venous Access	Connector Location	Years w/o Disconnection
Disconnection	IJ	Neck, C6 vertebral body level	3
	IJ	Neck, C5 vertebral body level	5
	IJ	Neck, C6 vertebral body level	7
No disconnection	IJ	Neck, C4 vertebral body level	>10
	IJ	Neck, C6 vertebral body level	>10
	IJ	Neck, C6 vertebral body level	>10
	IJ	Neck, C6 vertebral body level	>7
	IJ	None	>10
	Subclavian	Posterior neck & clavicle	>1
	Subclavian	Clavicle	>2
	Subclavian	Clavicle	>5
	Subclavian	Clavicle	>10
	Subclavian	Clavicle	>10
	Subclavian	Clavicle	>10
	Subclavian	Clavicle	>10

IJ = internal jugular.

Eighteen patients with VA shunts were identified at our institution. Seven of these patients were identified as having a connector in the neck, three patients experienced shunt disconnection, eight patients had the distal catheter introduced via the internal jugular vein, and 10 had the catheter introduced via the subclavian vein. The use of a connector at the level of the clavicle for introduction of the distal catheter into the subclavian vein was not associated with disconnection.

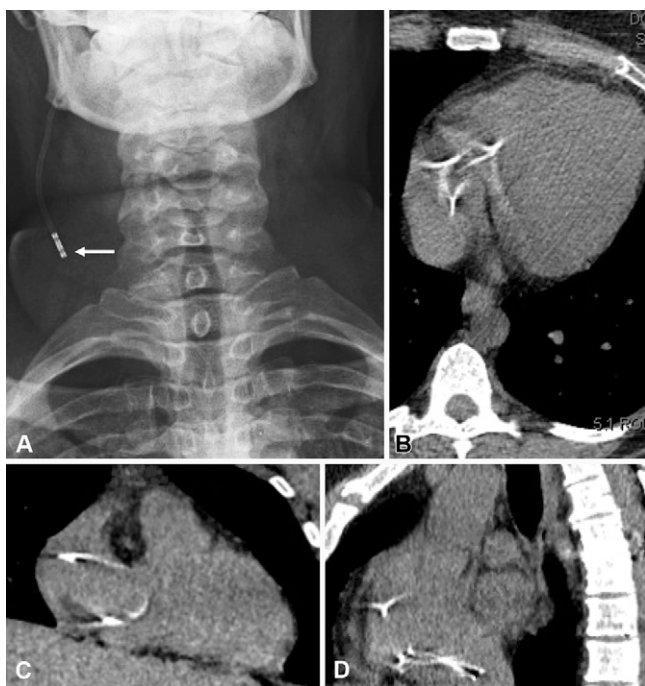

FIG. 3. Case 3. Shunt disconnection with distal catheter in right atrium. **A:** Radiograph demonstrating a disconnection of the distal tubing in the neck at the level of the connector (*white arrow*). **B–D:** Axial, coronal, and sagittal CTs of the chest demonstrating coiling of the distal catheter within the right atrium.

Lessons

Retrieval after disconnection and intravascular migration of a distal catheter in a VA shunt can often be achieved safely with the assistance of interventional cardiology. In certain instances, it may also be appropriate to abandon the distal catheter and retunnel to an alternative shunt terminus, such as the pleura. Ultimately, the best clinical strategy is that of connector avoidance to prevent this unfortunate complication up front.

Acknowledgments

We thank Susan MacPhee for editorial review and Ellen Air, MD, PhD, for her manuscript review.

References

1. Akhtar N, Khan AA, Yousaf M. Experience and outcome of ventricular-atrial shunt: a multi centre study. *J Ayub Med Coll Abbottabad*. 2015;27(4):817–820.
2. Lo WB, Ramirez R, Rodrigues D, Solanki GA. Ventriculoperitoneal shunt disconnection associated with spontaneous knot formation in the peritoneal catheter. *BMJ Case Rep*. 2013;2013.
3. Agha RA, Sohrabi C, Mathew G, Franchi T, Kerwan A, O'Neill N. The PROCESS 2020 guideline: updating consensus preferred reporting of CasESeries in Surgery (PROCESS) guidelines. *Int J Surg*. 2020;84:231–235.
4. Ghritlaharey RK. Ventriculoperitoneal shunt disconnection, shunt migration, and silent bowel perforation in a 10-year-old boy. *J Neurosci Rural Pract*. 2019;10(2):342–345.
5. Kuo MF, Wang HS, Yang SH. Ventriculoperitoneal shunt dislodgement after a haircut with hair clippers in two shunted boys. *Childs Nerv Syst*. 2009;25(11):1491–1493.

6. Mastroianni C, Chauvet D, Ressencourt O, Kirsch M. Late ventriculo-atrial shunt migration leading to pericardial cerebrospinal fluid effusion and cardiac tamponade. *Interact Cardiovasc Thorac Surg*. 2013;16(3):391–393.
7. Aloddadi M, Alshahrani S, Alnaami I. Endovascular retrieval of detached ventriculoatrial shunt into pulmonary artery in pediatric patient: case report. *J Pediatr Neurosci*. 2018;13(1):78–80.
8. Aoi S, Di Luozzo G, Torregrossa G, Finkielstein D. Successful retrieval of a migrated shunt catheter causing severe pulmonary insufficiency. *J Cardiovasc Echogr*. 2018;28(2):127–129.
9. Torres-Brunet L, Pérez-Bovet J, Cohn Reinoso C, Joly Torta MC, Rimbau-Muñoz J. Cross my heart: ventriculoatrial shunt migration into the pulmonary arteries. *Br J Neurosurg*. Published online January 9, 2020. doi: <https://doi.org/10.1080/02688697.2019.1710826>.
10. Fewel ME, Garton HJ. Migration of distal ventriculoperitoneal shunt catheter into the heart. Case report and review of the literature. *J Neurosurg*. 2004;100(suppl 2):206–211.
11. Decq P, Blanquet A, Yepes C. Percutaneous jugular placement of ventriculo-atrial shunts using a split sheath. Technical note. *Acta Neurochir (Wien)*. 1995;136(1-2):92–94.
12. Metellus P, Hsu W, Kharkar S, Kapoor S, Scott W, Rigamonti D. Accuracy of percutaneous placement of a ventriculoatrial shunt under ultrasonography guidance: a retrospective study at a single institution. *J Neurosurg*. 2009;110(5):867–870.

Disclosures

Dr. Schwalb reported grants from Medtronic, Inc. outside the submitted work. No other disclosures were reported.

Author Contributions

Conception and design: Schwalb, Kutschman, Mansour. Acquisition of data: Schwalb, Zervos, Frisoli. Analysis and interpretation of data: Schwalb, Zervos, Kutschman, Mansour. Drafting the article: Schwalb, Zervos, Kutschman, Mansour. Critically revising the article: Schwalb, Zervos, Frisoli, Mansour. Reviewed submitted version of manuscript: Schwalb, Zervos, Mansour. Approved the final version of the manuscript on behalf of all authors: Schwalb. Study supervision: Schwalb.

Supplemental Information

Video

Video 1. <https://vimeo.com/680049543>.

Previous Presentations

This work was a podium presentation at the CNS Annual Meeting, Austin, TX, October 16–20, 2021.

Correspondence

Jason M. Schwalb: Henry Ford Hospital, Detroit, MI. jschwal1@hfhs.org.