

Received: 2010.01.21
Accepted: 2010.03.16

MRI image characteristics of materials implanted at sellar region after transsphenoidal resection of pituitary tumours

Joanna Bładowska¹, Grażyna Bednarek-Tupikowska², Violetta Sokolska³, Roman Badowski³, Krzysztof Moroń³, Wiesław Bonicki⁴, Marek Szaśiadek¹

¹ Department of General Radiology, Interventional Radiology and Neuroradiology, Chair of Radiology, Wrocław Medical University, Wrocław, Poland

² Department of Endocrinology, Diabetology, and Isotope Treatment, Wrocław Medical University, Wrocław, Poland

³ Department of Radiology, Wrocław Medical University, Wrocław, Poland

⁴ Department of Neurosurgery, Centre of Oncology, Maria Curie-Skłodowska Institute, Warsaw, Poland

Author's address: Marek Szaśiadek, Department of General Radiology, Interventional Radiology and Neuroradiology, Chair of Radiology, Wrocław Medical University, Borowska 213 Str., 50-556 Wrocław, Poland, e-mail: mareks@rad.am.wroc

Summary

Background:

Post-surgical evaluation of the pituitary gland in MRI is difficult because of a change in anatomical conditions. It depends also on numerous other factors, including: size and expansion of the tumour before surgery, type of surgical access, quality and volume of implanted materials and time of its resorption.

The purpose was to demonstrate the characteristics of the implanted materials on MRI performed after transsphenoidal resection of pituitary tumours and to identify imaging criteria helpful in differential diagnosis of masses within the sellar region.

Material/Methods:

One hundred and fifty-four patients after transsphenoidal resection of pituitary tumours were included in the study. In general, 469 MRI examinations were performed with a 1.5T scanner. We obtained T1-weighted sagittal and coronal, enhanced and unenhanced images. In 102 cases, additional T2-weighted coronal, unenhanced images with 1.5 T unit were obtained as well.

Results:

The implanted materials appeared in 95 patient: fat in 86 and muscle with fascia in 3 patients. We could recognise implanted muscle and fascia in T2-weighted images, because of high signal intensity of the degenerating muscle and the line of low signal representing fascia. The implanted titanium mesh was found in 4 patients. Haemostatic materials were visible only in 2 patients in examinations performed at an early postoperative stage (1 month after the procedure).

Conclusions:

The knowledge of MRI characteristics of the materials implanted at the sellar region is very important in postoperative diagnosis of pituitary tumours and may help discriminate between tumorous and non-tumorous involvement of the sellar region. Some implanted materials, like fat, could be seen on MRI for as long as 10 years after the operation, others, like haemostatic materials, for only 1 month after surgery. T2-weighted imaging is a useful assessment method of the implanted muscle and fascia for a long time after surgery.

Key words:

implanted materials • MRI • pituitary tumours • surgery

PDF file:

<http://www.polradiol.com/fulltxt.php?ICID=878516>

Background

The aims of the pituitary tumour treatment involve: inhibition of hypersecretion and further expansion of the tumour, as well as relieving the pressure exerted on the structures compressed by the expansive lesion, i.e. on optic chiasm (with eyesight improvement or inhibition of eyesight deterioration), cavernous sinus with internal carotid artery and on parenchyma of the normal pituitary gland (for relief of hypopituitarism symptoms) [1–3].

These aims may be attained by the state-of-the-art neurosurgical methods, radiotherapy and pharmacotherapy based predominantly on neurohormones and neurotransmitters regulating the pituitary hormone secretion and inhibiting the proliferation of pituitary adenomas [2–5].

The basic therapeutic method of pituitary tumours (apart from microprolactinoma) is surgery [1,2,4,6–15]. From among several operation methods of the pituitary gland tumours, the most frequently applied is the one with transnasal transsphenoidal approach. This method has widely forced out craniotomy and is now concerned the method of choice in the treatment of the majority of pituitary adenomas, both the hormonally active and inactive ones [1,2,4,7,9–11,15].

A characteristic feature of surgery from transsphenoidal approach is the necessity of applying different filling materials to obtain haemostasis, to fill the resection site within the sella, and to inhibit the outflow of the CSF [2,16–20].

Filling materials are foreign or autogenic bodies that do not become vascularised [16]. To sustain haemostasis, the following materials are used: oxidised cellulose (Oxycel or Surgicel), spongostan (Gelfoam), tissue glue (Tissucol or Beriplast), bone wax (to restrain bleeding from bone) [2,16–20]. Liquorrhoea requires a reconstructive operation of sella, with the use autogenic fascia, lyophilised dura mater or tissue glue. Next, the sella is sealed with a muscle or flakes of oxidised cellulose. To close the bottom of the sella, it is necessary to use a fragment of the collected cartilaginous septum from nose, the vomer, or a silicon plate. To protect the postresection site and to reinforce the bottom of the sella, an autogenic fat graft is implanted in the sphenoidal sinus. The graft is collected from the fatty tissue of the lateral part of the thigh or from the patient's abdomen [2,16,17,20,21].

An imaging method of choice in the pre- and postsurgical pituitary tumour diagnostics is the MRI. Application of the above mentioned filling materials constitutes a considerable challenge in interpretation of the MRI results in patients who underwent surgery of the pituitary tumour. This can also lead to misdiagnosis.

The aim of the work was to present the characteristic features of the MRI image of filling materials, based on own material, i.e. 154 patients operated on due to the pituitary tumour.

Material and Methods

The study group included 154 patients who underwent transsphenoidal resection of the pituitary tumours,

including 147 pituitary adenomas, 1 colloid cyst, 1 pituitary abscess, 2 Rathke's cleft cysts and 3 craniopharyngiomas located intrasellarly.

The types of pituitary tumours in the studied material were presented in Table 1 and the types of diagnosed pituitary adenomas in patients subjected to surgery – in Table 2.

The study group included 92 women (59.7%) in the age of 15–70 years (mean 41.7 years) and 62 men (40.3%) aged 16–75 years (41.5 on average). In general, the age of the studied patients ranged from 15 to 75 years and the mean age at the moment of the procedure amounted to 41.5 years.

Patients underwent from 1 to 8 MRI examinations after the surgical procedure of the pituitary gland tumour. Thirty-two patients (20.78%) had only one examination performed, while the remaining 122 individuals (79.22%) were examined more than once. In total, 469 examinations were analysed, including also some previous ones, from other study centres. The exact number of MRI examinations carried out in every case and analysed in this work was shown in Table 3.

The duration of the follow-up – from the moment of the procedure till the last MRI study – amounted to 3–348 months (29 years). The mean follow-up time was 70.8 months.

The postoperative follow-up was partially conducted in a prospective manner, covering the period from January 2003 to December 2009 (i.e. 6 years) and partially it was a retrospective analysis (analysis of previous examinations).

MRI examinations were performed with a Picker Edge Eclipse 1.5 T unit. All the patients underwent T1-weighted imaging, in a coronal and sagittal plane, before and after intravenous administration of the paramagnetic contrast agent (0.1 ml/kg of the body mass), in FAST sequence (Fourier acquired steady-state sequence). Technical parameters of that sequence were presented in Table 4.

In 102 cases (66.23%), before administration of the paramagnetic contrast agent, additional scans were performed in the FSE (Fast Spin Echo) sequence, in T2-weighted images, in a coronal plane. Their parameters were shown in Table 5.

Results

In the study group, the filling material was shown in 95 patients. This included 86 cases with fatty tissue, 3 with muscle and fascia, 4 with titanium mesh, and 2 with haemostatic material (Table 6). The evaluation of the MRI results included data from surgical reports. It is known that haemostatic material was applied in all cases. Nevertheless, it was found on MRI in only 2 patients, subjected to examination early after the procedure (i.e. after 1 month).

Fatty filling material was represented by a characteristic signal of high intensity in T1-weighted images. In 65 cases,

Table 1. Types of pituitary tumours in the analysed material.

Types of pituitary tumours in the analysed material		Number of patients
Adenomas	Pituitary macroadenomas	128
	Pituitary microadenomas	19
	Intrasellar Craniopharyngioma	3
Other tumours	Rathke's cleft cyst	2
	Colloid cyst of the pituitary gland	1
	Pituitary abscess	1
In total		154

Table 2. Type of diagnosed pituitary adenomas in individual patients.

Type of pituitary adenoma	Number of cases	Rate
Adenomas secreting growth hormone (GH)	59	40.13%
Adenomas secreting prolactin (PRL)	36	24.49%
Adenomas secreting GH and PRL	2	1.36%
Adenomas secreting adrenocorticotropin (ACTH)	12	8.17%
Adenomas secreting luteotropin (LH)	1	0.68%
Hormonally inactive adenomas	37	25.17%
In total	147	100.00%

Table 3. Number of analysed follow-up MRI examinations in individual patients.

Number of postoperative MRI examinations	Number of examined patients	Rate
1 examination	32	20.78%
2 examinations	37	24.02%
3 examinations	34	22.08%
4 examinations	18	11.69%
5 examinations	19	12.34%
6 examinations	6	3.90%
7 examinations	6	3.90%
8 examinations	2	1.29%
469 examinations in total	154	100.00%

it was located in the lumen of the sphenoidal sinus, while in the remaining 21 patients, its fragments were present intrasellarly. In 12 patients who, according to surgical reports, were implanted fatty filling material, it was invisible on MRI.

Table 4. Technical parameters of MRI images in the pituitary gland examination.

Sequence	FAST T1-weighted	
Plane	Coronal	Sagittal
Repetition time – TR (ms)	229	229
Echo time – TE (ms)	4.5	4.5
Slice thickness/gap (mm)	2.5/0.5	2.5/0.5
Number of acquisitions	2	2
Matrix	256×256	256×256
Field of view – FOV (cm)	17.0	18.0
Scanning time (min)	01:57	02:18

Table 5. Technical parameters of T2-weighted images.

Sequence	FSE T2-weighted
Plane	Coronal
Repetition time – TR (ms)	2500
Echo time – TE (ms)	96.0
Slice thickness/gap (mm)	2.5/0.5
Number of acquisitions	2
Matrix	256×256
Field of view – FOV (cm)	17.0
Scanning time (min)	02:40

Table 6. Implanted materials used during surgery in the examined group.

	Number of patients – data from surgical reports	Number of patients – materials based on MRI results
Fat	98	86
Muscle with fascia	3	3
Titanium mesh	4	4
Haemostatic material	154	2

Muscle with fascia presented in T1-weighted images as a round hypointense structure, located in the lumen of the sphenoidal sinus. After contrast medium administration, the peripheral part of that material got slightly enhanced. In T2-weighted images, the implanted muscle with fascia produced a high signal intensity (increased signal intensity corresponded to degenerative processes of the denervated muscle).

Fascia presented as a line of low signal intensity.

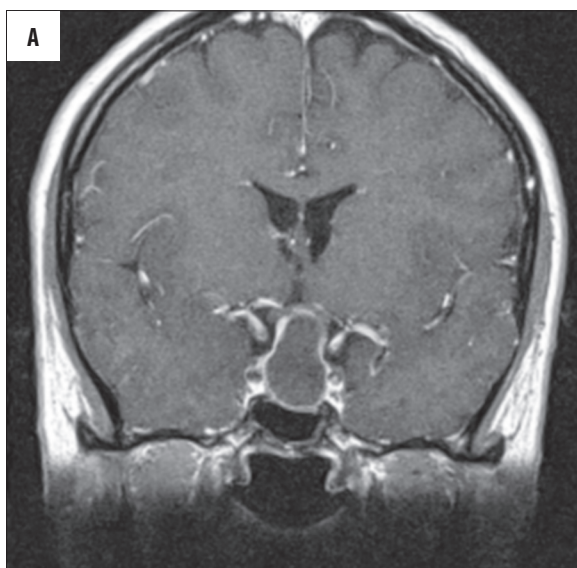


Figure 1A. T1-weighted image after contrast administration, coronal plane: the endosellar-suprasellar adenoma.

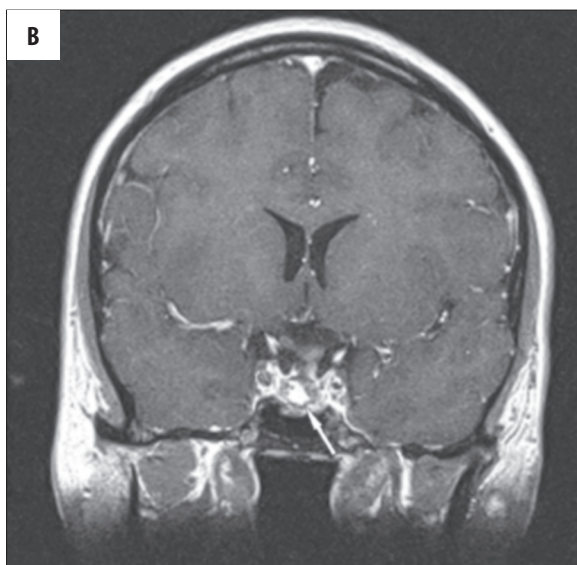


Figure 1B. MRI examination performed 1 month after surgery. T1-weighted image after contrast administration, coronal plane: the suprasellar residual tumour and endosellarly implanted fat (arrow).

The implanted titanium mesh was identified as a line of an absent signal intensity within the bottom of the sella, which corresponded to the presence of a metal foreign body.

Haemostatic material (according to neurosurgical reports – Oxycel) showed a low signal intensity surrounded by a line of a delicate enhancement after contrast administration.

We also evaluated the time for which the implanted material was present on MRI after the procedure. In our study group, the total absorption of the fatty material was found in 3 patients in examinations performed approx. 11 months following the surgery, and in 1 patient after 15 months. In the majority of patients, the fragments of fatty tissue were observed for a long time – for up to 112 months (over

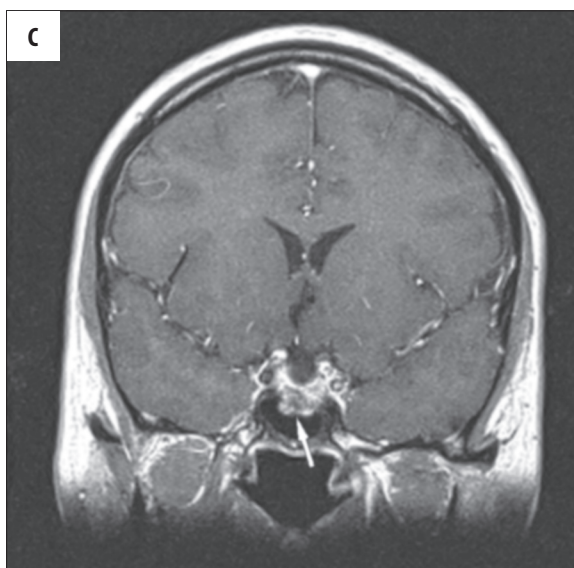

Figure 1C. MRI examination performed 1 month after surgery. T1-weighted image after contrast administration, coronal plane: at the bottom of the sella there is a structure which could be haemostatic material (arrow).

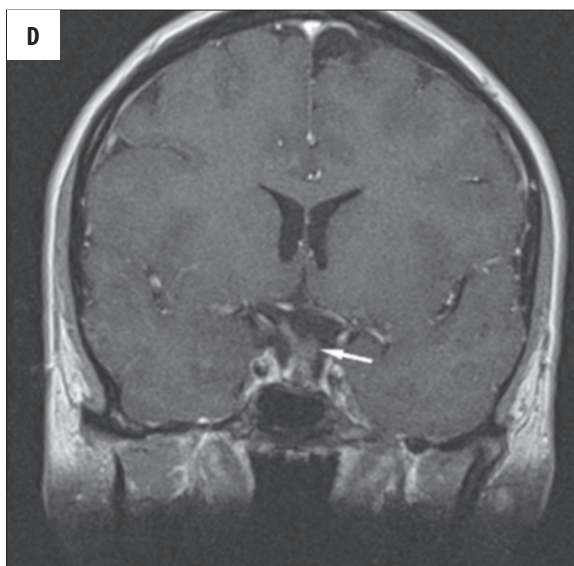


Figure 1D. Follow-up MRI, 15 months after the pituitary tumour resection. T1-weighted image after contrast administration, coronal plane: there is still the suprasellar residual tumour (arrow), the implanted fat had disappeared.

9 years) after the procedure, and in one patient, a large amount of fatty material was still present in the sphenoidal sinus after 348 months (29 years).

In 3 cases with muscle and fascia implanted within the sphenoidal sinus, the follow-up examinations showed a decreasing intensity of contrast enhancement in T1-weighted images (case 3). T2-weighted images did not reveal any significant changes in signal intensity within the implanted muscle and fascia for up to 31 months following the procedure – no further MRI examinations were performed in those cases. In the reported follow-up time, no

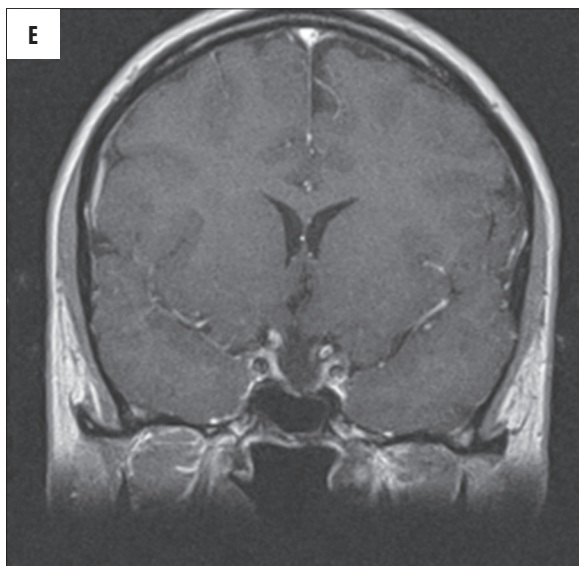


Figure 1E. Follow-up MRI at 15 months after the pituitary tumour resection. T1-weighted image after contrast administration, coronal plane: no structure suggestive of the presence of the filling material.

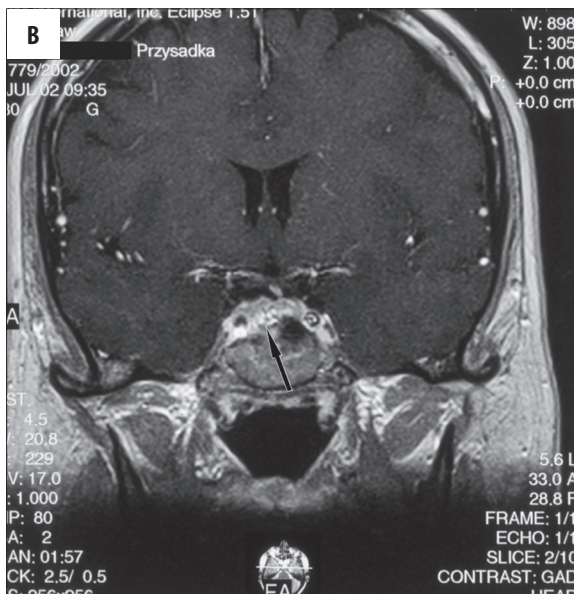


Figure 2B. MRI examination performed at 3 months after surgery. T1-weighted image after contrast administration, coronal plane: the residual adenoma at the right side of the sella (arrow).

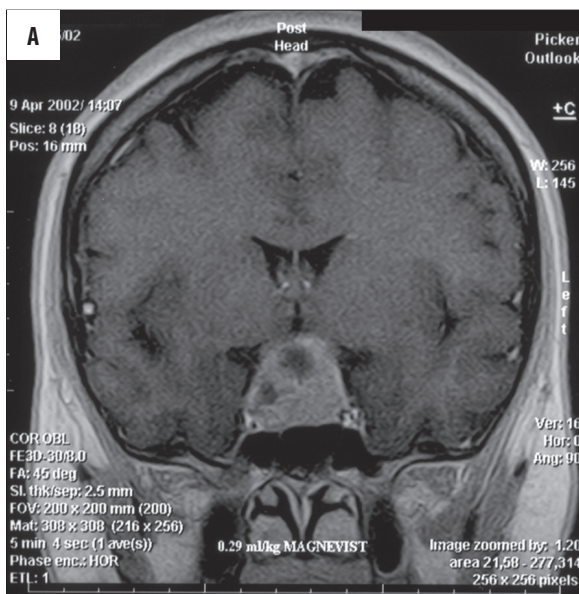


Figure 2A. T1-weighted image after contrast administration, coronal plane: the endosellar-suprasellar macroadenoma is visible.

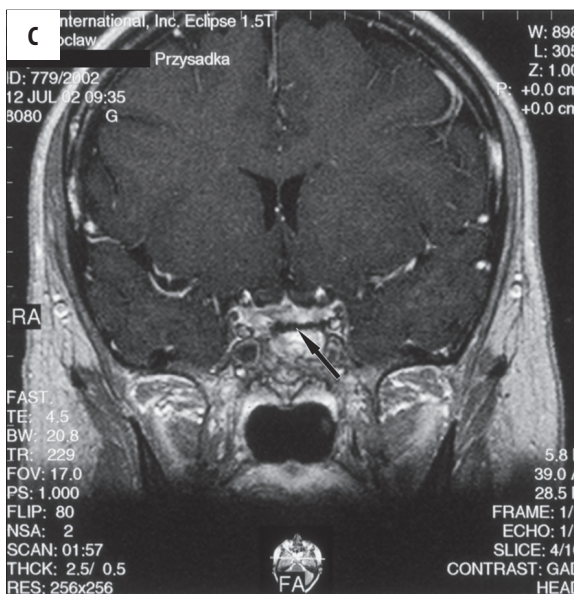


Figure 2C. MRI examination performed at 3 months after surgery. T1-weighted image after contrast administration, coronal plane: the titanium mesh at the bottom of the sella (arrow).

decrease in the volume of the implanted muscle and fascia was found, as it was seen in case of fat which was being progressively absorbed.

Underneath, we present some representative examples of MR images of 3 patients after pituitary tumour surgery.

Case 1

A 27-year-old woman admitted to the Department of Endocrinology due to hyperprolactinaemia of 311 ng/ml (N=1.9-25.0 ng/ml), diagnosed under outpatient conditions. Moreover, the patient reported secondary amenorrhea for approx. 3 years. The performed MRI showed a large

endo- and suprasellar tumour of solid-cystic type, measuring 2.8×1.9 cm (Figure 1A).

The patient was operated on from transsphenoidal approach. After the procedure, a high prolactin level and menstrual disturbances were still present. A follow-up MRI performed 1 month after surgery showed a residual tumour measuring 0.9×0.9 cm, located suprasellarly, at the region of the optic chiasm. Endosellarly, there was a hyperintense fat (Figure 1B). What is more, on the bottom of the sella, more anteriorly, there was a structure hypointense

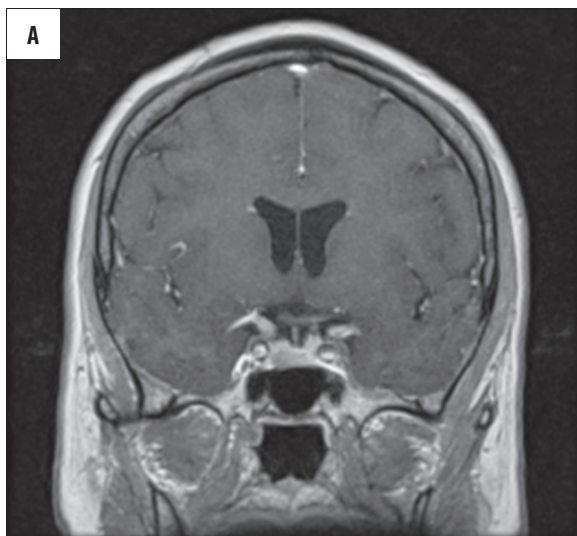


Figure 3A. MRI examination before surgery. T1-weighted image after contrast administration, coronal plane: low-signal-intensity microadenoma at the right side of the anterior pituitary lobe.

in T1-weighted images, protruding to the sphenoidal sinus and becoming slightly enhanced peripherally after contrast administration (Figure 1C) – MRI image suggested the presence of a haemostatic material.

In the next MRI examination, performed 15 months after the procedure, the residual tumour was still present. It was located suprasellarly, within the optic chiasm region (Figure 1D). However, the examination showed neither fatty filling material, nor hypointense structure in the bottom of the sella, present in the previous study (Figure 1D,E), which meant a total absorption of the fat and the haemostatic material.

Additional tests showed an elevated prolactin level, which confirmed the presence of the residual adenoma.

Case 2

A 38-year old woman admitted to the Department of Neurosurgery for the operation of prolactin secreting macroadenoma (macroprolactinoma). The patient reported headaches present for about 6 last years, menstruation abnormalities with galactorrhoea for the last two years and vision problems experienced for about half a year. The MRI examination showed a solid-cystic tumour of the pituitary gland, measuring 2.2×1.8×2.0 cm (Figure 2A).

The patient was subjected to a procedure from transsphenoidal approach. The surgery was complicated by rhinorrhoea which subsided after application of the lumbar drainage. Additionally, at the bottom of the sella, a titanium mesh was implanted. Follow-up laboratory studies revealed a sustained increased level of prolactin, while the MRI examination carried out 3 months after the procedure showed the presence of a residual tumour of 1.0×0.8 cm in size, located intrasellarly, on the right, as well as in the cavernous sinus (Figure 2B). Infundibulum of the pituitary gland was displaced to the left. The optic chiasm seemed normal. In the

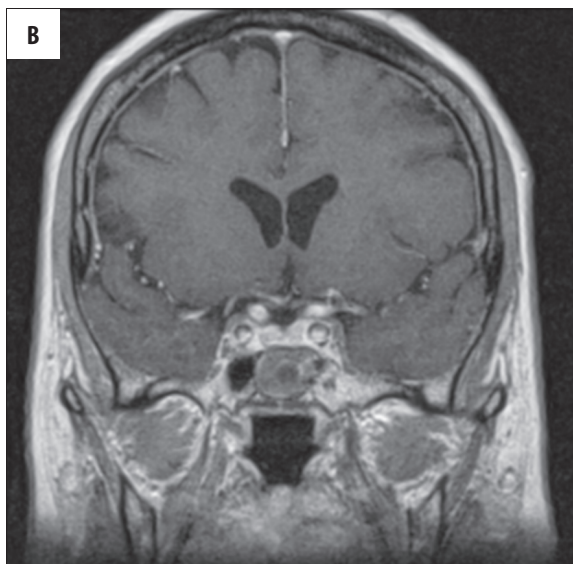


Figure 3B. MRI examination performed at 5 months after surgery. T1-weighted image after contrast administration, coronal plane: in the sphenoid sinus there is the round structure with slight peripheral enhancement.

bottom of the sella there was a linear area emitting no signal, representing an implanted titanium mesh (Figure 2C).

Case 3

A 70-year-old woman, admitted to the Department of Endocrinology due to typical clinical features of acromegaly becoming more pronounced in the last 10 years: enlarging hands, feet, and tongue, accompanied by headaches. The performed MRI revealed a hypointense area of 8 mm in diameter, highlighting the outlines of the pituitary gland and located within the anterior pituitary lobe, on the right. This image corresponded to the presence of microadenoma (Figure 3A).

The patient was subjected to surgery from transnasal and transsphenoidal approach. As a filling material, a muscle with fascia collected from the patient's thigh was used.

In the follow-up MRI performed 5 months after the procedure, the pituitary gland did not show any focal lesions. In the lumen of the sphenoidal sinus, there appeared a round structure, isointense in T1-weighted images, which became slightly enhanced peripherally, with a centrally located round area of lower signal intensity (Figure 3B). In T2-weighted images, the mass showed a high signal intensity with a linear structure of low enhancement (Figure 3C). All the features found during imaging, together with the clinical data, allowed for diagnosing the presence of an implanted muscle with fascia.

In the next follow-up MRI, 12 months after the procedure, the image of the pituitary gland and of the perisellar structures did not change significantly. However, after contrast administration, the previously distinct border between the enhanced peripheral part of the implanted muscle, and the central part of lower signal intensity, became indistinct (Figure 3D). The next MRI examination, performed 25 months after surgery, showed further evolution of the filling

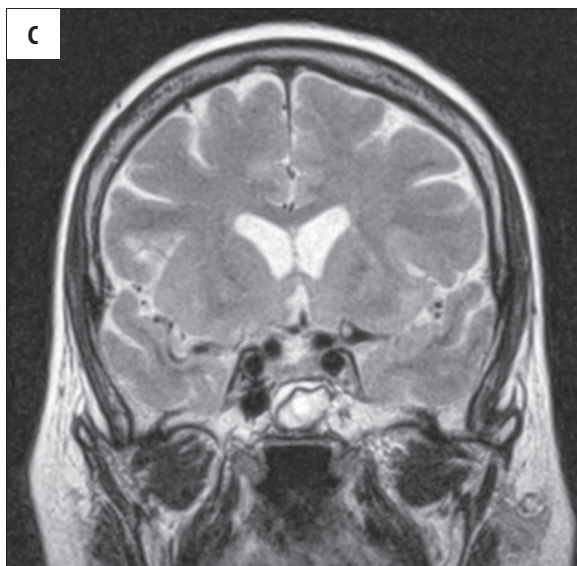


Figure 3C. MRI examination performed at 5 months after surgery. T2-weighted image before contrast administration, coronal plane: in the sphenoid sinus there is the implanted muscle and fascia.

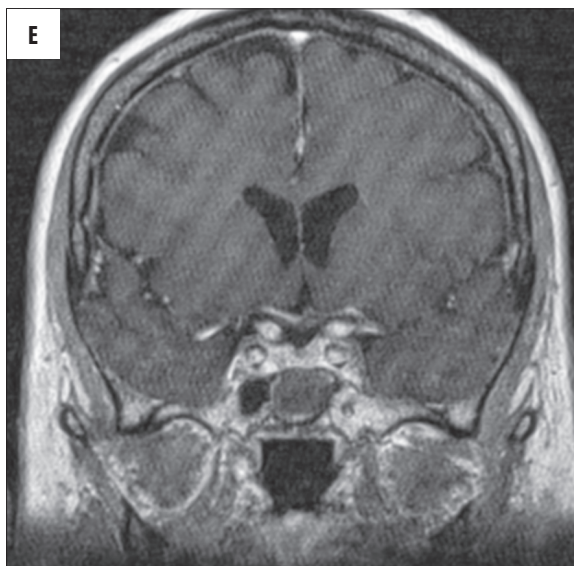


Figure 3E. MRI examination performed at 25 months after surgery. T1-weighted image after contrast administration, coronal plane: in the sphenoid sinus there is the implanted muscle and fascia, the enhancement is slighter than in the last MRI.

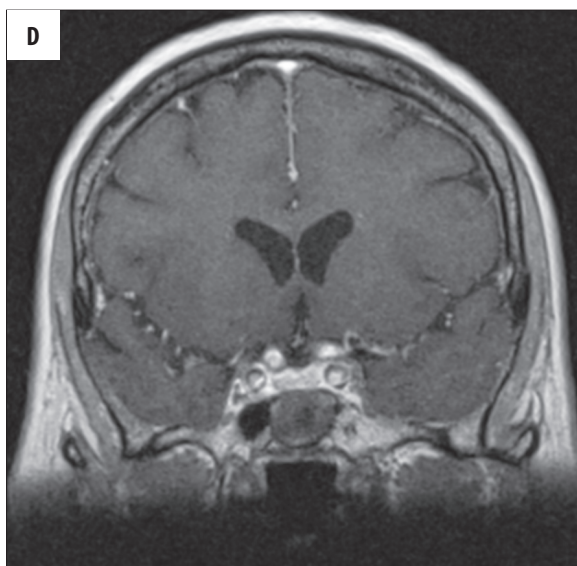


Figure 3D. MRI examination performed at 12 months after surgery. T1-weighted image after contrast administration, coronal plane: in the sphenoid sinus there is implanted muscle and fascia.

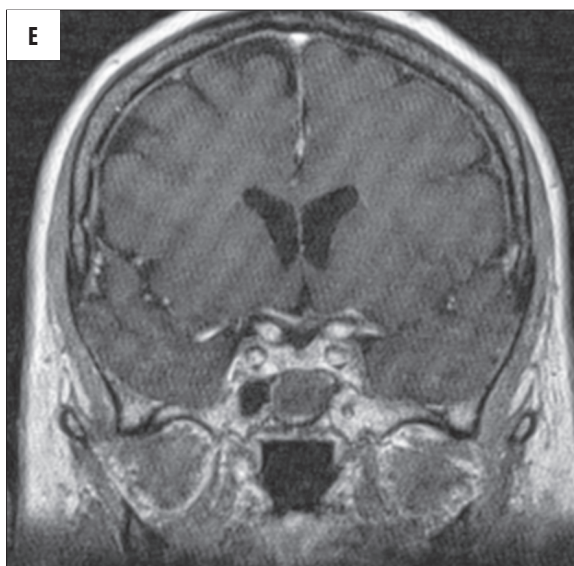


Figure 3F. MRI examination performed 25 months after surgery. T2-weighted image before contrast administration, coronal plane: the characteristic appearance of the implanted muscle and fascia.

material – the material did not show enhancement after contrast administration (Figure 3E). In T2-weighted images, there was still a characteristic hyperintense mass with a linear, low-signal structure (Figure 3F), which allowed for the diagnosis of the implanted muscle with fascia, even without knowing patient's history or previous examinations.

Discussion

In the postoperative evaluation of the pituitary gland and of the perisellar area, it is very important to know the type of filling material used in the procedure, its image on MRI, as well as the resorption time.

As it was already mentioned at the beginning, filling materials are foreign bodies which do not become vascularised [16]. In order to maintain haemostasis, the most common materials used are: flakes of oxygenated cellulose (Oxycel or Surgicel) and spongostan (Gelfoam) [2,16,17-20,22]. In the transsphenoidal access, an autogenic fat or muscle with fascia is implanted in the bottom of the sella for additional protection of the resection site [2,16,17,20-22].

In the MRI examination, in T1-weighted images, Surgicel (Oxycel) is represented by a heterogeneous structure with a regular, oval shape, low signal intensity, surrounded by a hyperintense rim [16,20]. Examinations performed in the

first days after the procedure, frequently reveal the presence of small air bubbles closed in the strips of Surgicel [20], in the hypointense central part of the filling material.

Spongostan (gelfoam) is represented in the MRI examination by an intrasellar mass of signal intensity similar to that of the grey matter [16,20]. In rare cases, spongostan may produce a heterogeneous high signal caused most probably by the presence of methemoglobin [16].

The similarity between signal intensity of the filling material, of the anterior pituitary lobe, and of a potential residual tumour often makes it difficult to interpret the image in an unequivocal way and to carry out a correct differential diagnosis. However, according to T. Kilic et al., spongostan and Surgicel (Oxycel) may be recognised only on an early performed MRI, i.e. within 24–48 hours after the procedure, because afterwards, the materials begin to undergo a progressive degeneration and their radiological identification becomes harder [22]. E. Steiner et al reported that these materials are normally recognisable on MRI for up to 3–6 months after the procedure [16]. Our studies showed that haemostatic materials may be identified in the early postoperative period only – in own material that was 1 month.

After contrast administration, the central part of the haemostatic material remained hypointense, with peripheral rim of enhancement [16,22]. This peripheral enhancement is caused by granulation tissue forming around the implanted material [16,22]. Filling materials undergo changes which surely inhibit their identification. It should be underscored that a hypointense mass with peripheral enhancement after contrast administration is not characteristic for the filling material only. It may also correspond to the presence of a fluid cystern, regions of necrosis within the tumour or cicatricial fibrous tissue with granulation around it [16,23].

In our own material, as much as 85.61% of the patients had their first postoperative MRI examination performed after 3 months following the procedure, and only 14.39% of the studied individuals (20 patients) – during the first 3 months. There were no examinations carried out within 24–48 hours from the procedure. When we consider the date of MRI examinations and the fast degeneration of the filling material, it is then easy to explain the fact why the haemostatic material was identified in only two patients of the study group (case 1).

The analysis of the conducted examinations revealed that the implanted autogenic fat and muscle with fascia, located in the lumen of the sphenoidal sinus, can be observed on MRI for much longer.

Fatty tissue is not too difficult to identify, as it emits a characteristic signal of high intensity in T1-weighted images [20,21]. There were reported cases of residual fatty material present in the sphenoidal sinus examined at 1–2 years after the procedure [21,24] or even 3–4 years afterwards [20]. However, according to the assessments, the implanted fat may remain in place for much longer [25]. The volume of the implanted fat influences the duration

of its presence on MRI. Normally, the adipose tissue implanted in larger amounts (in case of macroadenoma resection) retains for much longer than the small amount of that material (implanted after microadenoma resection), absorbed within 9–12 months [22].

As compared to other filling materials, identification of the fatty tissue in the MRI examination is easy thanks to the characteristic high signal intensity produced by the material, its longer persistence, but also the absence of adjacent contrast-enhanced areas formed by the granulation tissue [22].

In the studied material, the implanted fatty tissue was identified in as many as 86 patients after pituitary tumour surgery. In the remaining 12 patients, who according to surgical reports were implanted fatty filling material, it was impossible to find that material on MRI. No fatty tissue found in these patients may result from a small amount of the implanted material, from its fast absorption, as well as from a longer postoperative time to MRI examination.

The earliest total absorption of the fatty material was observed 11 months after the procedure. In most of the cases, residues of the adipose tissue were present for a long time, for even up to 112 months (nearly 10 years) after the procedure, while in one patient, there was a large amount of the fatty material still present in the lumen of the sphenoidal sinus after 348 months (29 years).

In 2 patients, it was possible to visualise the implanted titanium mesh (case 2). On MRI, the titanium mesh was represented by a linear area producing no signal and located in the bottom of the sella [16].

In 3 individuals, an implanted muscle with fascia was identified. It was represented by a round, isointense structure, filling nearly the whole sphenoidal sinus in T1-weighted MRI images. After intravenous contrast administration, the structure was becoming slightly enhanced in its peripheral part, with a central round area of lower signal intensity. Such an image of the implanted muscle was found in 2 patients after 4 months following the procedure, and in 1 patient after 5 months from surgery. The follow-up MRIs (beginning approx. from the 12th postoperative month) were revealing a gradual change in the image of that material. After contrast administration, the previously distinct border between the enhanced peripheral part and the central hypointense part of the implanted muscle became indistinct. In further MRI examinations, performed approx. 25 months after surgery or later, the structure present in the lumen of the sphenoidal sinus remained hypointense after contrast administration. Without the analysis of previous images and the knowledge of patient's history, the correct diagnosis of that mass in T1-weighted images was impossible (especially its differentiation from e.g. fluid cystern). The implanted muscle with fascia produced a very characteristic and almost stable image in T2-weighted sequence, for at least 31 months following the procedure. In the T2-weighted sequence, the material is represented by a hyperintense mass with a linear structure, of a very low signal intensity, corresponding to fascia. It should also be pointed out that fascia was not identified in T1-weighted images (case 3).

The final diagnosis and evaluation of the surgical completeness on the basis of the performed MRI is often equivocal, in spite of the presence of the above mentioned criteria.

It is especially hard to evaluate the effectiveness of the surgical treatment of the hormonally inactive tumours on the basis of the MRI examination results and their interpretation only [20,26]. These tumours require a postsurgical endocrinological and MRI follow-up.

Follow-up of abnormal structures present in the postsurgical area may allow for their verification. If in the following examinations there is a complete absorption of the focal lesion, this excludes the presence of a residual tumour and indicates to the filling material or postoperative lesions. Such a situation was present in case 1, where after 15 months following the procedure, the structure shown on MRI after one month from surgery, was not there anymore.

If the size and volume of the pathological structure increases, this points to the presence of a residual tumour. On the other hand, it should be remembered that pituitary

tumours grow slowly [4,27-30], so in a long-term follow-up, the tumour may seem stable, which does not facilitate the final diagnosis in unclear cases of hormonally inactive tumours.

Conclusions

1. The knowledge of MRI characteristics of the filling materials implanted during the transsphenoidal procedure is a very important factor which may help in the differential diagnosis of intra- and perisellar structures in patients after pituitary tumour surgery.
2. Haemostatic materials can be seen on MRI for only a short period of time after the procedure (1 month). Others, such as fat, may be present for as long as even 10 years after the procedure.
3. T2-weighted images are very useful in the postoperative evaluation of the implanted muscle with fascia, for a long time after the resection.

References:

1. Gołkowski F, Trofimiuk M, Huszno B et al: Ocena czynności hormonalnej przysadki po operacji gruczolaka z dojścia przez zatokę klinową. *Przeg Lek*, 2001; 58: 825-27
2. Hardy J, Czepko R: Guzy przysadki. In: Ząbek M (ed.): *Zarys neurochirurgii*. PZWL, Warszawa 1999; 83-107
3. Janicki K, Orski J, Telesińska D et al: Trudności diagnostyczne w skąpoobjawowym guzie przysadki. *Przeg Lek*, 2002; 59: 193-96
4. Bolanowski M: Guzy przysadki – możliwości diagnostyczne i terapeutyczne. *Terapia*, 2001; 102: 37-39
5. Kunert-Radek J: Leczenie farmakologiczne gruczolaków przysadki. *Endokrynol Pol – Polish J Endocrinol*, 1995; 46(Suppl.1): 37-47
6. Bonicki W, Michalik R, Krajewski R et al: Zastosowanie technik chirurgii podstawy czaszki w leczeniu gruczolaków przysadki. *Neurol Neurochir Pol*, 2002; 36: 1121-33
7. Czepko R, Danilewicz B, Anilewicz M et al: Bezpośrednie wyniki leczenia gruczolaków przysadki metodą przezczaszkową i przezklinową. *Przeg Lek*, 1999; 56: 638-43
8. Jho H-D, Carrau RL, Ko Y et al: Endoscopic pituitary surgery: an early experience. *Surg Neurol*, 1997; 47: 213-23
9. Patterson RH: The role of transcranial surgery in the management of pituitary adenoma. *Acta Neurochir (Suppl)*, 1996; 65: 16-17
10. Cooke RS, Jones AC: Experience with the direct transnasal transsphenoidal approach to the pituitary fossa. *Br J Neurosurg*, 1994; 8: 193-96
11. Liebert W, Szyfter W, Tokarz F et al: Chirurgiczne leczenie gruczolaków przysadki mózgowej z dojścia przez zatokę klinową. *Otolaryng Pol*, 1994; 48: 260-65
12. Sheehan MT, Atkinson JLD, Kasperbauer JL et al: Preliminary comparison of the endoscopic transnasal vs the sublabial transseptal approach for clinically nonfunctioning pituitary macroadenomas. *Mayo Clinic Proc*, 1999; 74: 661-70
13. Liebert W, Szyfter W: Leczenie gruczolaków przysadki mózgowej z dojścia przez nos i zatokę klinową. *Metoda chirurgiczna*. *Otolaryng Pol*, 1994; 48(Suppl.16): 93-95
14. Gierek T, Gałuszka-Ignasiak B, Krauze J et al: Dojście przez przegrodę nosową w operacjach transsphenoidalnych guzów przysadki mózgowej. *Otolaryng Pol*, 1995; 49(Suppl.19): 363-66
15. Bolanowski M: Treatment of pituitary tumours. In: *International Intensive Course in Oncology ERASMUS 2000 "Recent advances in the knowledge of cancer"*. P.2, Wrocław, 02-16.09.2000; 49-54
16. Steiner E, Knosp E, Herold ChJ et al: Pituitary adenomas: Findings of postoperative MR imaging. *Radiology*, 1992; 185: 521-27
17. Yen PJ, Chen JW: Pituitary tumors: surgical and medical management. *Surg Oncol*, 1997; 6: 67-92
18. Jane JA, Thapar K, Kaptain GJ et al: Pituitary surgery: Transsphenoidal approach. *Neurosurgery*, 2002; 51: 435-44
19. Ellegala DB, Maartens N, Laws ER: Use of FloSeal hemostatic sealant in transsphenoidal pituitary surgery: technical note. *Neurosurgery*, 2002; 51: 513-16
20. Bonneville JF, Bonneville F, Schillo F et al: Follow-up MRI after trans-sphenoidal surgery. *J Neuroradiol*, 2003; 30: 268-79
21. Dina TS, Feaster SH, Laws ER et al: MR of the pituitary gland postsurgery: serial MR studies following transsphenoidal resection. *AJNR*, 1993; 14: 763-69
22. Kilic T, Ekinci G, Seker A et al: Determining optimal MRI follow-up after transsphenoidal surgery for pituitary adenomas: scan at 24 hours postsurgery provides reliable information. *Acta Neurochir (Wien)*, 2001; 143: 1103-26
23. Rodriguez O, Mateos B, de la Pedraja R et al: Postoperative follow-up of pituitary adenomas after transsphenoidal resection: MRI and clinical correlation. *Neuroradiology*, 1996; 38: 747-54
24. Connor SEJ, Deasy NP: MRI appearances of the sphenoid sinus at the late follow-up of trans-sphenoidal surgery for pituitary macroadenoma. *Australasian Radiology*, 2002; 46: 33-40
25. Nakasu Y, Itoh R, Nakasu S et al: Postoperative sella: evaluation with fast spin echo T2-weighted high-resolution imaging. *Neurosurgery*, 1998; 43: 440-47
26. Kremer P, Forsting M, Ranaei G et al: Magnetic resonance imaging after transsphenoidal surgery of clinically non-functional pituitary macroadenomas and its impact on detecting residual adenoma. *Acta Neurochir (Wien)*, 2002; 144: 433-43
27. Evanson J: Imaging the pituitary gland. *Imaging*, 2002; 14: 93-102
28. Levy A, Lightman SL: Diagnosis and management of pituitary tumors. *BMJ*, 1994; 308: 1087-91
29. Zhang X, Horwitz GA, Heaney AP et al: Pituitary tumor transforming gene (PTTG) expression in pituitary adenomas. *J Clin Endocrinol Metab*, 1999; 84: 761-67
30. Faglia G: Epidemiology and pathogenesis of pituitary adenomas. *Acta Endocrinol*, 1993; 129(Suppl.1): 1-5