

Available online at [www.sciencedirect.com](http://www.sciencedirect.com)

ScienceDirect

journal homepage: <http://Elsevier.com/locate/radcr>

## Pediatric

# Surfer's exostosis in a child who does not surf

Michael Paddock FRCR<sup>a,\*</sup>, Kimberley Lau MRCS<sup>b</sup>, Ashok Raghavan FRCR<sup>a</sup>,  
Aikaterini Dritsoula Otolaryngology Specialist<sup>b</sup>

<sup>a</sup> Department of Radiology, Sheffield Children's NHS Foundation Trust, Western Bank, Sheffield, S10 2TH, UK

<sup>b</sup> Department of Otolaryngology, Sheffield Children's NHS Foundation Trust, Western Bank, Sheffield, S10 2TH, UK

### ARTICLE INFO

#### Article history:

Received 29 December 2017

Accepted 3 February 2018

Available online

#### Keywords:

Ear

Otorhinolaryngology

Pediatric otorhinolaryngology

Exostosis

### ABSTRACT

Surfer's exostoses are more commonly seen in adults who frequently participate in aquatic activities with repeated exposure to cold water and wind. However, this entity has not been previously reported in the pediatric population. Most patients can be managed conservatively, particularly considering that surgical removal of external auditory canal exostosis can be challenging.

© 2018 the Authors. Published by Elsevier Inc. under copyright license from the University of Washington. This is an open access article under the CC BY-NC-ND license (<http://creativecommons.org/licenses/by-nc-nd/4.0/>).

## Introduction

We report the case of a surfer's exostosis in a child in the absence of the typical history of cold water and wind exposure.

## Case report

A 15-year-old female was referred to the Ear, Nose, and Throat outpatient clinic by her general practitioner following a consultation for ear syringing. She was noted to have a lesion in her right external auditory canal (EAC) with symptoms of blockage, discomfort, and infrequent otalgia. There was no history of recurrent ear infection, otorrhoea, hearing loss or

participation in aquatic activities. After wax was microsuctioned, otoscopy revealed a broad-based bony lesion arising from the anterosuperior region of the bony EAC (Fig. 1). Her tympanic membrane, partially visualized behind the bony lesion, was normal and her audiogram was within normal limits.

High-resolution computed tomography of her temporal bones and internal acoustic meatuses demonstrated an exostosis arising from the anterosuperior tympanic portion of the right temporal bone (Fig. 2). She was followed up as an outpatient for monitoring of recurrent infections and wax accumulation. While she required microsuctioning for impacted wax, she had no further issues with recurrent otitis externa and hearing loss; as such, surgical intervention was not considered. Our patient only required wax microsuctioning every 6 months.

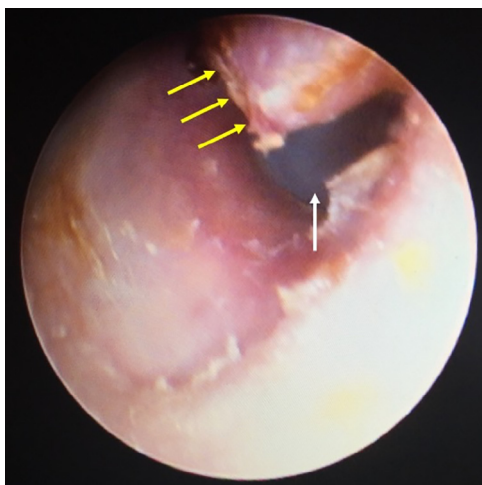
Competing Interests: The authors have declared that no competing interests exist.

\* Corresponding author.

E-mail address: [michael.paddock@doctors.org.uk](mailto:michael.paddock@doctors.org.uk) (M. Paddock).

<https://doi.org/10.1016/j.radcr.2018.02.010>

1930-0433/© 2018 the Authors. Published by Elsevier Inc. under copyright license from the University of Washington. This is an open access article under the CC BY-NC-ND license (<http://creativecommons.org/licenses/by-nc-nd/4.0/>).



**Fig. 1 – Photograph of a right external auditory canal exostosis in 15-year-old female. The exostosis (yellow arrows) is seen arising from, and partially obstructing, the anterosuperior region of the bony external auditory canal. The tympanic membrane (white arrow), partly visualized medial to the exostosis, is normal.**

## Discussion

Exostoses, the most common benign tumors of the EAC, are bony outgrowths that arise from the tympanic portion of the temporal bone [1]. Surfer's exostoses are more commonly seen in individuals who participate frequently in aquatic activities [2] and are thought to be caused by repeated exposure to cold water and wind [3]. It has been suggested that repeated cold water exposure leads to a recurrent periostitis [3] and an increase in osteoblastic activity [4] resulting in hyperostosis [5] and formation of exostoses. It has been shown that those who participate in cold-water surfing are more likely to develop EAC exostosis, and that with an increasing length of exposure to cold water (in years) there is an increase in the severity of

lesions [4,6–8]. As such, surfer's exostoses are so named because of those individuals who develop these lesions, a significant proportion are cold-water surfers [7].

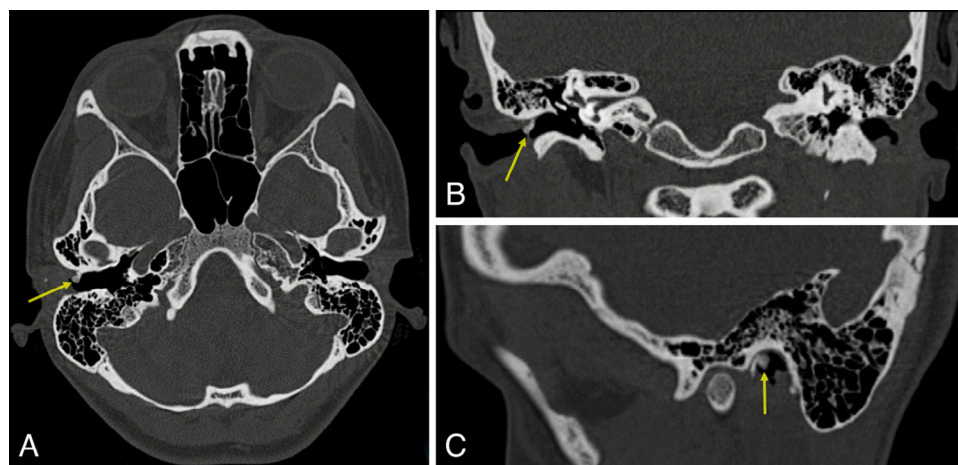
There is probably a geographical tendency to develop these lesions; if one lives in a coastal region, one may be more likely to surf or to be exposed to the conditions which encourage exostoses to develop. Indeed, this appears to be reflected in the populations examined in the literature [4,9–13]. It is difficult to ascertain the true age and gender prevalence of EAC exostoses given that anyone can participate in aquatic sports such as cold-water surfing. However, one study found that Australian male surfers were more likely to develop these lesions than females [9]. However, while more men were included in the study (which may reflect actual participation in this sport), the likelihood and severity of developing these lesions depended on the number of years surfed, as discussed above [4,6–9].

The majority of patients are asymptomatic and aural care to microsuction impacted wax and debris is only required infrequently. Those with exostoses severely obstructing the EAC are prone to recurrent episodes of otitis externa and related conductive hearing loss [6]; surgical resection is considered when there is severe EAC obstruction, along with severely symptomatic patients [5,14,15]. When surfers are made aware of the risk of developing EAC exostosis, the use of preventative measures (e.g. ear plugs) increases [11], advocating an increased awareness of this condition in this population and the health-care professionals who treat them.

The main differential diagnosis for EAC exostosis is an EAC osteoma. These lesions are usually pedunculated, arise from bony cartilaginous junctions and given that they are slow growing, are usually asymptomatic and discovered incidentally (i.e. high-resolution computed tomography of the temporal bones performed for another indication) [16].

## Conclusion

It is unusual that our patient developed a surfer's exostosis in the absence of the usual precipitating factors cited in the



**Fig. 2 – High-resolution computed tomography of the petrous temporal bones in a 15-year-old female. Selected (A) axial slice with (B) coronal and (C) sagittal reconstructions demonstrate a bony exostosis (yellow arrow) arising from the anterosuperior tympanic portion of the right temporal bone.**

literature. To the authors' knowledge, there has been no previously published case report of surfer's exostosis in children, nor in children without a previous history of repeated exposure to cold water aquatic activities. Further reports of such cases, particularly from specialist pediatric Ear, Nose, and Throat services, should be encouraged.

#### REFERENCES

- [1] Hirose Y, Shikino K, Ikusaka M. Surfer's ear and external auditory canal exostoses. *QJM* 2016;109(11):759.
- [2] Wong BJ, Cervantes W, Doyle KJ, Karamzadeh AM, Boys P, Brauel G, et al. Prevalence of external auditory canal exostoses in surfers. *Arch Otolaryngol Head Neck Surg* 1999;125(9):969–72.
- [3] Barbon DA, Hegde R, Li S, Abdelbaki A, Baja D. Bilateral external auditory exostoses causing conductive hearing loss: a case report and literature review of the surfer's ear. *Cureus* 2017;9(10):e1810.
- [4] Attlmayr B, Smith IM. Prevalence of 'surfer's ear' in Cornish surfers. *J Laryngol Otol* 2015;129(5):440–4.
- [5] Kutz JW Jr, Fayad JN. Exostosis of the external auditory canal. *Ear Nose Throat J* 2006;85(3):142.
- [6] Kroon DF, Lawson ML, Derkay CS, Hoffmann K, McCook J. Surfer's ear: external auditory exostoses are more prevalent in cold water surfers. *Otolaryngol Head Neck Surg* 2002;126(5):499–504.
- [7] Alexander V, Lau A, Beaumont E, Hope A. The effects of surfing behaviour on the development of external auditory canal exostosis. *Eur Arch Otorhinolaryngol* 2015;272(7):1643–9.
- [8] House JW, Wilkinson EP. External auditory exostoses: evaluation and treatment. *Otolaryngol Head Neck Surg* 2008;138(5):672–8.
- [9] Hurst W, Bailey M, Hurst B. Prevalence of external auditory canal exostoses in Australian surfboard riders. *J Laryngol Otol* 2004;118(5):348–51.
- [10] Nakanishi H, Tono T, Kawano H. Incidence of external auditory canal exostoses in competitive surfers in Japan. *Otolaryngol Head Neck Surg* 2011;145(1):80–5.
- [11] Reddy VM, Lau AS, Abdelrahman T, Flanagan PM. Surfers' awareness of the preventability of 'surfer's ear' and use of water precautions. *J Laryngol Otol* 2011;125(6):551–3.
- [12] Umeda Y, Nakajima M, Yoshioka H. Surfer's ear in Japan. *Laryngoscope* 1989;99(6 Pt 1):639–41.
- [13] Morris S, Martin T, Mccahon D, Bennett S. Awareness and attitudes towards external auditory canal exostosis and its preventability in surfers in the UK: cross-sectional study. *J Laryngol Otol* 2016;130(7):628–34.
- [14] Altuna Mariezkurrena X, Vea Orte JC, Camacho Arrioaga JJ, Algaba Guimerá J. Surgical treatment of exostosis in the external auditory canal. *Acta Otorrinolaringol Esp* 2006;57(6):257–61.
- [15] Whitaker SR, Cordier A, Kosjakov S, Charbonneau R. Treatment of external auditory canal exostoses. *Laryngoscope* 1998;108(2):195–199.
- [16] Sente M. External auditory canal osteoma. *Srp Arh Celok Lek* 2009;137(1–2):73–6.