

SPOTLIGHT

Omnipolar activation EGM to identify the earliest breakout site of atrial tachycardia

Colin Yeo MBBS, MRCP, DRCPC   | Vern Hsen Tan MBBS, MRCP, CEDS, CEPS  | Yue Wang MD, MRCP 

Department of Cardiology, Changi General Hospital, Singapore City, Singapore

Keywords: atrial tachycardia, catheter ablation, HD grid, LAT map, omnipolar

We present a case of a 45-year-old lady with symptomatic adenosine-sensitive atrial tachycardia (AT). She had a structurally normal heart and no prior cardiac history. Resting 12 lead ECG showed sinus rhythm with no pre-excitation. This was assessed to be AT during the diagnostic electrophysiology study. A decapolar catheter (Inquiry 6 French decapolar catheter [Abbott Technologies] was placed in the coronary sinus [CS]). Three-dimensional mapping was via Ensite X

[Abbott Technologies]. Tachycardia was inducible with programmed electrical stimulation (PES) without Isuprel. Overdrive pacing from the right ventricle without terminating tachycardia resulted in “ventricular atrial atrial ventricular” response, confirming AT. AT was terminated with IV adenosine 6 mg, suggesting triggered mechanism of AT.¹

Mapping of AT was performed with Advisor™ HD Grid [Abbott Technologies] for the earliest breakout site via local activation timing

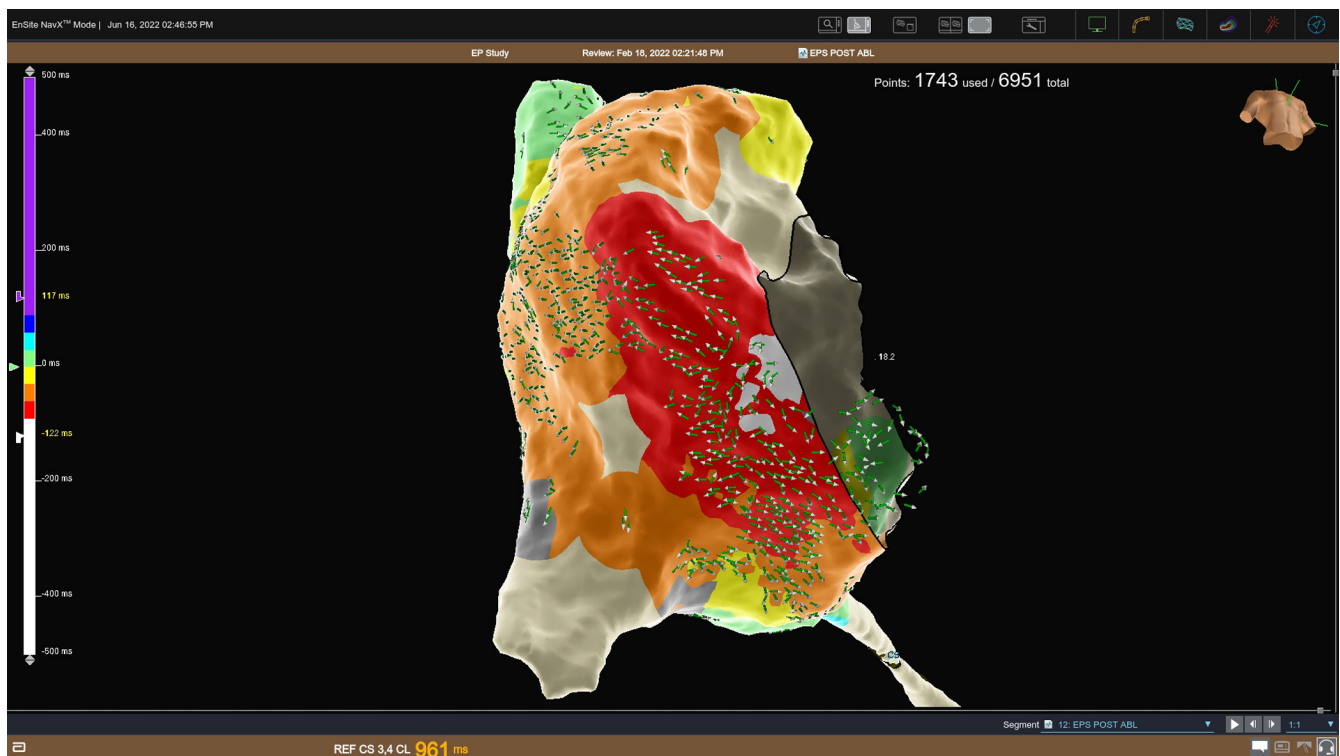


FIGURE 1 Local activation time (LAT) map of the right atrium (RA) overlaid with small arrows omnipolar technology (OT) activation vectors map demonstrating the direction of propagation during tachycardia. White on the LAT map annotates the earliest breakout site. Both maps confirm the earliest breakout site from anterior inferior RA, but OT activation vectors map allows more specific localisation.

This is an open access article under the terms of the [Creative Commons Attribution-NonCommercial-NoDerivs](https://creativecommons.org/licenses/by-nc-nd/4.0/) License, which permits use and distribution in any medium, provided the original work is properly cited, the use is non-commercial and no modifications or adaptations are made.

© 2022 The Authors. *Journal of Arrhythmia* published by John Wiley & Sons Australia, Ltd on behalf of Japanese Heart Rhythm Society.

(LAT) map and omnipolar signals (Figure 1). Bipolar high pass filter 30Hz and low pass filter 300Hz. Unipolar high pass filter 0.5 Hz and low pass filter 100Hz. LAT map is consistent with the bull's eye appearance of AT. LAT timing was changed from automatic to 122ms to produce the smallest possible breakout site on the LAT map.

Reference of AT was taken from CS 5,6. Window of interest was on atrial electrocardiogram (EGM) (Figure 2). Orthogonal bipoles B3C3 and C3C4 demonstrated consistent and early atrial EGM signals. Morphology and polarity obtained from omnipolar (C3, C4, and B3) were clearly different from orthogonal bipoles.

Both LAT and omnipolar technology (OT) activation vectors map localised the earliest breakout site of AT from the low anterior right atrium. However, the omnipolar map revealed that the earliest breakout site came from a specific spot rather than the larger area suggested by the LAT map. We targeted the earliest breakout site identified by the OT activation vectors map. A 4mm irrigated ablation catheter, Tacticath SE [Abbott Technologies] was placed at the earliest breakout spot (as identified in Figure 3). Pressure on this spot readily terminated the ongoing AT. Ablation of 30W, 60 s applied here rendered AT to be non-inducible. A total of three ablation lesions were applied. AT was non-inducible for 30 min waiting despite PES and Isuprel.

Advisor™ HD Grid is a rectangular-shaped mapping catheter of 16 electrodes equally distributed across four splines (four electrodes per spline with an interelectrode distance of 3 mm). Its algorithm uses orthogonal spaced electrodes to display EGM with greater amplitude even if the direction of propagation is perpendicular to bipolar electrodes.² This is unlike other conventional mapping catheters.

Omnipolar EGM allows freedom from wavefront directionality by utilising the spacial position of three electrodes to calculate EGM with the highest amplitude called a clique (Figure 4). Each time a wavefront moves past a clique, three unipolar, and two bipolar signals are recorded. This allows the local derivation of EGM, preserving spacial resolution. The algorithm works with the entire waveform signal around each detection without the need for a stable reference. It is able to do so because it only needs the clique's unipolar and bipolar signals.³ This allows it to be independent from cycle length variations compared to conventional LAT maps.⁴

LAT maps can be derived from either uni or bipolar signals, but the points that make up LAT maps are annotated in relation to timing from a stable reference. Multipolar mapping catheters improve the resolution of maps by increasing the density of points but remain dependent on timing reference.

Unipolar EGM is derived from the potential difference between a single electrode-tissue contact and an indifferent electrode at zero potential or Wilson Central Terminal. Thus, unipolar signals are sensitive to the direction and angle of wavefront propagation, but its near-field signal can be confused with large far-field signals. Bipolar EGM is derived from a pair of closely spaced electrode to improve the fidelity of nearfield signals but is indifferent to the direction of wavefront propagation.

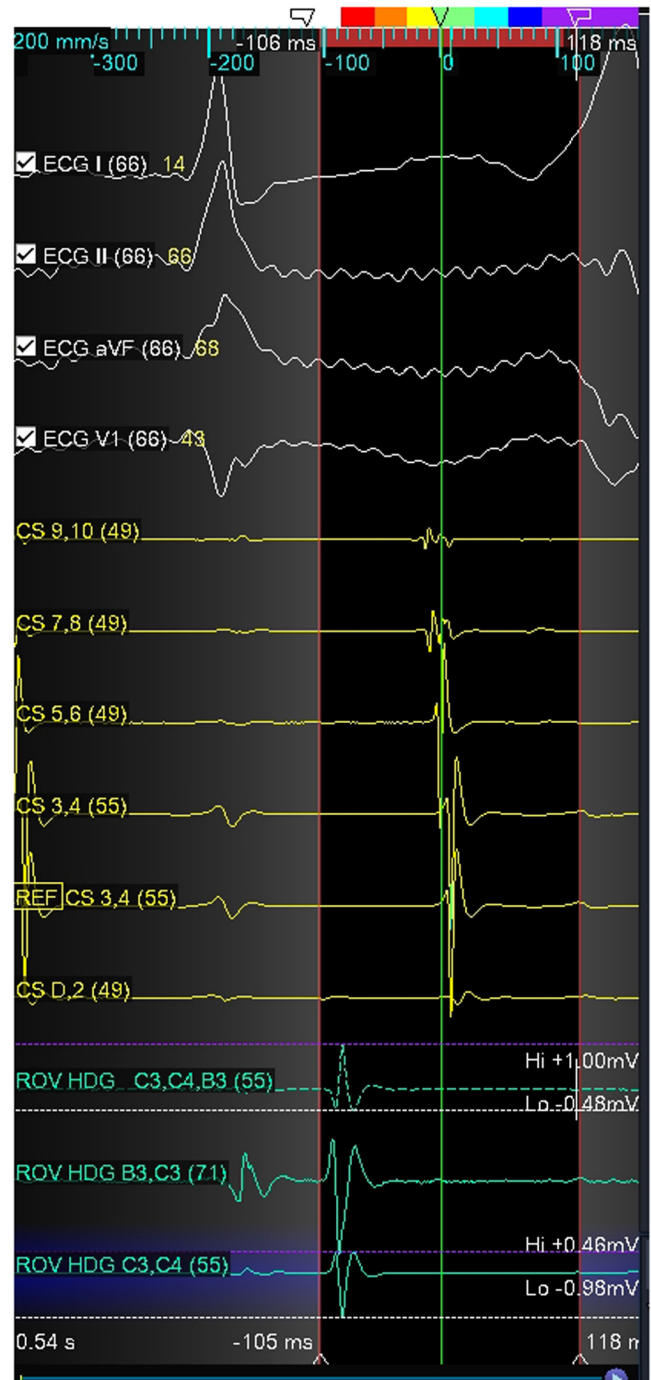


FIGURE 2 Local electrogram (EGM) of HD grid from the earliest breakout site during tachycardia (Figure 1). Reference of tachycardia was taken from CS 5,6. Window of interest was on atrial EGM. Although orthogonal bipoles B3C3 and C3C4 clearly demonstrated consistent and early atrial EGM signals, the morphology, and polarity obtained from omnipolar (C3, C4, and B3) are clearly different from orthogonal bipoles.

Activation maps derived from OT thus have several advantages. Firstly, it utilises signals from both uni and bipolar signals. This allows locally derived signals to be independent of catheter orientation, direction, and speed of wavefront. Secondly, it is independent from

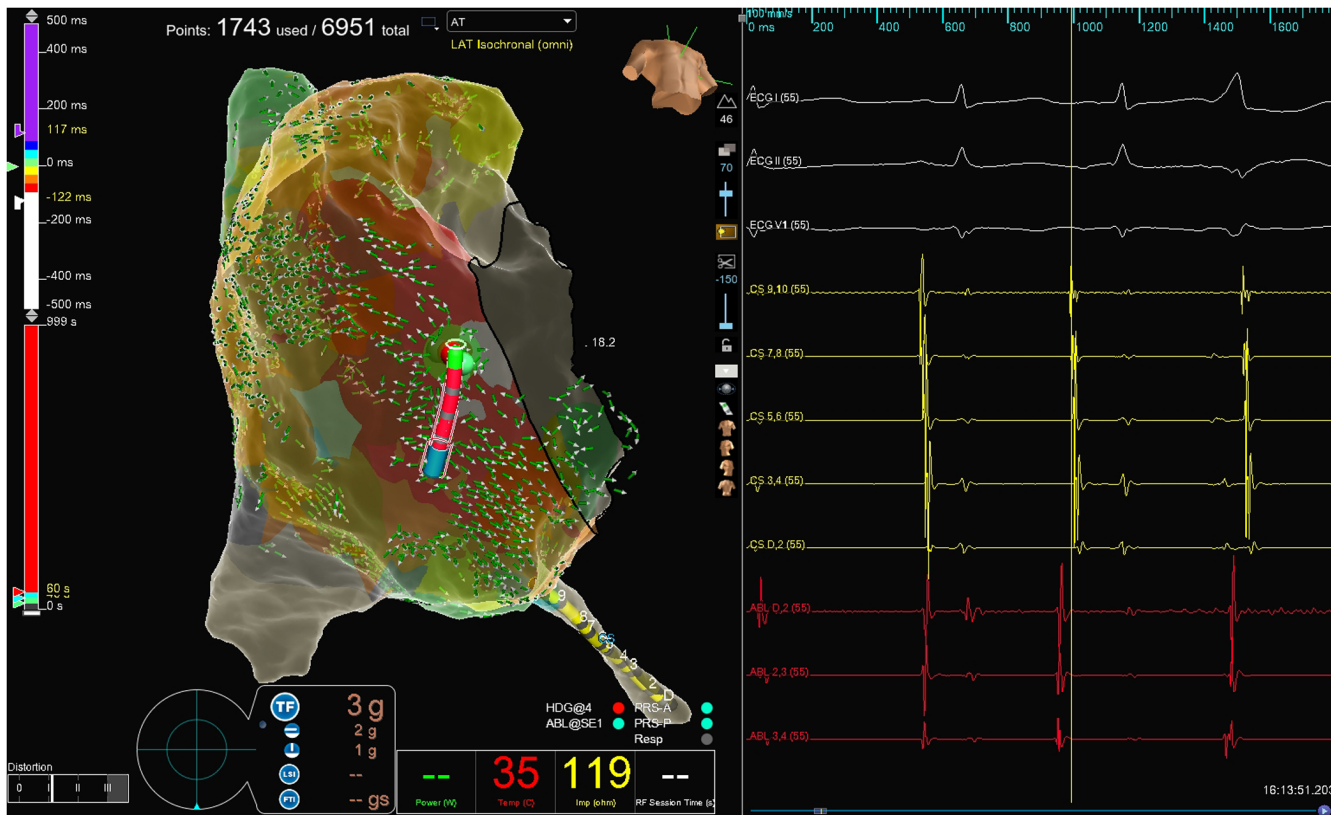

FIGURE 3 Location of ablation catheter where it bump terminated the tachycardia with corresponding local EGM recorded from ablation catheter. This was also the site of which ablation lesions were applied after tachycardia was not readily inducible.

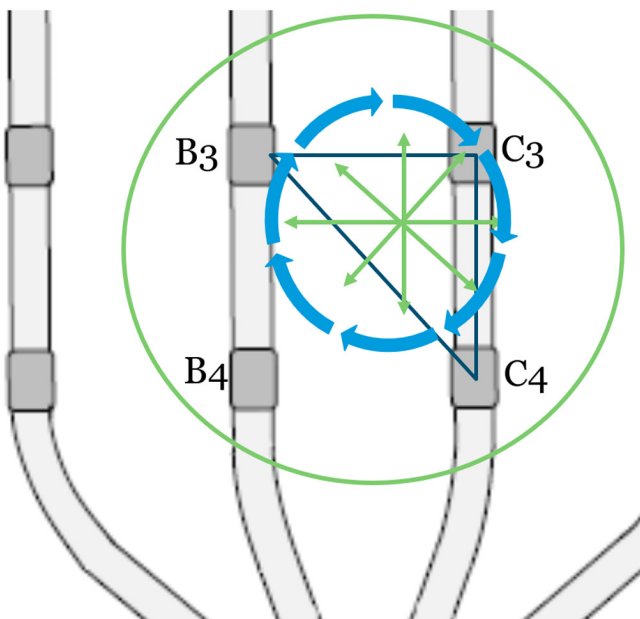


FIGURE 4 Derivation of electrocardiogram (EGM) with maximum amplitude is derived from three electrodes which are orthogonal to each other. This is known as a clique. Each time a wavefront moves past a clique, 3 unipolar, and 2 bipolar signals are recorded. Omnipolar technology (OT) allows the local derivation of EGM independent of directionality of wavefront propagation (green arrows), preserving spatial resolution, and independent of a stable reference.

fixed time reference. Each signal is derived within each clique. This is demonstrated by the difference in EGM morphology and vector as derived from omnipolar (C3, C4, and B3) as compared to bipolar (B3C3 and C3C4). This is despite having both B3C3 and C3C4 being orthogonal to each other, which takes away the effect of wavefront propagation direction. (see Figure 2).

To the best of our knowledge, this is the description of clinical case on the utility of OT activation vectors map in direct contrast with the LAT map for AT. The specificity of OT on the earliest break-out site allows a more precise and rapid resolution of AT compared to the LAT map allows it to be a promising mode of mapping. The availability of this technology with widely available commercial mapping catheter also opens up its utility to wider use.

CONFLICT OF INTEREST

Authors declare no conflict of interests for this article.

ORCID

Colin Yeo [ID https://orcid.org/0000-0002-1888-2246](https://orcid.org/0000-0002-1888-2246)
 Vern Hsen Tan [ID https://orcid.org/0000-0003-0164-7925](https://orcid.org/0000-0003-0164-7925)
 Yue Wang [ID https://orcid.org/0000-0001-7455-6405](https://orcid.org/0000-0001-7455-6405)

TWITTER

Colin Yeo [@https://twitter.com/yeocolin](https://twitter.com/yeocolin)

REFERENCES

1. Markowitz SM, Nemirovsky D, Stein KM, Mittal S, Iwai S, Shah BK, et al. Adenosine-insensitive focal atrial tachycardia: evidence for de novo micro-re-entry in the human atrium. *J Am Coll Cardiol*. 2007;49(12):1324–33.
2. Yeo C, Tan VH, Wong KCK. Pulmonary vein reconnection mapping with advisor HD grid demonstrating local EGM which were not visible on Tacticath ablation catheter. *J Arrhythm*. 2019;35(1):152–4.
3. de Groot NMS, Shah D, Boyle PM, Anter E, Clifford GD, Deisenhofer I, et al. Critical appraisal of technologies to assess electrical activity during atrial fibrillation: a position paper from the European heart rhythm association and European Society of Cardiology Working Group on eCardiology in collaboration with the Heart Rhythm Society, Asia Pacific Heart Rhythm Society, Latin American Heart Rhythm Society and computing in cardiology. *Europace*. 2022;24(2):313–30.
4. Deno DC, Bhaskaran A, Morgan DJ, Goksu F, Batman K, Olson GK, et al. High-resolution, live, directional mapping. *Heart Rhythm*. 2020;17(9):1621–8.

How to cite this article: Yeo C, Tan VH, Wang Y. Omnipolar activation EGM to identify the earliest breakout site of atrial tachycardia. *J Arrhythmia*. 2022;38:801–804. <https://doi.org/10.1002/joa3.12757>