

A Comparison of Two Types of Decalcified Freeze-Dried Bone Allograft in Treatment of Dehiscence Defects around Implants in Dogs

Ahmad Moghareh Abed¹, Rasool Heidari Pestekan², Jaber Yaghini³, Seyed Mohammad Razavi⁴,
Mohammad Tavakoli³, Mohammad Amjadi³

ABSTRACT

Background: Decalcified freeze-dried bone allograft (DFDBA) may have the potential to enhance bone formation around dental implants. Our aim in this study was the evaluation and comparison of two types of DFDBA in treatment of dehiscence defects around Euroteknika[®] implants in dogs.

Methods: In this prospective clinical trial animal study, all mandibular premolars of three Iranian dogs were extracted. After 3 months of healing, fifteen SLA type Euroteknika[®] dental implants (Nate) with 4.1mm diameter and 10mm length were placed in osteotomy sites with dehiscence defects of 5mm length, 4 mm width, and 3mm depth. Guided bone regeneration (GBR) procedures were performed using Cenobone and collagen membrane for six implants, the other six implants received Dembone and collagen membrane and the final three implants received only collagen membrane. All implants were submerged. After 4 months of healing, implants were uncovered and stability (Implant Stability Quotient) of all implants was measured. Then, block biopsies of each implant site were taken and processed for ground sectioning and histomorphometric analysis. The data was analyzed by ANOVA and Pearson tests. *P* value less than 0.05 was considered to be significant.

Results: All implants osseointegrated after 4 months. The mean values of bone to implant contact for histomorphometric measurements of Cenobone, Denobone, and control groups were $77.36 \pm 9.96\%$, $78.91 \pm 11.9\%$ and $71.56 \pm 5.61\%$ respectively, with no significant differences among the various treatment groups. The correlation of Implant Stability Quotient and histomorphometric techniques was 0.692.

Conclusion: In treating of dehiscence defects with GBR technique in this study, adding DFDBA did not significantly enhance the percentages of bone-to-implant contact measurements; and Implant Stability Quotient Resonance Frequency Analysis appeared to be a precise technique.

Keywords: Allograft, Collagen type IV, Dehiscence defects, Dental implantation, Osseointegration.

Received: January 2011

Accepted: April 2011

Dent Res J 2011; 8(3): 132-137

Introduction

Today, implant therapy is regarded as an extremely reliable approach to replace missing teeth. The introduction of osseointegrated implants in dentistry represented a turning point in dental clinical practice.¹ As a general principle in implant surgery im-

plant surfaces should be surrounded by alveolar bone.² Following loss of teeth, natural process of bone resorption occurs.³ Sometimes due to prosthetic or anatomical limitations of alveolar ridge, it is not possible to insert implants in bone appropri-

* This paper derived from a doctoral thesis and a research project in Isfahan University of Medical Sciences.

¹ Associate Professor, Department of Periodontics and Torabinejad Dental Research Center, School of Dentistry, Isfahan University of Medical Sciences, Isfahan, Iran.

² Postgraduate Student, Department of Periodontics, School of Dentistry, Isfahan University of Medical Sciences, Isfahan, Iran.

³ Assistant Professor, Department of Periodontics and Torabinejad Dental Research Center, School of Dentistry, Isfahan University of Medical Sciences, Isfahan, Iran.

⁴ Associate Professor, Department of Oral and Maxillofacial Pathology and Torabinejad Dental Research Center, School of Dentistry, Isfahan University of Medical Sciences, Isfahan, Iran.

Correspondence to: Seyed Mohammad Razavi, Email: Razavi@dnt.mui.ac.ir

ately.² And also, while preparing implant sites in narrow ridges, dehiscence or fenestration defects may occur frequently that threaten the survival of implants.⁴ Successful implant treatment depends on sufficient bone volume at the implant surface.⁵ Insufficient amount of supporting bone, will limit the effectiveness of osseointegrated dental implants³ and will have an adverse effect on dental implant prognosis.⁶ Several clinical studies have shown that to ensure long term success of implants, at least one millimetre thickness of bone in buccal surface and lingual surface of implant is essential. If the implant surface is not completely covered with bone, it will result in gingival recession, unpleasant appearance, problems in keeping good oral hygiene and ultimately increases the risk of infection around the implant.⁷ Implants can be placed in alveolar ridges with defects including dehiscence, intraalveolar defects, and fenestration.⁸

Several methods are presented to reconstruct the destroyed alveolar bone which include osteoconduction, osteoinduction and guided bone regeneration (GBR).⁶ Many surgical techniques are introduced to enhance alveolar bone volume for placing implants that include various grafting techniques, bone-building using splitting method, and expanding the bone and guided tissue regeneration (GTR).⁵ Among these techniques, GBR is widely used. GBR procedures performed in dental implants enable clinicians to increase the width and height of defected alveolar ridges or to treat fenestrations and dehiscence around implants. Many researchers have reported predictable results in the simultaneous use of GBR technique when placing implants.⁷

In most cases of GBR, membranes are supported by protective materials consisting allografts, synthetic materials and xenografts.⁶ Using autograft in augmentation has always been considered as a gold standard, but limited access to autogenous sources, particularly in the areas inside the mouth, prolongation of surgical procedures and bacterial contamination complication have always been considered as the limiting factors in autogenous transplantation. In addition, general surgical risks such as infection, bleeding, pain and swelling, damage to inferior alveolar nerve and the adjacent teeth should also be noted. Therefore, using biomaterials on its own or in combination with autogenous bone is very common.⁹ DFDBA can be named as one of the allograft materials which has osteoinductive potential, because this substance contains some major bone morphogenetic proteins (BMPs) of donor tissue

matrix. Against this view, many recent reports have shown that augmentation with DFDBA is not osteoinductive, because it does not contain the necessary BMPs to induce bone formation. In the United States, demineralized bone matrix (DBM) is considered a transplantable tissue and therefore, is regulated primarily by the American Association of Tissue Banks.¹⁰ Treatment of dehiscence and fenestration lesions with GBR technique and placing of implants simultaneously have predictable results.¹¹ Recent clinical studies have proven that the use of bone substitute materials together with placing implants led to successful coverage of pre-exposed implant surfaces.¹²

Materials and Methods

This prospective clinical trial animal study was conducted in Professor Torabinejad Dental Research Centre Isfahan University of Medical Sciences, Isfahan, Iran. Samples' dissection was carried out in the Department of Materials Science and Engineering, Sharif University of Technology, Tehran, Iran. Studied population included three healthy adult Iranian dogs that were chosen by convenient method. Inclusion criteria included healthy 2 to 4 years old dogs that held all the teeth. At the beginning of the study, the dogs were about two years old. After examination to confirm their health and having the required criteria; seven step vaccination was carried out and the dogs were quarantined for 15 days.

All the mandibular premolars teeth were extracted and then, the area was left to heal for three months. After healing period, the area assessed by periapical radiography in order to ensure full recovery, After preparing two sites on one side of each mandible and three sites on the other side which were more appropriate in terms of size and bone quality to place the implants, dehiscence bone defects, were prepared with dimensions of 5 mm apicocronaly, 4 mm mesiodistaly and 3 mm buccolingual in buccal plate using high-speed handpiece and diamond fissure bur and abundant irrigation. 10 mm periodontal probes were used to measure dimensions of the artificial dehiscence defects; all measurements were performed by a specialist investigator. Euroteknika implants with 10 mm in length, 4.1 mm in diameter and SLA surface (Natea System) inserted into the prepared sites. Implant Stability Quotient (ISQ) of each implant was recorded using Ostell device (Ostell Integration Diagnostics, Sävedalen, Sweden) which was higher than 56 % in all cases, indicating good initial stability of all implants placed.

After that in two lesions, that was chosen in random, DFDBA Cenobone, Hamanand Saz Baft, Iran and in two other lesions DFDBA Dembone, Pacific Coast Tissue Bank, U.S were placed and the fifth lesion was left empty; finally, they all were covered by collagen membranes (Bicon, USA). Both DFDBA brands were powder in sachape in 0.5 and 1 grams vials the size of the particles were almost similar and of the existing type to treat small lesions. DFDBA particles were placed in the lesions and were gently pressed against the implant; the lesion were with particles filled up in a way that all the screws were covered and the primary bone contour was maintained. Then, the grafted material and surrounded bone were covered completely by collagen membrane. Moreover, the gingival flaps were replaced without stretching to submerge the implant and were stitched by polyglycolic acid sutures (Vicryl) using simple and interrupted loop sutures. Then, final status of implants were determined by periapical radiography.

During the first week after surgery, animals were examined several times a day to control the health and complications after the operation and also to ensure the sutures are not opened. The animals' mouth was washed twice a day using 0.2 chlorhexidine mouthwashes during the first week and thereafter, once a week.

After four months of osseointegration period, dogs were anesthetized and periapical radiographs were taken to observe implants situation within the bone. Then, crestal incision was done and the implants were exposed and the value of ISQ was recorded. Samples were taken and immediately transferred to formaldehyde 10% and kept for 24 hours

to be prepared for optical microscope Study.

Samples were sectioned by with the Ground Section method using microtome (Accutom-50 cutting machine, Copenhagen, Denmark). Sectioned samples were obtained buccolingually and parallel to the axis of implants in 100 micron thickness. Sectioned samples prepared with Trichro Massons' staining studied by optical microscope (Olympus, Japon). Using histomorphometric method, the percentage of bone implant contact (BIC) was calculated and type of bone (lamellar, woven) was determined at 40 times magnification and recorded by an experienced pathologist using optical microscope. In this method, the area of 2 mm around the implants is evaluated.

SPSS 11.5 software was used to analyse data, using one-way ANOVA and Pearson correlation and regression tests. P value less than 0.05 was considered significant.

Results

In this study, all 15 implants were osseointegrated. The total sample average BIC was $76.82\% \pm 9.96$ (max 91% and min 56.3%). Average BIC in Cenobone group (Iranian DFDBA), Dembone group (American DFDBA) and control group were $77.36\% \pm 9.96$ (max 89.1% and min 63.4%), $78.91\% \pm 11.99$ (max 91% and min 56.3%) and $71.56\% \pm 5.61$ (max 75.8% and min 65.2%), respectively. There was no significant difference in BIC amounts among the three groups ($P = 0.607$).

There was not significant difference in the BIC amounts among the three groups' defects ($P=0.388$). Comparison of average BIC of lamellar bone, woven bone, Cenobone and Dembone groups' defects and control group is presented in Figure 1.

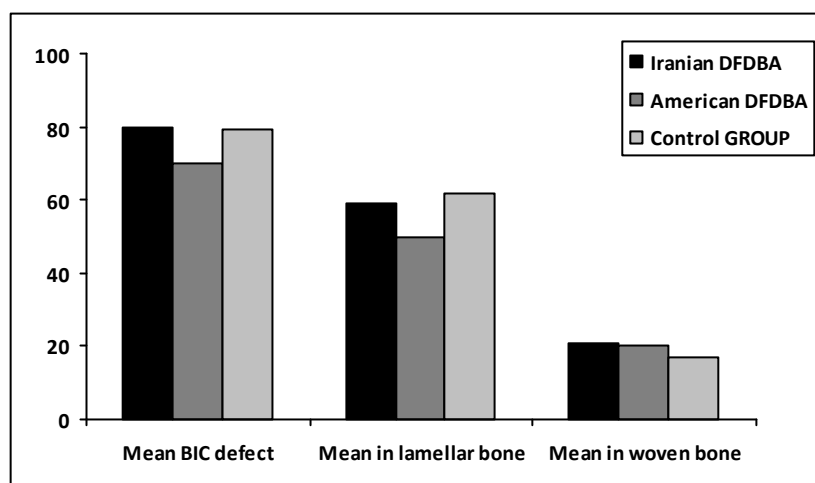


Figure 1. Comparison of average BIC of lamellar bone, woven bone, Cenobone and Dembone groups' defects and control group (lamellar bone $P = 0.298$ and woven bone $P = 0.380$).

Furthermore, there was not meaningful difference in rate of lamellar bone ($P=0.298$) and woven bone ($P = 0.380$) formation in defects among the three groups.

The total sample average ISQ was $70.83\% \pm 6.30$ (max 82.5% and min 61.5%). Average ISQ in Cenobone group, Dembone group and control group were $70.29\% \pm 7.74$ (max 82.25% and min 61.5%), $72.25\% \pm 6.81$ (max 82.5% and min 65.25%) and $69.08\% \pm 2.67$ (max 72% and min 66.75%), respectively. There was no significant difference in ISQ amounts among the three groups ($P = 0.781$).

There was a positive relationship between total sample BIC and ISQ ($P = 0.004$, $r = 0.692$).

Figure 2 and Figure 3 represent histological views of bone to implant contact.

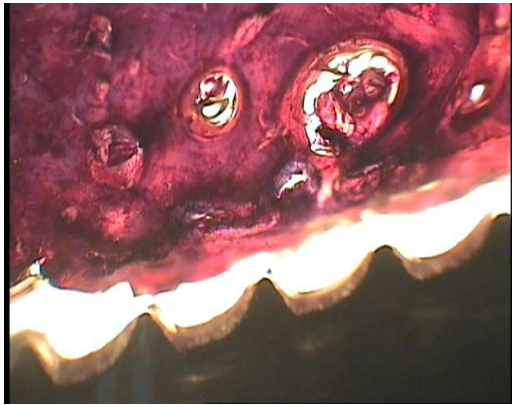


Figure 2. Histological view under light Microscope shows contact of lamellar new bone with implant in Cenobone group magnification X40 –massons's trichrom staining.

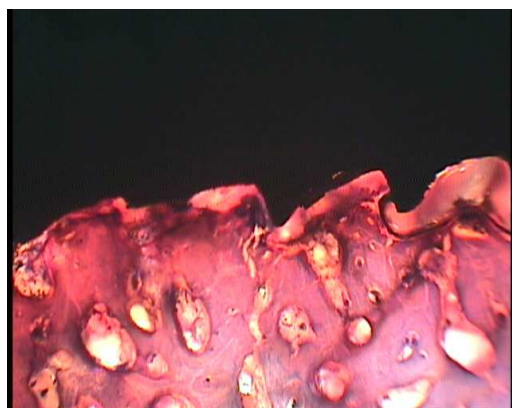


Figure 3. Histologic view under light Microscope shows contact of lamellar new bone with implant in Dembone group (magnification X40 –massons's trichromstaning).

Discussion

Results of the current study indicated that adding

DFDBA (Dembone and Cenobone) to membrane, on its own did not significantly increase the obtained BIC and ISQ amounts. Caplanis and colleagues' placed, implants in the alveolar defects which treated with membrane on its own and membrane plus DFDBA in dogs, the average BIC was about 70%¹³ which is consistent to our study. And also, the BIC obtained in this study is consistent with the findings of von Arx and colleagues' study¹⁴ that placed implants in areas grafted with DFDBA and other hybrid materials in dogs and gained a high percentage of BIC (59% to 75%).

In this study, adding DFDBA to the collagen membrane did not lead to strengthen induction of bone formation, and these findings were consistent with the results of other studies that showed adding DFDBA to the membrane on its own did not significantly increase the clinical results obtained with the GBR procedure.^{15-19,20} There were significant differences between the products of bone banks in terms of induction of bone formation. Some studies found the use of DFDBA to have a positive impact to increase bone growth while others considered it not to be beneficial.

Schwartz and colleagues have shown that there is a wide variety of DFDBA products on the market which have different inductive capabilities.²¹ These differences may be related to the origin and methods of preparation of DFDBA and if the preparation methods were the same in different bone banks, this would be due to individual donors' ages and sexes, disease and injury, medical treatment or genetic differences. Also, the variations of time between death and the bone extraction, may result in significant loss of the bone inductive ability. There are many differences in size and the surface shape of DFDBA particles that may affect their inductive ability. Bone cells distinguish different surface shapes and roughness and this will lead to differences in phenotypic diversity.²² In De Vicente and colleagues' study, the implants which the bone defects around them were filled with DFDBA showed similar BIC to the implants which their defects had just covered with collagen membranes.²³ Therefore, adding DFDBA did not have any advantages over membrane on its own, which was in line with other studies.^{15,16,19,20,24,25,26} In Stentz and colleague's study,²⁶ using DFDBA together with membrane in bone defects around implants improved the healing of the bone density. Since they had used radiographic method, the obtained information could not

determine the value of BIC, which is a better evaluating index for outcome of implant treatment and for these reason, they could not show the DFDBA efficiency to increase BIC.

Becker and colleagues²⁷ did not find the use of DFDBA beneficial for periodontal regeneration and bone regeneration around implants, while Abolfazli and colleagues found the use of DFDBA (Cenobone) beneficial to repair periodontal lesions in two or three walls alveolar bone defects and reported its effect on bone-formation being the same as autogenous bone graft. In some studies DFDBA was enriched with rhBMP-2 and growth factors and produced better results.²²⁻³⁰

The current study results indicated that the relationship between indices of BIC and ISQ was positive and significant. These findings are compatible with Huang and colleagues' study³¹ as well as Nkenke and colleagues' study³² which also found the significant and positive relationship between BIC and ISQ amounts in implants placed in human cadaver bone.

Results of this study are coincident with the findings of other researchers in efficiency of using the resonance frequency analysis method to determine the implants stability³¹⁻³³ and showed the resonance frequency analysis is a suitable and reliable method to determine implant stability.

Conclusion

Adding DFDBA (Dembone and Cenobone), either the American or Iranian type, to membrane on its own did not significantly increase the obtained BIC and ISQ with the GBR procedure. The resonance frequency analysis is still a suitable and reliable method to determine implant stability.

Acknowledgement

This article was prepared based on a doctoral thesis approved by the Medical Ethics and Research Office at the Isfahan University of Medical Sciences.

References

- Misch CE. Immediate load Application in implant dentistry. Dental implant prosthetics. China: Mosby; 2004. p. 531-67.
- Qahash M, Susin C, Polimeni G, Hall J, Wikesjo UM. Bone healing dynamics at buccal peri-implant sites. *Clin Oral Implants Res* 2008; 19(2): 166-72.
- Moses O, Pitaru S, Artzi Z, Nemcovsky CE. Healing of dehiscence-type defects in implants placed together with different barrier membranes: a comparative clinical study. *Clin Oral Implants Res* 2005; 16(2): 210-9.
- Carmagnola D, Berglundh T, Araujo M, Albrektsson T, Lindhe J. Bone healing around implants placed in a jaw defect augmented with Bio-Oss: an experimental study in dogs. *J Clin Periodontol* 2000; 27(11): 799-805.
- Hammerle CH, Jung RE, Yaman D, Lang NP. Ridge augmentation by applying bioresorbable membranes and deproteinized bovine bone mineral: a report of twelve consecutive cases. *Clin Oral Implants Res* 2008; 19(1): 19-25.
- Jung RE, Glauser R, Schärer P, Hämmerle CH, Sailer HF, Weber FE. Effect of rhBMP-2 on guided bone regeneration in humans. *Clin Oral Implants Res* 2003; 14(5): 556-68.
- Juodzbalys G, Raustia AM, Kubilius R. A 5-year follow-up study on one-stage implants inserted concomitantly with localized alveolar ridge augmentation. *J Oral Rehabil* 2007; 34(10): 781-9.
- Hämmerle CH, Lang NP. Single stage surgery combining transmucosal implant placement with guided bone regeneration and bioresorbable materials. *Clin Oral Implants Res* 2001; 12(1): 9-18.
- Boyan D, Ranly D, Schwartz Z. Use of growth factors to modify osteoinductivity of demineralized bone allografts: lessons for tissue engineering of bone. *Dent Clin N Am* 2006; 50(2): 217-28.
- Takikawa S, Bauer TW, Kambic H, Togawa D. Comparative evaluation of the osteoinductivity of two formulations of human demineralized bone matrix. *J Biomed Mater Res* 2003; 65(1): 37-42.
- Klokkevold PR. Localized Bone Augmentation and Implant site Development. In: Newman MG, Takei HH, Klokkevold PR, Carranza FA, editors. *Clinical periodontology*. USA: Saunders Co; 2006. p. 1135-47.
- Christoph HF, Jung HE, Jung RE. Ridge Augmentation Procedures. In: Lindhe J, Lang NP, Karring T, editors. *Clinical Periodontology and Implant Dentistry*. Oxford: Blackwell; 2008. p. 1084-92.
- Caplanis N, Lee MB, Zimmerman GJ, Selvig KA, Wikesjo UM. Effect of allogenic freeze-dried demineralized bone matrix on guided tissue regeneration in dogs. *J Periodontol* 1998; 69(8): 851-6.
- Von Arx T, Cochran DL, Hermann JS, Schenk RK, Higginbottom FL, Buser D. Lateral ridge augmentation and implant placement: an experimental study evaluating implant osseointegration in different augmentation materials in the canine mandible. *Int J Oral Maxillofac Implants* 2001; 16(3): 343-54.
- Aspenberg P, Lohmander LS, Thorngren KG. Failure of bone induction by bone matrix in adult monkeys. *J Bone Joint Surg Br* 1988; 70(4): 625-7.
- Paul BF, Horning GM, Hellstein JW, Schafer DR. The osteoinductive potential of demineralized freeze-dried bone allograft in human non-orthotopic sites: a

- pilot study. *J Periodontol* 2001; 72(8): 1064-8.
17. Shanaman RH. A retrospective study of 237 sites treated consecutively with guided tissue regeneration. *Int J Periodontics Restorative Dent* 1994; 14(4): 292-301.
 18. Trejo PM, Weltman R, Caffesse R. Treatment of intraosseous defects with bioabsorbable barriers alone or in combination with decalcified freeze-dried bone allograft: a randomized clinical trial. *J Periodontol* 2000; 71(12): 1852-61.
 19. De Vicente JC, Lopez-Arranz E, Lopez-Arranz JS. Tissue regeneration in bone defects adjacent to endosseous implants: an experimental pilot study. *Int J Periodontics Restorative Dent* 2000; 20(1): 41-9.
 20. Becker W, Schenk R, Higuchi K, Lekholm U, Becker BE. Variations in bone regeneration adjacent to implants augmented with barrier membranes alone or with demineralized freeze-dried bone or autologous grafts: a study in dogs. *Int J Oral Maxillofac Implants* 1995; 10(2): 143-54.
 21. Schwartz Z, Mellonig JT, Carnes DL Jr., de la Fontaine J, Cochran DL, Dean DD, et al. Ability of commercial demineralized freeze-dried bone allograft to induce new bone formation. *J Periodontol* 1996; 67(9): 918-26.
 22. Martin JY, Schwartz Z, Hummert TW, Schraub DM, Simpson J, Lankford J Jr, et al. Effect of titanium surface roughness on proliferation, differentiation, and protein synthesis of human osteoblast-like cells (MG63). *J Biomed Mater Res* 1995; 29(3): 389-401.
 23. De Vicente JC, Recio O, Martin-Villa L, Junquera LM, Lopez-Arranz JS. Histomorphometric evaluation of guided bone regeneration around implants with SLA surface: an experimental study in beagle dogs. *Int J Oral Maxillofac Surg* 2006; 35(11): 1047-53.
 24. Hürzeler MB, Quiñones CR, Morrison EC, Caffesse RG. Treatment of peri-implantitis using guided bone regeneration and bone grafts, alone or in combination, in beagle dogs. Part 1: Clinical findings and histologic observations. *Int J Oral Maxillofac Implants* 1995; 10(4): 474-84.
 25. Becker W, Clokie C, Sennerby L, Urist MR, Becker BE. Histologic findings after implantation and evaluation of different grafting materials and titanium micro screws into extraction sockets: case reports. *J Periodontol* 1998; 69(4): 414-21.
 26. Stentz WC, Mealey BL, Gunsolley JC, Waldrop TC. Effects of guided bone regeneration around commercially pure titanium and hydroxyapatite-coated dental implants. II. Histologic analysis. *J Periodontol* 1997; 68(10): 933-49.
 27. Becker W, Becker BE, Caffesse R. A comparison of demineralized freeze-dried bone and autologous bone to induce bone formation in human extraction sockets. *J Periodontol* 1994; 65(12): 1128-33.
 28. Feighan JE, Davy D, Prewett AB, Stevenson S. Induction of bone by a demineralized bone matrix gel: a study in a rat femoral defect model. *J Orthop Res* 1995; 13(6): 881-91.
 29. Martin GJ Jr, Boden SD, Titus L, Scarborough NL. New formulations of demineralized bone matrix as a more effective graft alternative in experimental posterolateral lumbar spine arthrodesis. *Spine (Phila Pa 1976)* 1999; 24(7): 637-45.
 30. Sigurdsson TJ, Nygaard L, Tatakis DN, Fu E, Turek TJ, Jin L, et al. Periodontal repair in dogs: evaluation of rhBMP-2 carriers. *Int J Periodontics Restorative Dent* 1996; 16(6): 524-37.
 31. Huang HM, Pan LC, Lee SY, Chiu CL, Fan KH, Ho KN. Assessing the implant/bone interface by using natural frequency analysis. *Oral Surg Oral Med Oral Pathol Oral Radiol Endod* 2000; 90(3): 285-91.
 32. Nkenke E, Hahn M, Weinzierl K, Radespiel-Troger M, Neukam FW, Engelke K. Implant stability and histomorphometry: a correlation study in human cadavers using stepped cylinder implants. *Clin Oral Implants Res* 2003; 14(5): 601-9.
 33. O'Sullivan D, Sennerby L, Meredith N. Measurements comparing the initial stability of five designs of dental implants: a human cadaver study. *Clin Implant Dent Relat Res* 2000; 2(2): 85-92.