

CASE REPORT

Rebleeding in aneurysm after rectal enema: Re-emphasis on careful subarachnoid hemorrhage management

Suraj Shrestha¹  | Akash Raut¹  | Sushan Homagain¹ | Gopal Sedain² | Rupesh Ramtel³¹Maharajgunj Medical Campus, Institute of Medicine, Kathmandu, Nepal²Department of Neurosurgery, Tribhuvan University Teaching Hospital, Kathmandu, Nepal³Kathmandu Medical College and Teaching Hospital, Kathmandu, Nepal**Correspondence**Suraj Shrestha, Maharajgunj Medical Campus, Institute of Medicine, Kathmandu, Nepal.
Email: multisurazz@gmail.com**Abstract**

Rebleeding in an aneurysmal subarachnoid hemorrhage (SAH) is catastrophic with high mortality and grave outcome. Meticulous management of SAH patients and the prevention of activities that might increase the chances of rebleeding are life-saving.

KEYWORDS

aneurysm, enema, rebleed, subarachnoid hemorrhage

1 | INTRODUCTION

Subarachnoid hemorrhage (SAH), considered a type of stroke, is a devastating condition in which bleeding occurs in the subarachnoid space alone or in conjunction with bleeding elsewhere in the central nervous system. Although trauma is the most common cause of SAH, ruptured saccular aneurysms represent the commonest cause of non-traumatic SAH, accounting for approximately 85% of all cases of spontaneous SAH.¹

Rebleeding after SAH is defined as a sudden clinical deterioration with signs of increased hemorrhage on the subsequent computed tomography (CT) scan.² Despite the skyrocketing advances in the field of neurosurgery, aneurysmal rebleeding still accounts for a high mortality and poor outcome in patients with SAH.³

Here, we report the case of a 60-year-old female patient with rebleed from aneurysm after administration of the rectal enema.

2 | CASE-REPORT

A 60-year-old female patient hailing from remote part of Nepal developed an episode of non-bilious vomiting,

following which she lost consciousness for about 10 min. There was no abnormal body movement. On regaining consciousness, she complained of a severe headache and pain around the nape of her neck. She had no fever or photophobia. She was a chronic smoker and had no history of hypertension or diabetes mellitus, no significant surgical history, and was not under any type of anticoagulants. She was taken to another center after a week of the initial episode and development of fever, where preliminary investigations and conservative management were done. As bleed was already a week back, the minimal SAH was missed and was managed as meningitis. Since the patient was constipated, a rectal enema was advised. A few minutes post enema, she had pressure to evacuate and went to the toilet where she collapsed and her GCS (Glasgow Coma Scale) dropped to E₁M₁V₁. Plain CT-head revealed SAH (Figure 1).

On re-examination of the previous CT done 1 day back, she had subtle signs of SAH. Following the incident, she was referred to a higher center for further management where she was intubated and admitted to the ICU. She underwent CT cerebral angiography which revealed a saccular aneurysm arising from the anterior communicating artery (ACA) (Figure 2).

She underwent right pterional craniotomy with clipping of an aneurysm. A post-operative angiogram showed severely narrowed bilateral A1 and A3 ACA and right distal M1 and M3 middle communicating arteries (MCA) with beaded appearance suggestive of post-SAH vasospasm with clip in situ (Figure 3).

The patient underwent tracheostomy for failed extubation in the same center. When the patient presented to our center, her GCS was $E_4M_5V_T$ with a 3 mm bilaterally reactive pupil, blood pressure of 130/90 mmHg, in situ double-lumen tracheostomy, and 16fr Nasogastric tube. There was bilateral weakness involving both upper and lower limbs with diminished reflex. NCCT head revealed decompensated extra-ventricular obstructive hydrocephalus with clip in situ for which the patient underwent left Kocher's Ventriculoperitoneal shunt placement. She was discharged after 60 days of hospital admission with GCS of $E_4M_5V_T$ and bilaterally reactive pupil with appropriate instructions and medications. She could not come for the follow-up amidst the COVID-19 travel restrictions. The patient succumbed to the illness after 2 months of being discharged.

3 | DISCUSSION

Rebleeding after initial SAH, occurring in about 8%–23% of patients, is an extremely serious complication with mortality rates as high as 80%.⁴ The 24-h period after the event is considered to carry the greatest risk of rebleeding as well as mortality and is more frequent within the first few hours

after initial rebleed.^{3,5} A study reported that 37% of rebleeding happened within 3–7 days of the first bleeding. A second peak is often observed after the first week, during the 11th to 12th day.⁶ Our patient developed rebleeding after a week of the initial episode.

Risk factors for rebleeding are longer time to aneurysm treatment, initial loss of consciousness, previous sentinel headaches (severe headache lasting for >1 h without the diagnosis of SAH), neurological deficit on admission, larger aneurysm size, intracerebral or intraventricular hematomas, an aneurysm in the posterior circulation, and possibly systolic blood pressure >160 mmHg.⁷ Our patient had an initial loss of consciousness, sentinel headache, and an aneurysm in the anterior circulation. In addition to the delayed presentation to a healthcare facility, she was also misdiagnosed. All these factors likely contributed to the rebleed. Elevated systolic pressure and decrease in cerebrospinal fluid (CSF) pressure which compromise the hemostatic clot likely result in the rebleeding.⁸ During defecation/micturition, the Valsalva maneuver is an essential predominant physiologic response that accompanies sudden remarkable changes in arterial blood pressure and intracranial pressure. The resulting pressure changes across the aneurysmal wall are likely to precipitate an aneurysmal rupture.⁹ Since our patient had rebleeding immediately after an enema, pressure changes during bowel evacuation might have caused rebleeding owing to the mentioned fact.

Subarachnoid hemorrhage is a serious event, timely diagnosis of which is very crucial for the intervention that can potentially decrease the rate of devastating rebleed. About 5% of patients with SAH are missed on their first presentation to an emergency department, with low acuity presentations patients at greater risk. In addition to good clinical grade, smaller hemorrhages (perhaps relating to less severe headache) and right-sided aneurysm location were independently associated with initial misdiagnosis which holds for our case.¹⁰ Also, reduced SAH volume in our case might also be explained by the gradual disappearance of the bleed on CT in due course of time. Also, due to a wide range of clinical presentations of SAH, about 25%–30% of all cases are diagnosed incorrectly. The aftereffect of which are severe with a nearly fourfold increase in the likelihood of death at 12 months and with worse functional recovery and quality of life among

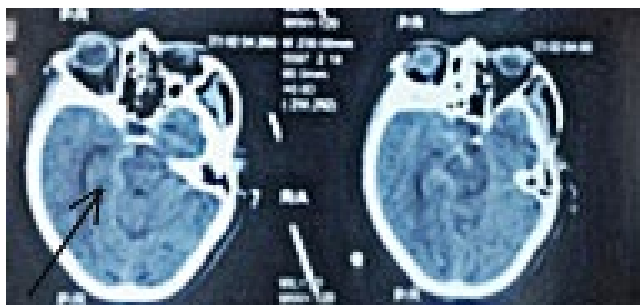


FIGURE 1 Plain CT (post-bleed) showing hyperdensity in subarachnoid space suggestive of SAH (arrow)

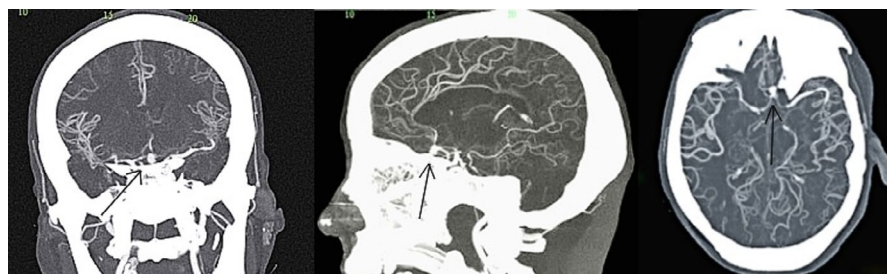

FIGURE 2 CT Cerebral Angiogram (Coronal/Sagittal/Axial view) demonstrating the ACOM aneurysm (arrow)

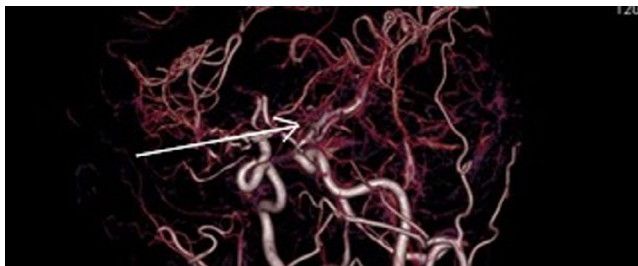


FIGURE 3 Post-operative cerebral angiography showing clip in situ (arrow)

survivors.¹¹ Moreover, the most common events following missed SAH diagnosis are rebleeding and decreased level of consciousness, both of which occurred in our case.¹¹ In addition to careful attention to presenting symptoms and signs, CT imaging (and CSF examination when necessary) should be used to exclude SAH in any patient with mild symptoms and for whom the diagnosis is a consideration.¹¹

Most of the SAH presents with an intense, sudden-onset headache that reaches maximum intensity in seconds or minutes known as a thunderclap headache. This is the only manifestation in a third of all cases, and these are the cases that are most likely to be misdiagnosed. All sudden-onset headaches with or without other symptoms should be regarded with a high level of clinical suspicion as sudden-onset headache with loss of consciousness often predicts aneurysmal hemorrhage.¹² Fever is prevalent in the majority of patients after aneurysmal subarachnoid hemorrhage and is associated with worse outcomes.¹³ Our patient had fever only after a few days because of which she was misdiagnosed as a case of meningitis.

CT scan has high sensitivity and specificity for detecting SAH within the first 6 h of bleeding accompanying the typical presentation of SAH without neck pain, syncope, and seizure.¹⁴ Our patient had syncope and neck pain. CT may be highly sensitive in the first 5 days but gradually loses sensitivity thereafter.¹² However as in our case, subtle signs of SAH may be present when observed carefully in suspected cases or cases with delayed presentation. Identification of such subtle signs can often lead to a definitive diagnosis. With the advent of modern CT scans with sensitivity nearing 100%, the role of lumbar puncture after a negative CT remains a topic of debate when clinical doubts of SAH still exist.¹⁴ However, when urgent surgical intervention is needed, as in patients with massive bleed and signs of cerebral herniation, digital subtraction angiography preferred to CT angiography.¹⁵ Our patient underwent CT angiography before securing the aneurysm.

The most effective strategies to prevent rebleeding after aneurysmal SAH are to secure the aneurysm either via surgical clipping or coil embolization, whichever appropriate, as soon as possible with a course of antifibrinolytic therapy.¹⁶

Studies have shown that emergency treatment of a ruptured aneurysm significantly decreases the chances of rebleed and also improves the clinical outcome.^{17–19} In a resource-poor setting like ours, many of the SAH patients are admitted only after few days following the ictus, and for this reason, the surgical or endovascular treatment is often delayed for up to 3 weeks post the event, increasing the risk of rebleed. Without operative intervention and antifibrinolytic treatment, an untreated aneurysm has a high rebleed risk. In addition, without intervention, annual rates of re-rupture after the first year remain high (3.5% vs. 0.11%).²⁰ Even when the surgical treatment is delayed, the use of antifibrinolytics such as aminocaproic acid decreases the risk of re-rupture.²¹

Along with bed rest, patients with SAH should remain in quiet rooms with few visitors, with the head of the bed elevated to 30° to facilitate venous drainage. It is important that patients avoid efforts that increase intracranial pressure (any symptoms of cough, nausea, and vomiting, and constipation must be treated), all of which are effective for preventing rebleeding and aids in aneurysm repair.¹² As evident from the case, Valsalva should be avoided in suspected SAH cases. Also, excessive stimulation should be minimized. The headache should be controlled. Agitated patients should be sedated with short-acting agents to the point of drowsiness, but should remain responsive for assessment of neurologic status, and over-sedation should be avoided that could mask clinical deterioration.²² Blood pressure control is particularly important: High blood pressure and rapid increases in blood pressure must be avoided. Systolic blood pressure should be kept <150 mm Hg to prevent re-rupture of the aneurysm.²³

In addition to rebleeding, delayed cerebral ischemia and delayed (up to several weeks) hydrocephalus are other dreadful complications of SAH. Delayed hydrocephalus develops in about one-fourth of surviving patients of SAH reflecting disturbed circulation of the CSF and is associated with older age, early ventriculomegaly, ventricular hemorrhage, poor clinical condition on presentation, and female gender.²⁴ At some time in the course of their disease, the patients go on to require a permanent CSF diversion procedure. Our patient underwent left Kocher's ventriculoperitoneal shunt placement for decompensated extra-ventricular obstructive hydrocephalus which she developed a few weeks post-SAH. Delayed cerebral ischemia occurs in about 30% of the cases and is the main cause of delayed morbidity and mortality.¹²

4 | CONCLUSIONS

Prompt diagnosis and proper treatment of SAH have a favorable outcome. However, a rebleeding aneurysm is catastrophic with significant morbidity and mortality. Every attempt should be made to secure the aneurysm as soon as possible along with the prevention of activities that might increase the

chances of rebleeding. In addition to careful management of SAH patients, this article emphasizes on careful evaluation of radiographic images to not miss the subtle signs indicative of SAH in patients presenting with the worst headaches.

ACKNOWLEDGMENTS

We would like to acknowledge the Department of Neurosurgery, Tribhuvan University Teaching Hospital. Published with written consent of the patient.

CONFLICT OF INTEREST

None declared.

AUTHOR CONTRIBUTIONS

SS, SH, AR, and RR were involved in the writing of the manuscript. GS reviewed the manuscript. All the authors were involved in the final review of the manuscript.

DATA AVAILABILITY STATEMENT

The data that support the findings of this study are available from the corresponding author upon reasonable request.

ORCID

Suraj Shrestha  <https://orcid.org/0000-0001-6888-260X>
Akash Raut  <https://orcid.org/0000-0003-2561-9531>

REFERENCES

- van Gijn J, Rinkel GJ. Subarachnoid haemorrhage: diagnosis, causes and management. *Brain*. 2001;124(Pt 2):249-278. <https://doi.org/10.1093/brain/124.2.249>
- Koopman I, Greving JP, van der Schaaf IC, van der Zwan A, Rinkel GJ, Vergouwen MDI. Aneurysm characteristics and risk of rebleeding after subarachnoid haemorrhage. *Eur Stroke J*. 2019;4(2):153-159. <https://doi.org/10.1177/2396987318803502>
- Cha KC, Kim JH, Kang HI, Moon BG, Lee SJ, Kim JS. Aneurysmal rebleeding: factors associated with clinical outcome in the rebleeding patients. *J Korean Neurosurg Soc*. 2010;47(2):119-123. <https://doi.org/10.3340/jkns.2010.47.2.19>
- Rosenørn J, Eskesen V, Schmidt K, Rønne F. The risk of rebleeding from ruptured intracranial aneurysms. *J Neurosurg*. 1987;67(3):329-332. <https://doi.org/10.3171/jns.1987.67.3.0329>
- Tanno Y, Homma M, Oinuma M, Kodama N, Ymamoto T. Rebleeding from ruptured intracranial aneurysms in North Eastern Province of Japan. A cooperative study. *J Neurol Sci*. 2007;258(1-2):11-16. <https://doi.org/10.1016/j.jns.2007.01.074>
- Cong W, Zhongxin Z, Tiangui L, Zhang Y, Min H, Chao Y. Risk factors for rebleeding of aneurysmal subarachnoid hemorrhage based on the analysis of on-admission information. *Turk Neurosurg*. 2012;22(6):675-681. <https://doi.org/10.5137/1019-5149.JTN.5054-11.1>
- Tang C, Zhang T-S, Zhou L-F. Risk factors for rebleeding of aneurysmal subarachnoid hemorrhage: a meta-analysis. *PLoS One*. 2014;9(6):e99536. <https://doi.org/10.1371/journal.pone.0099536>
- Rodríguez DR, Sánchez YP. Rebleeding in aneurysmal subarachnoid haemorrhage: epidemiology, risk factors, pathophysiology, diagnosis and preventive treatment. *Austin Neurosurg Open Access*. 2015;2(2):1029.
- Matsuda M, Watanabe K, Saito A, Matsumura K-I, Ichikawa M. Circumstances, activities, and events precipitating aneurysmal subarachnoid hemorrhage. *J Stroke Cerebrovasc Dis*. 2007;16(1):25-29. <https://doi.org/10.1016/j.jstrokecerebrovasdis.2006.09.001>
- Vermeulen MJ, Schull MJ. Missed diagnosis of subarachnoid hemorrhage in the emergency department. *Stroke*. 2007;38(4):1216-1221. <https://doi.org/10.1161/01.STR.0000259661.05525.9a>
- Kowalski RG, Claassen J, Kreiter KT, et al. Initial misdiagnosis and outcome after subarachnoid hemorrhage. *JAMA*. 2004;291(7):866-869. <https://doi.org/10.1001/jama.291.7.866>
- Vivancos J, Gilo F, Frutos R, et al. Clinical management guidelines for subarachnoid haemorrhage. Diagnosis and treatment. *Neurologia*. 2014;29(6):353-370. <https://doi.org/10.1016/j.nrl.2012.07.009>
- Wolf S. Take care when taking care of fever after aneurysmal subarachnoid hemorrhage. *Crit Care*. 2013;17(4):160. <https://doi.org/10.1186/cc12768>
- Dubosh NM, Bellolio MF, Rabinstein AA, Edlow JA. Sensitivity of early brain computed tomography to exclude aneurysmal subarachnoid hemorrhage: a systematic review and meta-analysis. *Stroke*. 2016;47(3):750-755. <https://doi.org/10.1161/STROKEAHA.115.011386>
- Petridis AK, Kamp MA, Cornelius JF, et al. Aneurysmal subarachnoid hemorrhage. *Dtsch Arztebl Int*. 2017;114(13):226-236. <https://doi.org/10.3238/arztebl.2017.0226>
- Connolly ES Jr, Rabinstein AA, Carhuapoma JR, et al. Guidelines for the management of aneurysmal subarachnoid hemorrhage: a guideline for healthcare professionals from the American Heart Association/American Stroke Association. *Stroke*. 2012;43(6):1711-1737. <https://doi.org/10.1161/STR.0b013e3182587839>
- Park J, Woo H, Kang D-H, et al. Formal protocol for emergency treatment of ruptured intracranial aneurysms to reduce in-hospital rebleeding and improve clinical outcomes. *J Neurosurg*. 2015;122(2):383-391. <https://doi.org/10.3171/2014.9.JNS131784>
- Wong GKC, Boet R, Ng SCP, et al. Ultra-early (within 24 hours) aneurysm treatment after subarachnoid hemorrhage. *World Neurosurg*. 2012;77(2):311-315. <https://doi.org/10.1016/j.wneu.2011.09.025>
- Grasso G, Alafaci C, Macdonald RL. Management of aneurysmal subarachnoid hemorrhage: state of the art and future perspectives. *Surg Neurol Int*. 2017;8:11. <https://doi.org/10.4103/2152-7806.198738>
- Kassell NF, Torner JC. Aneurysmal rebleeding: a preliminary report from the Cooperative Aneurysm Study. *Neurosurgery*. 1983;13(5):479-481. <https://doi.org/10.1227/00006123-19831000-00001>
- Chwajol M, Starke RM, Kim GH, Mayer SA, Connolly ES. Antifibrinolytic therapy to prevent early rebleeding after subarachnoid hemorrhage. *Neurocrit Care*. 2008;8(3):418-426. <https://doi.org/10.1007/s12028-008-9088-5>
- Diringer MN. Management of aneurysmal subarachnoid hemorrhage. *Crit Care Med*. 2009;37(2):432-440. <https://doi.org/10.1097/CCM.0b013e318195865a>

23. Owens WB. Blood pressure control in acute cerebrovascular disease. *J Clin Hypertens*. 2011;13(3):205-211. <https://doi.org/10.1111/j.1751-7176.2010.00394.x>
24. Hirashima Y, Hamada H, Hayashi N, Kuwayama N, Origasa H, Endo S. Independent predictors of late hydrocephalus in patients with aneurysmal subarachnoid hemorrhage—analysis by multivariate logistic regression model. *Cerebrovasc Dis*. 2003;16(3):205-210. <https://doi.org/10.1159/000071117>

How to cite this article: Shrestha S, Raut A, Homagain S, Sedain G, Ramtel R. Rebleeding in aneurysm after rectal enema: Re-emphasis on careful subarachnoid hemorrhage management. *Clin Case Rep*. 2021;9:e04538. <https://doi.org/10.1002/ccr3.4538>