

## Effects of *Escherichia coli* strain Nissle 1917 on arsenic-challenged goldfish (*Carassius auratus*): histological evidence

Katayoon Nofouzi<sup>1\*</sup>, Najmeh Sheikhzadeh<sup>2</sup>, Gholamreza Hamidian<sup>3</sup>, Amir Ali Shahbazfar<sup>1</sup>, Amin Marandi<sup>4</sup>

<sup>1</sup> Department of Pathobiology, Faculty of Veterinary Medicine, University of Tabriz, Tabriz, Iran; <sup>2</sup> Department of Food Hygiene and Aquatic Animals, Faculty of Veterinary Medicine, University of Tabriz, Tabriz, Iran; <sup>3</sup> Department of Basic Sciences, Faculty of Veterinary Medicine, University of Tabriz, Tabriz, Iran;

<sup>4</sup> Department of Aquatic Animal Health, Faculty of Veterinary Medicine, University of Tehran, Tehran, Iran.

Article Info	Abstract
<b>Article history:</b>  Received: 23 July 2022 Accepted: 16 October 2022 Available online: 15 July 2023	Arsenic (As) contamination in natural water resources has become a great disaster throughout the world posing serious health problems. The current study was performed to evaluate the protective effects of <i>Escherichia coli</i> strain Nissle 1917 (EcN) against As exposure in goldfish ( <i>Carassius auratus</i> ). Fish were fed three times a day with 4.00% of body weight of diet with different doses (0.00, $1.00 \times 10^6$ , $1.00 \times 10^7$ and $1.00 \times 10^8$ CFU g <sup>-1</sup> ) of EcN for 80 days and then, challenged with 20.00 mg L <sup>-1</sup> As for 96 hr under stagnant flow. Physicochemical characteristics of the inlet water were temperature of $25.10 \pm 0.70$ °C, pH of $7.30 \pm 0.20$ and dissolved oxygen of $7.30 \pm 0.30$ mg L <sup>-1</sup> and 50.00% of water was exchanged once a week. Afterwards, fish were euthanized with a clove oil solution (50.00 µL L <sup>-1</sup> ) and tissues were dissected from each fish and immediately fixed in 10.00% buffered formalin. The histopathological results indicated that the supplemented EcN did not have any side effects on various organs. It was also observed that the damages to kidney, liver, gill and skin were pronounced in fish exposed to As. However, the histopathological damages induced by As in fish tissues were less pronounced in the EcN-treated groups compared to the fish fed with the basal diet. Lamellar blood congestion in gills and epidermal cells detachment from the skin surface as well as hepatocytes, enterocytes and tubular necrosis were reduced in treated groups. These findings indicate that EcN has the potential to ameliorate the As-induced organ toxicity.
<b>Keywords:</b>  Arsenic <i>Escherichia coli</i> strain Nissle 1917 Goldfish Histopathology Probiotics	

© 2023 Urmia University. All rights reserved.

### Introduction

Arsenic (As) is ranked as the first substance in the list of hazardous substances and widely distributed in freshwater sediment as a result of anthropogenic and natural processes.<sup>1</sup> The available data indicate that the highest level of toxicity is found in inorganic forms of As; whereas, organo-arsenicals are considered to have a lower toxicity.<sup>2</sup> Most organs affected by As are the ones with a role in absorption, accumulation and/or excretion, i.e., circulatory system and gastrointestinal tract organs as well as liver, skin and kidney.<sup>3</sup> High levels of As in the aquatic ecosystem affect various physiological activities, namely smoltification, reproduction, ion regulation, growth, immune function and enzyme activities of fish species.<sup>4</sup>

One of the best identified and documented probiotic micro-organisms is strain Nissle 1917 (EcN). It belongs to

the *Escherichia coli* serotype O6:K5:H1 which Alfred Nissle was able to isolate from a healthy soldier during a diarrhea outbreak during world war one.<sup>5</sup> The EcN persistently colonizes its hosts and is found capable of synthesizing anti-microbial products such as microcins and bacteriocins, modulating host immune responses and participating in comparative exclusion of pathogens.<sup>6</sup> Moreover, EcN interacts with intestinal epithelial cells to express proteins which mediate normal gut barrier functions, regulate gut permeability and improve mucosal integrity.<sup>7</sup> Therefore, EcN has plentiful of positive probiotic properties that can benefit the overall gut health. Furthermore, it can protect the organs against enteric infections. Despite the vast studies in human, few investigations were performed in fish species. For example, dietary EcN could enhance the systemic immune responses in the Nile tilapia (*Oreochromis niloticus*).<sup>8</sup> Besides, our previous study

#### \*Correspondence:

Katayoon Nofouzi. DVM, PhD  
Department of Pathobiology, Faculty of Veterinary Medicine, University of Tabriz, Tabriz, Iran  
E-mail: nofouzi@tabrizu.ac.ir



This work is licensed under a Creative Commons Attribution-NonCommercial-ShareAlike 4.0 International (CC BY-NC-SA 4.0) which allows users to read, copy, distribute and make derivative works for non-commercial purposes from the material, as long as the author of the original work is cited properly.

showed that EcN had the potential to enhance growth performance, adjust digestive enzymatic and heterotrophic bacteria and provide immunostimulation and resistance against *Aeromonas hydrophila* in goldfish (*Carassius auratus*; unpublished data).

Regarding the constant addition of this compound into the water in one side and the potential of this probiotic in human and animal health on the other side,<sup>9</sup> we performed an *in vivo* experiment to investigate the dynamic effects of As exposure in goldfish following EcN administration. Goldfish was selected as a model because of its round the year availability, adaptability to laboratory conditions and the fact that it is easily affected by different contaminations. The goal of this study was to look into the ameliorating effects of EcN on histopathological damages of different organs including intestine, kidney, liver, skin and gill caused by As.

## Materials and Methods

**Experimental diet.** The EcN prepared from Pharma-Zentrale Company (Herdecke, Germany) was cultured in Luria-Bertani broth (Himedia, Mumbai, India) at 37.00 °C. After overnight incubation with shaking, probiotic EcN cells were centrifuged (2,500 *g*, 15 min), suspended in phosphate buffer saline and finally adjusted to different concentrations (0.00, 1.00 × 10<sup>6</sup>, 1.00 × 10<sup>7</sup> and 1.00 × 10<sup>8</sup> CFU g<sup>-1</sup>). The bacterial suspensions were added to the control diet (Table 1) and re-pelleting was performed.<sup>10</sup> The final pellets were exposed to room temperature to be dried and stored inside airtight packaging at 4.00 °C for weekly use. After batch preparation, the viability of probiotic cells in each group was determined by culturing on Luria-Bertani broth to be over 96.00%. Probiotic bacteria were also amplified from the main stocks frozen at - 80.00 °C to prevent genetic instability.<sup>11</sup>

**Table 1.** Proximate composition of control diet used in this study.

Ingredient	Amount (g kg <sup>-1</sup> )
Kilka fish meal <sup>a</sup>	300
Wheat flour	240
Soybean meal <sup>b</sup>	310
Cottonseed meal	100
Cellulose	10.00
Vitamin pre-mix*	20.00
Mineral pre-mix*	20.00
<b>Chemical composition (% dry matter)</b>	
Dry matter	88.50
Crude protein	37.07
Crude lipid	8.54
Ash	6.55
Gross energy (kcal kg <sup>-1</sup> )	4,159.97

<sup>ab</sup> Crude protein: 60.60 and 44.20%, respectively.

\* Mixture detailed by Mousavi *et al.*<sup>12</sup>

**Fish.** Healthy goldfish (1.81 ± 0.02 g and 2.84 ± 0.02 cm) purchased from a private fish farm in Qom, Iran, were kept in a commercial fish farm in Marand, Iran. Fish were adapted to the experimental situation for 10 days and fed with the control diet. Next, the fish were randomly allotted and placed into 12 glass tanks (300 L) with 10 fish stocked in each tank with properly aerating. Physicochemical characteristics of the inlet water to the tanks were as follows: Temperature: 25.10 ± 0.70 °C, pH: 7.30 ± 0.20 and dissolved oxygen: 7.30 ± 0.30 mg L<sup>-1</sup>. About 30.00% of the water in each tank was exchanged every two days to reduce water fouling. During the experiment, each three tanks (n = 30) were allocated to one treatment group and fed with different doses of EcN (0.00, 1.00 × 10<sup>6</sup>, 1.00 × 10<sup>7</sup> and 1.00 × 10<sup>8</sup> CFU g<sup>-1</sup>), namely EcN0, EcN1, EcN2 and EcN3, for 80 days up to apparent satiation.<sup>13</sup> The fish care and handling procedures in this study were approved by the Animal Experimentation Committee of the Tabriz University, Tabriz, Iran (IR.TABRIZU.REC.1398.035).

**Challenge with arsenic.** After 80 days of feeding with probiotic cells, the fish in the experimental aquaria were exposed to a sub-lethal arsenic trioxide (Sigma-Aldrich, St. Louis, USA) concentration of 20.00 mg L<sup>-1</sup>,<sup>2</sup> being prepared as a stock solution and added depending on the volume of each aquarium to achieve the required concentration for a period of 96 hr. The exposure solution was renewed every 24 hr. In this bioassay test, the water in the tanks was controlled daily to be the same as the feeding trial. Two control groups, a negative control without probiotics or As and a positive control with As but without EcN (negative control fish were kept in As-free water and fed the basal diet and positive control fish were kept in As water and fed the probiotics-free diet), were considered.<sup>14</sup> After the challenge test, fish in different groups (EcN0, EcN1, EcN2 and EcN3) were euthanized with a clove oil solution (50.00 µL L<sup>-1</sup>).<sup>15</sup> Afterwards, tissues including intestine, kidney, liver, skin and gill from all fish of each group were dissected from each fish, immediately fixed in 10.00% buffered formalin for 24 hr and embedded in paraffin wax for histopathological analyses.<sup>16</sup>

**Histological analysis.** Each block of fixed samples was divided into four 20.00-µm thick serial sections and then, four 5.00 µm thin serial sections were prepared by a rotary microtome (Leica, Munich, Germany). The sections were gathered on slides and then, stained using Hematoxylin and Eosin. Histological sections were studied using light microscopy to evaluate the structure of the tissues. Five fields from each section were photographed at 200× magnification and then, recorded utilizing BX-60 Olympus microscope equipped with an Olympus DP 12 digital camera (Olympus Corp., Tokyo, Japan).<sup>17</sup>

**Stereological and histomorphometrical studies.** Stereological studies were conducted under rigidity blind

conditions using the optical fractionator Stereo- Investigator software (version 9.0; MicroBrightField Inc., Wetzlar, Germany). This system is made up of a motorized stage, standard microscope, digital camera and a computer application. This program commands automatic XY movements of the microscope stage, making the systematic randomized sampling of tissue microscopical fields possible. The program produces graphical images of the nucleators, dissectors and point grids super-imposed on the tissue samples on a monitor.<sup>18</sup> The thickness of skin epidermis was measured in three zones and the average thickness was reported for every part. For the evaluation of goblet cell density in the skin epidermis, the number of these cells present in 1.00 mm was identified.<sup>19</sup> The approximate goblet cell volumetric density in the epidermis was calculated using the point counting technique.

**Statistical analysis.** All values were reported as mean  $\pm$  standard error of the mean (SEM). The data were applied to the Kolmogorov-Simimov test to confirm the data normal distribution and the Levene tests, to verify the homogeneity of variances. Different groups were compared by one way analysis of variance and Tukey's post hoc test in SPSS Software (version 22.0; IBM Corp., Armonk, USA), when significant differences among means were discovered. Probabilities of  $p < 0.05$  were considered as significant.

## Results

**Histopathological analysis.** Challenging the fish with As caused enterocytes necrosis, especially in the apex of villi in foregut in the EcN0 and EcN1 groups. In comparison, fish in the EcN2 and EcN3 groups presented improvements in villi architecture and an increase in villi height and goblet cell percentage compared to the EcN0 group (Fig. 1). Lesions in gills were quantified as follow: Score 0: Normal; score 1: Slight lamellar congestion; score 2: Moderate lamellar congestion and score 3: Severe lamellar congestion. In the control group, gill tissue showed a normal histology. Challenging the fish with As caused lamellar congestion in the EcN0 (score 3) and EcN1 (score 2) groups. In comparison, fish in the EcN2 (score 2) and EcN3 (score 1) groups presented improvements in primary and secondary lamellar architectures (Fig. 1). Skin tissue and epidermal thickness appeared normal in the control

group; however, in the EcN0 group, detachment of epidermal cells from the skin surface, degenerative changes and vacuolation in epidermal cells were observed. In the EcN1 group, partial improvement in epidermal tissue and regeneration of secretory cells in the middle and superficial layers of epidermis were noted. In the EcN2 group, improvement in epidermal tissue architecture was observed compared to the EcN1 group. In the EcN3 group, recovery of volume, number and architecture of epidermal cells and tissue restoration were observed (Fig. 1).

No pathological lesions were observed in the hepatic tissues of the control group. Conversely, vasodilatation, fatty change and scattered necrosis of hepatocytes in the form of pyknosis and karyorrhexis and hyperemia in sinusoids were observed in the liver of fish in the EcN0 group. In the EcN1 group, hepatocytes vacuolation (fatty change) and scattered pyknosis were less significant compared to the EcN0 group. In the higher dose of EcN administration, especially in the EcN3 group, a slight fatty change was visible, showing the protective effects of EcN in hepatic tissues (Fig. 1).

Renal tissue appeared normal in negative control group; however, in the EcN0 group, hyperemia and hemorrhage in interstitial connective tissue and tubular necrosis with pyknosis of the nuclei in the tubular epithelial cells were observed. In the EcN1 group, hyperemia, destruction and vacuole formation in the renal tubular epithelium and scattered infiltration of lymphocytes in interstitial tissue were noted. In the EcN2 group, hyperemia and improvement in tubular architecture were observed. In the EcN3 group, slight hyperemia and improvement in renal architecture were also noted (Fig. 1).

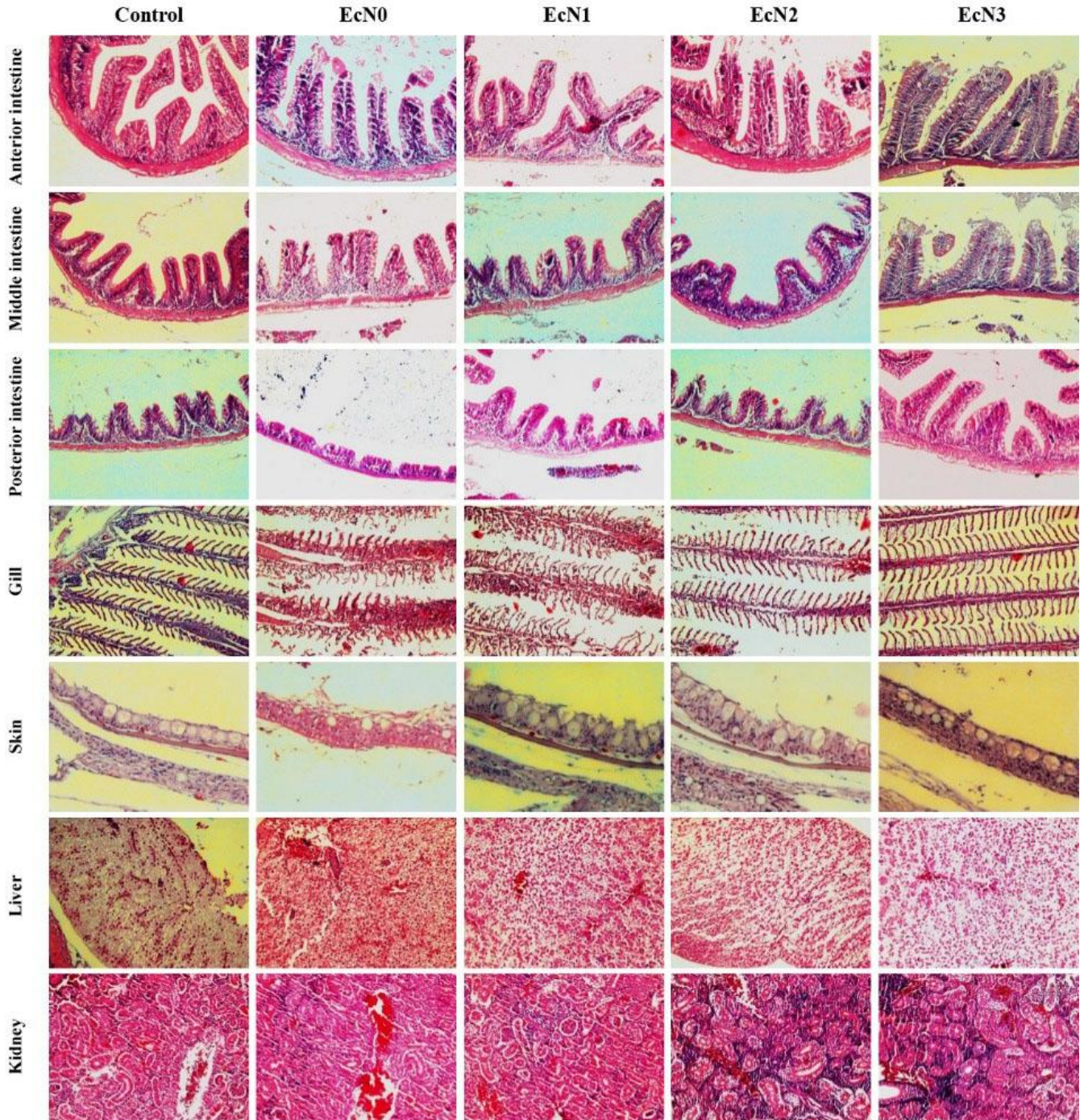
**Skin epithelium thickness and goblet cell density.** The effects of As challenge after EcN administration on skin mucous cells of *C. auratus* were presented in Table 2. Challenging the goldfish with As caused lower epidermis thickness in EcN0 group compared to the control group. However, the increase in goblet cell density in the skin epithelium was highly significant ( $p < 0.05$ ) in all experimental groups compared to the EcN0 group. Meanwhile, goblet cell volume density showed the same pattern in a way that in the treated groups including EcN1, EcN2 and EcN3, higher goblet cell volume density was observed compared to the EcN0 group (Table 2).

**Table 2.** Skin epidermal thickness, goblet cell density and goblet cell volume density of gold fish in different experimental groups.

Parameters	Control	EcN0	EcN1	EcN2	EcN3
Epidermis thickness ( $\mu\text{m}$ )	44.00 $\pm$ 1.87 <sup>b</sup>	32.00 $\pm$ 2.55 <sup>a</sup>	43.00 $\pm$ 1.22 <sup>b</sup>	47.00 $\pm$ 1.22 <sup>b</sup>	45.00 $\pm$ 1.58 <sup>b</sup>
Goblet cell density (number per cm)	248.00 $\pm$ 5.15 <sup>bc</sup>	118.00 $\pm$ 4.64 <sup>a</sup>	232.00 $\pm$ 8.00 <sup>b</sup>	263.00 $\pm$ 3.74 <sup>c</sup>	264.00 $\pm$ 4.30 <sup>c</sup>
Goblet cell volume density (%)	37.40 $\pm$ 1.03 <sup>bc</sup>	18.80 $\pm$ 2.48 <sup>a</sup>	34.60 $\pm$ 2.54 <sup>b</sup>	45.20 $\pm$ 1.77 <sup>c</sup>	39.40 $\pm$ 2.29 <sup>bc</sup>

EcN0: 0.00, EcN1:  $1.00 \times 10^6$  CFU g<sup>-1</sup>, EcN2:  $1.00 \times 10^7$  CFU g<sup>-1</sup> and EcN3:  $1.00 \times 10^8$  CFU g<sup>-1</sup>.

<sup>abc</sup> Data within a row superscripted by different letters are significantly different ( $p < 0.05$ ).



**Fig. 1.** Cross-sections of goldfish tissues after administration of *Escherichia coli* strain Nissle 1917 bacterium (EcN) for 60 days and exposure to arsenic through diet being compared to those of the control group and the group without receiving arsenic (Hematoxylin and Eosin staining, 200 $\times$ ). EcN0: 0.00, EcN1:  $1.00 \times 10^6$  CFU g $^{-1}$ , EcN2:  $1.00 \times 10^7$  CFU g $^{-1}$  and EcN3:  $1.00 \times 10^8$  CFU g $^{-1}$ .

## Discussion

Waterborne As remarkably accumulates in specific organs, e.g., liver, gill, kidney and intestine, and manipulates growth in fish.<sup>18,19</sup> Amongst these organs, the kidneys and liver are vital ones in vertebrates carrying out detoxification mechanisms, nitrogenous waste excretion,

homeostatic functions and protein synthesis. As the gill has a steeper sigmoid profile than liver, it is the more sensitive of the two when fish are exposed to waterborne As. The gill is a key accumulation site for numerous transition metals.<sup>20</sup> Gills are also the primary locations of toxicity, since metal-induced mortality in freshwater fish occurs via the distribution of branchial ion regulation.<sup>21</sup>

Acute and sub-acute effects of As may reach numerous fish body systems such as the gastrointestinal, nervous, cardiovascular, respiratory and hematopoietic systems. Arsenic accumulation in tissues will be a function of the uptake and clearance rates of individual organs. Sub-lethal effects, namely gall bladder inflammation, anemia and liver degeneration were detected in aquatic organisms.<sup>22</sup> Challenging the fish with As could cause severe damages in kidneys, liver, skin, intestine and gills, based on the results of our study; whereas, EcN particularly at  $1.00 \times 10^8$  CFU  $g^{-1}$ , could mitigate As-induced pathological lesions in the liver, kidney, skin, intestine and gills. Similar results were obtained by other researchers.<sup>23,24</sup>

Over the past decades, some researchers have investigated the different aspects of the probiotic administration, affecting fish anti-oxidant systems through different mechanisms:<sup>25</sup> The production of anti-oxidant metabolites and prevention of reactive oxygen species (ROS) generation are the main mechanisms of action. The beneficial effects of various probiotics in the improvement of anti-oxidant systems and ROS production reduction in different organs are well documented.<sup>26-29</sup> Previous studies have shown that Nrf2-Keap1 signaling pathway has an important role in the anti-oxidant system through balancing the expression of anti-oxidant genes.<sup>30</sup> Higher expressions of Keap1 and Nrf2 genes were observed in different tissues following probiotic administration, being accompanied by a higher expression of anti-oxidant-related genes, alongside with anti-oxidant property.<sup>31</sup> Previous studies have also proved that K5 polysaccharide present in EcN is responsible for mediating the interaction between this probiotic and intestinal cells as well as chemokine induction.<sup>32</sup>

Modulation of gut microbiota is another mechanism of probiotic action. It was shown that probiotics are able to regulate the microbial composition in fish intestine and help oxidative stresses mitigation through lowering harmful bacteria.<sup>31</sup> Some probiotics are also able to chelate metal ions. For example, it was proven that some lactic acid bacteria have the ability to chelate some metal ions including iron and copper ions.<sup>30</sup> Therefore, future studies exploring the detailed EcN probion mechanism of actions are needed to understand how this probiotic can mitigate the oxidative stress caused by As in goldfish.

Mucous cells located in the epidermis are required for mucus production.<sup>32</sup> Mucus mostly consists of mucins, which either bind to the outer layer of epidermis and create an additional defensive layer with the goal of protecting epithelial cells, or form viscous gel preventing microbial penetration.<sup>33</sup> The probiotic induced increase of goblet cell density, indicating an activation of skin mucosal response.<sup>32</sup> Our results cleared that the application of EcN in goldfish diet provides adequate protection against As toxicity. This study demonstrated that EcN is efficient in enhancing the histological structure and function of fish

skin. Further research is required to clarify the mechanisms by which EcN can influence general and mucosal immunities.

In general, challenging the fish with As could cause severe damage in different organs including intestine, kidney, liver, gill and skin of goldfish. Based on the results of this study, EcN probiotic, particularly at  $1.00 \times 10^8$  CFU  $g^{-1}$ , could mitigate As-induced pathological lesions in the mentioned tissues. Therefore, EcN can be considered as a potential feed additive against As-induced toxicity even though complementary studies focusing on the anti-oxidant responses of tissues are warranted.

### Acknowledgments

The authors are grateful for funding support from the Research affairs of the University of Tabriz, Tabriz, Iran.

### Conflict of interest

The authors had no conflict of interests to report.

### References

1. Cui D, Zhang P, Li H, et al. The dynamic effects of different inorganic arsenic species in crucian carp (*Carassius auratus*) liver during chronic dietborne exposure: bioaccumulation, biotransformation and oxidative stress. *Sci Total Environ* 2020; 727: 138737. doi: 10.1016/j.scitotenv.2020.138737.
2. Kumari B, Kumar V, Sinha AK, et al. Toxicology of arsenic in fish and aquatic systems. *Environ Chem Lett* 2017; doi: 10.1007/s10311-016-0588-9.
3. Lavanya S, Ramesh M, Kavitha C, et al. Hematological, biochemical, and ionoregulatory responses of Indian major carp *Catla* during chronic sublethal exposure to inorganic arsenic. *Chemosphere* 2011; 82(7): 977-985.
4. Pedlar RM, Ptashynski MD, Evans R, et al. Toxicological effects of dietary arsenic exposure in Lake Whitefish (*Coregonus clupeaformis*). *Aquat Toxicol* 2002; 57(3): 167-189.
5. Barth S, Dunker S, Hempe J, et al. *Escherichia coli* Nissle 1917 for probiotic use in piglets: evidence for intestinal colonization. *J Appl Microbiol* 2009; 107(5): 1697-1710.
6. Helmy YA, Kassem II, Kumar A, et al. *In vitro* evaluation of the impact of the probiotic *E. coli* Nissle 1917 on *Campylobacter jejuni*'s invasion and intracellular survival in human colonic cells. *Front Microbiol* 2017; 8: 1588. doi: 10.3389/fmicb.2017.01588.
7. Zyrek AA, Cichon C, Helms S, et al. Molecular mechanisms underlying the probiotic effects of *Escherichia coli* Nissle 1917 involve ZO-2 and PKCzeta redistribution resulting in tight junction and epithelial barrier repair. *Cell Microbiol* 2007; 9(3): 804-816.
8. ZeinEddine R, Nasser N, Kassem I, et al. Effect of the

- human probiotic bacterium *Escherichia coli* Nissle (1917) on performance and immune response of Nile tilapia *Oreochromis niloticus*. *J Appl Aquac* 2022; 34(3): 527-541.
9. Mandal P. An insight of environmental contamination of arsenic on animal health. *Emerg Contam* 2017; 3(1): 17-22.
  10. Ahmadifar E, Heydari Sadegh T, Dawood MAO, et al. The effects of dietary *Pediococcus pentosaceus* on growth performance, hemato-immunological parameters and digestive enzyme activities of common carp (*Cyprinus carpio*). *Aquaculture* 2020; 516: 734656. doi: 10.1016/j.aquaculture.2019.734656.
  11. Hayati A, Pramudya M, Soepriandono H. The ability of probiotics to ameliorate blood and gonad damage caused by copper toxicity in Nile tilapia (*Oreochromis niloticus*). *Vet World* 2021; 14(11): 2964-2970.
  12. Mousavi S, Sheikhzadeh N, Hamidian G, et al. Changes in rainbow trout (*Oncorhynchus mykiss*) growth and mucosal immune parameters after dietary administration of grape (*Vitis vinifera*) seed extract. *Fish Physiol Biochem* 2021; 47(2): 547-563.
  13. Correia AM, Pedrazzani AS, Mendonça RC, et al. Basil, tea tree and clove essential oils as analgesics and anaesthetics in *Amphiprion clarkii* (Bennett, 1830). *Braz J Biol* 2017; doi: 10.1590/1519-6984.166695.
  14. Kim RK, Fitzgerald SD, Kiupel M, et al. Tissue distribution of the piscine novirhabdovirus genotype IVb in Muskellunge (*Esox masquinongy*). *Animals (Basel)* 2022; 12(13): 1624. doi: 10.3390/ani12131624.
  15. Hamidian GH, Zirak K, Sheikhzadeh N, et al. Intestinal histology and stereology in rainbow trout (*Oncorhynchus mykiss*) administrated with nano-chitosan/zeolite and chitosan/zeolite composites. *Aquac Res* 2018; 49(5): 1803-1815.
  16. Kretz A, Barger N. Maximizing explanatory power in stereological data collection: A protocol for reliably integrating optical fractionator and multiple immunofluorescence techniques. *Front Neuroanat* 2018; 12: 73. doi: 10.3389/fnana.2018.00073.
  17. Heidarieh M, Mirvaghefi AR, Sepahi A, et al. Effects of dietary Aloe vera on growth performance, skin and gastrointestinal morphology in rainbow trout (*Oncorhynchus mykiss*). *Turkish J Fish Aquat Sci* 2013; 13: 367-373.
  18. Liao CM, Tsai JW, Ling MP, et al. Organ-specific toxicokinetics and dose-response of arsenic in tilapia *Oreochromis mossambicus*. *Arch Environ Contam Toxicol* 2004; 47(4): 502-510.
  19. Pichhode M, Gaherwal S. Histopathology of liver and kidney of telost, *Clarias batrachus* of arsenic contaminated Chhulpura Pond water. *Uttar Pradesh J Zool* 2020; 41(9): 83-92.
  20. Sorensen EMB. Metal poisoning in fish. Florida, USA: CRC press 1991: 367-379.
  21. Laurén JD, McDonald DG. Acclimation to copper by rainbow trout, *Salmo gairdneri*: physiology. *Can J Fish Aquat Sci* 1987; 44: 99-104.
  22. Cockell KA, Hilton JW, Bettger WJ. Hepatobiliary and hematological effects of dietary disodium arsenate heptahydrate in juvenile rainbow trout (*Oncorhynchus mykiss*). *Comp Biochem Physiol* 1992; 103C: 453-458.
  23. Monachese M, Burton JP, Reid G. Bioremediation and tolerance of humans to heavy metal through microbial process: a potential role for probiotics? *Appl Environ Microbiol* 2012; 78(18): 6397-6404.
  24. Han R, Khan A, Ling Z, et al. Feed-additive *Limosilactobacillus fermentum* GR-3 reduces arsenic accumulation in *Procambarus clarkii*. *Ecotoxicol Environ Saf* 2022; 231: 113216. doi: 10.1016/j.jecoenv.2022.113216.
  25. Hoseinifar SH, Yousefi S, Doan HV, et al. Oxidative stress and antioxidant defense in fish: the implications of probiotic, prebiotic, and synbiotics. *Rev Fish* 2020; 29(2): 1-20.
  26. Weifen L, Xiaoping Z, Wenhui S, et al. Effects of *Bacillus* preparations on immunity and antioxidant activities in grass carp (*Ctenopharyngodon idellus*). *Fish Physiol Biochem* 2012; 38(6):1585-1592.
  27. Gobi N, Vaseeharan B, Chen JC, et al. Dietary supplementation of probiotic *Bacillus licheniformis* Dab1 improves growth performance, mucus and serum immune parameters, antioxidant enzyme activity as well as resistance against *Aeromonas hydrophila* in tilapia *Oreochromis mossambicus*. *Fish Shellfish Immunol* 2018; 74: 501-508.
  28. Yang G, Shen K, Yu R, et al. Probiotic (*Bacillus cereus*) enhanced growth of Pengze crucian carp by modulating the antioxidant defense response and exerting beneficial impacts on inflammatory response via Nrf2 activation. *Aquaculture* 2020; 529: 735691. doi: 10.1016/j.aquaculture.2020.735691.
  29. Bellezza I, Giambanco I, Minelli A, et al. Nrf2-Keap1 signaling in oxidative and reductive stress. *Biochim Biophys Acta Mol Cell Res* 2018; 1865(5): 721-733.
  30. Hafez M, Hayes K, Goldrick M, et al. The K5 capsule of *Escherichia coli* Strain Nissle 1917 is important in mediating interactions with intestinal epithelial cells and chemokine induction. *Infect Immun* 2009; 77(7): 2995-3003.
  31. Lin MY, Yen CL. Antioxidative ability of lactic acid bacteria. *J Agric Food Chem* 1999; 47(4):1460-1466.
  32. Nimalan N, Sørensen SL, Fečkaninová A, et al. Mucosal barrier status in Atlantic salmon fed marine or plant-based diets supplemented with probiotics. *Aquaculture* 2022; 547: 737516. doi: 10.1016/j.aquaculture.2021.737516.
  33. Dash S, Das SK, Samal J, et al. Epidermal mucus, a major determinant in fish health: a review. *Iran J Vet Res* 2018; 19(2): 72-81.