



## Case report

# Cytomegalovirus induced hemophagocytic lymphocytic histiocytosis in two pediatric patients with acute lymphoblastic leukemia



Benjamin Waddell<sup>a,\*</sup>, Chris Belcher<sup>b</sup>, Emily Willey<sup>c</sup>

<sup>a</sup> Peyton Manning Children's Hospital at St. Vincent, 220 Naab Rd # 200, 46260, United States

<sup>b</sup> Peyton Manning Children's Hospital at St. Vincent, Infectious Disease of Indiana, 11455 N Meridian St, Carmel, IN 46032, United States

<sup>c</sup> Indiana University School of Medicine, 340 W 10th St #6200, Indianapolis, IN 46202, United States

## ARTICLE INFO

## Keywords:

Hemophagocytic lymphohistiocytosis  
Cytomegalovirus  
Acute lymphoblastic leukemia  
Pediatric infections

## ABSTRACT

Hemophagocytic lymphohistiocytosis (HLH) is a rare inflammatory condition with tissue destruction due to abnormal immune activation. We present a series of 2 cases of cytomegalovirus-induced HLH in children during maintenance chemotherapy for acute lymphoblastic leukemia. These cases emphasize the importance of considering secondary HLH in this high-risk subset of pediatric patients.

## Introduction

Hemophagocytic lymphohistiocytosis (HLH) is an inflammatory condition with tissue inflammation and destruction due to abnormal immune activation. It is characterized by fever, pancytopenia, splenomegaly, and hemophagocytosis in the bone marrow, liver, or lymph nodes [1]. Infection, malignancy, and autoimmune conditions are known triggers. There are a growing number of genetic mutations implicated as predisposing factors. We present a series of 2 cases of HLH in children with CMV infection undergoing treatment for acute lymphoblastic leukemia (ALL). In our literature review, we can only find two previous cases of CMV-induced HLH with patients undergoing treatment for ALL. These cases emphasize the importance of considering secondary HLH in this high-risk subset of patients.

## Case 1

A seven-year-old male with high risk acute lymphoblastic leukemia in remission on cycle 2 of maintenance therapy was admitted to an outside hospital for persistent fever and pancytopenia: WBC 900/uL, Hgb 9.8 g/dL, platelets 41 000/uL and absolute neutrophil count (ANC) 117/uL. His physical exam was unremarkable with the exception of acute otitis media for which he was treated with intravenous cefepime. Two peripheral blood cultures were negative. A respiratory PCR was positive for rhinovirus. He was persistently febrile and he was then transferred to our tertiary pediatric center. Pediatric infectious disease was consulted. The patient underwent a CT scan of the sinuses, neck,

chest, and abdomen. It was remarkable for mild mucosal thickening involving the maxillary sinuses bilaterally, nephromegaly, splenomegaly, and gallbladder wall thickening. Antimicrobial coverage was broadened to: vancomycin, piperacillin/tazobactam, and voriconazole. Significant lab results included CMV quantitative DNA PCR 416,929 copies/mL, ferritin 25,246 ng/mL (reference range 7–140 ng/mL), LDH 1104 IU/L (reference range 104–333 IU/L), and triglycerides of 301 mg/dL (reference range Normal: < 150 mg/dL. Borderline high: 150–199 mg/dL. High: 200–499 mg/dL). A bone marrow aspirate and biopsy yielded no evidence of hemophagocytosis or leukemia. Fundoscopic examination revealed no signs of CMV retinitis. Ganciclovir 400 mg twice daily was started to treat CMV viremia. Within 48 h his fever resolved, a repeat CMV level at that time was decreased to 6073 copies/mL. Genetic testing found no sentinel mutations to suggest familial HLH.

He was continued on antiviral therapy at home for several weeks. His regular maintenance chemotherapy was resumed and he had a full recovery. He was re-hospitalized six months later for persistent recurrent cytomegalovirus infection and was treated with intravenous foscarnet for two weeks and one month into outpatient oral therapy he developed seizures so the foscarnet was discontinued at that time. At his last follow up two years later he was clinically well and off any therapy.

## Case 2

A six and a half-year-old boy with high risk ALL in morphological

**Abbreviations:** HLH, hemophagocytic lymphocytic histiocytosis; CMV, cytomegalovirus; ALL, acute lymphoblastic leukemia

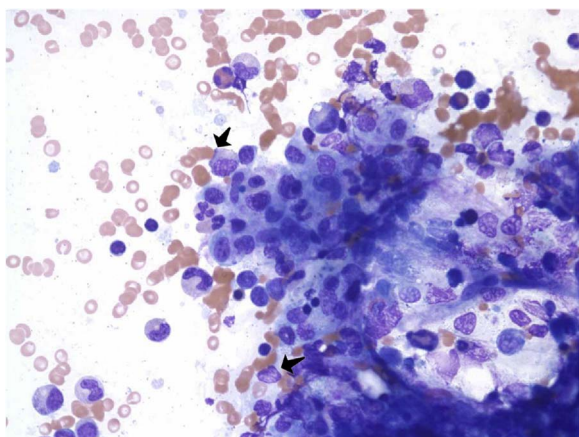
\* Corresponding author at: St Vincent Primary Care Center, 8220 Naab Rd # 200, 46260, United States.

E-mail addresses: [benjamin.waddell@ascension.org](mailto:benjamin.waddell@ascension.org) (B. Waddell), [cbelcher@idipsc.com](mailto:cbelcher@idipsc.com) (C. Belcher), [ekath321@gmail.com](mailto:ekath321@gmail.com) (E. Willey).

<http://dx.doi.org/10.1016/j.idcr.2017.07.003>

Received 11 May 2017; Received in revised form 8 July 2017; Accepted 8 July 2017

2214-2509/ © 2017 The Authors. Published by Elsevier Ltd. This is an open access article under the CC BY-NC-ND license (<http://creativecommons.org/licenses/by-nc-nd/4.0/>).



**Fig. 1.** Bone Marrow Aspiration: demonstrates adequate hypocellular bone marrow (65%) showing trilineage hematopoiesis, marked histiocytosis, hemophagocytosis, adequate iron stores and no malignancy.

and molecular remission had several episodes of myelosuppression during maintenance chemotherapy. Attempts to mitigate this included pentamidine instead of trimethoprim-sulfamethoxazole for pneumocystis prophylaxis and maintenance chemotherapy doses of 6-MP and methotrexate doses were reduced by 50%. During maintenance cycle five he was admitted to the hospital with fever and pancytopenia. His WBC was  $0.7 \times 10^3/\mu\text{L}$ , Hemoglobin 8.1 g/dL, Hct 23.2% and platelets of  $111 \times 10^3/\mu\text{L}$ . Soon after admission, the patient developed hypoxemia, and his chemotherapy was held. Chest radiography revealed bilateral perihilar opacities and atelectasis. Cefepime and azithromycin were started for pneumonia. On day 4 of admission, he developed hepatosplenomegaly, mediastinal adenopathy, and nephromegaly. Voriconazole was initiated for presumed invasive fungal disease. Significant lab results include: include ferritin 40 000 ng/mL, CMV PCR 11 949 copies/mL, soluble IL-2r 11 000 U/mL (reference range 406–1100 U/mL) and a bone marrow biopsy revealed moderate hemophagocytosis (Fig. 1). He was started on 5 mg twice daily dexamethasone and intravenous ganciclovir twice daily, was failing to respond and was switched to cidofovir and completed two weeks of treatment. He also completed eight weeks of chemotherapy without incident. Follow up labs including a CBC, soluble IL-2R receptor, ferritin, fibrinogen and triglycerides were all within normal limits. At discharge he had fully recovered and at his last follow up appointment two years later he was alive and well.

## Discussion

HLH is a clinical syndrome of immune dysregulation and hyperactivation on the spectrum of sepsis and SIRS, derived from hypercytokinemia with numerous possible etiologies, including genetic predisposition, infection, autoimmunity, and immunodeficiency. Familial HLH has multiple subtypes, and with advancement in genetic testing, it is now understood that this can present at any age [1]. Immunodeficiency syndromes associated with HLH include: Chediak-Higashi syndrome, Griscelli syndrome, and X-linked lymphoproliferative syndrome [1]. Autoimmune disease include systemic lupus erythematosus, systemic sclerosis, dermatomyositis and Sjogren's syndrome. Malignancies include acute lymphocytic leukemia, neuroblastoma, Hodgkin's disease and non-Hodgkin's lymphoma have also been described [1]. Immunosuppressed patients undergoing chemotherapy or post-transplant therapy are also at risk. In 2009 the Histiocytic Society put forth the revised HLH-2004 criteria for diagnosis as seen in Table 1.

The criteria are a collection of clinical, laboratory and histologic features. Perhaps the most common signs are fever and splenomegaly. Hepatomegaly, lymphadenopathy and a maculopapular rash have been

**Table 1**

HLH-2004 revised diagnostic criteria. Of note, absence of hemophagocytosis in the bone marrow does not exclude the diagnosis of HLH.

1.	Molecular diagnosis consistent with HLH or genetic analysis consistent with Familial Hemophagocytic Lymphohistiocytosis.
2.	At least 3 of 4 Fever for $\geq 7$ days Splenomegaly Cytopenia ( $\geq 2$ lineages), anemia (Hb $< 9.0$ g/dL) Hepatitis
3.	At least 1 of 4 Hemophagocytosis Hyperferritinemia ( $\geq 500$ $\mu\text{g/L}$ ) Increased soluble CD25 $> 2400$ units/mL. (also known as sIL-2) Low/absent natural killer cell activity
4.	Findings supportive of HLH Hypertriglyceridemia ( $\geq 265$ mg/dL) Hypofibrinogenemia ( $< 1.5$ g/L) Hyponatremia

described as well [2]. Laboratory abnormalities are often most notable for significant cytopenias. Elevated bilirubin, triglycerides, ferritin, and lactate dehydrogenase are chemistry findings that suggest hemolysis. Many patients with HLH present with shock or sepsis, and the clinical presentation and laboratory values may initially suggest an infectious process. NK cell activity as measured by flow cytometry and soluble CD25 levels help differentiate these conditions [3]. In our two patients, one had hemophagocytosis demonstrated on bone marrow biopsy, and one did not. Both met criteria based on having fever, splenomegaly and cytopenias and hyperferritinemia. This highlights the need for a diagnostic criteria based on multiple factors as bone marrow biopsy is not sufficient in making this diagnosis.

The pathogenesis of HLH is not well understood. There is evidence to suggest impairment in NK-cell activity leads to persistent activation of macrophages and production of cytokines [4]. Infections, especially viral, have been associated with reduced NK cell quantities, underlying the basis for viral-associated HLH syndromes [5]. Previously reported infectious organisms include parvovirus B19, herpes simplex virus (HSV), varicella-zoster virus, Epstein-Barr virus, cytomegalovirus, influenza virus, coxsackie virus, fungi, parasites, rickettsiae, *Mycobacterium tuberculosis* and other bacteria, including *Streptococcus pneumoniae*. Most primary cases of HLH are secondary to infection [1].

Our two cases underscore the importance of recognizing secondary infections in pediatric oncology patients as well as having a keen awareness of the complications of secondary infections. The key to treatment in most cases is to treat the underlying infection.

Pediatric oncology patients, in particular, remain at risk for these infections as a result of immunosuppressive therapy. HLH often has a poor prognosis, but fortunately if identified early, secondary types of the hemophagocytic syndrome have a better prognosis than familial types. Similar to patients in the present case series, Wakai et al. described a pediatric patient who presented with persistent fever, leukocytopenia and hepatosplenomegaly secondary to CMV-HLH with CMV retinitis during maintenance therapy for T-ALL, with remission achieved with dexamethasone and IVIG despite the persistence of CMV retinitis [6]. Similarly, Kobayashi and colleagues describe a young patient with B-ALL presenting with persistent fever during maintenance therapy. In this case, fever resolved with prednisolone with the development of visual disturbance and discovery of CMV antigenemia several days later [7]. In both cases as well as ours, ultimate eradication of antigenemia required antiviral therapy.

In conclusion, secondary infections in pediatric oncology patients should be very high on the differential of a patient with fevers. In the presence of persistent fevers and lack of improvement despite appropriate therapy, further testing for HLH should be obtained. In both of our cases, a markedly elevated ferritin level was an important

diagnostic indicator to pursue further diagnostic possibilities beyond secondary infections. HLH, even viral induced, is a serious complication of chemotherapy, but if identified and treated the overall prognosis is excellent.

#### Conflict of interest

The other authors have no conflicts of interest to disclose.

#### Funding source

No funding was secured for this study.

#### Financial disclosure

This research did not receive any specific grant from funding agencies in the public, commercial, or not-for-profit sectors.

#### Author contributions

All authors meet ICMJE authorship criteria, approved the final manuscript as submitted and agree to be accountable for all aspects of the work.

#### Acknowledgement

Special thanks to Bassem Razzouk MD for his guidance on developing this manuscript.

#### References

- [1] Janka GE, Lehmer K. Hemophagocytic syndromes – an update. *Blood Rev* 2014;28(4):135–42.
- [2] Janka GE. Hemophagocytic syndromes. *Blood Rev* 2007;21(5):245–53.
- [3] Bode S, Ammann S, Al-Herz W, Bataneant M, Dvorak C, Gehring S, et al. The syndrome of hemophagocytic lymphohistiocytosis in primary immunodeficiencies: implications for differential diagnosis and pathogenesis. *Haematologica* 2015;100(7):978–88.
- [4] Maakaroun NR, Moanna A, Jacob JT, Albrecht H. Viral infection associated with hemophagocytic syndrome. *Rev Med Virol* 2010;20:93–105.
- [5] Malinowska I, Machaczka M, Popko K, Siwicka A, Salamonowicz M, Nasilowska-Adamska B. Hemophagocytic syndrome in children and adults. *Archivum Immunol et Ther Exp* 2014;62(October (5)):385–94.
- [6] Wakai K, Sano H, Shimada A, Shiozama Y, Park M, Sotomatsu M, et al. Cytomegalovirus retinitis during maintenance therapy for T-cell acute lymphoblastic leukemia. *J Pediatr Hemat/Oncol* 2013;35(March (2)):162–3.
- [7] Kobayashi R, Takashi K, Suzuki D, Nasu T, Uetake K, Matsumoto Y. Retinitis from cytomegalovirus during maintenance treatment for acute lymphoblastic leukemia. *Pediatr Int* 2012;54(April (2)):288–90.