




## OPERATIVE TECHNIQUE

# Posterior Decompression and Fusion with Vertical Pressure Procedure in the Treatment of Multilevel Cervical OPLL with Kyphotic Deformity

Cheng Li, MS<sup>#</sup>, Yunli Mei, MS<sup>#</sup> , Lei Li, MD , Zeqing Li, MS , Shuai Huang, MS

Department of Orthopaedic Surgery, Shengjing Hospital of China Medical University, Shenyang, P.R. China

**Objective:** To report the outcomes and feasibility of a new technique to change K-line (–) to K-line (+) via only a posterior approach to treat multilevel non-continuous cervical ossification of the posterior longitudinal ligament (C-OPLL) with kyphotic deformity.

**Methods:** In this study, 17 consecutive cases of patients who underwent vertical pressure procedure (VP) combined with posterior cervical single-open-door laminoplasty and instrumented fusion from January 1, 2017 to December 31, 2019 were enrolled. The following radiographic parameters: C2-C7 Cobb angle, local Cobb angle, extent of OPLL, and the distance from OPLL to the K-line (DK) were measured and analyzed. Clinically, the JOA score, VAS-N and VAS-A, NDI, and complications were collected from medical records to evaluate the clinical outcomes.

**Results:** All 17 cases shifted from K-line (–) to K-line (+). Comparing the preoperative images to the final follow-up images, the mean C2-7 Cobb angle changed from  $-6.94^{\circ} \pm 8.30^{\circ}$  to  $8.18^{\circ} \pm 4.43^{\circ}$ , and the local Cobb angle altered from  $-9.12^{\circ} \pm 8.68^{\circ}$  to  $6.65^{\circ} \pm 6.11^{\circ}$ . The mean DK increased from  $-2.64 \pm 1.52$  mm to  $3.09 \pm 2.19$  mm. One patient showed C5 palsy and recovered within 3 months. The mean JOA score increased from  $8.88 \pm 2.11$  to  $14.71 \pm 1.36$ . The average NDI decreased from  $20.65 \pm 7.80$  to  $8.94 \pm 4.93$ . The mean VAS-N and VAS-A decreased from  $3.44 \pm 1.80$  and  $4.69 \pm 1.97$  to  $1.25 \pm 0.86$  and  $1.38 \pm 1.16$ . All patients were followed up for at least 1 year.

**Conclusion:** A new technique added to posterior decompression and fusion (PDF), the vertical pressure procedure effectively corrects K-line (–) to K-line (+) and avoids the shortcomings of conventional anterior decompression and fusion (ADF) as well as PDF to provide a relatively safe and adequate decompression, cervical realignment. It pronounced satisfactory clinical outcome for extensive non-continuous OPLL with kyphotic deformity even though OPLL remains ventral to the spinal cord.

**Key words:** Cervical spine; Fusion surgery; K-line; OPLL; Pedicle screw

## Introduction

Ossification of the posterior longitudinal ligament (OPLL) is an ectopic bone formation within the posterior longitudinal ligament. The incidence of cervical myelopathy caused by OPLL among individuals is between 1.9% and 4.3% in Japan, and the incidence is reported up to about 3% in other Asian countries.<sup>1,2</sup> In reference to European and North American cohorts, records show a much lower morbidity rate, ranging from 0.1 to 1.7%.<sup>3–5</sup> OPLL is

morphologically classified into four types: continuous (ossification extends across several vertebrae), segmental (fragmented ossification located posterior to the vertebral body), mixed (combination of segmental and continuous), and a particular type, localized (confined to disc space).

The K-line is a virtual line connecting the midpoint of the C2 and C7 spinal canals that can estimate the thickness of the OPLL and cervical alignment. When the OPLL does not exceed the K-Line, it is classified as K-line (+), and when

**Address for correspondence** Lei Li, Department of Orthopaedic Surgery, Shengjing Hospital of China Medical University, Shenyang, Liaoning, 110055, China. Email: [18940258679@163.com](mailto:18940258679@163.com)

<sup>#</sup>Cheng Li and Yunli Mei contributed equally to this work.

Received 21 February 2021; accepted 7 July 2022

the OPLL exceeded the K-Line, it is classified as K-line (–).<sup>6</sup> K-line (–) indicated thick OPLL and/or kyphotic alignment that led to poor outcomes because of a lack of posterior shifting space for the spinal cord.<sup>6,7</sup> Postoperative K-line conversion from negative to positive is associated with a better surgical outcome.<sup>8</sup>

OPLL is primarily found in the cervical spine and is a common pathology of cervical myelopathy.<sup>9,10</sup> Most patients with C-OPLL do not exhibit any neurological symptoms in the early stages. As OPLL develops, the spinal cord is compressed which causes cervical myelopathy. Though surgical therapy is required for symptomatic patients, the most appropriate surgical program has not been established. There are several surgical options, including posterior laminoplasty (LMP), posterior decompression and fusion (PDF), anterior decompression and fusion (ADF), and multiple stages surgery.<sup>11,12</sup> Various imaging parameters can be used to assess OPLL, including compression level, cervical alignment, extent, shape, thickness, and location of OPLL. Among all these parameters, cervical alignment and compression levels are the two most crucial elements for selecting surgical criteria.<sup>13,14</sup> Anterior decompression and fusion are commonly performed in patients with only one or two levels of compression and kyphosis.<sup>15</sup> Either the anterior or posterior approach has been considered effective for patients with one or two levels of compression and lordosis. Moreover, posterior decompression through posterior laminoplasty is preferred in multiple levels of involvement with lordotic alignment.<sup>15</sup> On the other hand, patients who suffer from multilevel compression of ossification of the posterior longitudinal ligament and kyphotic alignment are usually treated with both anterior and posterior (AP) decompression.

The incidence of complications associated with the surgical operation of OPLL may depend on various factors including surgeon experience, surgical approach, and the presence of general systemic and neurologic comorbidity, including dural ossification (DO). Dural tear, cerebral-spinal fluid (CSF) leakage, and neurological deterioration limited the anterior decompression surgery, which is also a part of the anterior and posterior one-stage (AP) surgery.<sup>16–18</sup> Dysphagia, hoarseness, and dysarthria are common complications of the anterior approach and are related to the recurrent laryngeal nerve injury or manipulation and retraction of the esophagus. Removing the ossification dura and the OPLL may result in a CSF leak. Once the leak is identified intraoperatively, many techniques can be applied to repair the defect and prevent further complications. Primary watertight repair remains ideal, but this is not always practical from the anterior cervical approach. This may lead to reoperation, meningitis, persistent fistula formation, pseudomeningocele formation, and may even require permanent CSF diversion to manage definitively. Poor outcomes originating from residual ventral compression of ossification of the posterior longitudinal ligament, C5 nerve root palsy, and axial pain are limitations of the posterior approach, which is also a part of the anterior and posterior one-stage

(AP) surgery.<sup>19–21</sup> The etiology of the postoperative “C5 palsy” has yet to be definitively established, but it is a phenomenon that is widely acknowledged after posterior cervical spine surgery. Two probable explanations of the pathophysiology of C5 palsy are now highly accepted including the tethering phenomenon, in which the spinal cord shifts with traction on the spinal cord and/or nerve roots following posterior decompression, and changes in spinal cord perfusion in the context of impaired autoregulation mechanisms caused acutely at the time of decompression.<sup>22</sup> Axial pain has been defined as pain from the nuchal to the shoulder region. Such a complication has been reported mainly after posterior cervical surgery. Furthermore, conventional AP surgery is common with prolonged hospitalization, anesthesia, and surgical times of high risks.

This study aims to: (i) introduce a novel vertical pressure procedure that changes K-line (–) to K-line (+) to treat multilevel non-continuous OPLL with kyphotic deformity; and (ii) report the feasibility and clinical outcomes of the vertical pressure procedure adding to posterior decompression with instrumented fusion.

## Materials and Methods

### General Information

This study was approved by the Ethics Committee of China Medical University (Ethical Code: 2019PS038J, Project Title: Posterior cervical screw-rod system and vertical pressure procedure in the treatment of K-line (–) cervical OPLL). We conducted a retrospective study of 17 patients who underwent vertical pressure procedures for multilevel compression of non-continuous (segmental or mixed type) OPLL with a kyphotic deformity in Shengjing Hospital of China Medical University from 1 January 2017 to 31 December 2019. These OPLL diagnoses were made by magnetic resonance imaging, plain film, and computed tomography.

### Inclusion and Exclusion Criteria

The following were the inclusion criteria: (i) patients who had cervical myelopathy caused by non-continuous (segmental or mixed type) OPLL compression with/without radiculopathy; (ii) three or more vertebrae involved; (iii) kyphosis or lordosis with C2-7 Cobb angle less than 10°; (iv) K-line (–), (v) cervical instability verified by cervical X-ray; (vi) patients underwent vertical pressure (VP) procedure in addition to posterior single-open-door laminoplasty decompression with instrumented fusion using a screw-rod system; and (vii) patients who were followed up for at least 1 year.

Our study excluded patients who had: (i) asymptomatic cervical cord compression; (ii) prior cervical surgery; and (iii) traumatic injury, cerebrovascular accident, lumbar and thoracic spinal stenosis, infection, ankylosing spondylitis, rheumatoid arthritis, and neoplastic diseases.

### Preoperative Preparation

All patients underwent Dynamic X-ray, 3D CT, and MR examination before surgery to understand the type of OPLL, cervical range of motion, and anatomy of pedicles which were important in making surgery plans. Centered on the apex of the ossification, pedicle screws were planned to insert at the corresponding level and the adjacent segments to prepare for the Vertical Pressure procedure. All other preoperative examinations and blood tests were perfected.

### Surgical Techniques

#### Position

The patient was placed in a prone position under general anesthesia with a silicone head frame applied with the neck slightly flexed.

#### Incision and Exposure

A standard midline incision was made between the spinous processes of C2 and C7, and lateral margins of C3-6 were fully exposed using subperiosteal dissection. The vertebrae into which screws were planned to be inserted were identified, and the lateral masses were exposed until they reached their lateral margins.

#### Pedicle Screw Fixation and Laminoplasty

The entry point was chosen as the intersection of the horizontal line through the midpoint of the transverse process root and the vertical line through the posterolateral plane and the posterior plane of the isthmus. Cervical pedicle screw fixation was performed in the upper and lower levels with the screws positioned at the most compressive level. Then a C3-6 single-open-door laminoplasty was performed with arch miniplates, the level of decompression was determined by the compression of the spinal cord and a C7 hemilaminectomy or C7 laminectomy was conducted if necessary.

#### Vertical Pressure Procedure

First, a prefabricated titanium rod with target curvature was positioned and a special bilateral annular tube was placed to hold the center screws on both sides, then the center tap screws on both sides were locked. Second, the surgeon applied vertical pressure on the handle of the bilateral annular tube to restore cervical lordosis, and the changes in cervical curvature were monitored through intraoperative fluoroscopy. Third, all the other tap screws were locked when the target cervical curvature was achieved. All the procedures were done under intraoperative neurological monitoring.

The basic information of patients, the number of fixation and instrumental fusion levels, decompression levels, intraoperative blood loss, surgical time, clinical complication, and hospitalization period were obtained from medical records (Fig. 1).

### Radiographic Parameters

Furthermore, the following radiographic parameters were evaluated using midsagittal preoperative, 1 day after surgery operation (postoperative), and final follow-up CT images (or digital radiography when follow-up CT was not available): the number of involved levels, C2-7 Cobb angle (or C2-C6 Cobb angle if C7 is not observable in follow-up digital radiography), local Cobb angle, the distance from OPLL to K-line (DK) and the maximal occupying ratio (MOR) of the cervical spinal canal. The fixation levels were used to calculate the local Cobb angle. Both preoperative and postoperative MOR of the cervical spinal canal were calculated with the canal diameter and the sagittal thickness of OPLL at the most compromised levels, which was the most compressive level (Fig. 2).

### Clinical Parameters

A Japanese Orthopaedic Association (JOA) score was collected preoperatively, the myelopathy severity is considered mild if the JOA score is higher than 13, moderate if the JOA score ranges from 9 to 13, and severe if the JOA score is lower than 9. At the final follow-up, while collecting the recovery rate we used the following formula: (postoperative JOA - preoperative JOA) / (17 - preoperative JOA). The visual analogue scale of the neck (VAS-N), arm pain (VAS-A), and neck disability index (NDI) were also collected.

### Statistical Analysis

The average radiographic parameters of MOR, DK, and C2-C7 Cobb angle were collected preoperatively and at the final follow-up. Paired t-tests were performed using SPSS version 21.0 for Windows (SPSS, Inc., Chicago, IL, USA). *P*-values less than 0.05 were considered statistically significant.

### Result

#### Follow-up

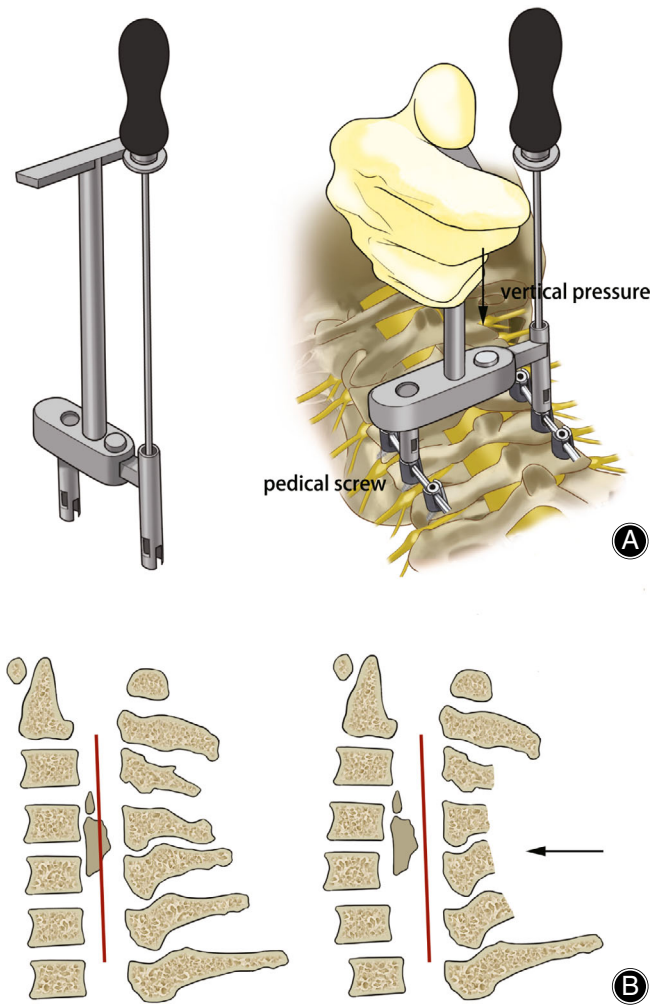
We included 17 patients in our study (M: F = 12:5) (Table 1). The mean follow-up time was  $16.06 \pm 3.28$  months.

#### General Results

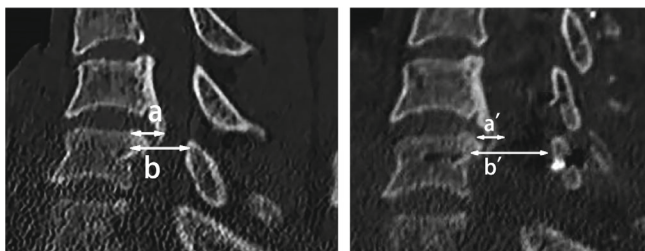
The mean age was  $57.06 \pm 10.56$  years. There was C3-5 fixation in five cases, C4-6 fixation in seven cases, and C3-6 fixation in five cases. The mean surgical time was  $137.82 \pm 24.72$  minutes, and the mean intraoperative blood loss was  $315.29 \pm 339.41$  ml. Moreover, the mean hospitalization period was  $8.12 \pm 1.41$  days.

#### Clinical Improvements

The mean JOA score increased from  $8.88 \pm 2.11$  to  $14.71 \pm 1.36$  ( $t = 11.78$ ,  $P < 0.05$ ), and the average recovery rate was 70.59%. The average NDI decreased from  $20.65 \pm 7.80$  to  $8.94 \pm 4.93$  ( $t = 10.21$ ,  $P < 0.05$ ). The mean VAS-N and VAS-A decreased from  $3.44 \pm 1.80$  and  $4.69 \pm 1.97$  to  $1.25 \pm 0.86$  ( $t = 7.49$ ,  $P < 0.05$ ) and  $1.38 \pm 1.16$  ( $t = 5.53$ ,  $P < 0.05$ ).



**Fig. 1** The schematic drawings of the bilateral annular tube and VP procedure. After the center screws on both sides were locked, we apply vertical pressure on the handle for cervical realignment. After confirming the cervical alignment under intraoperative radiograph, we locked all the tap screws. Preoperative K-line (-) and kyphotic deformity were corrected to K-line(+) and lordotic cervical alignment after VP procedure



**Fig. 2** Radiographic parameter on CT midsagittal images: the preoperative maximal canal occupying rate ( $MOR = a/b \times 100\%$ ,  $a = a'$  = the thickness of OPLL,  $b$  = the preoperative canal diameter at the most compromised level,  $b'$  = the postoperative canal diameter at the most compromised level)

### Radiographic Improvements

Radiographic images were anonymous and were measured blindly by two experienced neuroradiologists. All 17 patients suffered from K-line (-) non-continuous (segmental or mixed type) OPLL. The mean number of OPLL levels was  $4.82 \pm 1.42$  since the cases with less than three levels were not included. All 17 cases shifted from K-line (-) to K-line (+). Thirteen cases converted from kyphosis to lordosis as their C2-7 Cobb angle changed from negative to positive. The other four cases were more lordotic after treatment. The mean C2-7 Cobb angle altered from  $-6.94^\circ \pm 8.30^\circ$  to  $8.18^\circ \pm 4.43^\circ$  ( $t = 9.78$ ,  $P < 0.05$ ), and the mean C2-7 Cobb angle change was  $15.12^\circ \pm 6.18^\circ$ . The local Cobb angle changed from  $-9.12^\circ \pm 8.68^\circ$  to  $6.65^\circ \pm 6.11^\circ$  ( $t = 10.96$ ,  $P < 0.05$ ) and the average change was  $15.76^\circ \pm 5.76^\circ$ . The mean distance from OPLL to K-line increased from  $-2.64 \pm 1.52$  mm to  $3.09 \pm 2.19$  mm ( $t = 7.90$ ,  $P < 0.05$ ), and the mean distance change was  $5.73 \pm 2.90$  mm. The most compressive level was C3-4 in 3 cases, C4-5 in 7 cases, C5-6 in 4 cases, C4-6 heavily compressed in 1 case, and moderately compressed from C2 to C5 in 2 cases. The mean maximal occupying ratio of the cervical spinal canal decreased from 56.53% to 36.35% ( $t = 13.36$ ,  $P < 0.05$ ) (Table 2).

### Complications

Postoperative complications were acquired from clinical records. Three patients showed moderate axial pain after the surgery, and this subsided within several months without specific management. One patient showed postoperative anemia due to intraoperative blood loss, which was successfully managed by intraoperative autotransfusion and postoperative blood transfusion. Another patient showed C5 palsy and recovered within 3 months. No patient showed pedicle screw fracture, surgical site infection, CSF leakage, neurological deterioration, or pseudarthrosis.

### Discussion

According to the results we obtained, patients who underwent PDF and VP have better outcome in neurological recovery and cervical alignment.

### The Controversy of Conventional Surgical Procedures for K-Line(-) OPLL

Ossification of the posterior longitudinal ligament (OPLL) is primarily found in the cervical spine and the surgical treatment for K-line (-) cervical OPLL is still controversial. Since LMP cannot control postoperative kyphotic alteration and cause severe neurological deterioration, it was considered unsuitable for K-line (-) patients. Several studies showed ADF and PDF achieve better outcomes as they maintain cervical alignment superiorly to LMP in cases with lordosis angles of less than  $10^\circ$  or kyphosis.<sup>6,9,23-25</sup>

ADF is a good option when the complete removal of OPLL is feasible. However, the complications after ADF, such as CSF leakage, neurological deterioration, and airway



TABLE 1 Clinical data of the patients

Sex	Age	Segment	Involvement	MCL	FL	Preop Cobb	Postop Cobb	Preop LC	Postop LC	DK1	DK2	Preop JOA	Postop JOA	RR	Preop NDI	F/U NDI	FT	OT	IOBL	HP
F	54	4	3-6	4-5	4-6	-3	10	-6	5	-0.74	5.47	11	17	100.00%	14	3	14	134	400	8
M	48	3	3-5	3-4	3-5	-5	8	-8	4	-3.54	5.19	7	15	80.00%	26	12	19	127	170	7
F	51	6	2-7	3-4	3-5	2	13	-10	10	-0.80	1.73	9	14	62.50%	22	15	18	138	210	8
M	66	5	3-7	5-6	4-6	2	13	1	15	-3.23	4.33	6	11	45.45%	36	17	13	152	310	9
M	74	4	4-7	5-6	4-6	1	12	-3	7	-5.62	9.2	9	15	75.00%	27	11	14	97	150	7
F	62	5	3-7	4-5	3-5	-7	11	-16	-2	-2.36	0.4	9	15	75.00%	29	15	12	110	110	8
M	60	3	4-6	4-5	3-5	-7	6	-7	13	-1.20	2.53	8	15	77.78%	15	7	24	115	140	8
M	62	5	2-6	5-6	4-6	-27	5	-36	-8	-5.28	0.63	11	16	83.33%	18	4	15	142	190	8
M	35	5	2-6	5-6	4-6	-16	5	-12	11	-2.81	3.54	6	15	81.82%	33	12	13	190	1600	13
M	51	7	2T1	3-4	3-6	-5	4	2	13	-0.76	3.57	14	15	33.33%	6	4	17	139	180	8
M	60	8	2T2	4-5	3-6	2	14	0	13	-3.75	4.6	7	15	80.00%	13	3	16	183	500	7
M	69	4	3-6	4-5	3-6	-7	16	-11	10	-2.25	2.51	9	14	62.50%	25	13	21	140	270	7
F	35	5	3-7	4-6	3-6	-1	5	-3	3	-1.78	1.65	12	14	40.00%	11	3	19	125	180	7
M	63	3	4-6	4-5	4-6	-15	1	-9	12	-1.16	2.04	10	17	100.00%	15	4	14	103	120	7
F	56	6	2-7	2-5	3-5	-20	2	-19	2	-2.79	2.32	8	15	77.78%	20	5	14	131	130	9
M	69	6	2-7	2-5	3-6	-9	6	-9	4	-2.44	1.72	8	13	55.56%	22	15	12	162	300	9
M	55	3	4-6	4-5	4-6	-3	8	-9	1	-4.3	1.16	7	14	70.00%	19	9	18	155	400	9

Abbreviations: Cobb, C2-C7 Cobb angle; DK1, preoperative distance from OPLL to K-line; DK2, postoperative distance from OPLL to K-line; F/U, final follow-up; FL, fusion level; FT, follow-up time; HP, hospitalization period; IOBL, intraoperative blood loss; JOA, Japanese Orthopaedic Association score; LC, local Cobb angle; MCL, most compressive level; NDI, neck disability index; OT, surgical operation time; Postop, postoperative; Preop, preoperative; RR, recovery rate.

edema are of high risk which limited its clinical application and ADF is highly technically demanding.

In comparison, the technically easier PDF is usually adopted.<sup>21</sup> However, a disadvantage in indirect decompression of PDF is that OPLL remains ventral to the cord, and that might lead to insufficient decompression in K-line (-) cases.

Previous reports demonstrated that the posterior shift of the spinal cord of more than 3 mm indicates good clinical outcomes. The clinical prognosis of patients with OPLL was validly related to postoperative cervical lordosis after PDF.<sup>26,27</sup> However, conventional PDF would not change cervical alignment and C2-7 Cobb angle.<sup>25</sup>

**Novel Vertical Pressure (VP) Procedure to Change K-Line (-) to (+)**

The mobility of cervical alignment in patients with a non-continuous type (segmental and mixed types) of OPLL is the foundation of our vertical pressure procedure. It provides the possibility of cervical realignment without management of anterior compression. All cases are changeable in cervical alignment, as proven by lateral dynamic radiogram preoperatively (Figs 3A,B, 4A,B, and 5A,B).

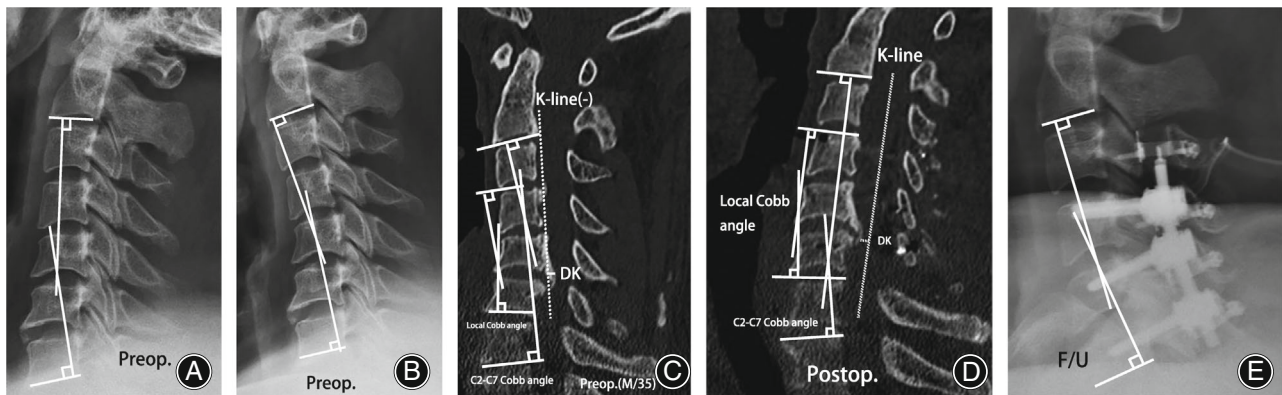
Theoretically, cervical realignment converting kyphosis to lordosis may improve the decompression between OPLL and the anterior edge of the dura mater, producing further decompression in cases where PDF provided inadequate ventral decompression for K-line (-) patients and contributing to the change from K-line (-) to K-line (+). The authors requested to use the midsagittal images of CT to establish the K-line since C7 is usually not observed in plain lateral radiography, and CT reveals OPLL clearly.<sup>28,29</sup>

With the cervical pedicle screw fixation system and the VP procedure, spinal surgeons were able to apply adequate vertical force to convert local kyphosis into lordosis, thus restoring cervical lordotic alignment to convert K-line (-) to K-line (+) and improve the decompression between OPLL and dura mater with only a posterior approach (Fig. 1A). After cervical realignment through VP, the K-line was reestablished in the new lordotic cervical alignment (Fig. 1B.). In our study, the mean distance from OPLL to K-line increased from  $-2.64 \pm 1.52$  mm to  $3.09 \pm 2.19$  mm ( $P < 0.05$ ) after which VP demonstrated better ventral decompression of the spinal cord (Fig. 1B.). As a result of better ventral decompression together with reestablished K-line, all patients in our study who suffered from K-line (-) multilevel non-continuous OPLL were corrected to K-line (+) after vertical pressure combined with posterior cervical single-open-door laminoplasty and instrumented fusion using a screw-rod system. Vertical pressure has played a vital role in restoring the lordotic alignment of the cervical spine, and the prefabricated rod could help avoid Cobb angle loss and maintain the cervical alignment.

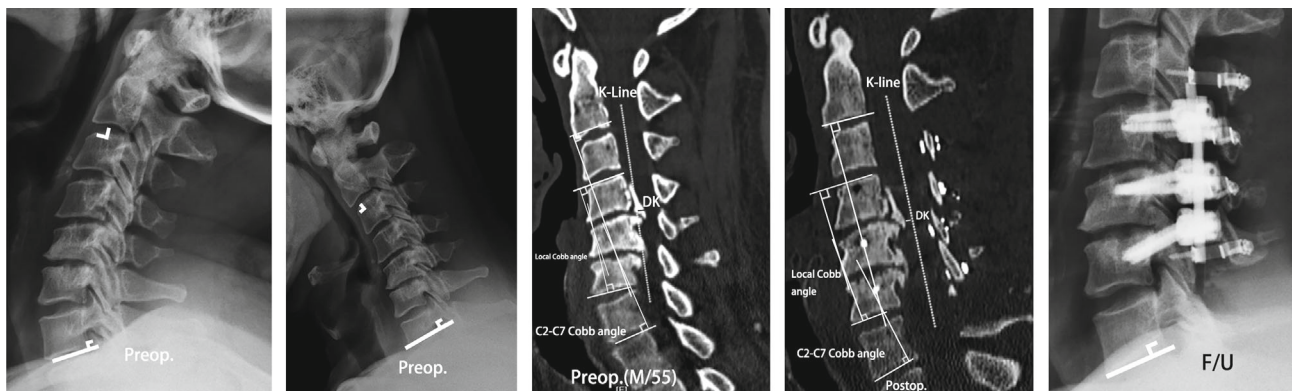
**TABLE 2** The average radiographic parameters indicating improvement

	Preop	F/U	t	P
MOR	56.53% ± 13.28%	36.35% ± 9.10%	13.36	$4.28 \times 10^{-10}$ (<0.05)
DK (mm)	-2.64 ± 1.52	3.09 ± 2.19	7.90	$6.53 \times 10^{-7}$ (<0.05)
Cobb	-6.94° ± 8.30°	8.18° ± 4.43°	9.78	$3.73 \times 10^{-8}$ (<0.05)

Abbreviations: Cobb, C2-C7 Cobb angle; DK, distance from OPLL to K-line; F/U, final follow-up; MOR, maximal occupying rate; Preop, preoperative.



**Fig. 3** A representative case of VP procedure combining with PDF. A 35-year-old male patient showed Kline(-) extensive OPLL with a 60% canal occupying rate and kyphotic deformity. Favorable clinical outcomes were obtained after the authors' VP procedure and PDF. (A and B:dynamic radiograph, DK: distance from OPLL to K-line)



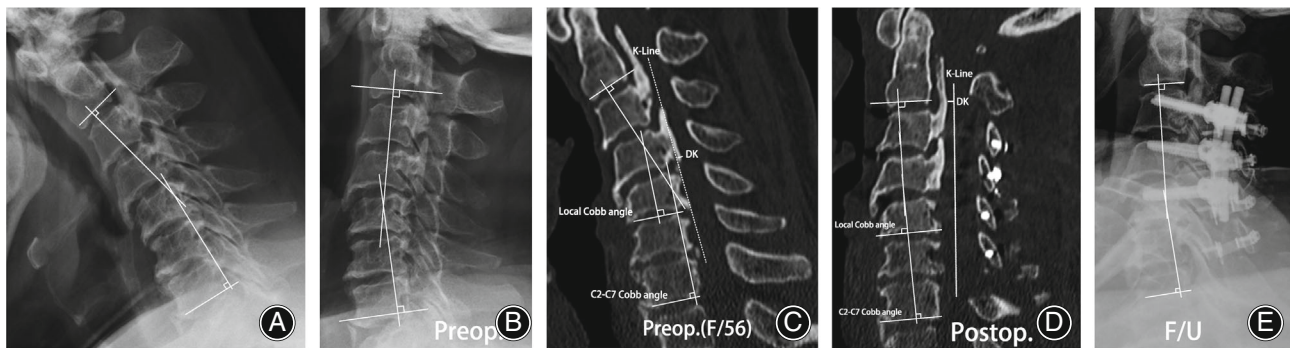
**Fig. 4** A 55-year-old male patient showed K-line (-) multilevel OPLL with a 76% canal occupying rate and kyphotic deformity. Eximious decompression and lordotic alignment were observed on postoperative and follow-up images

### **Surgical Feasibility, Complications and Prevention**

As K-line (-) was converted to K-line (+) using PDF with VP, sufficient ventral and posterior decompression were met, which led to better outcomes than conventional PDF in the K-line (-) case. To the best of our knowledge, the recovery rate for K-line (-) patients approximately ranges from 54% to 73% after ADF and 38.2% to 43.6% after PDF.<sup>8,9,24,25,30,31</sup> Our study showed an average recovery rate of 70.59% in the

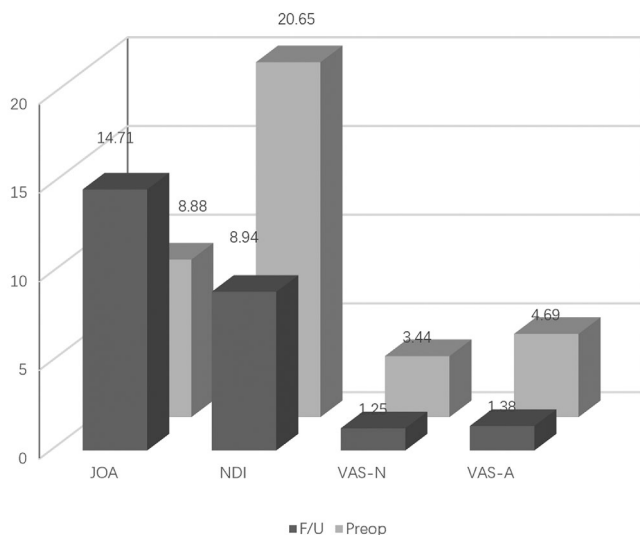
JOA score of all cases, 72.08% in kyphotic cases, and 70.51% in thick OPLL (MOR>50%), which is acceptable as K-line (-) indicates poor clinical prognosis (Fig. 6).

All cases underwent PDF and additional vertical pressure procedures under neural monitoring to avoid neural damage caused by over lordosis after cervical realignment. In our cases, one patient had C5 palsy, and this outcome may occur due to excessive posterior drifting of the spinal cord



**Fig. 5** A 56-year-old female patient showed K-line (-) multilevel OPLL with kyphotic deformity and shifted to K-line(+) after VP

### The Clinical Parameters Indicating Improvement



**Fig. 6** Graph showing improvement in average clinical parameters before (preop.) and after (postop.) surgery

after posterior decompression, which can cause a tethering effect.<sup>32</sup> The two most acceptable and imperative pathologic mechanisms of C5 palsy are nerve root traction and displacement of tethering effect.<sup>33</sup> However, normal cervical alignment was restored after VP, leading to a normal intervertebral foramen whose size and position were adequate for the nerve root without pathological changes. The present lordotic angle was determined intraoperatively and subjectively by experienced spinal surgeons using intraoperative C-arm radiography and neural monitoring. The inexact degree of cervical realignment may have skewed our results towards a worse outcome because the specific lordotic angle varies with each individual, and even lordosis might be supraphysiological for some patients.<sup>34</sup> Further

research was required to explore the individualized optimum lordotic angle.

In summary, the vertical pressure procedure could effectively correct K-line (-) to (+) and provide a relatively safe and adequate decompression *via* a single posterior approach, which avoids the high risk of conventional ADF and insufficient decompression of PDF. The new method pronounced satisfactory outcomes for extensive non-continuous OPLL with kyphotic deformity even though OPLL remains ventral to the spinal cord.

There are some limitations to the current study: (i) with relatively small patient samples and the nature of the retrospective study, further long-term follow-up research is required; (ii) the VP procedure requires sufficient stability, so it should be used with cervical pedicle screws which have certain technical difficulties and risks; and (iii) the outcome of additional vertical pressure procedures in other types of OPLL is unknown and requires further research to identify.

### Conclusion

A new technique added to PDF, the vertical pressure procedure effectively corrects K-line (-) to K-line (+). Although OPLL remains ventral to the spinal cord, this procedure avoided the shortcomings of conventional ADF as well as PDF to provide a relatively safe and adequate decompression, cervical realignment, and pronounced outcome for extensive non-continuous OPLL with kyphotic deformity even though OPLL remains ventral to the spinal cord.

### Author Contribution

Conception and design: all authors. Acquisition of data: Cheng Li, Yunli Mei, Zeqing Li, Huang S. Analysis and interpretation of data: Yunli Mei, Cheng Li. Drafting the article: Yunli Mei Critically revising the article: Cheng Li. Reviewed submitted version of manuscript: Cheng Li, Yunli Mei Statistical analysis: Yunli Mei Administrative/technical/material support: Lei Li, Li C, Yunli Mei Study supervision: Lei Li.



**Acknowledgments**

The study was supported by the Department of Orthopedic Surgery, Shengjing Hospital of China Medical

University. We sincerely thank all the medical staff and all the enrolled patients in this study.

**References**

1. Ohtsuka K, Terayama K, Yanagihara M, Wada K, Kasuga K, Machida T, et al. An epidemiological survey on ossification of ligaments in the cervical and thoracic spine in individuals over 50 years of age. *Nihon Seikeigeka Gakkai Zasshi*. 1986; 60:1087–98.
2. Matsunaga S, Sakou T. Ossification of the posterior longitudinal ligament of the cervical spine: etiology and natural history. *Spine*. 2012;37:E309–14.
3. McAfee PC, Regan JJ, Bohlman HH. Cervical cord compression from ossification of the posterior longitudinal ligament in non-orientals. *J Bone Joint Surg, Br*. 1987;69:569–75.
4. Epstein NE. The surgical management of ossification of the posterior longitudinal ligament in 43 North Americans. *Spine*. 1994;19:664–72.
5. Belanger TA, Roh JS, Hanks SE, Kang JD, Emery SE, Bohlman HH. Ossification of the posterior longitudinal ligament. Results of anterior cervical decompression and arthrodesis in sixty-one North American patients. *J Bone Joint Surg, Am*. 2005;87:610–5.
6. Fujiyoshi T, Yamazaki M, Kawabe J, Endo T, Furuya T, Koda M, et al. A new concept for making decisions regarding the surgical approach for cervical ossification of the posterior longitudinal ligament: the K-line. *Spine*. 2008;33:E990–3.
7. Lee DH, Joo YS, Hwang CJ, Lee CS, Cho JH. A novel technique to correct kyphosis in cervical myelopathy due to continuous-type ossification of the posterior longitudinal ligament. *J Neurosurg Spine*. 2017;26:325–30.
8. Koda M, Furuya T, Saito J, Ijima Y, Kitamura M, Ohtori S, et al. Postoperative K-line conversion from negative to positive is independently associated with a better surgical outcome after posterior decompression with instrumented fusion for K-line negative cervical ossification of the posterior ligament. *Eur Spine J*. 2018;27:1393–400.
9. Iwasaki M, Okuda S, Miyauchi A, et al. Surgical strategy for cervical myelopathy due to ossification of the posterior longitudinal ligament: part 2: advantages of anterior decompression and fusion over laminoplasty. *Spine*. 2007;32:654–60.
10. Choi BW, Song KJ, Chang H. Ossification of the posterior longitudinal ligament: a review of literature. *Asian Spine J*. 2011;5:267–76.
11. Woods BI, Hohl J, Lee J, Donaldson W 3rd, Kang J. Laminoplasty versus laminectomy and fusion for multilevel cervical spondylotic myelopathy. *Clin Orthop Relat Res*. 2011;469:688–95.
12. Liu X, Wang H, Zhou Z, Jin A. Anterior decompression and fusion versus posterior laminoplasty for multilevel cervical compressive myelopathy. *Orthopedics*. 2014;37:e117–22.
13. Lawrence BD, Shamji MF, Traynelis VC, Yoon ST, Rhee JM, Chapman JR, et al. Surgical management of degenerative cervical myelopathy: a consensus statement. *Spine*. 2013;38:S171–2.
14. Emery SE. Anterior approaches for cervical spondylotic myelopathy: which? When? How? *Eur Spine J*. 2015;24(Suppl 2):150–9.
15. Lee SH, Kim KT, Lee JH, Kang KC, Jang SJ, Hwang SP, et al. 540° cervical realignment procedure for extensive cervical OPLL with kyphotic deformity. *Spine*. 2016;41:1876–83.
16. Cardoso MJ, Koski TR, Ganju A, Liu JC. Approach-related complications after decompression for cervical ossification of the posterior longitudinal ligament. *Neurosurg Focus*. 2011;30:E12.
17. Mazur M, Jost GF, Schmidt MH, Bisson EF. Management of cerebrospinal fluid leaks after anterior decompression for ossification of the posterior longitudinal ligament: a review of the literature. *Neurosurg Focus*. 2011;30:E13.
18. Kawaguchi Y, Nakano M, Yasuda T, Seki S, Hori T, Kimura T. Anterior decompressive surgery after cervical laminoplasty in patients with ossification of the posterior longitudinal ligament. *Spine J*. 2014;14:955–63.
19. Iwasaki M, Kawaguchi Y, Kimura T, Yonenobu K. Long-term results of expansive laminoplasty for ossification of the posterior longitudinal ligament of the cervical spine: more than 10 years follow up. *J Neurosurg*. 2002;96:180–9.
20. Imagama S, Matsuyama Y, Yukawa Y, Kawakami N, Kamiya M, Kanemura T, et al. C5 palsy after cervical laminoplasty: a multicentre study. *J Bone Joint Surg, Br*. 2010;92:393–400.
21. Seichi A, Hoshino Y, Kimura A, Nakahara S, Watanabe M, Kato T, et al. Neurological complications of cervical laminoplasty for patients with ossification of the posterior longitudinal ligament—a multi-institutional retrospective study. *Spine*. 2011;36:E998–1003.
22. Head J, Rymarczuk G, Stricsek G, Velagapudi L, Maulucci C, Hoelscher C, et al. Ossification of the posterior longitudinal ligament: surgical approaches and associated complications. *Neurospine*. 2019;16:517–29.
23. Yamazaki A, Homma T, Uchiyama S, Katsumi Y, Okumura H. Morphologic limitations of posterior decompression by midsagittal splitting method for myelopathy caused by ossification of the posterior longitudinal ligament in the cervical spine. *Spine*. 1999;24:32–4.
24. Tani T, Ushida T, Ishida K, Iai H, Noguchi T, Yamamoto H. Relative safety of anterior microsurgical decompression versus laminoplasty for cervical myelopathy with a massive ossified posterior longitudinal ligament. *Spine*. 2002;27:2491–8.
25. Koda M, Mochizuki M, Konishi H, Aiba A, Kadota R, Inada T, et al. Comparison of clinical outcomes between laminoplasty, posterior decompression with instrumented fusion, and anterior decompression with fusion for K-line (–) cervical ossification of the posterior longitudinal ligament. *Eur Spine J*. 2016;25:2294–301.
26. Sodeyama T, Goto S, Mochizuki M, Takahashi J, Moriya H. Effect of decompression enlargement laminoplasty for posterior shifting of the spinal cord. *Spine*. 1999;24:1527–31. discussion 1531-1532.
27. Chen Y, Guo Y, Chen D, Wang X, Lu X, Yuan W. Long-term outcome of laminectomy and instrumented fusion for cervical ossification of the posterior longitudinal ligament. *Int Orthop*. 2009;33:1075–80.
28. Kawaguchi Y, Matsumoto M, Iwasaki M, Izumi T, Okawa A, Matsunaga S, et al. New classification system for ossification of the posterior longitudinal ligament using CT images. *J Orthop Sci*. 2014;19:530–6.
29. Ijima Y, Furuya T, Ota M, Maki S, Saito J, Kitamura M, et al. The K-line in the cervical ossification of the posterior longitudinal ligament is different on plain radiographs and CT images. *J Spine Surg*. 2018;4:403–7.
30. Chen Y, Guo Y, Lu X, Chen D, Song D, Shi J, et al. Surgical strategy for multilevel severe ossification of posterior longitudinal ligament in the cervical spine. *J Spinal Disord Tech*. 2011;24:24–30.
31. Sakai K, Okawa A, Takahashi M, Arai Y, Kawabata S, Enomoto M, et al. Five-year follow-up evaluation of surgical treatment for cervical myelopathy caused by ossification of the posterior longitudinal ligament: a prospective comparative study of anterior decompression and fusion with floating method versus laminoplasty. *Spine*. 2012;37:367–76.
32. Tsuzuki N, Abe R, Saiki K, Zhongshi L. Extradural tethering effect as one mechanism of radiculopathy complicating posterior decompression of the cervical spinal cord. *Spine*. 1996;21:203–11.
33. Zhao J, Zhao Q, Liu Z, Deng S, Cheng L, Zhu W, et al. The anatomical mechanism of C5 palsy after expansive open-door laminoplasty. *Spine J*. 2020; 20:1776–84.
34. Virk S, Lafage R, Elysee J, Louie P, Kim HJ, Albert T, et al. The 3 sagittal morphotypes that define the normal cervical spine: a systematic review of the literature and an analysis of asymptomatic volunteers. *J Bone Joint Surg, Am*. 2020;102:e109.