

A case of polypoid and papillary cystitis mimicking an advanced bladder carcinoma with invasion of perivesical fat

Kumi Ozaki^{1,2}, Kiyohide Kitagawa¹, Toshifumi Gabata², Osamu Matsui²

Departments of Radiology, ¹Kouseiren Takaoka Hospital, Takaoka, ²Kanazawa University Graduate School of Medical Science, Ishikawa, Japan

Abstract

A rare case of polypoid and papillary cystitis without a history of catheterization is reported. A 69-year-old man was admitted to our hospital because of pain during urination and gross hematuria. The cystoscopic and imaging findings including ultrasound, CT, and MR image showed an irregular wall thickening and stranding in the perivesical fat, which indicated an advanced bladder carcinoma, but histopathological findings obtained by transurethral resection revealed polypoid and papillary cystitis. Such benign lesions need to be discussed in the differential diagnosis of patients with bladder tumor to avoid excessive resection.

Key Words: Bladder carcinoma, MR imaging, perivesical fat stranding, polypoid and papillary cystitis

Address for correspondence:

Dr. Kumi Ozaki, Department of Radiology, Kanazawa University Graduate School of Medical Science, 13-1 Takara-Machi, Kanazawa, Ishikawa, Japan.
E-mail: ozakik-rad@umin.org

Received: 25.04.2012, Accepted: 21.07.2012

INTRODUCTION

Polypoid and papillary cystitis is defined as nonspecific mucosal reaction secondary to chronically inflamed bladder, with grossly noted polypoid or papillary lesions.^[1] It is common and tends to be more frequent and severe with repeated catheterization, but not always due to bladder catheterization.^[2] On imaging, it sometimes presents a mass mimicking various papillary urothelial neoplasms and is preoperatively misdiagnosed as bladder carcinoma.^[3] We report a case of polypoid and papillary cystitis without any relevant history of catheterization, and describe the CT and MR imaging findings.

CASE REPORT

A 69-year-old man was admitted to our hospital because of

pain during urination and gross hematuria. There was no relevant medical history and no presenting complaints. Routine urine examination was positive for red blood cells and showed the absence of white blood cell, protein, and glucose. Blood urea, serum creatinine, and other biochemical blood tests showed no abnormal findings. There was no clinical sign of infection and no history of bladder catheterization. Ultrasound showed an irregular and isoechoic thickening of the left side of the bladder wall. Cystoscopic examination suggested a broad expanding mass on the left side of the bladder wall. Pre- and postcontrasted CT images revealed an irregular thickening of the left side of the bladder wall and an increased density of a surrounding fat tissue [Figure 1]. The irregular wall thickening showed isointensity relative to the bladder wall on T1-weighted images [Figure 2a], and inhomogeneous hypointensity on T2-weighted images [Figure 2b], and gradual and inhomogeneous enhancement were seen on dynamic contrast study [Figure 2c]. In addition, there was obliteration of the normal hypointensity of the muscle layer of the bladder wall on T2-weighted images [Figure 2b]. Furthermore, T1- and T2-weighted images including dynamic contrast study showed a stranding of perivesical fat [Figure 2a and b], which suggested the perivesical fat invasion. The results of urine cytology showed no malignancy. However, imaging findings suggested

Access this article online

Quick Response Code:



Website:

www.urologyannals.com

DOI:

10.4103/0974-7796.127016

an advanced bladder carcinoma invading muscle layer and perivesical fat.

Transurethral partial resection of the bladder tumor was performed to obtain a histological diagnosis. Pathologic examination revealed a polypoid or papillary appearance of the mucosa, with submucosal edematous changes, neutrophil invasions, and granulomatous formations [Figure 3a and b]. The patient was diagnosed as having a polypoid and papillary cystitis.

He was followed closely without any treatment, and both the irregular thickening of the bladder wall and the stranding of a surrounding adipose tissue nearly-disappeared on MR and cystoscopic findings after 3 months [Figure 2d].

DISCUSSION

According to some urological or pathological reports, a polypoid and papillary cystitis itself is not uncommon, especially in a patient with a history of long-standing catheterization.^[4-7] However, clinical features were nonspecific,^[2,8] and in the present case, as there was no history of catheterization, the diagnosis was difficult. In addition, the reports about imaging findings are very few because the cystitis rarely makes the gross mass. The only previous report about imaging findings described by Kim *et al.*^[3] showed large polypoid mass with a narrow stalk, in which hemorrhagic infarct and the edematous fibrovascular core were histologically observed, unlike in our case. The features were quite different from the present case, which showed a broad expanding mass with the change of the muscle layer and perivesical fat. Neither hemorrhagic infarct nor the edematous fibrovascular core was histologically detected in the present case. Although the typical imaging findings of polypoid and papillary cystitis have not been established, in general, the muscle layer in cystitis should be intact.^[3,9] Because the cystitis lies mainly in the mucosa and/or submucosa, this finding is considered to be the characteristic feature that distinguishes cystitis from urothelial carcinoma.^[3,9] So, the partial obliteration of the bladder wall and the stranding of perivesical fat in the present case, which strongly suggested the bladder carcinoma, might reflect the extension of the inflammation. In addition, the absence of the diffusion-weighted images and positron emission tomographic images might make the diagnosis difficult.

A usual treatment consists of removing the source of irritation and surgical excision or cystectomy in rare severely involved cases.^[9] The present irregular wall thickening and stranding of perivesical fat disappeared on MR imaging after 3 months' follow-up without any treatment.

CONCLUSION

Polypoid and papillary cystitis should be considered in the

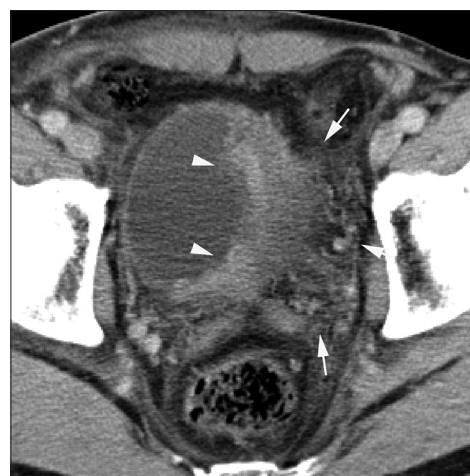

Figure 1: Postcontrasted CT image revealing an irregular thickening of the left side of the bladder wall (arrowheads) and a stranding of a surrounding fat tissue (arrows)

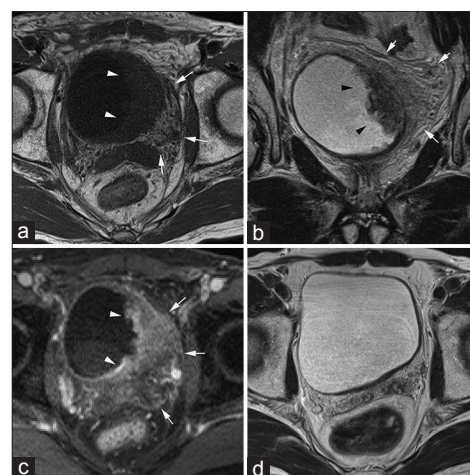


Figure 2: (a) On axial T1-weighted image, the irregular thickening of the bladder wall showing isointensity (arrowheads), and the stranding of a surrounding fat tissue is also seen (arrows) (b) On coronal T2-weighted image, the irregular thickening of the wall showing hypointensity (arrowheads). The stranding of a surrounding fat tissue is seen (arrows). The obliteration of the normal hypointensity of the muscle layer adjacent to the mass is also seen (c) The irregular thickening of the bladder wall showing a gradual and inhomogeneous enhancement (arrowheads) on equilibrium phase of the dynamic contrast study. The stranding of a surrounding fat tissue is also seen (arrows) (d) The both the irregular thickening of the bladder wall and the stranding of a surrounding adipose tissue was nearly disappeared on MR image without any treatment after three months

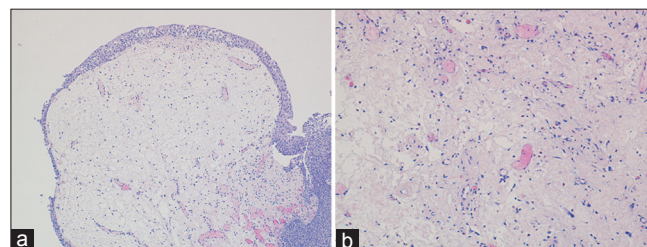


Figure 3: Pathological figures with low (a) and high (b) magnification showing a polypoid or papillary appearance of the mucosa, an edematous change, neutrophil invasion, and granulomatous formation. The patient is diagnosed as a polypoid and papillary cystitis

differential diagnosis of transitional cell carcinoma of the bladder, and a biopsy is necessary for a definitive diagnosis. Further case accumulation is required for elucidation of the typical imaging findings of this rare lesion and its correct diagnosis.

REFERENCES

1. Lane Z, Epstein JI. Polypoid/papillary cystitis: A series of 41 cases misdiagnosed as papillary urothelialneoplasia. *Am J Surg Pathol* 2008;32:758-64.
2. Kiliç S, Erguvan R, Ipek D, Gökçe H, Güneş A, Aydın NE, *et al.* Polypoid cystitis unrelated to indwelling catheters: A report of eight patients. *Int Urol Nephrol* 2002;34:293-7.
3. Kim SH, Yang DM, Kim NR. Polypoid and papillary cystitis mimicking a large transitional carcinoma in a patient without a history of catheterization: Computed tomography and magnetic resonance findings. *J Comput Assist Tomogr* 2004;28:485-7.
4. Young RH. Papillary and polypoid cystitis. A report of eight cases. *Am J Surg Pathol* 1988;12:542-6.
5. Ekelund P, Johansson S. Polypoid cystitis: A catheter associated lesion of the human bladder. *Acta Pathol Microbiol Scand* 1979;87:179-84.
6. Buck EG. Polypoid cystitis mimicking transitional cell carcinoma. *J Urol* 1984;131:963.
7. Abu-Yousef MM, Narayana AS, Brown RC. Catheter-induced cystitis: Evaluation by cystosonography. *Radiology* 1984;151:471-3.
8. Waisman SS, Banco J, Gromie WJ. Single polypoid cystitis cystica and glandularis presenting as benign bladder tumor. *Urology* 1990;36:364-6.
9. Wong-You-Cheong JJ, Woodward PJ, Manning MA, Davis CJ. Inflammatory and nonneoplastic bladder masses: Radiologic-pathologic correlation. *Radiographics* 2006;26:1847-68.

How to cite this article: Ozaki K, Kitagawa K, Gabata T, Matsui O. A case of polypoid and papillary cystitis mimicking an advanced bladder carcinoma with invasion of perivesical fat. *Urol Ann* 2014;6:72-4.

Source of Support: Nil, **Conflict of Interest:** None.