



A good surgical option for ischemic mitral regurgitation in co-morbid patients: semicircular reduction annuloplasty

Bilgin Emreca¹, Gokhan Onem¹, Ahmet Coskun Ozdemir², İsmail Doğu Kılıç³, Yusuf İzzettin Alihanoglu³

¹Department of Cardiac and Vascular Surgery, Pamukkale University, Kınıklı, Denizli 20070, Turkey

²Department of Cardiac and Vascular surgery, Denizli Cerrahi Hastanesi, Acipayam yolu 5, Bağbaşı, Denizli 20225, Turkey

³Department of Cardiology, Pamukkale University, Kınıklı, Denizli 20070, Turkey

Abstract

Background Ring annuloplasty is the standard treatment of ischemic mitral regurgitation (MR), however, it has been associated with some drawbacks. It abolishes normal annular dynamics and freezes the posterior leaflet. In the present study, we evaluated Paneth suture annuloplasty in chronic ischemic MR and both early and mid-term outcomes of the technique on a selected population. **Methods** The study period was from June 2010 to June 2012. We operated on 21 patients who had the diagnosis of coronary artery disease and MR of grade 3 or 4. The patients had both a coronary artery bypass operation and the mitral semicircular reduction annuloplasty described by Paneth-Burr. The data on the patients were retrospectively collected. Patients were contacted by outpatient clinic controls for mid-term results. **Results** The male/female ratio was 10/11. The mean age of the patients was 71.0 ± 6.4 years. Preoperative and postoperative left ventricular ejection fraction was statistically similar ($P = 0.973$). Early postoperative MR grade (mean, 0.57 ± 0.51) was statistically lower than the preoperative MR grades (mean, 3.38 ± 0.50) ($P < 0.001$). There was no revision for excess bleeding. Two patients had prolonged hospitalization, one for sternal infection and the other for severe chronic obstructive pulmonary disease. No hospital or late postoperative deaths occurred. The mean late postoperative MR grade was 0.66 ± 0.97 degrees. One patient had progression of MR in the later follow-up, which was treated by mitral valve replacement. **Conclusion** Semicircular reduction annuloplasty is an effective, inexpensive and easy surgical annuloplasty technique with low mortality and morbidity in severe symptomatic ischemic MR.

J Geriatr Cardiol 2013; 10: 141–145. doi: 10.3969/j.issn.1671-5411.2013.02.002

Keywords: Mitral valve; Surgery; Myocardial ischemia

1 Introduction

The best method for surgical correction of mitral regurgitation (MR) is repair because it does not require anticoagulation and carries a lower risk of late death and valve-related morbidity.^[1] Annuloplasty is an essential component of mitral valve repair whether it is performed with, or without, a prosthetic ring. Currently, ring annuloplasty is considered as the gold standard although some unfavorable pathophysiologic effects have been identified in experimental and clinical studies.^[2] On the other hand, suture annuloplasty is preferred by some authors for some of

its advantages.^[3,4]

Ischemic MR results from myocardial infarction or ischemia.^[5] It is associated with separation, or weak, coaptation of the anterior and posterior leaflets.^[6] Long-term survival is poor despite medical or surgical treatment in ischemic MR.^[5] The mechanism of MR in chronic ischemic disease has been described as local left ventricular remodeling (apical and posterior displacement of papillary muscles), which leads to excess valvular tenting and loss of systolic annular contraction.^[7]

In the present study, we retrospectively evaluated the outcomes of patients who had both coronary artery bypass surgery (CABG) and semicircular posterior annular reduction surgery for ischemic MR.

2 Methods

2.1 Patients

Between June 2010 and June 2012, a total of 21 patients

Correspondence to: Bilgin Emreca, MD, Associate Professor, Pamukkale University, Department of Cardiac and Vascular Surgery, Denizli 20070, Turkey. E-mail: bilginemreca@yahoo.com

Telephone: +90-5054889916 **Fax:** +90-2582961765

Received: September 13, 2012 **Revised:** October 23, 2012

Accepted: December 3, 2012 **Published online:** May 24, 2013

who underwent open heart surgery for coronary artery disease and ischemic mitral valve insufficiency were included in the study. These patients had both coronary artery revascularization and mitral semicircular Paneth-Burr annuloplasty.^[7] Patients with aortic valve disease, ascending aorta disease, chordal or papillary muscle rupture, left ventricle aneurysm, and patients who had had previous cardiac operation were excluded from the study. Preoperative demographic and echocardiographic data on the patients, and operative and postoperative in-hospital data were retrospectively collected. Postoperative outpatient visits were evaluated. Patients were called by outpatient clinic controls if they had missed their control visits. Collected data were analyzed with statistical software SPSS. Continuous variables were expressed as mean \pm SD. Preoperative and postoperative values were compared with repeated measures test in general linear model. $P < 0.05$ was considered as statistically significant.

2.2 Surgical technique

The operations were done under general anesthesia and intra-tracheal intubation. Median sternotomy was done. Bypass grafts were prepared before cardiopulmonary bypass (CPB). Anticoagulation was accomplished with heparin until a target activated clotting time of a minimum 450 s was achieved. Standard ascending aorta and bicaval cannulations were done. Standard cardiopulmonary bypass techniques were used for the operations. The patients were cooled to 30°C–32°C. Antegrade isothermic hiperpotassemic blood cardioplegia was used for myocardial protection.

Mitral valve was explored after coronary artery distal anastomosis had been done, except for distal anastomosis of left anterior descending artery (LAD). The left internal thoracic artery was used for LAD revascularization in all patients. Saphenous vein grafts were used for the other vessel revascularizations. No jump or sequential anastomosis was done. Every saphenous vein graft was proximally anastomosed to the aorta. The technique for mitral valve repair has been previously described.^[8] The mitral valve was accessed *via* left atriotomy made through the interatrial groove. Mitral posterior annulus was constricted with two 2-0 polyfilament polyester pledgetted sutures starting from each commissure. One end of the suture was spirally coiled both around the annulus and the other end of the suture. Both sutures met at the midpoint of the posterior annulus and were tied with a pledget until a good coaptation was attained (Figure 1). The coaptation of the valve was checked by filling the left ventricle with saline. After finishing the valvular repair, LAD anastomosis was done.

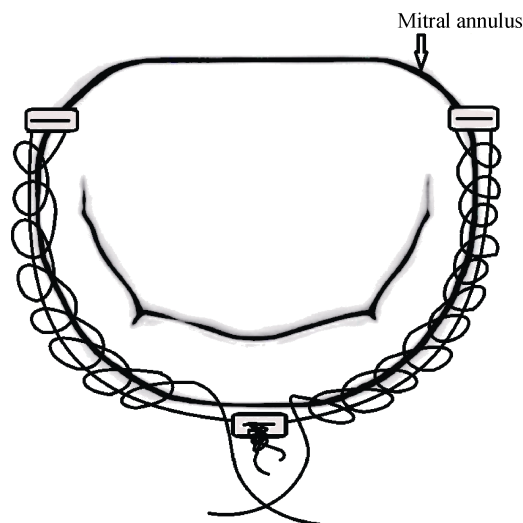


Figure 1. Semicircular reduction annuloplasty.

3 Results

During the study period, 21 patients who met the inclusion criteria were evaluated. Male/ female ratio was 10/11. Mean age of the patients was 71.0 ± 6.4 years (range 58–84 years). Preoperative risk factors were peripheral artery disease (3 patients), chronic obstructive pulmonary disease (4 patients), smoking (8 patients), diabetes (11 patients) and hypercholesterolemia (9 patients). Four of the patients had previous elective percutaneous coronary intervention.

Preoperative echocardiographic data of the patients are found in the Table 1. All patients had mitral repair and coronary artery bypass operations. The mean number of revascularized coronary artery was 3.14 ± 0.73 (range; 2–4). Three patients had tricuspid valve repair as well. One patient had left atrial radiofrequency ablation for atrial fibrillation, which remained in sinus rhythm in the postoperative period.

Table 1. Preoperative echocardiographic data of the patients ($n = 21$).

	Mean	Minimum	Maximum
Preoperative MR degree	3.38 ± 0.50	3	4
LVESD (mm)	41.8 ± 6.8	30	56
LVEDD (mm)	54.5 ± 6.8	44	71
Left atrial diameter (mm)	47.4 ± 6.6	34	60
Preoperative LVEF (%)	45 ± 11	20	63

LVEF: left ventricular ejection fraction; LVESD: left ventricle end systolic diameter; LVEDD: left ventricle end diastolic diameter; MR: mitral regurgitation.

Preoperative and postoperative left ventricular ejection fraction was statistically similar ($P = 0.973$). Early postoperative MR grade was statistically lower than the preoperative values ($P < 0.001$). There was no revision for excess bleeding. Two patients had prolonged hospitalization, one for sternal infection and the other for severe chronic obstructive pulmonary disease. There was neither in-hospital nor follow-up mortality. There was no perioperative myocardial infarction demonstrated by myocardial markers or electrocardiographic evaluations. None of the patients needed control coronary angiography; therefore graft patency could not be exhibited. There was no systolic anterior motion of the mitral valve in the control echocardiographic evaluation. None of the patients had atrioventricular block in the postoperative period. The postoperative follow-up period was 11.9 ± 5.0 months. Mean late postoperative MR grade was 0.66 ± 0.97 degrees. One patient had progression of MR in the later follow-up. Early echocardiographic control of this patient showed improvement of MR from four degrees to one degree early after the operation, which later became four degrees in the 18th month. She had mitral valve replacement due to progression of the symptoms despite medical therapy. She had uneventful recovery after the second operation. Operative and postoperative data of the patients are presented in Table 2.

Table 2. Operative and postoperative data of the patients ($n = 21$).

	Mean	Minimum	Maximum
Cross clamp time (min)	79.8 ± 21.0	46	123
CPB time (min)	118.5 ± 24.1	75	165
Number of distal anastomosis	3.14 ± 0.73	2	4
Early postoperative MR degree	0.57 ± 0.51	0	1
Late postoperative MR degree	0.66 ± 0.97	0	4
Postop LVESD (mm)	39.8 ± 5.6	30	52
Postop LVEDD (mm)	52.6 ± 5.8	44	65
Postop left atrial diameter (mm)	43.3 ± 5.9	32	52
Postoperative LVEF(%)	45 ± 9	25	60
Total amount of bleeding (mL)	782 ± 214	400	1100
Intensive care unit follow-up (day)	2.86 ± 2.33	1	12
Postoperative hospitalization (day)	10.29 ± 4.6	6	20
Late follow-up (month)	11.9 ± 5.0	3	21

CPB: cardiopulmonary bypass; LVEF: left ventricular ejection fraction; LVEDD: left ventricle end diastolic diameter; LVESD: left ventricle end systolic diameter.

4 Discussion

Within a limited population, we succeeded in achieving near excellent results with semicircular reduction annuloplasty in ischemic MR. As reported in the other studies, mitral valve reconstruction, whenever feasible, is the surgical treatment of choice for MR. Recently, there have been reports of favorable results concerning suture annuloplasty. Some authors have used this annuloplasty suture for the reduction of the posterior ring size after mitral valve repair. Some authors suggest that suture annuloplasty does not seem to adversely affect the results of mitral valve repair; besides it might decrease the risk of postoperative endocarditis and embolic events.^[9] Some authors blamed the suture material for redilatation of the annulus due to stretching of polypropylene material. Therefore, these authors used the polytetrafluoroethylene (GoreTex[®]) suture as the best material to prevent redilatation.^[10] In our patients, we used polyfilament polyester pledgetted sutures for annuloplasty. These sutures are standard in valve replacement operations and they may also resist stretching. We have not encountered any problem of redilatation, except for one among twenty-one patients. This patient may have (undergone) ventricular remodeling, which might have increased the MR grade.

Matsuda *et al.*^[11] reported increased MR grade in large intraoperative annular sized patients, especially patients presenting 90% larger than that of normal. In patients with lower annular sizes, only increment has been in ischemic etiology. In our series, only one patient had an increment in the MR grade, although all patients were in ischemic etiology.

Risk factors blamed for reoperation are: no use of prosthetic ring, correction of the prolapse of the anterior leaflet by triangular resection or chordal shortening and ischemic etiology of the mitral insufficiency.^[12] In our series, we did not use rings and the patients were ischemic in etiology. Long term results are lacking in the present study and, therefore, it is premature to conclude about long term outcome, although early results are acceptable.

In a study, evaluation of systemic co-morbidities has resulted in better outcomes in octogenarians who undergo CABG.^[13] The mean age of the patients was 71 years and older. Patients, as in our study group, without a prosthesis and undergoing a rapid surgical procedure probably may recover faster. Two patients had prolonged hospitalization to 20 days due to pulmonary complication and wound infection. Therefore, a simple and a fast repair technique may be speculated to have better outcomes when compared to a longer replacement or repair technique. In our experience,

semicircular reduction may be done in 10–15 min. As seen in this study population, most of the patients had co-morbidities and were of advanced age, thus, the shortening of the surgical duration would (be advantageous) for these patients.

Ring annuloplasty significantly increases the mitral gradient and decreases the valve area. Ring prosthesis is a potential site of thrombus or pannus formation, infection, or hemolysis and, rarely, late fibrosis and calcification at the ring implantation site. Other disadvantages are ring dehiscence and higher expense. These complications may be eliminated by a simple reduction annuloplasty technique.

Semicircular reduction annuloplasty offers less leaflet and chordal stress, and improved left ventricular filling. It also preserves physiologic leaflet opening and closing dynamic timing.^[2] Posterior leaflet length correction has been found to correct bi-leaflet prolapse in patients with normal anterior cornea.^[1] In an experimental model of acute ischemic MR, semicircular reduction annuloplasty has maintained physiological posterior leaflet dynamics probably due to residual flexibility of the muscular (or posterior) mitral annulus. The lesser degree of annular reduction required by the Paneth suture annuloplasty may allow preservation of shortening of the mitral annular diameters.^[14] In addition to this, annular growth has been reported after suture annuloplasty in the pediatric population.^[15] This annular growth may be an advantage to rings, however, it may also be a disadvantage because of the potential for annular redilatation after annuloplasty.^[4] Surgical annuloplasty is effective in reversing ischemic MR, but the procedure does not address tethering, which is a component of ischemic MR. Advanced tethering is, therefore, speculated to result in persistent ischemic MR even after ring annuloplasty with, or without, downsizing. On the other hand, the posterior annular suture annuloplasty technique has shown 95.1% freedom from reoperation, and an 87.2% actuarial survival at 77 months.^[6]

Whether to operate on mitral valves in patients who undergo CABG with mild to moderate MR is still unclear, but such patients have benefitted from mitral repair. The patients with ischemic MR have also worse prognosis than those who do not have MR. CABG alone is insufficient and many patients have significant residual MR after the operation. Concomitant MV repair is suggested at the time of the CABG for these patients. Mitral annuloplasty alone with a downsized annuloplasty ring is often effective at relieving MR.^[7] In ischemic mitral insufficiency and moderately impaired LV function, the goal of mitral valve repair is to reduce valvular insufficiency to at least grade I. Otherwise, the prognosis of repair is reported to be worse than valve

replacement.^[16] In our series, the postoperative mean MR grade was lower than grade I. One patient had severe MR in the late postoperative period, which needed surgically correction.

CABG associated with ring annuloplasty has shown good survival and improved functional capacity in ischemic dilated cardiomyopathy.^[17] Semicircular reductive annuloplasty has also been reported as beneficial in selective patients with ischemic dilated cardiomyopathy. The elimination of valvular incompetence combined with CABG has resulted in improvement of immediate and long-term morbidity and mortality.^[18] We did not have any patients with ischemic dilated cardiomyopathy in the study population. However, we had patients with low left ventricular ejection fractions. Only one patient had an ejection fraction of 20% who needed intra-aortic balloon counterpulsation support during termination of CPB. This patient was also discharged on the 16th day after the operation without any other complication.

Patients over 75 years of age who had mitral repair have lower risk of mortality, postoperative stroke, and shorter intensive care unit and hospital stays compared with mitral valve replacement. Therefore, mitral repair has been suggested for patients over 75 years.^[19] Moreover, the benefits of mitral valve intervention in severe chronic ischemic MR have been well established. Therefore, an easily applicable (less complex) mitral valve repair procedure would probably be beneficial for the patients who are candidates for CABG operation no matter what their age. In a study comparing MitraClip with surgery, actuarial freedom from third degree MR at one year was determined as 79.1% for MitraClip and 94% for surgery ($P = 0.01$). In-hospital mortality has been reported as 6.6% for surgery (6/91) and 0% for MitraClip ($P = 0.01$). One year survival, however, has been found as 88.9% for surgery and 87.5% for MitraClip ($P = 0.6$). The authors concluded that the early and 1-year rates of recurrent MR were higher with MitraClip, but further studies were needed for the long-term clinical impact.^[20]

As a conclusion, in severe symptomatic ischemic MR patients, semicircular reduction annuloplasty is a good surgical option with the advantages of being effective, inexpensive and not complex as well as a time saving procedure, especially in the patients who have co-morbidities and who may not tolerate longer CPB times.

References

- 1 Cho L, Gillinov AM, Cosgrove DM 3rd, *et al.* Echocardiographic assessment of the mechanisms of correction of bileaflet prolapse causing mitral regurgitation with only posterior leaflet repair surgery. *Am J Cardiol* 2000; 86: 1349–1351.

- 2 Fundarò P, Tartara PM, Villa E, *et al.* Mitral valve repair: is there still a place for suture annuloplasty? *Asian Cardiovasc Thorac Ann* 2007; 15: 351–358.
- 3 Nagy ZL, Bodi A, Vaszi M, *et al.* Five-year experience with a suture annuloplasty for mitral valve repair. *Scand Cardiovasc J* 2000; 34: 528–532.
- 4 Aybek T, Risteski P, Miskovic A, *et al.* Seven years' experience with suture annuloplasty for mitral valve repair. *J Thorac Cardiovasc Surg* 2006; 131: 99–106.
- 5 Bakhshandeh AR, Salehi M, Radmehr H, *et al.* Autologous ring vs. flexible prosthetic ring for ischemic mitral regurgitation. *Asian Cardiovasc Thorac Ann* 2010; 18: 127–130.
- 6 Otsuji Y, Levine RA, Takeuchi M, *et al.* Mechanism of ischemic mitral regurgitation. *J Cardiol* 2008; 51: 145–156.
- 7 American College of Cardiology/American Heart Association Task Force on Practice Guidelines; Society of Cardiovascular Anesthesiologists; Society for Cardiovascular Angiography and Interventions; Society of Thoracic Surgeons. Bonow RO, Carabello BA, Kanu C, *et al.* ACC/AHA 2006 guidelines for the management of patients with valvular heart disease: a report of the American College of Cardiology/American Heart Association Task Force on Practice Guidelines (writing committee to revise the 1998 Guidelines for the Management of Patients With Valvular Heart Disease): developed in collaboration with the Society of Cardiovascular Anesthesiologists; endorsed by the Society for Cardiovascular Angiography and Interventions and the Society of Thoracic Surgeons. *Circulation* 2006; 114: e84–e231.
- 8 Burr LH, Krayenbuhl C, Sutton MS. The mitral plication suture: a new technique of mitral valve repair. *J Thorac Cardiovasc Surg* 1977; 73: 589–595.
- 9 Duebener LF, Wendler O, Nikoloudakis N, *et al.* Mitral-valve repair without annuloplasty rings: results after repair of anterior leaflet versus posterior-leaflet defects using polytetrafluoroethylene sutures for chordal replacement. *Eur J Cardiothorac Surg* 2000; 17: 206–212.
- 10 Nagy ZL, Péterffy A. Mitral annuloplasty with a suture technique. *Eur J Cardiothorac Surg* 2000; 18: 739–741.
- 11 Matsuda H, Shintani H, Taniguchi K, *et al.* Semicircular suture annuloplasty for mitral regurgitation: appraisal of the Paneth-Burr method. *J Heart Valve Dis* 1997; 6: 48–53.
- 12 Fucci C, Sandrelli L, Pardini A, *et al.* Improved results with mitral valve repair using new surgical techniques. *Eur J Cardiothorac Surg* 1995; 9: 621–626 discuss 626–627.
- 13 Nicolini F, Molardi A, Verdichizzo D, *et al.* Coronary artery surgery in octogenarians: evolving strategies for the improvement in early and late results. *Heart Vessels* 2012; 27: 559–567.
- 14 Tibayan FA, Rodriguez F, Liang D, *et al.* Paneth suture annuloplasty abolishes acute ischemic mitral regurgitation but preserves annular and leaflet dynamics. *Circulation* 2003; 108 Suppl 1: II128–II133.
- 15 Komoda T, Huebler M, Berger F, *et al.* Growth of mitral annulus in the pediatric patient after suture annuloplasty of the entire posterior mitral annulus. *Interact Cardiovasc Thorac Surg* 2009; 9: 354–356.
- 16 Hausmann H, Siniawski H, Hetzer R. Mitral valve reconstruction and replacement for ischemic mitral insufficiency: seven years' follow up. *J Heart Valve Dis* 1999; 8: 536–542.
- 17 Nicolini F, Zoffoli G, Cagnoni G, *et al.* Mitral valve annuloplasty and myocardial revascularization in the treatment of ischemic dilated cardiomyopathy. *Heart Vessels* 2006; 21: 28–32.
- 18 Jonjev ZS, Mijatov M, Fabri M, *et al.* Systematic reductive annuloplasty of the mitral and tricuspid valves in patients with end-stage ischemic dilated cardiomyopathy. *J Card Surg* 2007; 22: 111–116.
- 19 Ailawadi G, Swenson BR, Girotti ME, *et al.* Is mitral valve repair superior to replacement in elderly patients? *Ann Thorac Surg* 2008; 86: 77–85.
- 20 Taramasso M, Denti P, Buzzatti N, *et al.* Mitraclip therapy and surgical mitral repair in patients with moderate to severe left ventricular failure causing functional mitral regurgitation: a single-centre experience. *Eur J Cardiothorac Surg* 2012; 42: 920–926.