

Received: 2017.08.02  
Accepted: 2017.11.16  
Published: 2018.03.12

e-ISSN 1941-5923  
© Am J Case Rep, 2018; 19: 284-288  
DOI: 10.12659/AJCR.906486

# A Case of Carcinoid Syndrome Due to Malignant Metastatic Carcinoid Tumor with Carcinoid Heart Disease Involving Four Cardiac Valves

Authors' Contribution:  
Study Design A  
Data Collection B  
Statistical Analysis C  
Data Interpretation D  
Manuscript Preparation E  
Literature Search F  
Funds Collection G

EF 1 **Brianna J. Shinn**  
E 2 **Laura J. Tafe**  
E 3 **Pantila Vanichakarn**

1 Department of Internal Medicine, The Commonwealth Medical College, Scranton, PA, U.S.A.  
2 Department of Pathology and Laboratory Medicine, Dartmouth-Hitchcock Medical Center, Lebanon, NH and The Geisel School of Medicine at Dartmouth, Hanover, NH, U.S.A.  
3 Department of Medicine, Krannert Institute of Cardiology, Indiana University School of Medicine, Indianapolis, IN, U.S.A.

**Corresponding Author:** Brianna J. Shinn, e-mail: [brianna.shinn@jefferson.edu](mailto:brianna.shinn@jefferson.edu)  
**Conflict of interest:** None declared

**Patient:** Female, 62  
**Final Diagnosis:** Carcinoid heart disease  
**Symptoms:** Abdominal discomfort • diarrhea • fatigue • weight loss  
**Medication:** —  
**Clinical Procedure:** —  
**Specialty:** Cardiology

**Objective:** Rare disease





**Background:** Carcinoid tumor, benign, low-grade malignant, and high-grade malignant, can be associated with the release of vasoactive substances that cause symptoms including cutaneous flushing, diarrhea, and bronchospasm. In 50–60% of patients with carcinoid syndrome, the vasoactive substances cause fibrosis of the pulmonary and tricuspid heart valves which lead to regurgitation and right-sided heart failure. The right side of the heart is usually affected because monoamine oxidases in the lungs usually inactivate the vasoactive substances.

**Case Report:** A 62-year-old woman presented with a four-month history of diarrhea and abdominal discomfort. The patient had bilateral pelvic masses and elevated serum CA125 and an elevated urinary 5-hydroxyindoleacetic acid (5-HIAA). Total abdominal hysterectomy (TAH) and bilateral salpingo-oophorectomy (BSO) identified a primary appendiceal carcinoid tumor with bilateral ovarian metastases. Post-operatively, a computed tomography (CT) scan showed cardiomegaly. Transthoracic echocardiography showed morphologic changes that affected all four heart valves, consistent with carcinoid heart disease but without a patent foramen ovale (PFO). The patient was evaluated for valve replacement surgery, but surgery was not performed due to the degree of heart failure.

**Conclusions:** This report describes a rare case of carcinoid heart disease with involvement of all four cardiac valves, but without the presence of a PFO, possibly due to a large amount of vasoactive substances in the patient's circulation, as supported by the patient's elevated urinary 5-HIAA. This rare presentation highlights the importance of early diagnosis and treatment with tumor resection and, if possible, Cardiac valve replacement to prevent irreversible heart failure.

**MeSH Keywords:** Carcinoid Heart Disease • Carcinoid Tumor • Heart Valve Diseases

**Full-text PDF:** <https://www.amjcaserep.com/abstract/index/idArt/906486>

 1952   7  9



## Background

Carcinoid tumors are rare, occurring in between 1.2–2.1 per 100,000 people in the general population per year [1]. Carcinoid tumors arise from enterochromaffin cells, with the most common primary site of origin being the gastrointestinal tract. Carcinoid tumors release vasoactive substances including serotonin, tachykinins, and prostaglandins, which are mainly inactivated in the liver and lungs [2]. In 20–30% of patients, the initial clinical manifestation of a carcinoid tumor is carcinoid syndrome which includes symptoms of cutaneous flushing, diarrhea, bronchospasm, and hypotension [1]. Symptoms of carcinoid syndrome typically occur when the tumor metastasizes to the liver and the vasoactive substances enter the systemic circulation [2].

Carcinoid heart disease remains a major source of morbidity and mortality for patients with carcinoid syndrome, occurs in 50–60% of patients with carcinoid syndrome, but most frequently involves the tricuspid and pulmonary valves [3]. Patients are often referred for valve replacement surgery before they develop heart failure, as valve replacement surgery is the most effective treatment [4].

In this report, a case of carcinoid heart disease is presented in a 62-year-old woman, with all four heart valves being affected. The patient had a primary appendiceal carcinoid tumor, which metastasized to both ovaries, but who did not have hepatic metastases or any form of intracardiac shunt. This rare presentation of carcinoid heart disease highlights the importance of early diagnosis and treatment with early carcinoid tumor resection and valve replacement to avoid significant heart failure.

## Case Report

A 62-year-old Caucasian woman presented to her primary care physician with a four-month history of diarrhea and abdominal discomfort. She reported passing stools 4–6 times per day and waking from sleep 4–5 times per night with diarrhea. She noted pain (severity, 8/10) along the right side of her abdomen. She also reported a lack of appetite, weight loss, abdominal bloating, extreme fatigue, and increased sleep. She denied any cutaneous flushing. An abdominal ultrasound was performed which showed ascites and a right pleural effusion. A computed tomography (CT) scan of the abdomen and pelvis showed two well-defined, low-density areas in the left lobe of the liver, which appeared to be cystic. There was a small enhancing focus in the upper anterior abdomen representing a possible omental metastasis, an 11.7×6.3 cm mass in the upper right pelvis, and a 6.7 cm midline mass in the lower pelvis. An omental biopsy and ultrasound-guided thoracentesis with cytology were performed. The omental biopsy showed

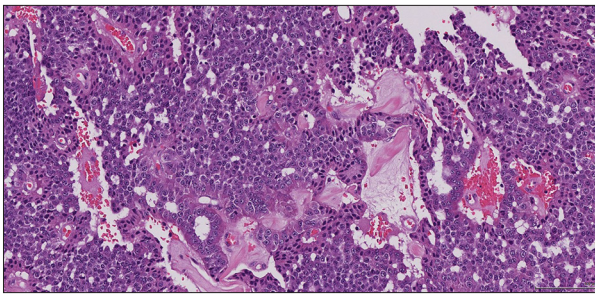
no evidence of malignancy. The thoracentesis drained 280 ml of thin serous pleural fluid, and the cytology showed atypical cells. The tumor markers Ca19-9 and carcinoembryonic antigen (CEA) were found to be within normal limits, at 25.6 U/ml and 1.4 ng/ml, respectively. However, CA125 was elevated at 1,030.0 IU/ml (normal, ≤35.0 IU/ml).

On the basis of these studies, the patient was scheduled to undergo a total abdominal hysterectomy (TAH) and bilateral salpingo-oophorectomy (BSO). At the time of surgery, the surgeon found 2,200 ml of ascites in the abdomen, a 12×5 cm right ovarian mass, and an 8×8 cm left ovarian mass. There were tumor nodules, measuring approximately 1 cm in size, involving the peritoneum and small bowel mesentery, a hyperemic appearing ileum with a tumor mass beneath the ileum and cecum, with the involvement of the appendix and extensive milary omental disease. Histology of a frozen section of the ovary diagnosed a carcinoid tumor. The patient also had an elevated plasma level of chromogranin A at 947 ng/ml (normal <93 ng/ml).

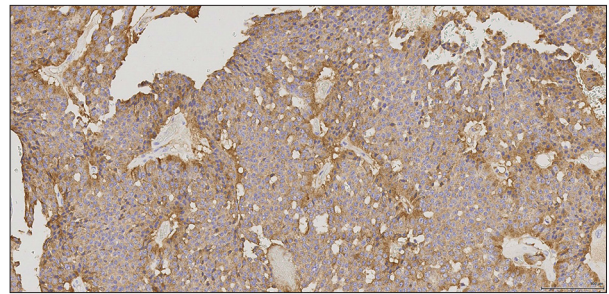
As the surgeon began to manipulate the appendix, the patient became hypotensive. She was given 500 mg of octreotide, which resulted in a positive response with stabilization of her vital signs. Because no octreotide had been given to the patient pre-operatively, and her disease was so advanced, the decision was made to not perform an omentectomy or resection of the primary appendiceal tumor. The patient tolerated the remainder of the procedure well. The final surgical pathology report was a metastatic carcinoid tumor involving both the left and right ovaries, which most likely to have metastasized from the appendix. The left ovarian mass was 10.3×6.1×4.8 cm and the right ovarian mass was 11.4×7.2×0.7 cm (Figure 1). Immunohistochemistry was performed and the tumor cells stained positively for both synaptophysin and chromogranin, which supported the diagnosis of carcinoid tumor (Figures 2, 3).

The following day, the patient underwent a computed tomography (CT) scan of the chest without contrast, which demonstrated a large right and a small left pleural effusion, cardiomegaly, abdominal ascites, but showed no pulmonary metastases. Magnetic resonance imaging (MRI) of the abdomen was performed which showed no hepatic metastases.

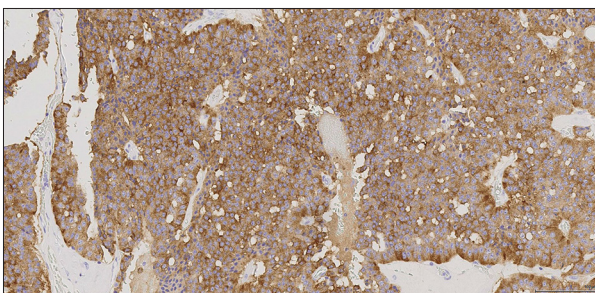
A transthoracic echocardiogram was ordered to evaluate the cardiomegaly found on the CT scan of the chest. The echocardiogram showed normal left ventricular size and systolic function. The right ventricle was moderately dilated with reduced systolic function (Figure 4). The tricuspid valve leaflets were thickened and non-mobile, consistent with carcinoid changes with severe tricuspid regurgitation (Figure 5). The pulmonary valve was not well visualized but appeared to be thickened



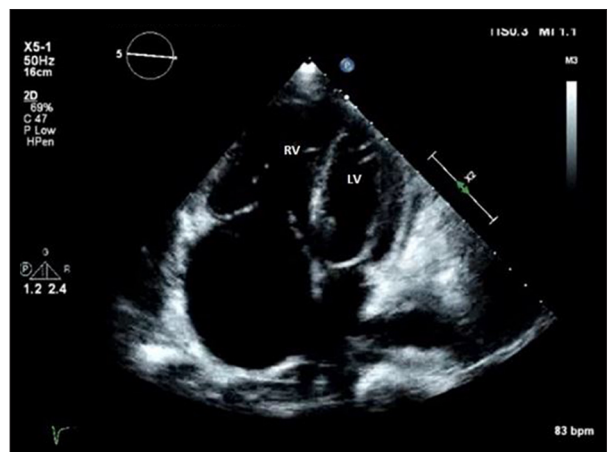
**Figure 1.** Photomicrograph of metastatic carcinoid tumor of the ovary. High power light microscopy of a tissue section of metastatic carcinoid tumor of the ovary. Hematoxylin and eosin (H&E) ×20 objective.



**Figure 3.** Photomicrograph of the immunohistochemical staining of metastatic carcinoid tumor of the ovary shows positive staining for chromogranin. High power light microscopy of a tissue section of metastatic carcinoid tumor of the ovary. Immunohistochemical staining shows positive staining of cells for chromogranin (brown). ×20 objective.

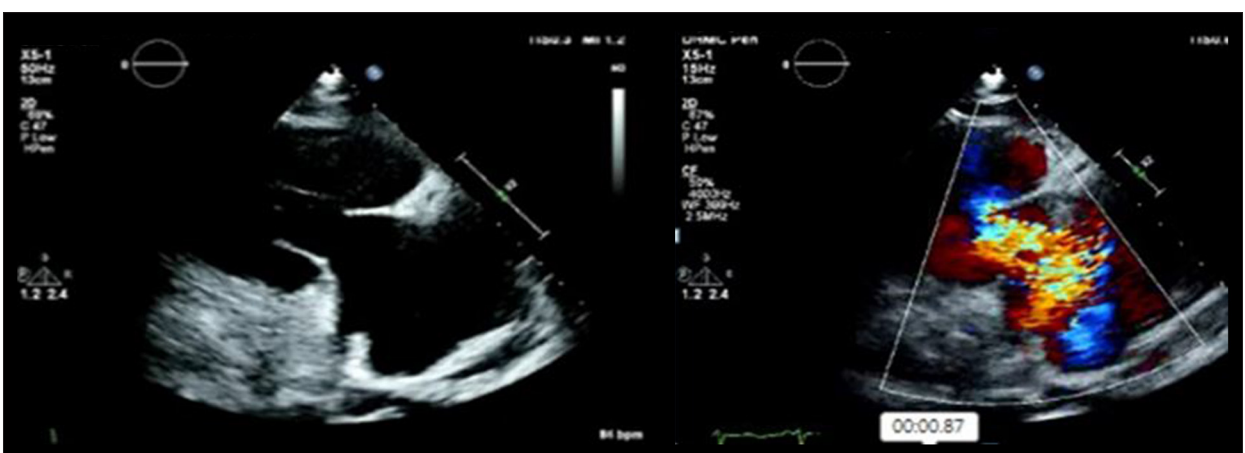

**Figure 2.** Photomicrograph of the immunohistochemical staining of metastatic carcinoid tumor of the ovary shows positive staining for synaptophysin. High power light microscopy of a tissue section of metastatic carcinoid tumor of the ovary. Immunohistochemical staining shows positive staining of cells for synaptophysin (brown). ×20 objective.

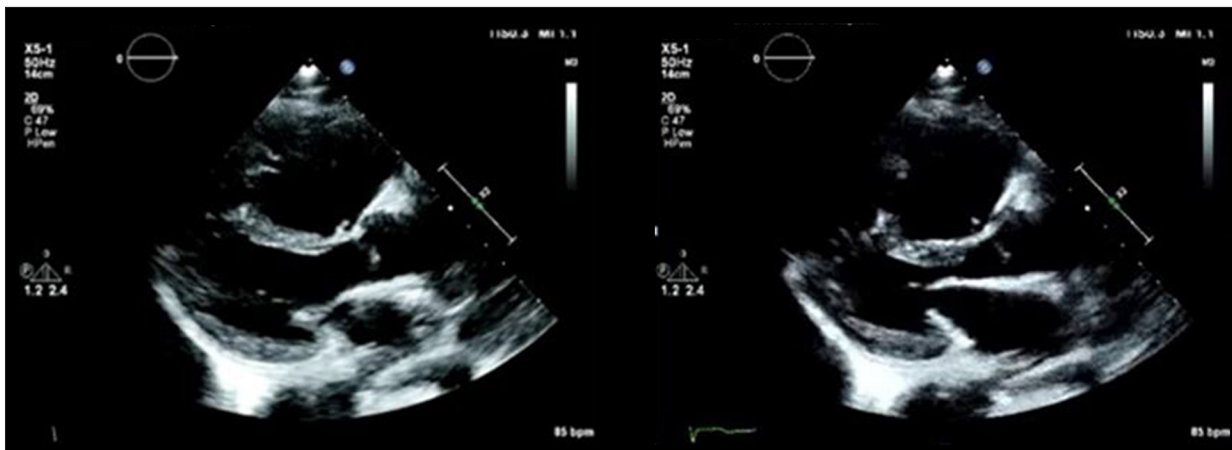

**Figure 4.** Transthoracic echocardiogram of the left and right ventricles. The left ventricle (LV) is normal in size, and systolic function is normal. The right ventricle (RV) is dilated with reduced systolic function.

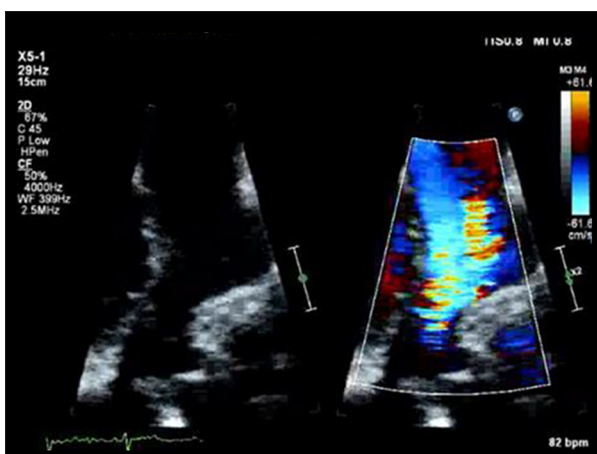
with severe pulmonic regurgitation. The posterior mitral valve leaflet also appeared thickened and non-mobile, and there was mild mitral regurgitation (Figure 6). The aortic valve was not well visualized, but there was moderate aortic regurgitation



**Figure 5.** Transthoracic echocardiogram of the tricuspid valve. The tricuspid valve leaflets are thickened and non-mobile. Severe tricuspid regurgitation is present.



**Figure 6.** Transthoracic echocardiogram of the mitral valve. The posterior mitral valve leaflet appears thickened and non-mobile during both systole and diastole.



**Figure 7.** Transthoracic echocardiogram of the aortic valve. Moderate to severe aortic regurgitation is present, but the aortic valve leaflets are not well visualized.

(Figure 7). There was no evidence of a patent foramen ovale (PFO) or an atrial septal defect (ASD) by color Doppler.

A cardiology consultation was requested on the following day for heart failure management. Clinically, the patient demonstrated signs of right-sided heart failure and appeared to be fluid overloaded (net of 13 liters since admission). Physical examination identified a 3/6 holosystolic murmur at the right upper sternal border, elevated jugular venous pressure to the angle of the jaw with a prominent V wave, a hepatic-jugular reflux, a right-ventricular heave, and severe lower extremity edema. She also had an elevated aspartate transaminase (AST) and alanine transaminase (ALT) measured at 206 units/l and 176 units/l, respectively, and likely to have been due to hepatic congestion from tricuspid regurgitation. The patient had a pro b-type natriuretic peptide (proBNP) of 2,056 pg/ml (normal,  $\leq 125$  pg/ml) and her urinary 5-hydroxyindole acetic acid (5-HIAA) was 15 mg/24 hr (normal,  $\leq 8.0$  mg/24hr).

Intravenous (IV) furosemide was administered at a rate of 10 mg/hour with a daily goal of net negative 1.5–2 liters/day fluid balance. Cardiothoracic surgery was consulted to discuss valve replacement surgery. The patient's Gupta myocardial infarction or cardiac arrest (MICA) calculator was around 3.5%, and the Revised Cardiac Risk Index (RCRI) score was  $>11\%$ , which estimated a high risk of perioperative myocardial infarction. Due to the high perioperative cardiac risk, the patient's severely decompensated heart failure, and progressive disease, the patient was not considered to be a suitable surgical candidate.

Since all four heart valves were affected by carcinoid disease, the surgery required to improve the patient's right-sided and left-sided heart failure would have involved replacing all four valves, which was not possible. Other interventional cardiac procedures, such as a percutaneous valve replacement, were not considered due to the patient's severely decompensated heart failure and because all four valves needed to be replaced. Therefore, the decision was made to treat her heart failure medically with furosemide 40 mg orally twice daily, spironolactone 12.5 mg orally daily, and metoprolol succinate 25 mg orally daily. She was scheduled for clinical follow-up in the heart failure clinic one week after hospital discharge. Regarding the treatment of her carcinoid syndrome, she received octreotide 20 mg intramuscularly and was scheduled to receive the same dose once per month.

The patient was discharged from the hospital and did well for one week at home. At the initial follow-up visit, she was found to be malnourished with superimposed infection. She was readmitted to the hospital. Unfortunately, the patient died from decompensated heart failure about a month after she was discharged from the initial hospital admission.

## Discussion

Cardiac involvement occurs in 50–60% of patients with carcinoid syndrome [4]. The plaques that develop on the heart valves are composed of myofibroblasts, smooth muscle cells, and extracellular matrix components, such as collagen. The results of these plaques are retraction and fixation of the valve leaflets, reduced motion, and valve regurgitation [1,5]. While the pathogenesis and development of carcinoid heart plaques are incompletely understood, there is evidence that suggests serotonin (5-HT) plays a key role, specifically through the activation of serotonin 2B receptors on the surface of the valves [6]. Serotonin is metabolized to 5-hydroxyindole acetic acid (5-HIAA) by monoamine oxidases in the liver and secreted into the urine [2]. Patients with carcinoid heart disease have significantly higher levels of urinary 5-HIAA compared to patients with carcinoid syndrome without cardiac involvement, which supports the role serotonin plays in the development of carcinoid heart disease [5].

When a carcinoid tumor is isolated in the gastrointestinal tract, carcinoid heart disease is not commonly seen, because the vasoactive substances released from the tumor drain through the portal venous system to the liver, where they are inactivated by monoamine oxidases. Carcinoid heart disease is typically seen in cases of carcinoid tumor that metastasizes to the liver. If hepatic metastases are present, the vasoactive substances can reach the heart because they drain directly from the liver into the systemic venous circulation and avoid inactivation [7]. This case is unique because, although the patient did not have hepatic metastases, she still developed carcinoid heart disease. The explanation for this presentation is most likely due to the metastasis of the carcinoid tumor from the gastrointestinal tract to the ovaries. The ovarian veins drain directly into the inferior vena cava, instead of the portal system. This anatomical design allows the vasoactive substances to bypass the liver completely and avoid hepatic inactivation [8].

Left-sided heart involvement occurs in less than 10% of patients with carcinoid heart disease. The preferential right-sided involvement is due to inactivation of vasoactive substances by

the lungs where serotonin is also degraded to 5-HIAA, which substantially reduces the amount of serotonin capable of inducing left heart fibrosis [9]. However, left-sided valve pathology can be seen in patients with an intracardiac shunt, such as a patent foramen ovale (PFO) or atrial septal defect (ASD), or with primary bronchial carcinoid [9]. This patient did not have an intracardiac shunt, nor did she have a primary bronchial carcinoid tumor. Her urinary 5-HIAA level was elevated at 15 mg/24 hr which suggests that the patient had high levels of circulating vasoactive substances, allowing damage to take place in the left side of the heart. The lack of hepatic inactivation of the vasoactive substances may have contributed to the overall increased disease activity seen in this patient.

While treatment of carcinoid syndrome with a medication such as octreotide can lead to symptomatic improvement of carcinoid syndrome, it does not lead to a regression of carcinoid heart disease and valve damage. The only effective treatment for carcinoid heart disease is valve-replacement surgery. In a retrospective clinical study conducted at the Mayo Clinic in which 200 cases of carcinoid heart disease were reviewed between 1981–2000, the effect of cardiac surgery on the long-term prognosis of carcinoid heart disease was evaluated [3]. Although a definitive cause for improved survival could not be determined from the study, the data suggested that there was improved prognosis over the past two decades, which may be related to valve replacement surgery [3]. Also, early cardiac evaluation and cardiac surgical intervention may decrease surgical mortality and improve prognosis in patients with carcinoid heart disease [6].

## Conclusions

This case report has shown how three factors presenting together, bilateral ovarian metastases, lack of hepatic metastases, and lack of an intracardiac shunt can lead to severe carcinoid heart disease involving all four heart valves. This case has shown the importance of early diagnosis and treatment of carcinoid heart disease to prevent irreversible valvular damage and heart failure.

## References:

1. Damen N: Ovarian carcinoid presenting with right heart failure. *BMJ Case Rep*, 2014; 2014: pii: bcr2014204518
2. Bhattacharyya S, Davar J, Dreyfus G, Caplin ME: Carcinoid heart disease. *Circulation*, 2007; 116: 2860–65
3. Moller JE, Pellikka PA, Bernheim AM et al: Prognosis of carcinoid heart disease. *Circulation*, 2005; 112: 3320–27
4. Connolly HM, Schaff HV, Mullany CJ et al: Surgical management of left-sided carcinoid heart disease. *Circulation*, 2001; 104(12 Suppl. 1): I36–40
5. Grozinsky-Glasberg S, Grossman AB, Gross DJ: Carcinoid heart disease: From pathophysiology to treatment – ‘something in the way it moves’. *Neuroendocrinology*, 2015; 101: 263–73
6. Connolly HM, Pellikka PA: Carcinoid and drug-related heart disease. In: Murphy JG, Lloyd MA (eds.), *Mayo Clinic Cardiology: Concise Textbook*. 4<sup>th</sup> ed. New York: Oxford University Press, 2012; 409–15
7. Wilkowske MA, Hartmann LC, Mullany CJ et al: Progressive carcinoid heart disease after resection of primary ovarian carcinoid. *Cancer*, 1994; 73: 1889–91
8. Reed NS, Gomez-Garcia E, Gallardo-Rincon D et al: Gynecologic Cancer InterGroup (GCIg) consensus review for carcinoid tumors of the ovary. *Int J Gynecol Cancer*, 2014; 24: S35–41
9. Marupakula V, Vinales KL, Najib MQ et al: Occurrence of left-sided heart valve involvement before right-sided heart valve involvement in carcinoid heart disease. *Eur J Echocardiogr*, 2011; 12(3): E18