

Trauma and reconstruction

## Distal corporoplasty using an autologous tunica in the management of penile prosthesis pseudo aneurysm



Michel Apoj<sup>a</sup>, Elizabeth A. Phillips<sup>b</sup>, Shu Pan<sup>a</sup>, Ricardo Munarriz<sup>a,\*</sup>,<sup>1</sup>

<sup>a</sup> Boston University School of Medicine, United States

<sup>b</sup> CentraCare Health, United States

### Introduction

Inflatable penile prosthesis placement is an effective and safe treatment option for erectile dysfunction.<sup>1</sup> The 5-year revision rate is low (7%) and revisions are most likely due to infection or mechanical problems with the device.<sup>2</sup>

Penile prosthesis aneurysm is a rare complication that is managed surgically. The choice of graft used during tunical reinforcement is critical to avoid subsequent complications.<sup>3</sup> The use of autologous grafts from distant tissue often leads to deformations of penile tissue in addition to the increase in operative time, morbidity, and cost of the operation.<sup>4</sup> The use of synthetics increases the susceptibility to infection and decreases long-term pliability of the penile tissue.<sup>4</sup> More recently, a publication in plastics reconstructive literature suggests the use of an acellular porcine graft.<sup>5</sup> We believe using the patient's own tunica as an autologous graft should be more closely investigated.

### Case presentation

A 48-year-old man with a three-piece inflatable penile prosthesis presented complaining of device malfunction. Physical exam revealed a large right distal aneurysm of the device (Fig. 1).

The patient underwent elective removal and replacement of the inflatable penile prosthesis with a distal corporoplasty. A sub-coronal incision was made and the penis was de-gloved. A very large right corporal herniation with a tunical aneurysm was then identified. To minimize graft complications, morbidity, and cost, the corpus was repaired using the patient's existing tissue. A tunical incision was made parallel to the urethra exposing the cylinder herniation (Fig. 2). The tunica was noted to be extremely thin and weak. The lateral aspect of the tunica was folded back and sutured in an interrupted fashion to itself medially with 4–0 PDS sutures. (Fig. 3). The edge was then sutured to the medial aspect of the tunica restoring the normal cylindrical anatomic tunica. Ultimately, the penile prosthesis was replaced with a 3-piece inflatable penile prosthesis and the incision re-approximated with 3–0 Monocryl suture. The patient did well with no complications

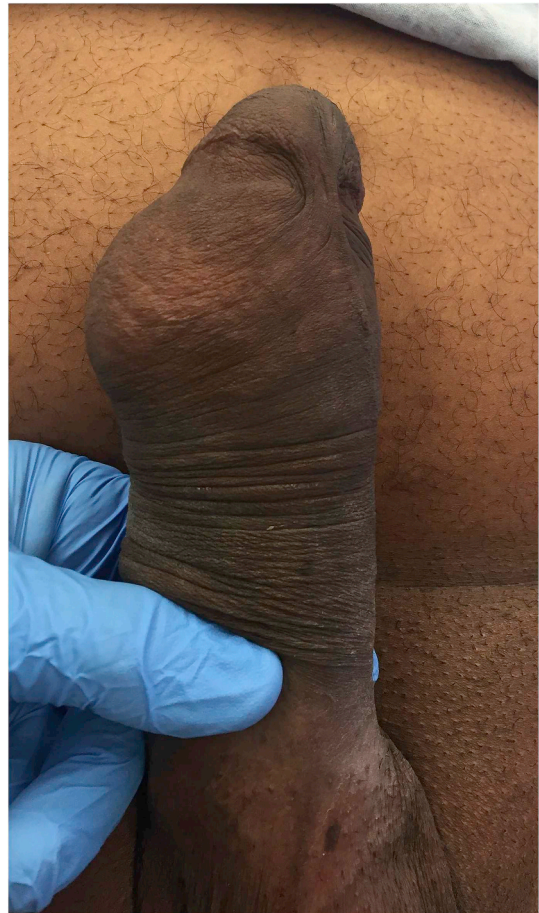

Fig. 1. Herniation/aneurysm of the right distal penile prosthesis cylinder.

\* Corresponding author. Boston University School of Medicine, Department of Urology, 725 Albany Street 3b, Boston, MA, 02118, United States.

E-mail address: [munarriz@bu.edu](mailto:munarriz@bu.edu) (R. Munarriz).

<sup>1</sup> Senior author.

<https://doi.org/10.1016/j.eucr.2018.10.015>

Received 3 October 2018; Accepted 23 October 2018

Available online 25 October 2018

2214-4420/ © 2018 The Authors. Published by Elsevier Inc. This is an open access article under the CC BY-NC-ND license (<http://creativecommons.org/licenses/by-nc-nd/4.0/>).

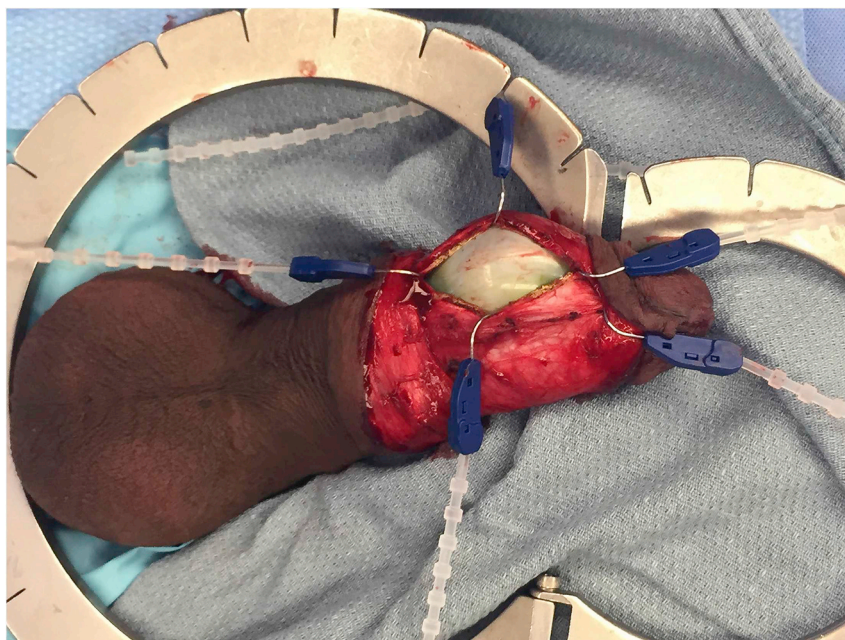


Fig. 2. Incision into the right corpus, exposing a significant herniation/aneurysm of the right cylinder.

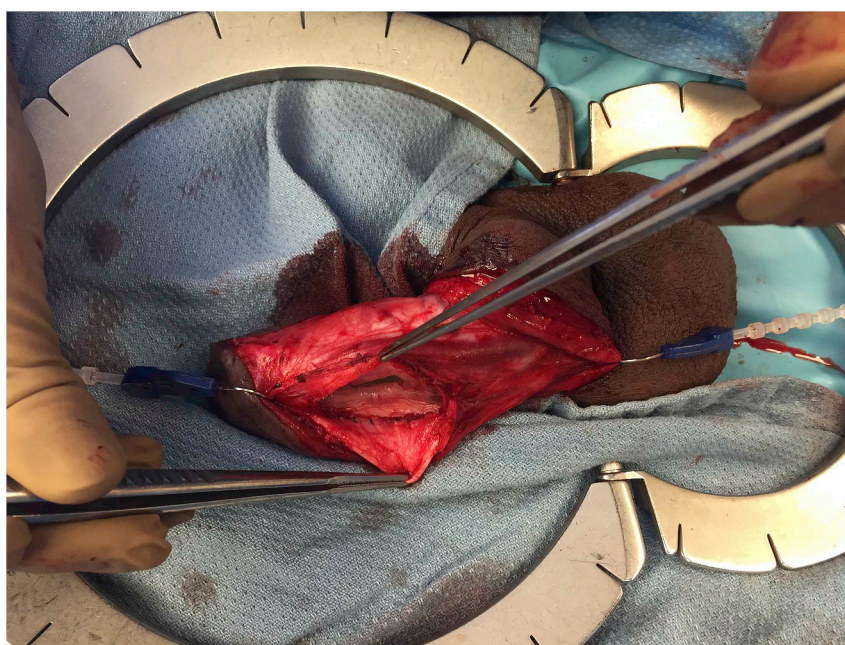

Fig. 3. Lateral aspect of tunica folded back and sutured on itself with interrupted 4-0 PDS sutures.

at his one week, 3- and 6-month postoperative visits. During his most recent visit, 2 years after his surgery, the patient elicited no urinary complaints, and no issues with his device. He reported his sexual function has returned to baseline, and is extremely satisfied with his operative outcome.

### Discussion

A critical decision during the surgical management of a prosthesis aneurysm is the surgeon's choice of what graft to use for the tunica repair. Post-operative outcomes of autologous grafts to the penile tissue have been studied retrospectively and prospectively for the surgical management of Peyronie's disease.<sup>4</sup> In addition to the increase in morbidity, operative time, and cost associated with the harvesting of

the tissue, these grafts often develop contractures and high rates of necrosis.<sup>4</sup> Various materials of different synthetic properties have been developed and used as non-autologous grafts for penile surgery.<sup>3</sup> The literature investigating post-operative outcomes after prosthesis herniation repair with the use of synthetics is ridden with high rates of infection, immunogenic response, and deformation of the penis due to their inherent decreased pliability.<sup>4</sup> One recent study found in the literature composed of 17 patients and a mean follow-up of 21-months suggests that acellular porcine xenografts from jejunal tissue may have none of these complications.<sup>3</sup> However, in the plastic surgery literature these grafts at long-term follow-up are associated with increased complications such as seromas, hematomas, and skin necrosis, often requiring additional procedures and medical treatment.<sup>5</sup> We suspect similar rates of complications with their use in urological surgeries.

## Conclusion

This case report of distal penile prosthesis aneurysm repair using an autologous graft with the redundant tunical tissue may be a better and safe way to approach this complication. Future research is needed to validate our results.

## References

1. Palma-Zamora I, Sood A, Dabaja AA. 30-day adverse event rates following penile prosthesis surgery: an American College of Surgeons National Surgical Quality Improvement Program based evaluation. *Transl Androl Urol*. 2017;6:S767–S773.
2. Grewal S, Vetter J, Brandes SB. A population-based analysis of contemporary rates of reoperation for penile prosthesis procedures. *Urology*. 2014;84:112–116.
3. Knoll, L. Dean. Use of porcine small intestinal submucosal graft in the surgical management of tunical deficiencies with penile prosthetic surgery. *Urology*. 59, (5), 758-761.
4. Hatzichristodoulou G. Grafting techniques for Peyronie's disease. *Transl Androl Urol*. 2016;5(3):334–341. <https://doi.org/10.21037/tau.2016.03.16>.
5. Paprottka FJ, Krezdorn N, Sorg H, et al. Evaluation of complication rates after breast surgery using acellular dermal matrix: median follow-up of three years. *Plastic Surgery Int*. 2017;2017:1283735. <https://doi.org/10.1155/2017/1283735>.

1. Palma-Zamora I, Sood A, Dabaja AA. 30-day adverse event rates following penile