Case Reports in Dermatology

Case Rep Dermatol 2023;15:26–30
DOI: 10.1159/000528422
Received: June 15, 2022
Accepted: November 9, 2022
Published online: January 27, 2023

Case Report

A Rare Case of Prurigo Pigmentosa in a Danish Sibling Couple

Maria Danielsen[a] Kristine Pallesen[a] Rikke Riber-Hansen[b] Anne Bregnhøj[a]

[a]Department of Dermatology, Aarhus University Hospital, Aarhus, Denmark; [b]Department of Pathology, Aarhus University Hospital, Aarhus, Denmark

Keywords
Case report · Prurigo pigmentosa · Ketogenic diet · Siblings · Pruritus

Abstract
Prurigo pigmentosa (PP) is probably underdiagnosed due to lack of awareness. Previously, it was assumed that PP primarily affected Japanese females; however, more cases are reported worldwide, and the pathogenesis is still not completely understood. In this case report, we present two healthy Danish siblings, who developed PP approximately 2 weeks after starting a ketogenic diet, suggesting that both increased levels of ketone bodies in the blood together with a genetic predisposition might play a role in the development of PP.

Introduction

Prurigo pigmentosa (PP) is an uncommon temporary inflammatory skin condition associated with ketosis which can be challenging to diagnose. The exact role of exclusion of carbohydrates and ketosis in the development of PP has not yet been clarified. The rash is described, almost pathognomonic, as an erythematous maculopapular rash with a brownish discoloration distributed in a reticular pattern. Histopathologic findings together with thorough review of diet prior to symptom debut can aid in the diagnostic workup of PP. Previously, most cases have been described in Japanese female patients suggesting an ethnic predisposition or environmental cause [1]. However, in this case report, we present the first case to our knowledge of PP occurring in two Danish siblings after a ketogenic (low carb-high fat) diet. Most patients with PP do not have ketosis or diabetes, and our cases raise the question whether certain tissue types (e.g., HLA types) nevertheless possess a different threshold to ketone bodies in the blood and thereby a higher likelihood of developing PP.

Correspondence to:
Maria Danielsen, maria.danielsen@clin.au.dk

Case Presentation

Two healthy siblings, a female aged 16 and a male aged 18, were referred to the dermatological department due to a sudden onset of pruritic rash approximately 1–2 weeks apart. The male patient experienced a rash arising overnight starting on the chest and abdomen and the following days also on the lower back. Interestingly, his younger sister presented with a similar pruritic rash initially located on the back but slowly spreading toward the axilla and the abdomen. The family doctor prescribed an oral antihistamine with limited effect on the pruritus and a group 2 topical corticosteroid with no effect at all. Physical examination by a certified dermatologist revealed a symmetrical erythematous infiltrated maculopapular rash distributed in a reticular pattern on the truncus of both patients. On the male, the rash was respecting the midline and progressing up to the scapula and pectoral muscles (shown in Fig. 1). Some areas had fine scaling and on the back some elements had started to pale off and become hyperpigmented. On the female, the rash was strikingly like that of her brother (shown in Fig. 2). There was no exuding or foul smell. At initial presentation, the working diagnosis was Gourgerot-Carteaud syndrome or Morbus Darier. However, shortly after that we learned that the two siblings had started a ketogenic diet about 14 days prior to debut of symptoms. The skin biopsies were reviewed by a dermatopathologist in regard to the possible diagnosis of PP and the histopathology substantiated this diagnosis.

Both patients were treated with oral tetracycline 500 mg twice daily for 4 weeks together with betnovate with chinoform, a strong-acting cortisone preparation (group 3) with an antibacterial/antifungal compound. At a follow-up visit, approximately 4 weeks later the pruritus and erythema was in complete resolution on both patients, leaving only the characteristic post-inflammatory hyperpigmented patches on the truncus. Also, the patients were recommended to cease the ketogenic diet.

Histopathology

The histological findings of PP are dynamic. Early elements show a superficial perivascular neutrophilic infiltrate, sometimes with a dermatitis herpetiformis-like pattern. Later, neutrophils may extend into the epidermis accompanied by spongiosis, ballooning, scattered necrotic keratinocytes, and formation of neutrophilic microabscesses. A focal lichenoid pattern, folliculitis, and dermal eosinophils and lymphocytes may be seen. Late stages are characterized by acanthosis and hyperkeratosis along with pigment incontinence and melanophages. The biopsy from the 18-year old showed an incrusted spongiosis with focal lichenoid changes with dermally located predominantly eosinophilic but also a few neutrophilic granulocytes (shown in Fig. 3a). The biopsy from the 16-year old showed minimal changes with mild hyperkeratosis, and mild epidermal hyperplasia with few necrotic keratinocytes, and a sparse dermal infiltrate of lymphocytes and a few melanophages (shown in Fig. 3b).

Discussion

PP has gradually been reported from many different places around the world suggesting different pathogenesis than originally proposed by the Japanese dermatologist Masaharu Nagashima [1], who first described the condition in Japan in 1971. PP has been associated with *Helicobacter pylori* infection [2], nutrition [3] and especially ketogenic diets [4–7], weight loss, and anorexia nervosa [8]. In a review by Böer et al. [9], they conclude that PP is highly distinctive clinically, histopathologically, and biologically, and the group raises question marks to all factors mentioned as being causative of PP due to short follow-up, incomplete and imprecise histopathology descriptions of biopsies performed in both early and late stages of disease.

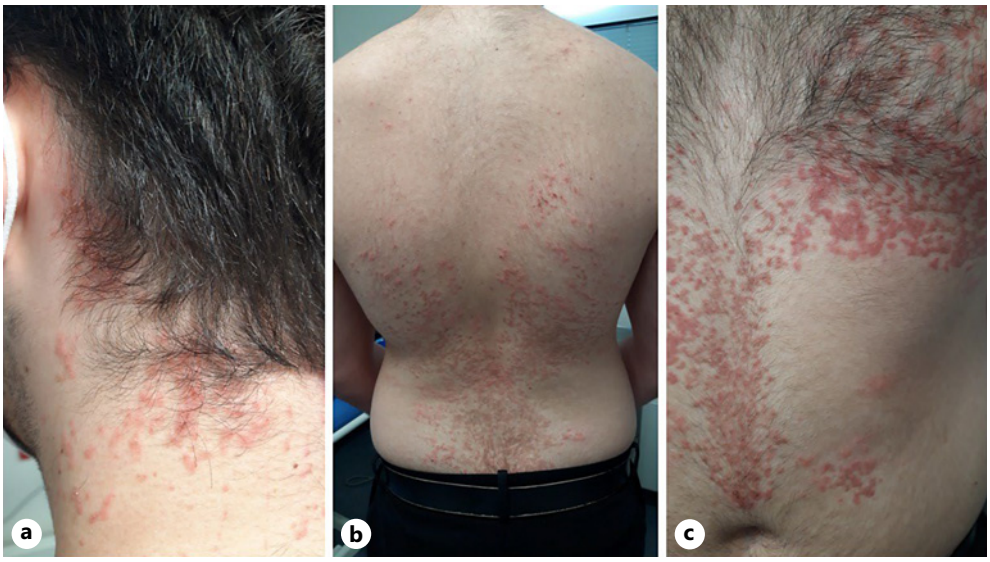

Fig. 1. a–c Distribution of rash on male patient.

Studies have shown that the histological features of PP are largely nonspecific and vary according to the stage of the disease [10] making it difficult to diagnose. Furthermore, in many instances a patient had the disease for months before correct diagnosis was made clinically.

Abbass et al. [11] hypothesized that ketone bodies may distribute around blood vessels leading to perivascular inflammation or enter into cells modifying their intracytoplasmic processes. This inflammation is believed to be mainly by neutrophils, which corresponds well with PP usually responding to medications with antineutrophil effect such as dapson or tetracyclines. However, not all patients with PP have ketone bodies in their urine or blood, and not all patients who have dysregulated diabetes or urinary or blood ketone bodies have PP. Both patients developed the same skin condition approximately 2 weeks after a strict ketogenic diet, which suggests that change of nutrition plays a role, but potentially also a certain genetic predisposition. Houriet et al. [12] made similar observations, when the group encountered PP in Caucasian monozygotic twins. This case differs from ours, being two female monozygotic twins, which developed PP 6 years apart, lasting for 10 and 4 years, respectively, at time of diagnosis. These findings also suggest the role of a certain genetic phenotype; however, there was no evidence of a putative trigger in the twins. Furthermore, in 2 other cases of PP the distribution is described as segmental in a 13-year-old girl [13] and unilateral in 2 different male patients [7] suggesting a possible genetic mosaicism. Finally, and most importantly, in a recent systematic review of the literature performed by Mufti et al. [14] it was proposed that PP is underdiagnosed in countries outside East Asia, hence the higher number of cases in Japan, due to lack of awareness. It is important to recognize this diagnosis because resuming of a balanced diet can be effective. With this case report of two Danish siblings, we hope to assist in raising awareness of PP in order to avoid unnecessary diagnostic workup of these patients in the future. The CARE Checklist has been completed by the authors for this case report, attached as a supplementary material at www.karger.com/doi/10.1159/000528422.

Statement of Ethics

Written informed consent was obtained from the male patient for publication of the details of his medical case and any accompanying images. Written informed consent was

Case Rep Dermatol 2023;15:26–30
DOI: 10.1159/000528422

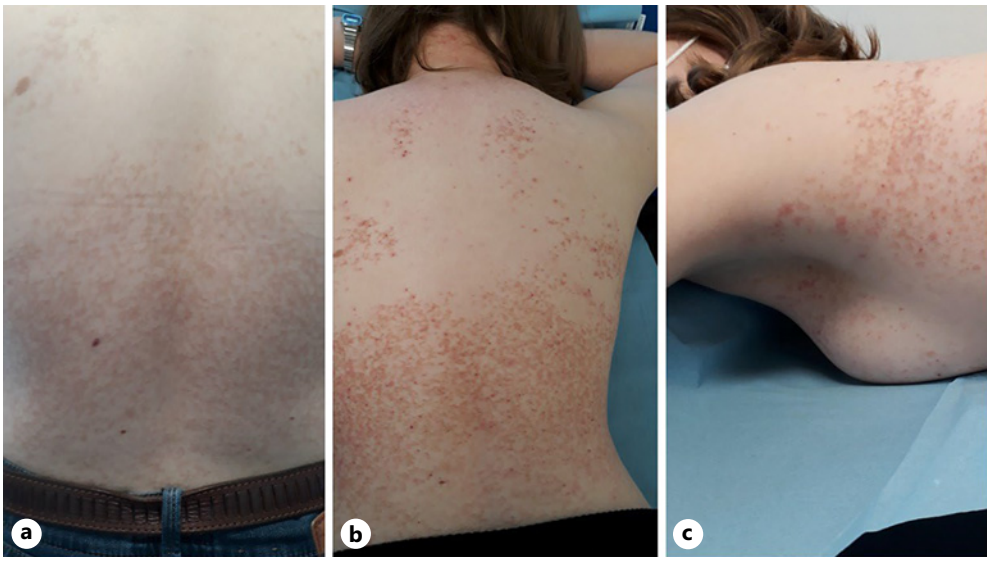

Fig. 2. a–c Distribution of rash on female patient.

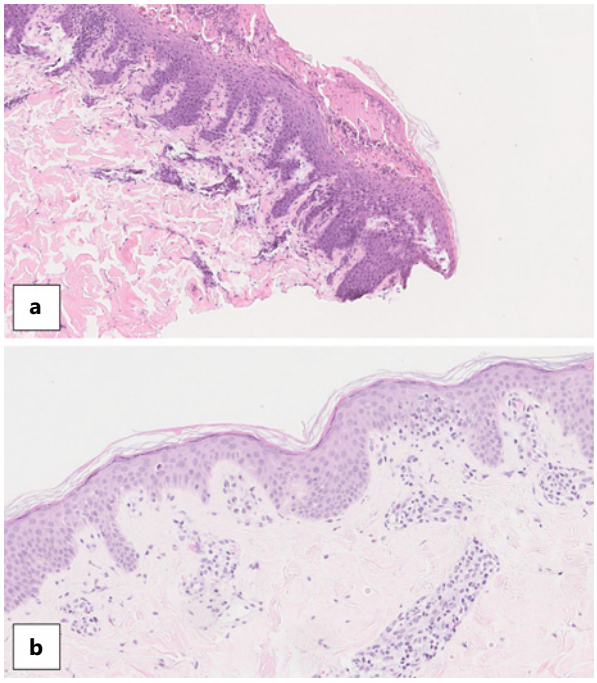

Fig. 3. a Microscopic photo of the skin of the 18-year old. Suboptimal processed biopsy with incrustation, spongiosis, and scattered necrotic keratinocytes (×100). **b** Microscopic photo of the skin of the 16-year old. Mild inflammatory changes with a few necrotic keratinocytes and a sparse lymphocytic dermal infiltrate (×150).

obtained from the parent of the female patient for publication of the details of her medical case and any accompanying images. The paper is exempt from Ethical Committee approval in accordance with local or national guidelines.

Conflict of Interest Statement

The authors have no conflicts of interest to declare.

Funding Sources

There were no founding sources.

Author Contributions

Maria Danielsen: writing – original draft and conceptualization; Anne Bregnhøj: investigation, conceptualization, and writing – review and editing; and Kristine Pallesen and Rikke Riber-Hansen: investigation and review and editing. All authors read and approved the final manuscript.

Data Availability Statement

All data generated or analyzed during this study are included in this article. Further inquiries can be directed to the corresponding author.

References

1 Nagashima M. Prurigo pigmentosa--clinical observations of our 14 cases. J Dermatol. 1978;5(2):61–7.
2 Erbagci Z. Prurigo pigmentosa in association with Helicobacter pylori infection in a Caucasian Turkish woman. Acta Derm Venereol. 2002;82(4):302–3.
3 Teraki Y, Teraki E, Kawashima M, Nagashima M, Shiohara T. Ketosis is involved in the origin of prurigo pigmentosa. J Am Acad Dermatol. 1996;34(3):509–11.
4 Michaels JD, Hoss E, DiCaudo DJ, Price H. Prurigo pigmentosa after a strict ketogenic diet. Pediatr Dermatol. 2015;32(2):248–51.
5 Shahrigharahkoshan S, AlHalees Z, Pehr K. Ketogenic diet-induced prurigo pigmentosa: a rising association. Int J Dermatol. 2022;61(7):779–82.
6 Sun HY, Sebaratnam DF. Prurigo pigmentosa following a ketogenic diet: a case report. Eur J Clin Nutr. 2022;76(4):624–5.
7 Teraki Y, Hitomi K. Unilateral prurigo pigmentosa: a report of two cases. J Dermatol. 2016;43(7):846–7.
8 Nakada T, Sueki H, Iijima M. Prurigo pigmentosa (Nagashima) associated with anorexia nervosa. Clin Exp Dermatol. 1998;23(1):25–7.
9 Böer A, Misago N, Wolter M, Kiryu H, Wang XD, Ackerman AB. Prurigo pigmentosa: a distinctive inflammatory disease of the skin. Am J Dermatopathol. 2003;25(2):117–29.
10 Beutler BD, Cohen PR, Lee RA. Prurigo pigmentosa: literature review. Am J Clin Dermatol. 2015;16(6):533–43.
11 Abbass M, Abiad F, Abbas O. Prurigo pigmentosa after bariatric surgery. JAMA Dermatol. 2015;151(7):796–7.
12 Houriet C, Perruchoud DL, Beltraminelli H, Borradori L. Prurigo pigmentosa in white monozygotic twins. JAMA Dermatol. 2017;153(3):353–4.
13 Torrelo A, Azorín D, Noguera L, Hernández-Martín A, Happle R, Requena L. Segmental prurigo pigmentosa. Pediatr Dermatol. 2014;31(4):523–5.
14 Mufti A, Mirali S, Abduelmula A, McDonald KA, Alabdulrazzaq S, Sachdeva M, et al. Clinical manifestations and treatment outcomes in prurigo pigmentosa (Nagashima disease): a systematic review of the literature. JAAD Int. 2021;3:79–87.