

Is Paget Disease of Bone more Common in South India? Clinical Characteristics, Therapeutic Outcome and follow-up of 66 Patients from Tamil Nadu

Adlyne R. Asirvatham, Subramanian Kannan¹, Shriram Mahadevan, Karthik Balachandran, Geethalakshmi Sampathkumar², Dhalapathy Sadacharan³, Satish K. Balasubramanian

Department of Endocrinology, Sri Ramachandra Medical College and Research Institute, Porur, Chennai, Tamil Nadu, ¹Department of Endocrinology, Mazumdar Shah Medical Centre, Bommasandra, Bengaluru, Karnataka, ²Department of Endocrinology, Kamakshi Memorial Hospital, ³Department of Endocrine Surgery, Madras Medical College, Chennai, Tamil Nadu, India

Abstract

Introduction: Paget disease of bone (PDB) is a disorder of altered bone remodeling mainly characterized by increased osteoclastic activity. While the exact Indian prevalence remains unknown, a clustering of published cases suggests South Indian predominance. **Objective:** To study the clinico-biochemical profile and therapeutic response of patients with PDB and briefly review the epidemiology of PDB from an Indian perspective. **Materials and Methods:** Retrospective data was collected from the charts of patients who have been seen in endocrine out-patient clinics in Tamil Nadu over a 12-year period. Published literature on PDB from India was reviewed. **Results:** A total of 66 patients (71% males) predominantly from Tamil Nadu were studied. The mean age at presentation was 67 ± 8 years. Polyostotic involvement was seen in 89% and familial occurrence of PDB in 5 patients. Symptoms at presentation mainly included bone pain (51%) and skeletal deformities (18%). Scalp vein sign (21%) and sensorineural hearing loss (64%) were also noted. Incidental PDB detection by raised serum alkaline phosphatase (SAP) levels was observed in 17% and by abnormal fluorodeoxyglucose-positron emission tomography (FDG-PET) scan in 6% of cases. Mean SAP at presentation was 606 ± 438 IU/L (Normal, 76–140). Major skeletal site involvement includes pelvis (62.1%) and spine (34.8%). Mean (range) follow-up of the cohort was 3.4 yrs (1–12 yrs). In all, 64 subjects received zoledronate and two received alendronate, and mean (SD) SAP at 1-year was 73 ± 42 IU/L. All but two showed remission at the end of 1 year. Two had pathological fractures and two had sarcomas. A review of epidemiology of PDB in Indian literature clearly showed a South Indian predilection for unclear reasons. **Conclusion:** In our cohort of PDB, male gender, polyostotic involvement, and hearing impairment were noted in more than two-thirds of patients and single-dose intravenous zoledronate was effective in normalizing SAP in almost all patients. PDB is intriguingly more common in South India and this needs more exploration.

Keywords: Alkaline phosphatase, paget disease of bone, South India, zoledronate

INTRODUCTION

Paget disease of bone (PDB) is a disorder of exaggerated bone remodeling. It starts as intense bone resorption by abnormal multi-nucleated osteoclasts, followed by chaotic bone formation by osteoblasts. Thus, it progresses through a lytic phase, mixed-phase of bone formation and resorption, and sclerotic phase followed by a quiescent phase. The pagetoid process may involve one (monostotic) or more (polyostotic) bones producing complications including deformities (osteitis deformans), pain, compressive neuropathies (especially in cranial involvement), increased propensity for fracture, and rarely malignant transformation.^[1] Accordingly, the clinical

presentation may vary from asymptomatic patients incidentally picked up by radiological abnormalities or elevated serum alkaline phosphatase to severe pain or deformities of

Address for correspondence: Dr. Shriram Mahadevan, Department of Endocrinology, Sri Ramachandra Medical College and Research Institute, Porur, Chennai - 600 116, Tamil Nadu, India. E-mail: mshriram@gmail.com

Submitted: 18-Apr-2020

Revised: 16-May-2020

Accepted: 19-Jun-2020

Published: 27-Aug-2020

This is an open access journal, and articles are distributed under the terms of the Creative Commons Attribution-NonCommercial-ShareAlike 4.0 License, which allows others to remix, tweak, and build upon the work non-commercially, as long as appropriate credit is given and the new creations are licensed under the identical terms.

For reprints contact: reprints@medknow.com

How to cite this article: Asirvatham AR, Kannan S, Mahadevan S, Balachandran K, Sampathkumar G, Sadacharan D, *et al.* Is Paget disease of bone more common in South India? Clinical characteristics, therapeutic outcome, and follow-up of 66 patients from Tamil Nadu. *Indian J Endocr Metab* 2020;24:306-11.

Access this article online

Quick Response Code:



Website:
www.ijem.in

DOI:
10.4103/ijem.IJEM_209_20

bones accompanied by hearing loss. Diagnosis is usually made by characteristic clinical, biochemical features with corroborative evidence in bone scan showing increased uptake of tracer [methylene diphosphonate (MDP)] in affected bones. The mainstay of treatment is bisphosphonates^[2] and intravenous zoledronate is preferred as it usually results in long-term remission of PDB.^[3] In settings where bisphosphonates are contraindicated as in chronic kidney disease, recently, usage of denosumab has been reported.^[4]

PDB was considered rare in Asians, especially Indians.^[5,6] Most of the case series and other studies were mainly from Caucasians in UK or the migrant English population in Australia. However, in little over a decade, there were several case studies and two case series from India. Interestingly, most of the cases reported are exclusively from South India. Hence, in this retrospective study, we intend to present the clinical and therapeutic aspects of 66 patients with PDB from Tamil Nadu (TN) and provide a focused review of the epidemiology of this disorder from an Indian perspective.

MATERIALS AND METHODS

This was a retrospective study in which subjects with newly diagnosed PDB who had attended the endocrine clinics in private outpatient set up of the authors between 2008 and 2020 were included. Out of 79 patients with PDB, 66 patients with complete biochemical data and follow-up of at least 1 year were analyzed. Diagnosis of PDB was made based on the characteristic bony deformities, elevated alkaline phosphatase, and increased uptake in technetium MDP bone scintigraphy in all cases. Data on demographic details, clinical features, and biochemical parameters were obtained. Biochemical data included serum levels of alkaline phosphatase (SAP) (IU/L), corrected calcium (mg/dL), phosphorus (mg/dL), 25-hydroxy vitamin D (ng/mL), parathyroid hormone (pg/mL), and creatinine (mg/dL). Therapeutic details including oral or intravenous bisphosphonates (zoledronate 5 mg), calcium, and vitamin D supplementation were noted. Clinical and biochemical follow-up with at least 3 SAP values over a 1-year period after bisphosphonate administration was available in all patients. Bone scan was not repeated in most of the patients unless a relapse was suspected based on rising SAP levels. PDB was considered to be in remission if there was improvement in clinical features and normalization of SAP levels. Continuous variables were represented as numbers and percentages and mean and standard deviation were used. Median and 5th–95th percentile was calculated as needed.

RESULTS

Demographic characteristics

Out of 66 patients with PDB, 47 were males (71%) with a male to female ratio of 2.5:1. The mean age at presentation was 67 ± 8 years (Range, 49–81 years). Positive family history of PDB was noted in five patients (7.6%). Geographically, all

patients were from South India except one from Orissa. Of the 65 cases, 55 were from in and around Chennai, 2 each from different parts of TN viz. Madurai, Cuddalore, Namakkal, Puducherry and 1 from Chidambaram (TN) and 1 from Tirupathi (Andhra Pradesh).

Clinical and biochemical characteristics

The clinical features at diagnosis are shown in Table 1. Incidental pick up of PDB in our series was 17% biochemical (elevated SAP) and 6% radiological (PET scan abnormal uptake). In the latter patients, once suspected complete evaluation with other biochemistries and technetium MDP bone scintigraphy was also done. Mean serum corrected calcium was 9.2 ± 0.48 mg/dL, serum phosphorus 3.8 ± 0.44 mg/dL, 25-hydroxy vitamin D 26.86 ± 10.41 ng/mL, PTH 68.5 ± 32.4 pg/mL, and SAP 606.43 ± 438.44 IU/L. Mean SAP levels at 1-year follow-up was 73 ± 42 IU/L, and at 2 years was 92 ± 49.8 IU/L. The clinical and biochemical characteristics among the various Indian zones are compared in Table 2.

Skeletal involvement

Polyostotic involvement was seen in 89.4% (*n* = 59) patients when compared to monostotic presentation in only 10.6% (*n* = 7). Major skeletal site involvement was pelvis (62.1%) and spine (34.8%). Out of 7 with monostotic involvement, five were males. The commonest site of involvement in these patients was vertebra (proven by biopsy in 6 patients) and 1 patient had unilateral tibia affliction picked-up by bone scan.

Co morbidities

Nineteen (28.8%) of the 66 patients had type 2 diabetes mellitus and 15.2% (*n* = 10) had systemic hypertension. Breast malignancy was noted in three patients who were initially worked-up for possible bone metastasis and later diagnosed with PDB. One patient had papillary thyroid cancer, which was later operated. None of our patients had primary hyperparathyroidism, which is considered to be an association with PDB.

Complications

Two patients in our series had bone malignancies associated with polyostotic PDB. Osteosarcoma of the right maxilla with extensive spread was seen in a 66-year-old lady and she did not undergo further treatment. The other patient was a

Table 1: Clinical characteristics of Paget Disease of Bone at presentation (*n*=66)

Clinical features - Symptoms	% (<i>n</i>)	Clinical features - Signs	% (<i>n</i>)
Bone pain	51.55%	Sensorineural deafness	63.6%
Low back ache	25%	Scalp vein sign	21.2%
Asymptomatic	16.7%	Skeletal deformities	18.2%
Headache	4.5%	Genu Varum	10.6%
Pathological fractures	3%	Leonine facies	3.03%
		Tibial bowing	1.5%

Table 2: Comparison of clinical and biochemical characteristics of Paget Disease of Bone (PDB) among the published Indian case series

Clinical and biochemical parameters	Published studies from Indian Zones			
	North ^[6] (2006)	West ^[7] (2006)	South ^[9] (2018)	Our study (2020)
Number of patients	21	17	48	66
Mean age±SD (years)	49.2±17.6	62±18.2	60±11.3	67±8
Familial cases	-	-	2	5
Presenting features	Low backache	Bone pain	Bone pain Low backache	Bone pain Hearing loss
Monostotic involvement	28.6%	5.9%	13%	10.6%
Commonly involved bones (in order of involvement)	Skull and Spine (61.9%) Pelvis (38.1%)	Pelvis (70%) Skull (59%) Spine (59%)	Pelvis (73.3%) Spine (62.2%)	Pelvis (62.1%) Spine (34.8%)
Mean Alkaline Phosphatase	1514 IU/L	980 IU/L	511 IU/L	606.43 IU/L
Complications	9.6% had fracture	Hyperuricemia Neurogenic radiculopathy	Hyperuricemia (17.6%) Deafness (11.8%)	3% had fracture 1.5% had Osteosarcoma 1.5% had Chondrosarcoma

68-year-old gentleman treated for PDB and was in remission, later developed chondrosarcoma in the pagetoid scapula and expired. Two other patients had pathological fractures in the affected bone at the time of the presentation.

Therapeutic details

In our series, 64 subjects received intravenous zoledronate and only 2 had received oral alendronate. Subjects who had vitamin D deficiency had received therapeutic doses of cholecalciferol prior to treatment with bisphosphonates. All but two treated patients showed good clinical improvement and normalization of alkaline phosphatase in less than a year. Those two patients required a second dose of zoledronate. The overall remission rate was 92.4% with intravenous zoledronate. Forty-two patients were followed-up for 1 year, and 31 were on regular visits until 2 years.

DISCUSSION

This is a retrospective study to describe the clinical, biochemical, and therapeutic profile of PDB that is otherwise considered rare in India. This is another large case series from South India. The mean age of presentation at the 6th decade and male preponderance in our study was akin to other case series published from India.^[6-9] The majority of our patients had polyostotic involvement especially of the pelvis, spine, and skull similar to earlier studies. The number of familial cases (5 patients) was higher than the series from Vellore, probably signifying the genetic basis of the disorder. Our series had two patients with bone malignancy; one with the less commonly reported chondrosarcoma, and the other had osteosarcoma that is usually associated with PDB.^[10] Scalp vein sign, the prominent superficial temporal vein seen often due to increased vascularity and arteriovenous shunting was seen in a fifth of our patients on careful observation. This along with decreased hearing may be a useful clinical clue, especially in those patients with significant skull

involvement.^[11] In our cohort of 66 patients, 28.8% had type 2 diabetes. The probable prevalence of PDB as diagnosed by raised alkaline phosphatase in a large cohort of type 2 diabetes patients was very low (0.066%).^[12]

Contrary to the previous belief that PDB is rare in India, this large case series reiterates the point that it is not uncommon. Even more curiously, from published literature, PDB is strikingly more prevalent in South India than in other parts of the country. Why the divide in cases within the same country? Attempting to answer this question, we reviewed the available literature from an Indian epidemiological viewpoint.

Asians and Indians were presumed to be protected from PDB till two decades ago. Several reasons were quoted for the reduced prevalence among Asians especially South Asians. Whether it was because of unawareness among physicians resulting in underestimation or reduced longevity or lack of testing facilities is still unclear. Only a few cases reports from India came forth since the late 1990s, and case series were published only a decade later. But significant case reports from China^[13] and Singapore^[14] were available by then. Even though Indian studies were unavailable, Asians with Paget's disease were studied in the United Kingdom and New Zealand, with significant information. In a report of eight cases from East London, 3 Indians were affected who lived in the UK for more than 30 years.^[15] Simultaneously, a study from New Zealand reported 14 Asians including 4 Indians with PDB between 1993 and 2010 who had lived in New Zealand for at least 8 years.^[16] The authors attribute this increase in Asian cases to the parallel increase in the Asian population in these countries as well as concurrent decline in the European (Caucasian origin) population. Surprisingly, none of the 8 patients tested carried a mutation in exon 8 of the sequestosome 1 (SQSTM1) gene, questioning the genetic predisposition of Asians. It would be premature to assume the lack of innate susceptibility without genetic analysis of a larger Indian population.

In a little over a decade, we have understood the increasing prevalence of this disorder in our country. This increase may be attributable to better longevity, more frequent testing, inter Asian-Caucasian marriages, early diagnosis, and of course possible environmental changes. Aren't these reasons common to all zones of India? Why is that South India reports a larger number of cases? When we analyzed the published Indian data, the north Indian series had pooled data of 21 patients from various zones including Varanasi, Cochin, New Delhi, and Bangalore, in which just four were from Chandigarh.^[6] This is surprising as this zone is known for its extraordinary work on other common bone disorders like primary hyperparathyroidism and fibrous dysplasia. On the other hand, the western Indian series had only 17 patients over a period of 7 years from Mumbai (8), Navi Mumbai (2), Nashik (1), Malegaon (1), Surat (1), Vapi (1), Raigad (1), and Thane (2).^[7] Whereas, in the South Indian series published from Vellore in 2006 with 51 patients over 8 years, 73% were from Tamil Nadu, and 8% each from West Bengal and Madhya Pradesh strongly pointing towards South Indian predilection.^[8] A recent study from the same center with 48 patients between 2007 and 2016 had approximately 90% of patients from Tamil Nadu (personal communication).^[9] In our series, 54 out of 66 patients (81.8%) were from places in and around Chennai. This pattern of clustering of cases around Chennai due to referral bias seems unlikely as these cases were consulted in private endocrine outpatient clinics and not in a referral tertiary care center. As far as we know, there is no large case series published from tertiary care institutes in eastern India despite encountering high endocrine caseload. The cases reported from India till now are depicted in Figure 1. The strengths of this study include a larger study cohort, longer follow-up, and availability of demographic details. However, it lacks the genetic testing of the study population. The precise explanation for Tamil Nadu, especially the northern regions to be a hub for PDB remains unknown. However, we believe that this insight would initiate further studies looking at genetic versus environmental factors in the development of this relatively uncommon disorder and a toponymous connotation of predominant South Indian disorder may also be considered.

CONCLUSION

In our cohort of Paget disease of bone, male gender, polyostotic involvement, and hearing impairment were noted in more than two-thirds of patients and single-dose intravenous zoledronate was effective in normalizing alkaline phosphatase in almost all patients. PDB is intriguingly more common in South India and this needs more exploration.

Financial support and sponsorship

Nil.

Conflicts of interest

There are no conflicts of interest.

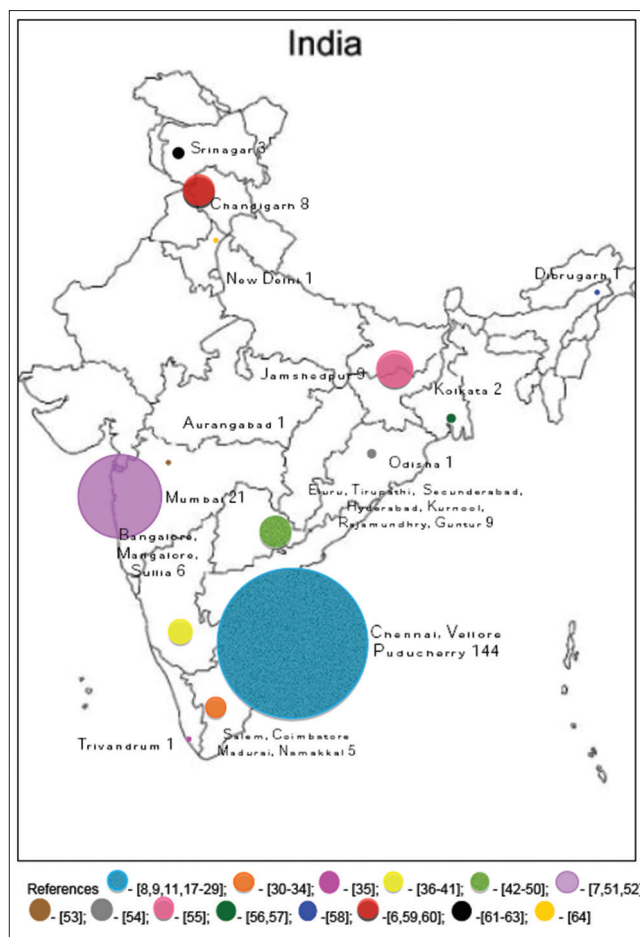


Figure 1: A cartoon of the number of published case reports/series on Paget Disease of Bone from India from Pubmed and Google Scholar from 1963 to 2019.^[17-64] The size of the dots is representative of the number of case reports from that state. Size expressed as a fraction (0.1cm X Number of cases) and for purpose of representation, the largest representation is shown as Square root of (0.1cm X Number of cases)

REFERENCES

- Shaker JL. Paget's disease of bone: A review of epidemiology, pathophysiology and management. *Ther Adv Musculoskelet Dis* 2009;1:107-25.
- Ralston SH, Langston AL, Reid IR. Pathogenesis and management of Paget's disease of bone. *Lancet* 2008;372:155-63.
- Hosking D, Lyles K, Brown JP, Fraser WD, Miller P, Curiel MD, *et al.* Long-term control of bone turnover in Paget's disease with zoledronic acid and risedronate. *J Bone Miner Res* 2007;22:142-8.
- Reid IR, Sharma S, Kalluru R, Egleton C. Treatment of Paget's disease of bone with denosumab: Case report and literature review. *Calcif Tissue Int* 2016;99:322-5.
- Sridhar GR. Paget's disease in India: Is it truly rare? *Natl Med J India* 1994;7:101.
- Bhadada S, Bhansali A, Unnikrishnan AG, Khadgawat R, Singh SK, Mithal A, *et al.* Does Paget's disease exist in India?: A series of 21 patients. *J Assoc Physicians India* 2006;54:530-4.
- Joshi SR, Ambhore S, Butala N, Patwardhan M, Kulkarni M, Pai B, *et al.* Paget's disease from Western India. *J Assoc Physicians India* 2006;54:535-8.
- Anjali, Thomas N, Rajaratnam S, Shanthly N, Oommen R, Seshadri MS. Paget's disease of bone: Experience from a centre in Southern India. *J Assoc Physicians India* 2006;54:525-9.
- Cherian KE, Kapoor N, Shetty S, Jebasingh FK, Asha HS, Hephzibah J,

- et al.* Paget's disease of bone: An entity still exists in India. *Indian J Endocrinol Metab* 2018;22:368-72.
10. Hadjipavlou A, Lander P, Srolovitz H, Enker IP. Malignant transformation in Paget disease of bone. *Cancer* 1992;70:2802-8.
 11. Mahadevan S, Asirvatham AR, Kannan S, Sadacharan D. Scalp vein sign: A forgotten clinical clue? *BMJ Case Rep* 2017;2017:bcr2017220259. doi: 10.1136/bcr-2017-220259.
 12. Palkar S, Mohan V. Paget's disease in diabetic subjects. *J Assoc Physicians India* 2006;54:585.
 13. Yip KM, Lee YL, Kumta SM, Lin J. The second case of Paget's disease (osteitis deformans) in a Chinese lady. *Singapore Med J* 1996;37:665-7.
 14. Hsu LF, Rajasoorya C. A case series of Paget's disease of bone: Diagnosing a rather uncommon condition in Singapore. *Ann Acad Med Singapore* 1998;27:289-93.
 15. Irving K, Jawad ASM. Paget's disease of bone in non-Caucasians in East London: A report of eight cases and a review of literature. *Grand Rounds* 2005;5:23-5.
 16. Sankaran S, Naot D, Grey A, Cundy T. Paget's disease in patients of Asian descent in New Zealand. *J Bone Miner Res* 2012;27:223-6.
 17. Durgia H, Sahoo J, Kamalanathan S, Palui R, Kumar R, Halanaik D, *et al.* Response to zoledronic acid in patients with active Paget's disease of bone: A retrospective study. *Indian J Endocr Metab* 2019;23:117-21.
 18. Narayanan K, Ramakrishnan N, Majumdar D. Paget's disease of the bone. *Med J Armed Forces India* 2003;59:70-2.
 19. Ramesh VG, Deiveegan K, Soundappan V. Vertex extradural hematoma in association with Paget's disease of skull. *Neurol India* 2005;53:115-6.
 20. Paul TV, Gurdasani D, Spurgeon R. Paget disease of bone. *Endocr Pract* 2008;14:255.
 21. Kannan S, Mahadevan S, Sathya A, Sriram U. A tale of three diseases of the bone. *Singapore Med J* 2008;49:e263-5.
 22. Sundaram G, Pramod, Sudhakar U, Kumar J. Periodontal management in Paget's disease: Case presentation and a brief review of literature. *J Indian Soc Periodontol* 2012;16:129-33.
 23. Shetty S, Kapoor N, Prabhu AJ, Paul TV. Paget's disease: A unique case snippet. *BMJ Case Rep* 2014;2014:bcr2013202955. doi: 10.1136/bcr-2013-202955.
 24. Naik D, Asha HS, Mathews SS, Paul TV. Two siblings with Paget's disease of bone. *BMJ Case Rep* 2014;2014:bcr20132032219. doi: 10.1136/bcr-2013-203219.
 25. Shetty S, Shetty S, Prabhu AJ, Kapoor N, Hepzibah J, Paul TV. An unusual presentation of metastatic bone disease in a subject with Paget's disease of bone. *J Family Med Prim Care* 2016;5:488-90.
 26. Kumar R, Selviambigapathy JK, Kamalanathan S, Sahoo JP. Stress fractures healing with bisphosphonates in Paget's disease. *Joint Bone Spine* 2017;84:91.
 27. Verma S, Thakur P, Kapoor N, Cherian KE, Hepzibah J, Paul TV. Visual vignette. *Endocr Prac* 2017;23:1032.
 28. Jayachandran S, Vasudevi R, Kayal L. A typical presentation of Paget's disease with secondary osteomyelitis of mandible. *J Indian Acad Oral Med Radiol* 2017;29:227-30.
 29. Senthil V, Balaji S. Monostotic paget disease of the lumbar vertebrae: A pathological mimicker. *Neurospine* 2018;15:182-6.
 30. Srinivasan KG, Gaikwad A, Ushanandhini KP, Ritesh K. Polyostotic Paget's disease with sarcomatous change in a skull lesion. A case report of imaging findings. *Neuroradiol J* 2007;20:373-6.
 31. Sekar B, Augustine D, Murali S. Paget's disease of mandible. A case report and review of literature. *J Orofac Sci* 2010;2:13-7.
 32. Karunakaran K, Murugesan P, Rajeshwar G, Babu S. Paget's disease of the mandible. *J Oral Maxillofac Pathol* 2012;16:107-9.
 33. Umamaheswari G, Pangarikar AB, Urade VB, Parab PG. Management of craniofacial osteitis deformans. *Ann Maxillofac* 2014;4:243-6.
 34. Kamaleshwaran KK, Natarajan S, Shibu D, Malaikkal A, Shinto AS. Paget's disease of pelvis mimicking metastasis in a patient with lung cancer evaluated using staging and follow-up imaging with fluorine-18 fluorodeoxyglucose-positron emission tomography/computed tomography. *Indian J Nucl Med* 2015;30:151-3.
 35. Sasikumar A, Joy A, Nanabala R, Pillai MR, T A H. 68Ga-PSMA PET/CT false-positive tracer uptake in paget disease. *Clin Nucl Med* 2016;41:e454-5.
 36. Moiyadi AV, Praharaj SS, Pillai VS, Chandramouli BA. Hydrocephalus in Paget's disease. *Acta Neurochir (Wien)* 2006;148:1297-300.
 37. Pandit V, Seshadri S. Paget's disease complicated by hydrocephalus and dementia. *Neurol India* 2008;56:216-8.
 38. Indumathi CK, Dinakar C, Roshan R. Juvenile Paget's disease. *Indian Pediatr* 2009;46:354-6.
 39. Sreejan CK, Gopakumar N, Subhas Babu G. Chronic idiopathic hyperphosphatasia with unusual dental findings-A case report. *J Clin Exp Dent* 2012;4:e313-6.
 40. Rai H, Pai SM, Dayakar A, Javagal V. A rare incident of Paget's disease of bone in early adult life. *J Oral Maxillofac Pathol* 2014;18(Suppl 1):S147-50.
 41. Rai NP, Anekar J, Mustafa SM, Devang Divakar D. Paget's disease with craniofacial and skeletal bone involvement. *BMJ Case Rep* 2016;2016:bcr2016216173. doi: 10.1136/bcr-2016-216173.
 42. Reddy DR, Prabhakar V, Rao BD. Anatomical study of circle of Willis. *Neurol India* 1972;20:8-12.
 43. Avadhanam PK, Ankathi P, Kumar PA. Does Paget's disease of affect a single vertebra? *Neurol India* 2010;58:499-500.
 44. Kalawat T, Batchu S, Parthasarathy R, Bathala C. Polyostotic Paget's disease mimicking multiple skeletal metastasis in planar bone scintigraphy in a patient with carcinoma of breast. *Indian J Nucl Med* 2012;27:50-1.
 45. Shankar YU, Misra SR, Vineet DA, Baskaran P. Paget disease of bone: A classic case report. *Contemp Clin Dent* 2013;4:227-30.
 46. Poliseti N, Neerupakam M, Prathi VS, Prakash J, Vaishnavi D, Beeraka SS, *et al.* Osteonecrosis secondary to Paget's disease: Radiologic and pathologic features. *J Clin Imaging Sci* 2014;4(Suppl 2):1.
 47. Chakravarthi PS, Peravali RK, Kattimani V. Paget's disease in Mandible: A rare occurrence in an Indian Sub-continent. *J Clin Diagn Res* 2015;9:ZJ02-3.
 48. Balani A, Marda SS. Images in clinical medicine. Paget's disease of bone. *N Engl J Med* 2016;374:1264.
 49. Patnayak R, Rajasekhar S, Chintam S, Kalawat TC, Jena A. A case of monostotic Paget's disease. *J Postgrad Med* 2016;62:211-2.
 50. Kumar SRR, Bagalad BS, Manohar CB, Kuberappa PH. Intermediate type of Juvenile Paget's disease: A rare case in Indian population. *Contemp Clin Dent* 2017;8:175-8.
 51. Wali CM, Desai SG, Duggani SV. Paget's disease with quadriplegia (A case report). *J Assoc Physicians India* 1981;29:865-8.
 52. Bhatt K, Balakrishnan C, Mangat G, Bajaj K, Ashavaid T, Joshi VR. Paget's disease of the bone: A report of three cases. *J Assoc Physicians India* 2006;54:571-4.
 53. Kulkarni M, Soni A, Shetkar S, Amer M, Mulavekar A, Joshi P. Coexistent superscan and Lincoln sign on bone scintigraphy. *Clin Nucl Med* 2017;42:630-2.
 54. Mahapatra SK, Mohanty R, Sen K, Beher S, Singh SC, Chaudhri M. Paget's disease of bone in a 85 year old woman. *J Assoc Physicians India* 2009;57:657-9.
 55. Mitra S, Kapoor A, Rawat S. Paget's disease: Not a rarity in India. *Indian J Nucl Med* 2004;19:45-9.
 56. Sharma P, Chatterjee P. Response monitoring to bisphosphonate therapy in monostotic Paget disease using (18) F-FDG PET/CT. *Clin Nucl Med* 2015;40:499-500.
 57. Kumar AA, Kumar P, Prakash M, Tewari V, Sahni H, Dash A. Paget's disease diagnosed on bone scintigraphy: Case report and literature review. *Indian J Nucl Med* 2013;28:121-3.
 58. Dutta A, Baruah RK, Haque R, Jindal S. Paget's disease of bone involving tibia in an Indian male: Deformity correction and fixation with an interlocking nail: A case report. *IOSR J Dent Med Sci* 2016;15:68-72.
 59. Chakraborty D, Mittal BR, Kamaleshwaran KK, Kashyap R, Bhattacharya A, Kumar S. Urinary bladder carcinoma associated with Paget's disease of skull: Imaging findings on Tc99m-MDP bone scintigraphy, F18-Fluoride PET/CT and F18 - FDG PET/CT. *Indian J Nucl Med* 2011;26:42-3.
 60. Hampannavar AS, Tripathy S, Akkina N, Sharma A. Paget's disease of humerus presenting with recurrent fractures. A case report. *Webmed Central Orthop* 2011;2:WMC001624.
 61. Zargar AH, Laway BA, Masoodi SR, Wani AI, Bashir MI, Trambo NA,

- et al.* Paget's disease of the bone. Saudi Med J 1999;20:629-32.
62. Malik RA, Lone NA, Rather HA, Jan VM, Malik JA, Khan KA, *et al.* Asymptomatic Paget's disease of bone presenting with complete atrioventricular block. Chin Med J (Engl) 2008;121:2357-9.
63. Mustafa SA. A 65-year-old female with Paget's disease of skull. J Enam Med Col 2016;6:106-9.
64. Bal CS, Sahoo MK, Damle N. Lincoln's sign. Where should we expect on ^{99m}Tc-MDP bone scintigraphy? Clin Nucl Med 2013;38:e390-1.