

Topical Bromfenac Sodium in Femtosecond Laser-Assisted Cataract Surgery

María Camila Aguilar Sierra¹, Rosa Alvarado-Villacorta², Claudia Palacio Pastrana¹

¹Anterior Segment Department, Fundacion Hospital Nuestra Señora de la Luz, Mexico, ²Cornea and Refractive Department, Asociacion Para Evitar la Ceguera en Mexico, Mexico

Abstract

Purpose: To evaluate the effect of preoperative 0.09% bromfenac ophthalmic solution for the reduction of intraoperative miosis and pain in patients who have undergone femtosecond laser-assisted cataract surgery.

Methods: This prospective randomized clinical study included 65 patients with senile cataracts in the absence of significant ocular comorbidity. The patients received 0.09% bromfenac ophthalmic solution or control placebo twice a day for 3 days before surgery. Pupil diameter was measured at the initiation and finalization of femtosecond laser-assisted cataract surgery, and pain quantification was assessed by an analogous pain scale after one day of follow-up.

Results: A total of 65 patients were randomly divided into two groups. Five patients were excluded due to defective coupling with the laser interface. Each of the 60 patients was randomized to receive preoperative topical treatment with either 0.09% bromfenac or 0.1% sodium hyaluronate. Baseline characteristics were similar between groups for age and gender. The mean change in horizontal and vertical pupil diameter from the preoperative to post-femtosecond laser measurements were significantly less in the bromfenac group than in the placebo group (0.43 ± 0.6 vs. 1.71 ± 0.9 , $P < 0.001$ and 0.40 ± 0.6 vs. 1.78 ± 0.9 , $P < 0.001$, respectively). Compared with untreated patients, the quantification of pain one day after the procedure was significantly lower in the 0.09% bromfenac group (46.7% with a score of 3 vs. 50% with a score of 1, $P < 0.001$, respectively).

Conclusions: The maintenance of pupil dilation and the prevention of miosis were more effective in the 0.09% bromfenac group than in the control group. Likewise, the greater control of postoperative pain represented an additional significant benefit.

Keywords: Bromfenac, Cataract, Femtosecond laser, NSAID, Pupil

Address for correspondence: Claudia Palacio Pastrana, Calle Ezequiel Montes 135, Tabacalera, Ciudad de Mexico, 06030, Mexico.

E-mail: drapalpas@hotmail.com

Submitted: 09-Feb-2019; **Revised:** 14-Jul-2019; **Accepted:** 31-Jul-2019; **Published:** 23-Mar-2020

INTRODUCTION

Femtosecond laser-assisted cataract surgery may enhance safety and precision in eyes undergoing cataract surgery and intraocular lens (IOL) implantation.¹ It has been shown to provide more precise corneal incisions and capsulotomy formation; the reduced phacoemulsification energy by prefragmentation of the crystalline lens is a potential advantage.² On the other hand, laser emissions applied to intraocular tissues might release unwanted cytokines and

inflammatory mediators.³ The literature has shown that significant intraoperative miosis occurs, with a reported prevalence ranging between 9.5% and 32%.³ In addition, small-pupil cataract surgery is more surgically challenging because of comorbidities, with associated higher complication rates.⁴ Sufficient mydriasis must be maintained during cataract surgery to allow for adequate access to the diseased lens and proper placement of an intraocular IOL without causing trauma to the iris.⁵

Access this article online

Quick Response Code:



Website:
www.jcurrophthalmol.org

DOI:
10.1016/j.joco.2019.07.007

This is an open access journal, and articles are distributed under the terms of the Creative Commons Attribution-NonCommercial-ShareAlike 4.0 License, which allows others to remix, tweak, and build upon the work non-commercially, as long as appropriate credit is given and the new creations are licensed under the identical terms.

For reprints contact: reprints@medknow.com

How to cite this article: Aguilar Sierra MC, Alvarado-Villacorta R, Pastrana CP. Topical bromfenac sodium in femtosecond laser-assisted cataract surgery. *J Curr Ophthalmol* 2020;32:32-7.

Previous studies have shown that nonsteroidal anti-inflammatory drugs (NSAIDs) are effective for the treatment or prevention of the postoperative ocular pain and inflammation without the adverse events commonly associated with corticosteroids.⁶⁻⁹ Bromfenac ophthalmic solution 0.09% was the first ophthalmic NSAID to receive Food and Drug Administration (FDA) approval based upon the clearance of anterior chamber inflammation after cataract surgery.¹⁰ The FDA-approved dosing for bromfenac is twice daily. The structure of bromfenac is similar to that of amfenac, with the exception of a bromine atom at the C4 position that confers lipophilicity to the molecule and facilitates its penetration through the cell membrane.¹¹ Bromfenac has been found to be more potent as a COX-2 inhibitor than diclofenac, amfenac, or ketorolac.¹²

This drug has been studied extensively for the control of pain and inflammation after conventional cataract surgery, but there are few reports in the literature about the inhibitory effect of bromfenac on surgically-induced miosis in patients undergoing phacoemulsification surgery.

The purpose of this study was to evaluate the reduction of postoperative pain and control of trans-surgical miosis with the administration of topical 0.09% bromfenac twice daily 3 days before surgery in patients undergoing femtosecond laser-assisted cataract surgery.

METHODS

This was a prospective randomized, single-masked, clinical study in patients undergoing femtosecond laser-assisted cataract surgery with posterior chamber IOL implantation at the Anterior Segment Department of Nuestra Señora de la Luz Hospital, over a period of 8 months from March 2018 to November 2018. The ethics and research committee of the institution approved the study, and patient consent for the study was obtained in accordance with the principles stated in the Declaration of Helsinki. Written informed consent was obtained from all subjects before initiation of any study-related procedure.

Sixty-five patients who met the inclusion/exclusion criteria were included in the study. The inclusion criteria were subjects 18 years of age or older, regardless of race or gender, who were diagnosed with senile and/or metabolic cataracts with a classification of nuclear (colour/opalescence), cortical, and posterior subcapsular opacity with a maximum of 3 according to the Lens Opacities Classification System, version III (LOCS III), and scheduled for unilateral femtosecond laser-assisted cataract surgery with posterior chamber IOL implantation. Exclusion criteria were as follows: the presence of corneal abnormalities; pathologies resulting in poor pupillary dilation (less than 6 mm) as posterior synechiae, history of intraocular surgery, history of ocular or systemic disease (glaucoma, diabetes, uveitis, pseudoexfoliation syndrome), regular systemic use of steroids or NSAIDs during the previous three months, or use of any selective alpha antagonist for the treatment of benign prostatic hyperplasia.

Subjects who met all entry criteria were sequentially assigned to receive either 0.09% bromfenac (Group 1) or the placebo (Group 2) (0.1% sodium hyaluronate) twice daily 3 days before surgery in a 2:1 ratio according to a computer-generated randomization list (using the website [random.org](http://www.random.org)). Preoperatively, all patients underwent a thorough ophthalmic examination and review of concurrent medications and medical history. Age, sex, laterality of surgery, visual acuity, and cataract severity using LOCS III were recorded.

Preoperative pupil dilation was performed using topical 0.5% tropicamide and 5.0% phenylephrine instilled three times at 15-min intervals within 1 h before surgery.

A first preoperative measurement of the maximum horizontal and vertical pupillary dilation diameter was made with the SG05 Castroviejo adjustable calliper under a slit-lamp three days before cataract surgery, and a second confirmatory measurement of the pupillary dilation diameter was performed under a surgical microscope with a SG05 Castroviejo calliper on the day of surgery just before initiating the femtosecond laser. If there was a difference of more than 1 mm between the two measurements, the patient was excluded from the study. It should be clarified that all measurements made on pupil diameter were performed by the same ophthalmologist.

All surgeries were performed in the Anterior Segment Department of Nuestra Señora de la Luz Hospital, Mexico City, under topical anesthesia by the same surgeon who was blinded to patient randomization.

All femtosecond laser pretreatments were performed using the LensX System (Alcon Laboratories, Fort Worth, TX). All laser procedures were performed under topical anesthesia with tetracaine hydrochloride. Anterior capsulotomy (5.0 mm size, 6 mJ pulse energy) and lens fragmentation (10 mJ pulse energy) were then performed with the femtosecond laser under optical coherence tomography (OCT) image control. A standardized lens fragmentation pattern (two cross-sections with a chop diameter of 5.2 mm and one central chop cylinder with a diameter of 3.0 mm) was used. Finally, the axis, width, and length of the primary incision and side-port incision were selected. All the main incisions were made by a superior approach. After completion of the entire laser emission procedure, the vacuum interface was removed, and the patient was transported to a surgery operating room. The same microscope with the same illumination (full) and magnification (x10) was used in all cases to ensure standardization of illumination and magnification during pupillary measurement.

Once the treatment with the femtosecond laser was finished and before opening the incisions of the cornea, a measurement of the horizontal and vertical pupillary diameter was performed in millimetres using the same SG05 Castroviejo adjustable surgical calliper, which measures from 0.0 mm to 20 mm in 0.5 mm increments, under a surgical microscope. The

measurement was made by the same ophthalmologist who performed the two previous measurements.

After hydro dissection, the surgery was completed with standard phacoemulsification using a Stellaris unit (Bausch and Lomb Rochester, New York, United States of America) for automated irrigation/aspiration removal of the cortex. Next, an Envista (Bausch and Lomb Rochester, New York, United States of America) foldable monofocal hydrophobic acrylic IOL was implanted into the capsular bag, using the same viscoelastic material in all cases.

All patients received topical antibiotic-corticosteroid treatment four times daily for 10 days after surgery and were evaluated at one day postoperatively for ocular pain, using a print pain visual analogue scale (VAS) with the endpoints defining extreme limits such as ‘no pain at all’ (0) and ‘pain as bad as it could be’ (10).

This study is registered at protocol.io as dx.doi.org/10.17504/protocols.io.xqjfmun.

Statistical analysis

The sample size was calculated based on data from previous studies, using a calculator for comparing two means, assuming 80% power and a 95% confidence interval using GPower 3.1 software, according to which we needed at least 30 patients in each group.

Statistical analysis was performed by using the STATA program (version 15). A univariate analysis was performed; for the categorical variables, the frequency distribution is reported as a percentage, and for the quantitative variables, measures of central tendency and dispersion were calculated (standard deviation, ranges).

Comparisons between the two groups for the continuous variables (age, pupillary diameter, and changes in pupillary diameter) were made using the Mann-Whitney U test or Student’s *t*-test. The χ^2 test was used to compare the qualitative variables. Statistical significance was established with a *P* value < 0.05.

RESULTS

A total of 65 patients were randomly divided into two groups. Five patients were excluded due to defective coupling with the laser interface. Each of the 60 patients was randomized to receive preoperative topical treatment with either 0.09% bromfenac or 0.1% sodium hyaluronate. The mean age of the study population was 64.7 ± 9.5 years in Group 1 and 64.9 ± 9.8 years in Group 2. Table 1 describes the demographic and clinical features of each group. No significant differences in demographic variables, medical history, or pretreatment ocular characteristics were observed between the two original groups. No significant differences in horizontal or vertical pupil diameter were observed between the two groups at baseline. The mean horizontal pupil diameter was 7.56 ± 0.8 mm in the 0.09% bromfenac group and 7.71 ± 0.6 mm in the control group,

and the mean vertical pupil diameter was 7.72 ± 0.8 mm in the 0.09% bromfenac group and 7.91 ± 0.6 mm in the control group.

The mean change in horizontal and vertical pupil diameter from the preoperative measurement to the post-femtosecond laser measurement did not present a normal distribution, so the Mann-Whitney U test was used to compare the medians of both groups. The mean change in horizontal and vertical pupil diameter was significantly less in the 0.09% bromfenac group than in the vehicle group, i.e., 0.43 ± 0.6 vs. 1.71 ± 0.9, *P* < 0.001 [Figure 1] and 0.40 ± 0.6 vs. 1.78 ± 0.9, *P* < 0.001 [Figure 2], respectively.

Compared with untreated patients, the quantification of pain one day after procedure was significantly lower in the 0.09% bromfenac group (46.7% with a score of 3 vs. 50% with a score of 1, *P* < 0.001). It was found that 15 patients in the group that received pre-surgical NSAIDs had a pain score of 1 versus one patient who received only placebo. Fourteen patients and nine

Table 1: Demographic and ocular characteristics of patients

	Bromfenac	Placebo	<i>P</i> ^a
Age (years±SD)	64.7±9.5	64.9±9.8	0.9256
Sex (%)			
Female	66.7	53.3	0.2918
Male	33.3	46.7	
Eye affected (%)			
Right eye	60	53.3	0.6023
Left eye	40	46.7	
Visual acuity (logMAR±SD)	0.85±0.5	1.01±0.6	0.4085
Pupil diameter horizontal (mean ± SD)	7.56±0.8	7.71±0.6	0.5584
Vertical (mean ± SD)	7.72±0.8	7.91±0.6	0.4766
Lens nuclear grade (LOCS III)			
Nuclear	2.5	2.3	0.703
Cortical	1.9	2	0.97
Capsular	2.1	2	0.82

^a*t*-student, U Mann-Whitney and Chi-square test. SD: Standard deviation, LOCS: Lens opacity classification system

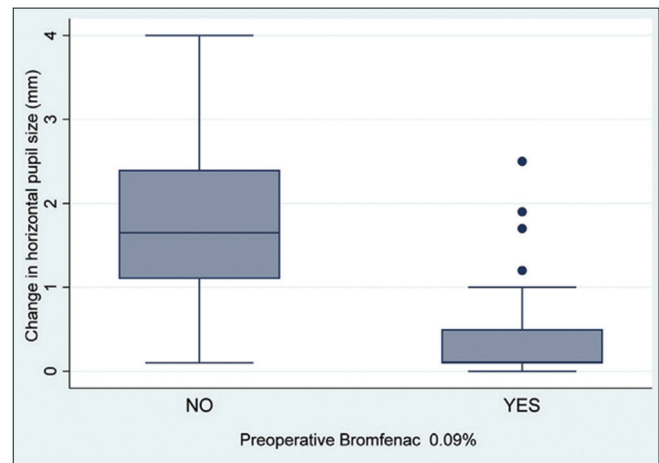


Figure 1: Change in horizontal pupil diameter in patient with either 0.09% bromfenac (study group) or the placebo (control group)

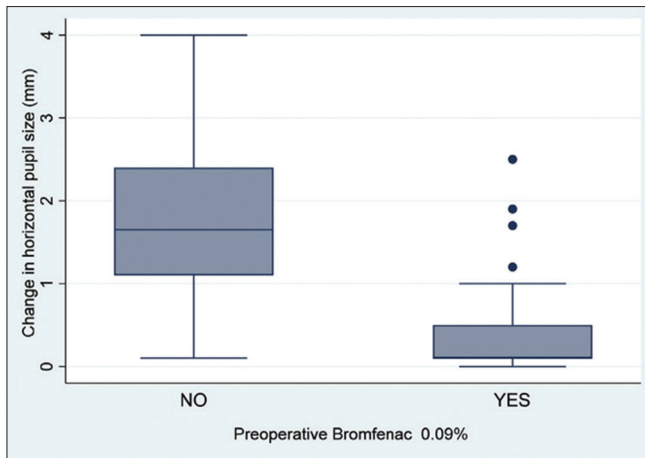


Figure 2: Change in vertical pupil diameter in patient with either 0.09% bromfenac (study group) or the placebo (control group)

patients who did not receive NSAIDs were had VAS scores of 3 and 4, respectively, versus two patients and no patients with VAS scores of 3 and 4, respectively, in the group receiving NSAIDs, as shown in Figure 3.

No statistically significant relationship was found between pupillary dilation and the degree of opacity or nuclear density of the cataract, for the horizontal and vertical pupillary diameter ($r = -0.09$, $P < 0.49$ and $r = -0.043$, $P < 0.74$, respectively), using the Pearson correlation test. Although there was a tendency to present greater maintenance of pupillary dilation in softer cataracts, this was not statistically significant.

Finally, two complications were reported during the surgery; both corresponded to rupture of the posterior capsule, and the two patients were in the placebo group. Both cases showed good dilation at the beginning of surgery (>6 mm). However, during the extraction of the first fragment, pupillary dilation was lost, and patients presented a floppy iris. The first case had a pupillary diameter decrease of 53% and the second case had a pupillary diameter decrease of 46% with respect to the initial measurement. In both cases, rupture of the posterior capsule was present during the aspiration of the last fragment. However, no positive correlation was found between the presence of complications and the administration of placebo versus the application of 0.09% bromfenac.

DISCUSSION

The femtosecond laser has improved precision and safety in phacoemulsification surgery and IOL implantation. However, the emission of shock waves is captured by the ocular tissue and generates the release of multiple inflammatory mediators like cytokines and lens proteins, which act on the smooth muscle of the iris, causing intraoperative miosis.⁵ Nagy and collaborators reported an increase in intraoperative miosis with a prevalence ranging between 9.5% and 32% with the use of the femtosecond laser.¹³ Conversely, Jun and collaborators observed a significant 30% reduction in pupillary area with

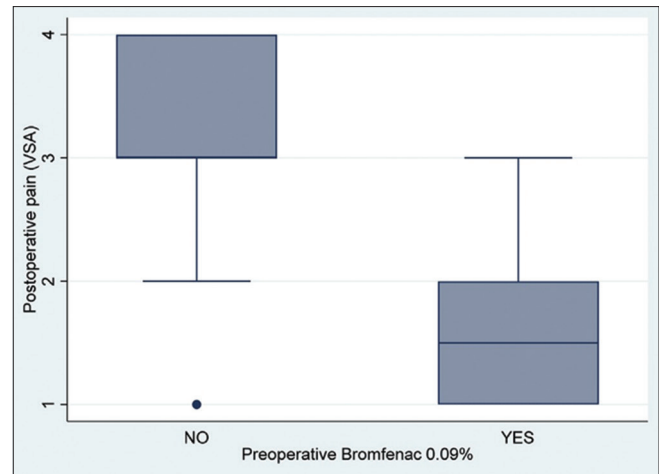


Figure 3: Quantification of pain according to the visual analogue scale in patients with and without 0,09% bromfenac before the surgery

an incidence of pupillary constriction of less than 6 mm in more than 40% of patients undergoing a femtosecond laser procedure.³

It is clear that cataract surgery requires stable and adequate mydriasis during the entire procedure to perform continuous capsulorhexis, complete removal of the cortical remains, and proper implantation of the IOL in the capsular bag.¹⁴

Different strategies have been used to maintain adequate dilation during surgery, including devices that expand the pupil. However, Taipale *et al.* reported a *post hoc* analysis of five consecutive prospective randomized clinical trials that included 536 eyes undergoing routine cataract surgery, analyzed according to the use of a pupil expansion device. They found that aqueous flare was greater in eyes that were operated on with pupil expansion device compared to those without. It was also described in a previous study that patients who develop pseudophakic cystoid macular oedema (PCME) after cataract surgery have significantly higher aqueous flare values than those who do not. In that study, at three months of follow-up, clinically significant PCME was reported in 12% of eyes with a pupil expansion device and in 2% of eyes without ($P = 0.006$).¹⁵

The administration of NSAIDs before cataract surgery reduces the possibility of surgically-induced miosis provoked by the release of prostaglandins induced by the action of the cyclooxygenase enzymatic cascade.¹¹ The efficacy of ophthalmic NSAIDs in preventing miosis has been well documented in cataract surgery by conventional phacoemulsification.⁷ Our findings further demonstrate that the use of pre-surgical 0.09% bromfenac allows for greater control of the miosis generated by the femtosecond laser applied in the Mexican population with a statistically significant difference versus those patients who received placebo with 0.1% sodium hyaluronate.

These results agree with those published by Kiss and collaborators, who also confirmed in laboratory studies that

there is an increase in the level of intracameral prostaglandins after treatment with a femtosecond laser as a result of the absorption of the variable energy required for the fracture of the lens according to its hardness and the formation of intracameral gas bubbles during treatment. Likewise, they demonstrated that prior treatment with topical NSAIDs inhibits the elevation in prostaglandins during the procedure.⁸

The role of postoperative pain control with the use of 0.09% bromfenac was also confirmed in this study. We observed that there was a statistically significant difference in the quantification of pain according to the VAS. Those patients who received only placebo had higher values with respect to patients who received pre-surgical NSAIDs. It was found that 15 patients in the group who received pre-surgical NSAIDs had a pain score of 1 versus one patient who received only placebo. This is consistent with the results reported by Donnenfeld and collaborators who demonstrated that 0.09% bromfenac ophthalmic solution was effective for the rapid resolution of ocular pain after cataract surgery.¹⁰ However, in this study, they only used topical NSAIDs after surgery, achieving resolution of ocular pain in 2 days compared to 5 days in cases that received placebo.

It is important to note, in addition, that no other ophthalmic NSAID has been approved by the FDA with a dosing regimen of twice a day. In contrast to the three- or four-times daily dosing schedules of other ophthalmic NSAIDs, the dosing schedule of every 12 h reduces exposure to the drug, results in greater adherence, and maintains significant clinical efficacy.

Although this study did not specifically study PCME, additional benefits have been reported with the prophylaxis use of preoperative NSAIDs to prevent PCME, especially in high-risk patients. However, studies in the literature have analyzed molecules such as ketorolac 0.4% and indomethacin, so it would be worthwhile to carry out future studies that evaluate the effectiveness of bromfenac in this regard.¹⁶

During our study, only two complications were reported, corresponding to rupture of the posterior capsule. Both patients had a reduction in pupillary diameter of more than 40% with respect to the initial one and were in the placebo group; however, these findings were not statistically significant. It would be necessary to obtain a larger sample size in both groups to confirm the positive correlation between poor pupillary dilation and greater presentation of intraoperative complications.

The limitations of this study may be that the patients were not blinded to the administration of the drug or the placebo; however, the principal investigator verified correct application through a daily record, and patients who did not comply with the application instructions were excluded from the study. The ophthalmologist who performed the measurement of pupillary diameter was blinded during the entire study.

This study may encourage new studies to evaluate and understand the role of NSAIDs for the control of pupil miosis

in patients with additional ophthalmological conditions that predispose to an increased risk of pupillary constriction, ideally including a larger sample of patients in different arms with a diagnosis of diabetes mellitus, the presence of pseudoexfoliation, and the use of alpha 1 receptor antagonists for the treatment of benign prostatic hyperplasia in order to assess the effectiveness of 0.09% bromfenac to reduce the risk of complications inherent to poor dilation in patients with risk factors and a predisposition for this condition.

Finally, additional clinical studies to investigate the effect of topical NSAIDs on visual results, postoperative inflammation, and macular thickening are justified.

The results of the present study indicate that topical 0.09% bromfenac is an effective inhibitor of miosis during femtosecond laser-assisted cataract surgery. Maintenance of pupil dilation and prevention of miosis during femtosecond laser-assisted cataract surgery were more effective in the 0.09% bromfenac group than in the control group. Likewise, greater control of postoperative pain represented an additional significant benefit.

Financial support and sponsorship

Nil.

Conflicts of interest

There are no conflicts of interest.

REFERENCES

1. Stewart R, Grosserode R, Cheetham JK, Rosenthal A. Efficacy and safety profile of ketorolac 0.5% ophthalmic solution in the prevention of surgically induced miosis during cataract surgery. *Clin Ther* 1999;21:723-32.
2. Conrad-Hengerer I, Hengerer FH, Schultz T, Dick HB. Femtosecond laser-assisted cataract surgery in eyes with a small pupil. *J Cataract Refract Surg* 2013;39:1314-20.
3. Jun JH, Hwang KY, Chang SD, Joo CK. Pupil-size alterations induced by photodisruption during femtosecond laser-assisted cataract surgery. *J Cataract Refract Surg* 2015;41:278-85.
4. Yu AY, Lin CX, Wang QM, Zheng MQ, Qin XY. Safety of femtosecond laser-assisted cataract surgery: Assessment of aqueous humour and lens capsule. *Acta Ophthalmol* 2016;94:e534-40.
5. Donaldson KE, Braga-Mele R, Cabot F, Davidson R, Dhaliwal DK, Hamilton R, *et al.* Femtosecond laser-assisted cataract surgery. *J Cataract Refract Surg* 2013;39:1753-63.
6. Srinivasan R, Madhavaranga. Topical ketorolac tromethamine 0.5% versus diclofenac sodium 0.1% to inhibit miosis during cataract surgery. *J Cataract Refract Surg* 2002;28:517-20.
7. Liu C, Liu Y, Ye S, Liu L, Zhang W, Wu M. Effect of topical nonsteroidal anti-inflammatory drugs and nuclear hardness on maintenance of mydriasis during phacoemulsification surgery. *J Ocul Pharmacol Ther* 2014;30:831-6.
8. Kiss HJ, Takacs AI, Kranitz K, Sandor GL, Toth G, Gilanyi B, *et al.* One-day use of preoperative topical nonsteroidal anti-inflammatory drug prevents intraoperative prostaglandin level elevation during femtosecond laser-assisted cataract surgery. *Curr Eye Res* 2016;41:1064-7.
9. Sharma AK, Sharma HR, Sharma R, Singh A. Comparison of preoperative topical dexamethasone phosphate versus ketorolac tromethamine in maintaining intraoperative mydriasis during small incision cataract surgery. *J Clin Diagn Res* 2016;10:NC09-13.
10. Donnenfeld ED, Holland EJ, Stewart RH, Gow JA, Grillone LR, Bromfenac Ophthalmic Solution 009% (Xibrom) Study Group.

- Bromfenac ophthalmic solution 0.09% (Xibrom) for postoperative ocular pain and inflammation. *Ophthalmology* 2007;114:1653-62.
11. Wilson DJ, Schutte SM, Abel SR. Comparing the efficacy of ophthalmic NSAIDs in common indications: A literature review to support cost-effective prescribing. *Ann Pharmacother* 2015;49:727-34.
 12. Riaz N, Wolden SL, Gelblum DY, Eric J. Cataract surgery and nonsteroidal antiinflammatory drugs. *J Cataract Refract Surg* 2016;118:6072-8.
 13. Nagy ZZ, Takacs AI, Filkorn T, Kránitz K, Gyenes A, Juhász É, *et al.* Complications of femtosecond laser-assisted cataract surgery. *J Cataract Refract Surg* 2014;40:20-8.
 14. Ewe SY, Abell RG, Vote BJ. Femtosecond laser-assisted versus phacoemulsification for cataract extraction and intraocular lens implantation: Clinical outcomes review. *Curr Opin Ophthalmol* 2018;29:54-60.
 15. Taipale C, Holmström EJ, Ilveskoski L, Tuuminen R. Incidence of pseudophakic cystoid macular edema in eyes with and without pupil expansion device. *Acta Ophthalmol* 2019;97:688-94.
 16. Chen H, Lin H, Chen W, Zhang B, Xiang W, Li J, *et al.* Topical 0.1% Bromfenac sodium for intraoperative miosis prevention and prostaglandin E2; inhibition in femtosecond laser-assisted cataract surgery. *J Ocul Pharmacol Ther* 2017;33:193-201.