

Ephedrine-Induced Increases in Blood Pressure and Heart Rate Due to Suspected Cardiac Sympathetic Denervation Supersensitivity in a Patient with Parkinson's Disease Under Spinal Anesthesia

Authors' Contribution:
Study Design A
Data Collection B
Statistical Analysis C
Data Interpretation D
Manuscript Preparation E
Literature Search F
Funds Collection G

E **Atsuhiko Kitaura**
C **Kei Houri**
EFG **Shinichi Nakao**

Department of Anesthesiology, Kindai University Faculty of Medicine,
Osaka-Sayama, Osaka, Japan

Corresponding Author: Atsuhiko Kitaura, e-mail: kitaura@med.kindai.ac.jp
Conflict of interest: None declared

Patient: Female, 60
Final Diagnosis: Parkinson disease
Symptoms: Unusual reaction to ephedrine
Medication: Ephedrine
Clinical Procedure: —
Specialty: Anesthesiology





Objective: Rare disease
Background: Denervation supersensitivity to sympathomimetic drugs has been noted in patients with Parkinson's disease (PD) whose cardiac sympathetic nerves are denervated. This phenomenon is not as well recognized as other complications of PD patients, but anesthesiologists should be aware of it because sympathomimetic drugs can sometimes be dangerous to these patients.

Case Report: A 60-year-old woman was scheduled for total hip joint replacement under combined spinal-epidural anesthesia and sedation. She had been diagnosed as PD (stage 4 on the Hoehn and Yahr scale) with a history of orthostatic hypotension. Her ¹²³I-metaiodobenzylguanidine (MIBG) scintigraphy revealed marked reduction of ¹²³I-MIBG accumulation in the heart. In the operating room, we placed an epidural catheter through the Th12–L1 space, and spinal anesthesia (2.6 mL of 0.5% normobaric bupivacaine) was administered. During the surgery, we infused propofol at 100 mg·hr⁻¹ for sedation. When 4 mg of ephedrine was administered intravenously because of marked decrease in patient's blood pressure, we observed unexpectedly large increases in the systolic blood pressure, from 78 mmHg to 168 mmHg, and the heart rate increased from 52 to 84 beats per minute (bpm). This phenomenon recurred each time 4 mg of ephedrine was administered.

Conclusions: We report a case in which ephedrine induced unexpectedly large increases in blood pressure and heart rate in a patient who suffered from PD with severe cardiac sympathetic nerve denervation. We speculate that this phenomenon was caused by denervation supersensitivity of the patient's heart.

MeSH Keywords: 3-Iodobenzylguanidine • Autonomic Denervation • Ephedrine • Parkinson Disease

Full-text PDF: <https://www.amjcaserep.com/abstract/index/idArt/916188>

 1168   2  13



Background

Parkinson's disease (PD) is a chronic, progressive, central nervous system disease caused by loss of dopaminergic neurons within the substantia nigra pars compacta. It is a common disease, and its prevalence in Japan is 100–150 per 100 000 people [1]. The dopaminergic deficiency within the basal ganglia results in movement disorders known as extrapyramidal symptoms, such as bradykinesia, muscle rigidity, resting tremors, and postural instability [2]. Cognitive impairment, psychiatric symptoms, and autonomic nerve dysfunction are also noted in PD patients [2]. In addition, PD patients often have cardiac sympathetic nerve denervation [3]. The most obvious autonomic nerve disorder is orthostatic hypotension. Furthermore, denervation supersensitivity, which is the result of post-synaptic adrenergic receptor proliferation caused by pre-synaptic nerve denervation presenting as excessive cardiovascular responses to sympathomimetic medicines, can develop in PD patients. This phenomenon is often overlooked because it can only be detected when sympathomimetic agents are administered. However, anesthesiologists should be aware of this phenomenon because it can cause dangerous hemodynamic changes [4–6]. Here, we present a case of ephedrine-induced increases in blood pressure and heart rate suspected to be due to denervation supersensitivity in a patient with PD. Written patient consent was obtained for publication.

Case Report

A 60-year-old woman was scheduled for total hip joint replacement under combined spinal-epidural anesthesia and sedation. Her height was 154 cm and her body weight was 51 kg. She developed PD when she was 58 years old. Her brain magnetic resonance imaging (MRI) revealed no findings that might cause parkinsonism (e.g., multiple cerebral infarction, midbrain

atrophy, putamen outer lesion, cerebral atrophy, and cerebellar atrophy). She had slow movement, but was able to walk and stand without assistance. She needed some assistance from her family with daily living activities (e.g., cooking, laundry, and shopping). Although the increased dosage of L-dopa produced some symptom improvement, her symptoms, which included slow movement and gait disturbance, subsequently rapidly progressed and reached stage 4 on the Hoehn and Yahr scale [7]. She also had a history of orthostatic hypotension. Her medications included 300 mg oral levodopa and 3 mg pramipexole hydrochloride hydrate when she was admitted.

Her preoperative blood pressure and heart rate were 120/70 mmHg and 60–80 bpm, respectively, without intervention. Her sinus rhythm had a normal ST-T on electrocardiography, but ^{123}I -metaiodobenzylguanidine (MIBG) scintigraphy revealed markedly reduced ^{123}I -MIBG accumulation in the heart (Figure 1). The early heart-to-mediastinum (H/M) ratio, which was obtained 15 min after injection of ^{123}I -MIBG, was 1.61 (normal range: >2.0). The late H/M ratio, which was obtained 4 h after injection of ^{123}I -MIBG, was 1.42 (normal range: >2.0), and the washout rate was 47.7% (normal range: 9–20%).

In the operating room, after installation of standard monitors, 2 mg of midazolam was intravenously administered for sedation. After placement of a 5-cm epidural catheter cephalad in the epidural space through the Th12–L1 space, a spinal needle was inserted at the L3–L4 space and 2.6 mL of 0.5% normobaric bupivacaine was injected. Surgery was started after confirming the Th7 block height by cold sensation assessment. During the surgery, we infused propofol at $100\text{ mg}\cdot\text{hr}^{-1}$ for sedation. Four mg of ephedrine was administered intravenously when the patient's blood pressure decreased, and then there were large increases in blood pressure, from 78 mmHg to 168 mmHg, and in the heart rate from 52 to 84 bpm (Figure 1). This phenomenon recurred each time 4 mg of ephedrine was administered.

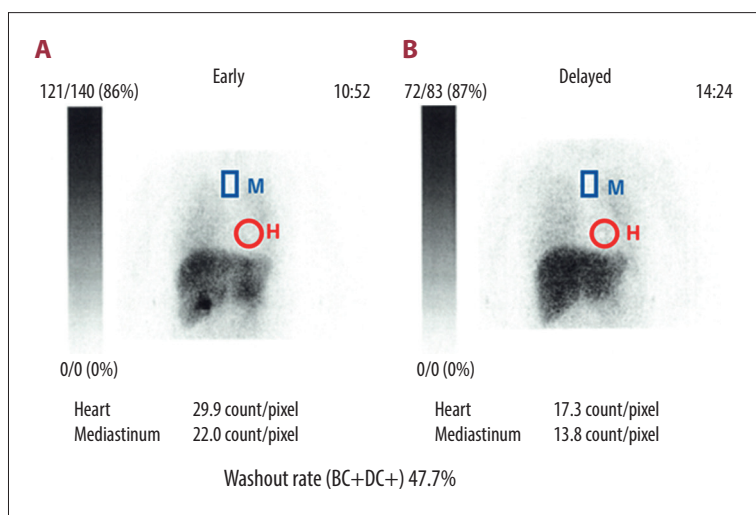


Figure 1. Planar views of ^{123}I -MIBG scintigraphy images. (A) Early image; (B) Late image. Circular regions of interest (ROI) were placed on the heart, and a rectangular ROI was placed on the upper mediastinum. The H/M ratio was defined as the ratio between the mean heart count divided by the mean mediastinal count. The washout rate was calculated as: (early heart count–late heart count)/early heart phase. The H/M ratio in the early phase was 1.61 (normal range ≥ 2.2), and the H/M ratio in the early phase was 1.42 (normal range ≥ 2.2).

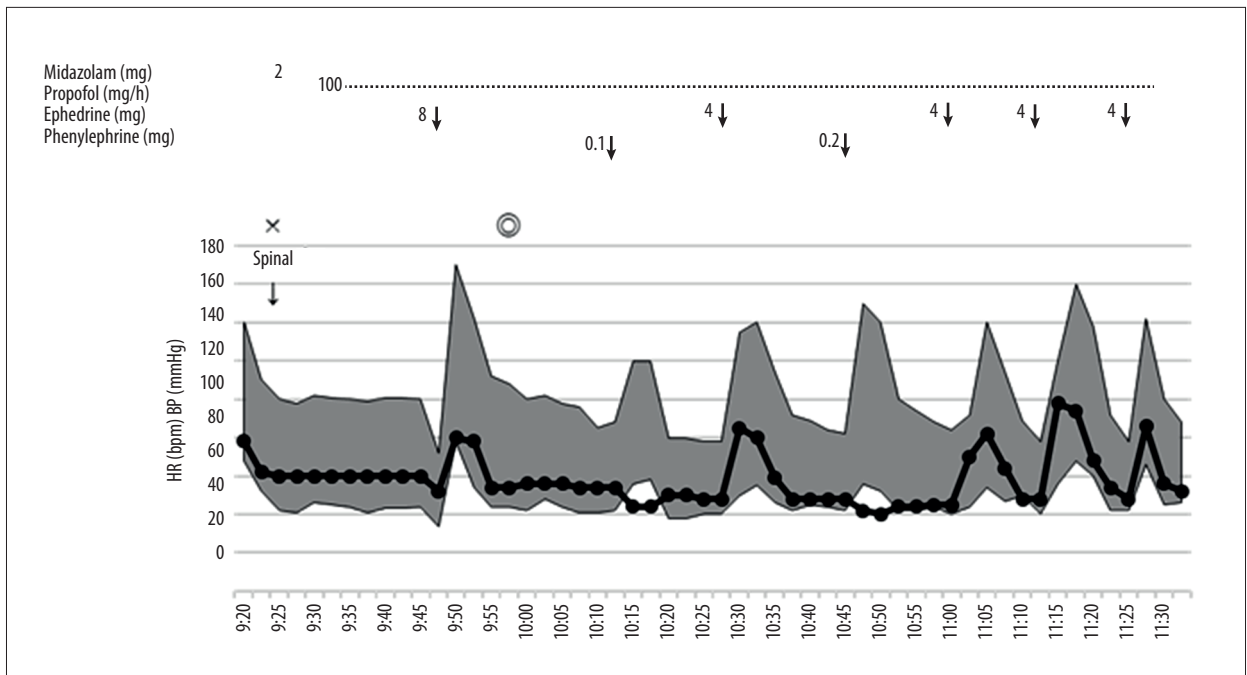


Figure 2. The anesthesia chart of the patient. Four mg of ephedrine reproducibly induced large increases in blood pressure and heart rate.

Discussion

We previously reported a case of unusually strong responses to ephedrine in a patient with PD under general anesthesia, which we thought was due to the sympathetic nerve denervation supersensitivity, because the patient's sympathetic nerves to the heart were completely denervated [6]. However, to the best of our knowledge, there have been few other clinical reports on denervation supersensitivity. The present case shows that denervation supersensitivity in a PD patient is not unusual and can occur under spinal anesthesia.

We report a case of marked response to ephedrine in a patient with PD. Although her history of PD was short, her cardiac sympathetic nerve denervation was severe. This observation was consistent with the report that cardiac sympathetic denervation can occur even in the early stage of PD [8]. MIBG scintigraphy is a useful and important diagnostic test for denervation of cardiac sympathetic nerves. MIBG is an analog of noradrenaline, which is taken into the cardiac cells, but it does not undergo intracellular metabolism or exhibit physiological activity [3]. The early H/M ratio reflects the integrity of pre-synaptic nerve terminals and their uptake functions. The late H/M ratio provides information on neuronal functions from uptake mechanisms to the release of neurotransmitters from the storage vesicles located at nerve terminals. The MIBG washout rate is an index of the degree of sympathetic drive [9]. In our case, MIBG scintigraphy demonstrated a low H/M ratio and a very high washout rate, which were indicative of cardiac sympathetic denervation.

Denervation hypersensitivity was first reported in 1990 [4]; mechanisms have been proposed, including over-expression of heart beta 1 receptor [10], reduction of pre-synaptic re-uptake of noradrenaline [11], and changes downstream of the beta 1 receptor without an increase in the GTP-binding protein alpha subunit levels [12]. Orthostatic hypotension is the most frequently observed symptom caused by cardiac sympathetic denervation in PD patients. In contrast, denervation supersensitivity is rarely noted because it can only be detected when sympathomimetic drugs are administered. In addition, it is difficult to know exactly why this phenomenon occurred, because there are many causes of blood pressure elevation and/or heart rate increases. However, it is important to be aware of this phenomenon because it can have serious consequences. Indeed, Miyamoto et al. reported a case of sustained ventricular tachycardia (VT) in a patient with PD, which occurred after continuous infusion of noradrenaline [5]; the VT subsided when noradrenaline was changed to vasopressin. In the present case, cardiac MIBG accumulation was markedly reduced despite the short PD history, indicating that the cardiac sympathetic nerve denervation was severe. Of note, the patient did not exhibit orthostatic hypotension preoperatively. The administration of 4 mg of ephedrine induced marked increases in blood pressure and heart rate (Figure 2), and this recurred after each ephedrine administration. Although ephedrine can induce marked increases in heart rate and/or blood pressure, the degree of increase caused by the small amount of ephedrine was unusual. There are many factors that can induce increases in either blood pressure or heart rate, such as surgical

and psychological stress, but the patient made no complaints during the operation. Serious complications, such as lethal arrhythmias and hypertension, did not occur in our patient, but we should have used phenylephrine instead of ephedrine because alpha-adrenergic receptor alteration is not involved in the mechanism of denervation supersensitivity [10,12,13].

References:

1. Ministry of Health, Labour and Welfare. Patient report, 2016 <https://www.mhlw.go.jp/toukei/saikin/hw/kanja/10syobyu/dl/h26syobyu.pdf> [in Japanese]
2. Kalia LV, Lang AE: Parkinson's disease. *Lancet*, 2015; 386: 896–912
3. Glodstein DS, Holmes C, Li S-T et al: Cardiac sympathetic denervation in Parkinson disease. *Ann Intern Med*, 2000; 133: 338–47
4. Senard JM, Valet P, Durrieu G et al: Adrenergic supersensitivity in parkinsonisms with orthostatic hypotension. *Eur J Clin Invest*, 1990; 20: 613–19
5. Miyamoto K, Tanaka K, Tanaka T et al: [Cardiac sympathetic denervation supersensitivity in Parkinson's disease.] *J Jpn Soc Intensive Care Med*, 2015; 22: 38–41 [in Japanese]
6. Shirai T, Nakao S, Kitaura A et al: Unusually large ephedrine-induced blood pressure increases due to cardiac sympathetic denervation supersensitivity in a patient with Parkinson's disease. *JA Clinical Reports*, 2018; 4: 44
7. Hoehn M, Yahr M: Parkinsonism: Onset, progression and mortality. *Neurology*, 1967; 17: 427–42
8. Orimo S, Oka T, Miura H et al: Sympathetic cardiac denervation in Parkinson's disease and pure autonomic failure but not in multiple system atrophy. *J Neurol Neurosurg Psychiatry*, 2002; 73: 776–77
9. Agostini D, Nakajima K, Verherne HJ: Innervation of heart: Imaging findings using [123I]-MIBG scintigraphy in different pathologies. In: Marzullo P, Mariani G (eds.), *From Basic Cardiac Imaging to Image Fusion*. Milan: Springer, 2013; 51–70
10. Nakamura T, Hirayama M, Ito H et al: Dobutamine stress test unmasks cardiac sympathetic denervation in Parkinson's disease. *J Neurol Sci*, 2007; 263: 133–38
11. Vatner DE, Lavalley M, Amano J et al: Mechanisms of supersensitivity to sympathomimetic amines in the chronically denervated heart of the conscious dog. *Circ Res*, 1985; 57: 55–64
12. Warner MR, Wisler PL, Hodges TD et al: Mechanisms of denervation supersensitivity in regionally denervated canine hearts. *Am J Physiol*, 1993; 264: H815–20
13. Tamura N, Shimazu K, Yamamoto T et al: [Cardiovascular alpha-, beta 1- and beta 2-adrenoceptor functions in neurogenic orthostatic hypotension.] *Rinsho Shinkeigaku*, 1995; 35: 1120–24 [in Japanese]

Conclusions

We report a case in which ephedrine induced unexpectedly large increases in blood pressure and heart rate in a patient with PD and severe cardiac sympathetic nerve denervation. We speculate that this phenomenon was caused by denervation supersensitivity of the patient's heart.

Conflicts of interest

None