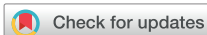



Since January 2020 Elsevier has created a COVID-19 resource centre with free information in English and Mandarin on the novel coronavirus COVID-19. The COVID-19 resource centre is hosted on Elsevier Connect, the company's public news and information website.

Elsevier hereby grants permission to make all its COVID-19-related research that is available on the COVID-19 resource centre - including this research content - immediately available in PubMed Central and other publicly funded repositories, such as the WHO COVID database with rights for unrestricted research re-use and analyses in any form or by any means with acknowledgement of the original source. These permissions are granted for free by Elsevier for as long as the COVID-19 resource centre remains active.



# COVID-19 and SARS-Cov-2 Infection: Pathophysiology and Clinical Effects on the Nervous System

Hilal Abboud<sup>1</sup>, Fatima Zahra Abboud<sup>4</sup>, Hanane Kharbouch<sup>2</sup>, Yasser Arkha<sup>1</sup>, Najia El Abbadi<sup>3</sup>, Abdessamad El Ouahabi<sup>1</sup>

## Key words

- COVID-19
- Long-term consequence
- Nervous system
- Pathophysiology
- SARS-Cov-2

## Abbreviations and Acronyms

**ACE:** Angiotensin-converting enzyme

**ANE:** Acute necrotizing encephalopathy

**CNS:** Central nervous system

**COVID-19:** Coronavirus disease 2019

**CSF:** Cerebrospinal fluid

**CT:** Computed tomography scan

**GBS:** Guillain-Barre syndrome

**MERS-CoV:** Middle East Respiratory Syndrome—Coronavirus

**SARS-CoV:** Severe acute respiratory syndrome coronavirus

**SARS-Cov-2:** Severe acute respiratory syndrome coronavirus-2

**T cells:** Thymus cells

From the Departments of <sup>1</sup>Neurosurgery and <sup>2</sup>Cardiovascular Diseases, Mohamed V University Hospital, Rabat;

<sup>3</sup>Department of Neurosurgery, Abulcasis University Hospital, Rabat; and <sup>4</sup>Department of Radiotherapy and Neuro-oncology, Hassan II University Hospital, Fez, Morocco

To whom correspondence should be addressed:

Hilal Abboud, M.D.

[E-mail: [abboud.hilal@gmail.com](mailto:abboud.hilal@gmail.com)]

Citation: *World Neurosurg.* (2020) 140:49-53.

<https://doi.org/10.1016/j.wneu.2020.05.193>

Journal homepage: [www.journals.elsevier.com/world-neurosurgery](http://www.journals.elsevier.com/world-neurosurgery)

Available online: [www.sciencedirect.com](http://www.sciencedirect.com)

1878-8750/\$ - see front matter © 2020 Elsevier Inc. All rights reserved.

## INTRODUCTION

The clinical course of COVID-19 ranges from asymptomatic infection to severe acute respiratory distress with multiorgan involvement and death. The disease can cause extrapulmonary complications such as neurologic disorders, which are increasingly reported in the literature. Understanding the nervous system involvement pathways and neurologic manifestations can be useful in improving assessment and management of SARS-Cov-2 patients. Indeed, these disorders

■ **BACKGROUND:** Coronavirus disease 2019 (COVID-19) is an infectious disease caused by SARS-Cov-2, resulting in severe acute respiratory syndrome, with high potential of spreading and infecting humans worldwide. Since December 2019, when the virus was identified in humans, the literature on COVID-19 has grown exponentially and extrarespiratory symptoms including neurologic symptoms are increasingly highlighted.

■ **METHODS:** Given the high and increasing number of publications reporting neurologic involvements of SARS-Cov-2, we thought that providing an update for neurologic complications of COVID-19 would be useful for physicians and especially young trainees in neurology and neurosurgery. Indeed, in this review we discuss several neurologic aspects reported in the literature to date including the evidence and pathways of neuroinvasion in COVID-19 and the main neurologic disorders reported in the literature to date, as well as future perspectives and the potential long-term consequence of current neuroinfection in COVID-19 patients.

■ **RESULTS:** Currently, there is convincing evidence that SARS-CoV-2, the etiologic agent of COVID-19, can affect the nervous system, with damage and neurologic alterations. These neurologic disorders are grouped into several categories, ranging from nonspecific and moderate symptoms such as headache, myalgia, and hyposmia to severe symptoms including cerebrovascular disease and intracranial infections. Severe neurologic symptoms such as acute cerebrovascular disease occur only in a minority of patients with usual risk factors and are associated with poor outcome. However, most COVID-19 patients exhibit only minor or mild neurologic symptoms.

■ **CONCLUSIONS:** Management of COVID-19 patients should include early clinical, radiologic, and laboratory neurologic assessment, with a close follow-up, especially in severe forms. Future studies should assess late and long-term consequences of current COVID-19 patients with neurologic involvement.

may interfere with the prognosis or require treatment modification.

## SARS-CoV-2 AND THE NERVOUS SYSTEM: A WELL-ESTABLISHED LINK

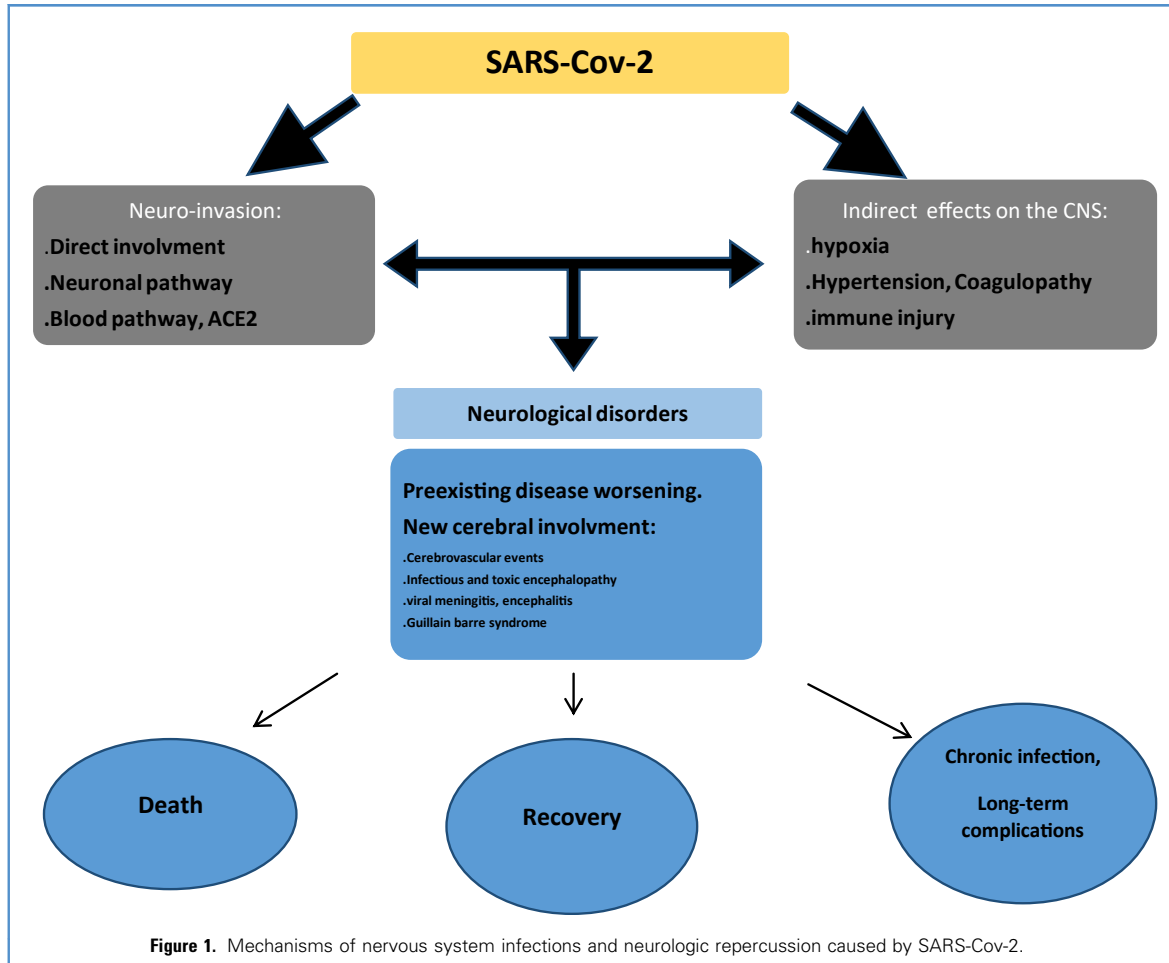
Although pneumonia is the most frequent manifestation of COVID-19, many other extrapulmonary involvements including nervous system have been reported.<sup>1</sup> Given high rates of COVID-19 infection in the general population, coincidental occurrence of neurologic events is likely. However, currently there is convincing evidence that SARS-Cov-2 can involve the

nervous system, and its neurotropic potential is increasingly well established.

## SARS-Cov-2 and SARS-Cov: High Similarities

Genomic analysis shows that SARS-CoV-2 is in the same beta-coronavirus clade as MERS-CoV and SARS-CoV and shares a highly homologous sequence with SARS-CoV.<sup>2</sup> In addition, the entry of SARS-CoV-2 into human host cells has been identified to use the same receptor as SARS-CoV.<sup>3,4</sup>

A growing body of evidence shows that neurotropism is a common feature of coronaviruses, which share a similar viral



structure and infection pathway,<sup>5</sup> and therefore the infection mechanisms and neurotropism previously found for other coronavirus may also be applicable for SARS-CoV-2.

#### SARS-CoV and SARS-CoV-2: A Documented Neuroinvasion

Previous autopsy studies identified SARS-CoV in brain tissue from both patients with significant central nervous system symptoms and experimental animals.<sup>6,7</sup> Recently, a Japanese team reported a young patient with convulsions and unconsciousness; he was diagnosed with aseptic encephalitis with SARS-CoV-2 ribonucleic acid in cerebrospinal fluid (CSF).<sup>8</sup>

SARS-CoV-2 has also been identified in the CSF of a 56-year-old male who developed COVID-19 in China<sup>9</sup>; this case remains unpublished in peer-reviewed literature but has been cited by other papers.<sup>10</sup> Note that

viral particles were also identified in brain tissue from postmortem examination of a SARS-CoV-2–infected patient.<sup>11</sup>

#### Neurologic Complications Related to Coronavirus

Published case series of other coronavirus respiratory viruses like MERS-CoV and SARS-CoV in prior years have listed many neurologic complications including intracranial hemorrhage, ischemic stroke, polyneuropathy, encephalitis, and Guillain-Barre syndrome.<sup>12-14</sup>

#### MECHANISMS OF NEUROINVASION AND REPERCUSSIONS ON THE NERVOUS SYSTEM

##### Direct Brain Invasion

**Direct Involvement.** Dissemination across the cribriform plate of the ethmoid bone

during the infection can lead to cerebral invasion; this was reported in SARS-CoV (Figure 1).<sup>15</sup>

**Neuronal Pathway.** Altered sense of smell and/or taste in uncomplicated early-stage COVID-19 patients is suggestive of a movement of the virus to the brain via the olfactory bulb, which enables the virus to reach and affect the brain.<sup>16</sup>

**Blood Circulation Pathway and ACE2 Receptor.** SARS-Cov-2 has been shown to use the ACE2 receptor for cell entry.<sup>17</sup> This receptor has also been detected over glial cells and neurones, which make it a potential target for COVID-19.<sup>18</sup> Moreover, SARS-CoV-2 spike protein could interact with ACE2 expressed in the capillary endothelium; the virus may also damage the blood-brain barrier and enter

the CNS by attacking the vascular system.<sup>18</sup>

### Indirect Effects on the Central Nervous System

**Hypoxia.** When a virus replicates and proliferates in pneumocytes, it causes diffuse alveolar and interstitial inflammatory exudate, as well as the formation of membranes in the most severe forms. This, in turn, leads to alveolar gas exchange disorders causing hypoxia in the CNS, increasing the anaerobic metabolism in brain cells, inducing cellular and interstitial edema, obstructing cerebral flow blood, as well as ischemia and vasodilation in the cerebral circulation.<sup>19</sup>

**ACE2, Hypertension, and Coagulopathy.** SARS-Cov-2 binds to ACE2 with a high affinity compared with SARS-CoV.<sup>20</sup> ACE2 is known to be a cardiocerebral vascular protection factor, playing a major role in regulating blood pressure and antiatherosclerosis mechanisms. Binding to ACE2, the previously mentioned viruses may cause abnormally elevated blood pressure and increase the risk of cerebral hemorrhage and ischemic stroke.

In addition, patients with COVID-19 often suffer from coagulopathy and prolonged prothrombin time,<sup>21,22</sup> both of which are also contributing factors to secondary cerebral hemorrhage.

**Immune-Meditated neurologic Injury.** The immune response can also play a role. Some patients with COVID-19 have died from hyperinflammatory syndrome (cytokine storm) and multiorgan failure.<sup>23</sup> Coronaviruses have the ability to infect macrophages and glial cells. Experimental models have shown that glial cells are capable of secreting proinflammatory factors, such as interleukin-6, interleukin-12, interleukin-15, and tumor necrosis factor alpha, after coronavirus infection.<sup>24</sup>

### Chronic Phase

The usual lack of permeability of cerebral blood vessels represents a barrier to virus invasion, but also a barrier to viruses' elimination in case of brain invasion. Given the lack of major histocompatibility complex antigen in nerve cells, the elimination of viruses is limited and depends

on the role of cytotoxic T-cells and apoptosis of infected neurons.<sup>25</sup>

The previously mentioned characteristics contribute to the chronic existence of viruses and may facilitate exacerbation of neurologic damage. Note that neuronal degeneration has been identified in SARS-CoV-infected patients, and viral particles were identified in human brain tissue and CSF in multiple sclerosis patients.<sup>26</sup>

### POTENTIAL NEUROLOGIC DISORDERS

A previous study in Wuhan, when the pandemic was first described, demonstrated that 36% of 214 patients hospitalized for COVID-19 developed neurologic symptoms or secondary cerebral events. Others studies reported several categories of central and peripheral neurologic disorders in COVID-19 patients. Here we highlight the main neurologic disorders observed in COVID-19 patients to date:

#### Nonspecific and Systemic Neurologic Symptoms

Headache, myalgia, dizziness, and fatigue are the most common nonspecific symptoms seen in COVID-19 patients. These symptoms range from 30% to 45.5% and are more common as the disease is severe.

**Headache.** The most reported neurologic symptom in COVID-19 patients. Several studies showed headache as a symptom occurred in 8% to 34% of patients, and the intensity is often described as mild.<sup>10,27</sup>

**Myalgia.** Myalgia has been commonly reported during the infection process. Some patients showed fatigue, muscle soreness, and elevated muscle enzyme levels, which may be related to the inflammation and muscle damage caused by the virus.<sup>28</sup>

#### Moderate Symptoms

**Hyposmia, Hypoguesia, and Visual Dysfunction.** Hyposmia or anosmia and, less commonly, disturbed taste is common in patients with COVID-19, even in the absence of nasal symptoms, and may be initial and appear suddenly.<sup>29</sup>

In a study reporting 417 patients with mild to moderate COVID-19 patients, 85.6% and 88% of the patients, respectively, described disturbances of smell and taste, and olfactory dysfunction was the initial symptom in 12% of the cases.<sup>30</sup>

Other moderate nervous symptoms including deficit in visual function and neuralgia were also reported; however, an electrophysiology report of COVID-19 with peripheral nervous system symptoms is still lacking.<sup>1</sup>

**Encephalopathy.** Infectious toxic encephalopathy, also known as acute toxic encephalitis, is a reversible brain dysfunction syndrome caused by factors such as systemic toxemia, metabolic disorders, and hypoxia during the process of acute infection.<sup>31</sup> The basic pathologic changes include cerebral edema, with no evidence of inflammation on CSF analysis. Clinical symptoms are complex and diverse including headache, dysphoria, mental disorder, and delirium. Some rare severe forms may experience disorientation, loss of consciousness, coma, and paralysis.<sup>32</sup>

**Epilepsy, Paralysis, and Consciousness Disorders.** Epilepsy, as well as paralysis and consciousness disorder, is a symptom associated with many underlying intracranial lesions and has been reported in COVID-19 patients. It may result from hypoxia, multiorgan failure, or metabolic and electrolyte derangements. This symptom may require specific medication and neurologic assessment. Hence it is plausible to expect clinical or subclinical acute symptomatic seizures and status epilepticus to happen in these patients.<sup>1,33</sup>

#### Severe Symptoms

**Cerebrovascular Events.** Several categories of cerebrovascular events (intracerebral hemorrhage, ischemic stroke, and cerebral venous thrombosis) were recently reported in COVID-19 patients.

**Intracerebral Hemorrhage.** Several cases have been reported in elderly COVID-19 patients with the usual risk factors, such as hypertension, diabetes, and underlying cardiac disease. Binding to ACE2, which is known to be a cerebrovascular protective factor, SARS-Cov-2 may cause abnormally elevated blood pressure. This hypertension, associated with the presence of thrombocytopenia and bleeding disorders, is a factor that may contribute and increase the risk of intracerebral hemorrhage in patients with COVID-19.<sup>34,35</sup>

**Ischemic Stroke.** SARS-Cov-2 infection has been suggested to cause stroke. Current evidence suggests that COVID-19 patients

commonly had neurologic symptoms manifested as acute stroke in 2.8% to 6%, and most (80%) were ischemic.<sup>36,37</sup> A number of potential mechanisms by which COVID-19 might increase ischemic stroke risk have been reported. These include hypercoagulability as evidenced by raised D-dimer levels, exaggerated systemic inflammation (cytokine storm), and cardioembolism from virus-related cardiac injury.<sup>37</sup>

**Acute Necrotizing Encephalopathy.** Acute necrotizing encephalopathy, a rare disorder leading to brain dysfunction, has been reported recently in COVID-19 patients. It results in seizures, liver problems, and mental disorientation.<sup>9</sup> The disease is characterized by multifocal symmetric lesions in the brain, which affect the brainstem, thalami, cerebellum, and cerebral white matter. ANE is characterized by neuroinflammation resulting from a cytokine storm mediated mainly by the production of the interleukin-6. This systemic inflammation causes severe encephalopathy in the patient and may lead to stroke.

**Meningitis and Encephalitis.** The first case of COVID-19 with encephalitis was reported in Beijing, China. The man presented with convulsions and persistent hiccups. Neurologic examination revealed bilateral ankle clonus, bilateral positive Babinski sign, and meningeal irritation. The patient had a normal computed tomography scan. A lumbar puncture showed an increased opening pressure of 330 mm H<sub>2</sub>O and normal biochemical and cytologic parameters with a positive polymerase chain reaction for SARS-CoV-2.<sup>28</sup> Another case of meningitis associated with coronavirus was recently reported in Japan, in a young patient without medical history, with a negative nasopharyngeal swab. The SARS-Cov-2 ribonucleic acid was detected in CSF.<sup>8</sup> Note that symptoms of meningitis or encephalitis may be the first symptoms, as well as the respiratory symptoms.

**Guillain-Barre Syndrome.** A case of Guillain-Barre syndrome (GBS) associated with SARS-CoV-2 infection has been described in a 62-year-old patient who presented motor weakness in the lower extremities and clinical symptoms of COVID-19 a week later. The CSF study

showed a hyperproteinorachia (124 mg/dL) and absence of cells. Neurophysiologic examination revealed an increase in distal latencies and an absence of F-waves, pointing to a demyelinating form of GBS. The authors suggest that the patient was infected with SARS-CoV-2 at the onset of GBS symptoms, as she had lymphopenia and thrombocytopenia.<sup>38</sup>

### Potential Long-Term Central Nervous System Consequences of COVID-19: Neurodegenerative and Demyelinating Disorders

Given the chronic neuroinflammation and neuronal degeneration reported in SARS-CoV patients, as well as the viral particles found in multiple sclerosis patients,<sup>25,26</sup> and considering that human neurodegenerative diseases often involve a gradual process that evolves, in some cases, over several decades, we think that current COVID-19 patients, especially with neurologic symptoms, may develop late and long-term neurologic complications. Hence they should be closely followed up, and futures studies should consider late neurologic complications, such as demyelinating and degenerative disorders in these patients (e.g., polyneuropathies, Parkinson disease, multiple sclerosis).

### CONCLUSION

Currently, there is convincing evidence that SARS-CoV-2, the etiologic agent of COVID-19, can affect the nervous system, with damage and neurologic alterations. Management of COVID-19 patients should include early clinical, radiologic, and laboratory neurologic assessment, with a close follow-up, especially in severe forms. Future studies should assess late and long-term consequences of current COVID-19 patients with neurologic involvement.

### REFERENCES

- Mao L, Jin H, Wang M, et al. Neurologic manifestations of hospitalized patients with coronavirus disease 2019 in Wuhan, China [e-pub ahead of print]. *JAMA Neurol.* 2020. e201127. <https://doi.org/10.1001/jamaneurol.2020.1127>, accessed February 28, 2020.
- Yu F, Du L, Ojcius DM, Pan C, Jiang S. Measures for diagnosing and treating infections by a novel coronavirus responsible for a pneumonia outbreak originating in Wuhan, China. *Microbes Infect.* 2020; 22:74-79.

- Lu R, Zhao X, Li J, et al. Genomic characterisation and epidemiology of 2019 novel coronavirus: implications for virus origins and receptor binding. *Lancet.* 2020;395:565-574.
- Wan Y, Shang J, Graham R, Baric RS, Li F. Receptor recognition by the novel coronavirus from Wuhan: an analysis based on decade-long structural studies of SARS coronavirus. *J Virol.* 2020;94:e00127-20.
- Yuan Y, Cao D, Zhang Y, et al. Cryo-EM structures of MERS-CoV and SARS-CoV spike glycoproteins reveal the dynamic receptor binding domains. *Nat Commun.* 2017;8:15092.
- Gu J, Gong E, Zhang B, et al. Multiple organ infection and the pathogenesis of SARS. *J Exp Med.* 2005;202:415-424.
- Xu J, Zhong S, Liu J, et al. Detection of severe acute respiratory syndrome coronavirus in the brain: potential role of the chemokine MIG in pathogenesis. *Clin Infect Dis.* 2005;41:1089-1096.
- Moriguchi T, Harii N, Goto J, et al. A first case of meningitis/encephalitis associated with SARS-Coronavirus-2. *Int J Infect Dis.* 2020;94:55-58.
- Poyiadji N, Shahin G, Noujaim D, Stone M, Patel S, Griffith B. COVID-19-associated Acute Hemorrhagic Necrotizing Encephalopathy: CT and MRI features [e-pub ahead of print]. *Radiology.* <https://doi.org/10.1148/radiol.2020201187>, accessed April 30, 2020.
- Huang NC, Wang Y, Li X, et al. Clinical features of patients infected with 2019 novel coronavirus in Wuhan, China. *Lancet.* 2020;395:497-506.
- Paniz-Mondolfi A, Bryce C, Grimes Z, et al. Central nervous system involvement by severe acute respiratory syndrome coronavirus-2 (SARS-CoV-2) [e-pub ahead of print]. *J Med Virol* <https://doi.org/10.1002/jmv.25915>, accessed April 21, 2020.
- Algahtani H, Subahi A, Shirah B. Neurological complications of Middle East respiratory syndrome coronavirus: a report of two cases and review of the literature. *Case Rep Neurol Med.* 2016; 2016:3502683.
- Kim JE, Heo JH, Kim HO, et al. Neurological complications during treatment of Middle East respiratory syndrome. *J Clin Neurol.* 2017;13: 227-233.
- Sellner J, Taba P, Öztürk S, Helbok R. The need for neurologists in the care of COVID-19 patients [e-pub ahead of print]. *Eur J Neurol* <https://doi.org/10.1111/ene.14257>, accessed April 23, 2020.
- Netland J, Meyerholz DK, Moore S, Cassell M, Perlman S. Severe acute respiratory syndrome coronavirus infection causes neuronal death in the absence of encephalitis in mice transgenic for human ACE2. *J Virol.* 2008;82:7264-7275.
- Swanson PA 2nd, McGavern DB. Viral diseases of the central nervous system. *Curr Opin Virol.* 2015;11: 44-54.
- Yan R, Zhang Y, Li Y, Xia L, Guo Y, Zhou Q. Structural basis for the recognition of the SARS-CoV-2 by full-length human ACE2. *Science.* 2020; 367:1444-1448.

18. Baig AM, Khaleeq A, Ali U, Syeda H. Evidence of the COVID-19 virus targeting the CNS: tissue distribution, host-virus interaction, and proposed neurotropic mechanisms. *ACS Chem Neurosci*. 2020; 11:995-998.
19. Abdennour L, Zeghal C, Deme M, Puybasset L. Interaction brain-lungs. *Ann Fr Anesth Reanim*. 2012; 31:e101-e107.
20. Gheblawi M, Wang K, Viveiros A, et al. Angiotensin converting enzyme 2: SARS-CoV-2 receptor and regulator of the renin-angiotensin system. *Circ Res*. 2020;126:10.
21. Chen ZM, Fu JF, Shu Q, et al. Diagnosis and treatment recommendations for pediatric respiratory infection caused by the 2019 novel coronavirus [e-pub ahead of print]. *World J Pediatr* <https://doi.org/10.1007/s12519-020-00345-5>, accessed February 5, 2020.
22. Wang D, Hu B, Hu C, et al. Clinical characteristics of 138 hospitalized patients with 2019 novel coronavirus-infected pneumonia in Wuhan, China [e-pub ahead of print]. *JAMA* <https://doi.org/10.1001/jama.2020.1585>, accessed February 7, 2020.
23. Mehta P, McAuley DF, Brown M, et al. COVID-19: consider cytokine storm syndromes and immunosuppression. *Lancet*. 2020;395:1033-1034.
24. Bohmwald K, Gálvez NMS, Ríos M, Kalergis AM. Neurologic alterations due to respiratory virus infections. *Front Cell Neurosci*. 2018;12:386.
25. Reinhold AK, Rittner HL. Barrier function in the peripheral and central nervous system—a review. *Pflugers Arch*. 2017;469:123-134.
26. Murray RS, Brown B, Brian D, Cabirac GF. Detection of coronavirus RNA and antigen in multiple sclerosis brain. *Ann Neurol*. 1992;31:525-533.
27. Xu X-W, Wu X-X, Jiang X-G, et al. Clinical findings in a group of patients infected with the 2019 novel coronavirus (SARS-CoV-2) outside of Wuhan, China: retrospective case series. *BMJ*. 2020;368:m606.
28. Liu K, Pan M, Xiao Z, Xu X. Neurological manifestations of the coronavirus (SARS-CoV-2) pandemic 2019-2020 [e-pub ahead of print]. *J Neurol Neurosurg Psychiatry* <https://doi.org/10.1136/jnnp-2020-323177>, accessed April 20, 2020.
29. Giacomelli A, Pezzati L, Conti F, et al. Self-reported olfactory and taste disorders in SARS-CoV-2 patients: a cross-sectional study [e-pub ahead of print]. *Clin Infect Dis* <https://doi.org/10.1093/cid/ciaa330>, accessed March 26, 2020.
30. Lechien JR, Chiesa-Estomba CM, De Siaty DR, Horoi M, Le Bon SD, Rodríguez A. Olfactory and gustatory dysfunctions as a clinical presentation of mild-to-moderate forms of the coronavirus disease (COVID-19): a multicenter European study [e-pub ahead of print]. *Eur Arch Otorhinolaryngol* <https://doi.org/10.1007/s00405-020-05965-1>, accessed April 6, 2020.
31. Mizuguchi M, Yamanouchi H, Ichiyama T, Shiomi M. Acute encephalopathy associated with influenza and other viral infections. *Acta Neurol Scand Suppl*. 2007;186:45-56.
32. Dobbs MR. Toxic encephalopathy. *Semin Neurol*. 2011;31:184-193.
33. Chen N, Zhou M, Dong X, et al. Epidemiological and clinical characteristics of 99 cases of 2019 novel coronavirus pneumonia in Wuhan, China: a descriptive study. *Lancet*. 2020;395:507-513.
34. Li Y, Wang M, Zhou Y, et al. Acute cerebrovascular disease following COVID-19: a single, retrospective, observational study *Lancet*; 2020. Available at: <https://doi.org/10.2139/ssrn.3550025>; 2020. Accessed March 3, 2020.
35. Sharifi-Razavi A, Karimi N, Rouhani N. COVID-19 and intracerebral haemorrhage: causative or coincidental? *N Microbes N Infect*. 2020;35:100669.
36. Filatov A, Sharma P, Hindi F, Espinosa PS. Neurological complications of coronavirus disease (COVID-19): encephalopathy. *Cureus*. 2020;12:e7352.
37. Markus HS, Brainin M. COVID-19 and stroke—a global World Stroke Organization perspective [e-pub ahead of print]. *Int J Stroke* <https://doi.org/10.1177/174749320923472>, accessed April 29, 2020.
38. Zhao H, Shen D, Zhou H, Liu J, Chen S. Guillain-Barré syndrome associated with SARS-CoV-2 infection: causality or coincidence? *Lancet Neurol*. 2020;19:383-384.

*Conflict of interest statement: The authors declare that the article content was composed in the absence of any commercial or financial relationships that could be construed as a potential conflict of interest.*

*Received 13 May 2020; accepted 20 May 2020*

*Citation: World Neurosurg. (2020) 140:49-53.*

*<https://doi.org/10.1016/j.wneu.2020.05.193>*

*Journal homepage: [www.journals.elsevier.com/world-neurosurgery](http://www.journals.elsevier.com/world-neurosurgery)*

*Available online: [www.sciencedirect.com](http://www.sciencedirect.com)*

*1878-8750/\$ - see front matter © 2020 Elsevier Inc. All rights reserved.*