

# Reattachment After Foldable Capsular Vitreous Body Implantation in Severe Retinal Detachment Eyes

Sheng Chen<sup>1,\*</sup>, Meiwen Tian<sup>1,2,\*</sup>, Liang Zhang<sup>3</sup>, Chenli Hu<sup>1</sup>, Ke Liu<sup>1</sup>, Bo Qin<sup>3</sup>, and Shenwen Liu<sup>1</sup>

<sup>1</sup> Affiliated Shenzhen Eye Hospital of Jinan University, Shenzhen Eye Hospital, Shenzhen Key Laboratory of Ophthalmology, Shenzhen University School of Medicine, Shenzhen, Guangdong province, China

<sup>2</sup> Second Clinical College of Jinan University, Shenzhen, Guangdong Province, China

<sup>3</sup> Shenzhen Aier Eye Hospital, Shenzhen, Guangdong Province, China

**Correspondence:** Bo Qin, Shenzhen Aier Eye Hospital, Shenzhen, Guangdong Province, China. e-mail: [qinbozf@163.com](mailto:qinbozf@163.com).

Shenwen Liu, Affiliated Shenzhen Eye Hospital of Jinan University, Shenzhen Eye Hospital, Shenzhen Key Laboratory of Ophthalmology, Shenzhen University School of Medicine, Shenzhen, Guangdong province, China. e-mail: [liushenwents@126.com](mailto:liushenwents@126.com)

**Received:** February 22, 2021

**Accepted:** July 11, 2021

**Published:** September 7, 2021

**Keywords:** foldable capsular vitreous body; pars plana vitrectomy; severe retinal detachment; silicone oil tamponade

**Citation:** Chen S, Tian M, Zhang L, Hu C, Liu K, Qin B, Liu S. Reattachment after foldable capsular vitreous body implantation in severe retinal detachment eyes. *Transl Vis Sci Technol.* 2021;10(11):8. <https://doi.org/10.1167/tvst.10.11.8>

**Purpose:** To evaluate the clinical effectiveness and safety of foldable capsular vitreous body (FCVB) implantation for severe retinal detachment.

**Methods:** A retrospective analysis was performed on 26 patients with severe ocular trauma and one with recurrent retinal detachment. Clinical data—including surgery success, complications, retinal reattachment, vision, and intraocular pressure (IOP)—were analyzed for patients who underwent 23G pars plana vitrectomy and FCVB implantation combined with silicone oil tamponade.

**Results:** The mean follow-up period was  $10.44 \pm 2.68$  months. All surgeries were smooth; the FCVBs were properly positioned and supported the retina well, and the retinal reattachment rate reached 92.59%. At the six-month follow-up, preoperative ( $1.30 \pm 1.20$ ) and postoperative ( $0.63 \pm 0.79$ ) vision was significantly different ( $t = 3.03$ ,  $P = 0.005$ ), and the postoperative IOP ( $7.93 \pm 3.57$  mm Hg) was lower than the preoperative IOP ( $13.98 \pm 10.72$  mm Hg) ( $t = 2.74$ ,  $P = 0.01$ ). Among 20 patients followed up for > 12 months, preoperative ( $1.20 \pm 0.95$ ) and postoperative ( $0.75 \pm 0.91$ ) visions were significantly different ( $t = 1.831$ ,  $P = 0.005$ ), and the postoperative IOP ( $9.85 \pm 6.48$  mm Hg) was lower than the preoperative IOP ( $14.85 \pm 12.17$  mm Hg) ( $t = 1.82$ ,  $P = 0.01$ ). No endophthalmitis, sympathetic ophthalmia, and rejection of FCVB occurred during follow-up.

**Conclusions:** FCVB combined with silicone oil tamponade showed good efficacy and safety in severe retinal detachment treatment during the follow-up period.

**Translational Relevance:** Vitreous substitution is deemed a highly challenging and interesting research topic in ophthalmology. Traditional method such as silicone oil tamponade often causes various complications such as silicone oil emulsification, silicone oil migration, and corneal degeneration. The foldable capsular vitreous body as a novel vitreous substitute combined silicone oil injection into it can stay in the eyeball for a long time without obvious complications.

## Introduction

The natural vitreous body is a transparent, gel-like, nonrenewable structure occupying 80% of the volume of the eyeball, which is mainly composed of water, collagen fibers, hyaluronic acid, and mucopolysaccharides. The natural vitreous body can support the eyeball, supply nutrition, act as an ocular refractive

media and cell barrier, and facilitate intraocular nutritional metabolism.<sup>1,2</sup> Since Cibis introduced the use of silicone oil in the treatment of retinal detachment in 1962, it has been used as a vitreous substitute to treat severe retinal detachment.<sup>3</sup> Globally, pars plana vitrectomy (PPV) in combination with silicone oil tamponade is the primary treatment for patients with severe retinal detachment.<sup>4-6</sup> However, this treatment method often causes various complications such as silicone

oil emulsification,<sup>7</sup> silicone oil migration, and corneal degeneration. If the retina does not reattach during the treatment period, the silicone oil should be tamponaded again for treatment. Unfortunately, in many clinical cases, this results in the enucleation of the eyeball and an eventual loss of vision in the patients. Thus, preserving the original structure and appearance of the eyeball are important considerations in the treatment of severe retinal detachment.<sup>8,9</sup>

Vitreous substitution is deemed a highly challenging and interesting research topic in ophthalmology. The foldable capsular vitreous body (FCVB)—a novel vitreous substitute—was developed by the State Key Laboratory of Ophthalmology (Zhongshan Ophthalmic Center, Sun Yat-sen University, Guangzhou, China). It has been certified as meeting the requirements of the EU Medical Devices Directive 93/42/EEC and has also been officially approved and registered as a Class III medical appliance by the China Food and Drug Administration.

The FCVB contains a vitreous-like capsule, drain tube, and drain valve. After implanting the FCVB in the vitreous cavity, silicone oil is injected into the capsule through the drainage valve, and the capsule is inflated to support the eyeball and to restore intraocular pressure (IOP).<sup>10</sup> The FCVB is made from a Food and Drug Administration-registered, nontoxic, medical grade silicone rubber with good biocompatibility and stability.<sup>11</sup> The capsule shape is determined by computer simulation of the human and rabbit vitreous cavities.

FCVB implantation is primarily used to treat severe retinal detachment, and it can stay in the eyeball for a long time without obvious complications. It can completely cut off direct contact between the silicone oil and eye tissues, avoid silicone oil emulsification and migration,<sup>12</sup> reduce damage to the function of the ciliary body, and provide 360° full-filled support retina. The FCVB also allows control of the eye pressure by increasing or decreasing silicone oil injection through the drainage valve during or after surgery.<sup>10,12,13</sup> Gao et al.<sup>14</sup> reported that the FCVB is morphologically similar to the natural vitreous body and can physiologically help the recovery of vitreous body functions in animal models.<sup>15–19</sup> In a pilot study, 11 cases of FCVB filled BSS that was found leaking in three cases, the authors concluded that silicone oil (SO) is much more inert and preservative than BSS within the FCVB.<sup>12,13</sup> Thereafter, in later studies all cases were injected with SO. So far there are few studies conducted with FCVB for treatment of severe retinal detachment in human eyes with very small cases.<sup>13,20,21</sup> Therefore, to date the current clinical evidence of safety and efficacy of FCVB injected with SO is inadequate.

The purpose of this study was to evaluate the clinical effectiveness and safety of FCVB implantation for severe retinal detachment by dynamically monitoring the changes of the indicators, which is different from previous case reports, and with large number of clinical cases.

## Methods

This study protocol was reviewed and approved by the Medical Ethics Committee of the Shenzhen Eye Hospital. In addition, each patient and their family was informed of the implantation risks before the operation and provided informed consent.

The inclusion criteria were as follows: (1) patients aged 18 to 65 years; (2) treated eye vision <0.05; (3) without a lens; (4) ocular axial length between 16 and 28 mm; and (5) severe retinal detachment that could not be treated by current vitreous substitutes. The latter criterion included the following: (a) severe unilateral ocular perforating injuries or compounded retinal or choroidal detachments resulting from retinal rupture or retinal choroidal hemorrhage; (b) retinal or choroidal defects resulting from severe unilateral ocular rupture injuries; (c) giant posterior scleral rupture injuries that could not be repaired; (d) silicone oil could not be removed for a long time with incomplete retinal reattachment; and (e) the patient had undergone retinal detachment surgery and silicone oil tamponade two or more times, although the retina re-detached after silicone oil removal.

The exclusion criteria were as follows: (1) patients allergic to silicone rubber or scar diathesis; (2) enophthalmia; (3) uveitis; (4) other uncontrollable eye diseases; (5) proliferative diabetic retinopathy; (6) the lens of the target eye was transparent; (7) serious heart, lung, liver, or kidney dysfunction; (8) pregnancy or breast-feeding females; and (9) drug abuse or alcoholism.

A retrospective evaluation was performed for 27 patients who underwent PPV and FCVB implantation at the Shenzhen Eye Hospital from July 2018 to August 2019. The FCVB was manufactured by Guangzhou Vesber Co. Ltd., and silicone oil was obtained from Bausch and Lomb (Rochester, NY, USA). Patient medical records were reviewed, and their sex, age, ophthalmic history, FCVB implantation period, follow-up period (beginning from the time of FCVB implantation to the last visit), preoperative and postoperative visual acuity (VA), postoperative IOP, and retinal reattachment results were recorded (Table 1).

**Table 1.** General Information and Eye Diagnosis Information of Patients

Patient	Sex	Age	Eye	Main Diagnosis	Other Ophthalmological Diagnosis	Operation History Before FCVB Implantation	Implant Stage (I/II)	Follow-Up Time (Mo)	Initial VA	Final VA	Final Operative Eye IOP (mm Hg)	Final Central Eye IOP (mm Hg)	Surgical Success (Yes/No)	Retinal Reattachment (Yes/No)
1	Male	33	OS	Eyeball rupture	1. Silicon oil tamponade 2. Lack of lens 3. Retina defect	1. Lacerated scleral suture 2. Lensectomy 3. Vitrectomy 4. Silicone oil tamponade	II	12	HM	LP	23.4	16.2	Yes	Yes
2	Male	43	OS	Eyeball rupture	1. Traumatic cataract 2. Retinal detachment 3. Hemorrhagic choroid detachment 4. Vitreous hemorrhage	Lacerated corneal suture	I	6	LP	NLP	15	17.2	Yes	Yes
3	Male	39	OS	Perforating eye injury	1. Vitreous hemorrhage 2. Traumatic cataract 3. Retinal detachment 4. hemorrhagic choroid detachment	Lacerated corneal suture	I	12	LP	LP	8.4	12.6	Yes	Yes
4	Male	37	OS	Perforating eye injury	1. Silicon oil tamponade 2. Lack of lens 3. Retinal choroidal hemorrhage 4. Retinal or choroidal Detachments	1. Lacerated corneal suture 2. Lensectomy 3. Vitrectomy 4. Silicone oil tamponade	II	12	CF	NLP	28.9	13	Yes	Yes
5	Male	66	OD	Recurrent retinal detachment	1. Retinal detachment 2. Silicon oil tamponade 3. Lack of lens 4. High myopia 5. Macular hole	1. Lensectomy 2. Vitrectomy 3. Silicone oil tamponade	II	12	HM	LP	5.2	15	Yes	Yes
6	Male	37	OS	Eyeball rupture	1. Traumatic cataract 2. Vitreous hemorrhage 3. Retinal detachment 4. Retina defect	Lacerated scleral suture	I	6	LP	NLP	7.8	11	Yes	Yes
7	Male	50	OS	Eyeball rupture	1. Traumatic glaucoma 2. Silicon oil tamponade 3. Lack of lens 4. Retinal defect	1. Lacerated corneal and scleral suture 2. Lensectomy 3. Vitrectomy 4. Silicone oil tamponade 5. Removed of intraocular Foreign body	II	24	LP	HM	18.3	15	Yes	Yes
8	Male	31	OS	Perforating eye injury	1. Retinal detachment 2. Silicon oil tamponade 3. Lack of lens	1. Lacerated corneal suture 2. Lensectomy 3. Vitrectomy 4. Silicone oil tamponade	II	6	CF	NLP	8.6	10	Yes	Yes
9	Male	26	OD	Penetrating eye injury	1. Vitreous hemorrhage 2. Retinal detachment	Lacerated corneal and Scleral suture	I	6	NLP	NLP	6	17.1	Yes	Yes

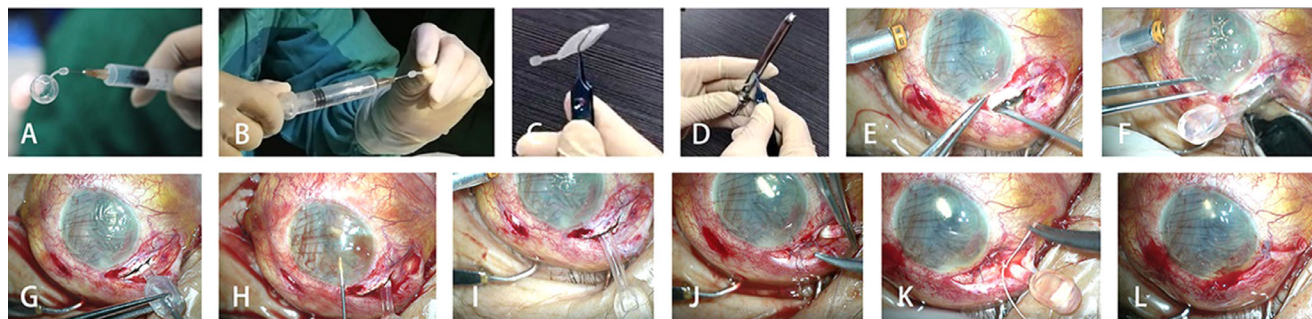
Table 1. Continued

Patient	Sex	Age	Eye	Main Diagnosis	Other Ophthalmological Diagnosis	Operation History Before FCVB Implantation	Implant Stage (I/II)	Follow-Up Time (Mo)	Initial VA	Final VA	Final Operative Eye IOP (mm Hg)	Final Contralateral Eye IOP (mm Hg)	Surgical Success (Yes/No)	Retinal Reattachment (Yes/No)
10	Male	24	OD	Perforating eye injury	1. Retinal detachment 2. Silicon oil tamponade 3. Lack of lens	1. Lacerated scleral suture 2. Lensectomy 3. Vitrectomy 4. Silicone oil tamponade 5. Removed of intraocular foreign body	II	6	0.1	LP	6	14	Yes	Yes
11	Male	50	OS	Eyeball rupture	1. Retinal defect 2. Silicon oil tamponade 3. Lack of lens	1. Lacerated sclera suture 2. Lensectomy 3. Vitrectomy 4. Silicone oil tamponade 5. Ciliary suture Lacerated scleral and scleral suture	II	6	LP	NLP	14.5	17	Yes	Yes
12	Male	24	OD	Eyeball rupture	1. Vitreous hemorrhage 2. Traumatic cataract 3. Retinal detachment 4. Hemorrhagic choroid detachment		I	6	NLP	NLP	7	17	Yes	Yes
13	Male	45	OS	Ocular blunt trauma	1. Retinal defect 2. Silicon oil tamponade 3. Lack of lens	1. Lensectomy 2. Vitrectomy 3. Silicone oil tamponade	II	12	NLP	NLP	4.2	15.8	Yes	Yes
14	Male	37	OS	Perforating eye injury	1. Retinal defect 2. Silicon oil tamponade 3. Lack of lens	1. Lacerated corneal suture 2. Lensectomy 3. Vitrectomy 4. Silicone oil tamponade removed from intraocular foreign body	II	12	HM	HM	10.9	11.8	Yes	Yes
15	Male	55	OD	Eyeball rupture	1. Retinal detachment 2. Silicon oil tamponade 3. Lack of lens	1. Lacerated corneal suture 2. Lensectomy 3. Vitrectomy silicone oil tamponade	II	12	HM	HM	6.1	15.2	Yes	Yes
16	Male	46	OS	Eyeball rupture	1. Retinal detachment 2. Silicon oil tamponade 3. Lack of lens	1. Lacerated scleral suture 2. Lensectomy 3. Vitrectomy	II	12	NLP	NLP	9.3	17	Yes	Yes
17	Male	21	OD	Penetrating eye injury	1. Retinal detachment 2. Lack of lens	1. Lacerated corneal and scleral suture 2. Lensectomy 3. Vitrectomy silicone oil tamponade	II	12	LP	HM	6.9	16	Yes	Yes
18	Male	29	OD	Eyeball rupture	1. Vitreous hemorrhage 2. Retinal detachment 3. Hemorrhagic choroid Detachment	Lacerated corneal and Scleral suture	II	12	NLP	NLP	18	16	Yes	Yes

Table 1. Continued

Patient	Sex	Age	Eye	Main Diagnosis	Other Ophthalmological Diagnosis	Operation History Before FCVB Implantation	Implant Stage (I/II)	Follow-Up Time (Mo)	Initial VA	Final VA	Final Operative Eye IOP (mm Hg)	Final Contralateral Eye IOP (mm Hg)	Surgical Success (Yes/No)	Retinal Reattachment (Yes/No)
19	Male	53	OD	Eyeball rupture	1. Vitreous hemorrhage 2. Retinal detachment 3. Hemorrhagic choroid detachment 4. Traumatic cataract	Lacerated corneal and sclera suture	I	12	LP	LP	6.4	15	Yes	Yes
20	Male	45	OS	Perforating eye injury	1. Retinal detachment 2. Silicon oil tamponade 3. Lack of lens	1. Lacerated corneal and sclera suture 2. Lensectomy 3. Vitrectomy silicone oil tamponade	II	12	CF	HM	6.4	21	Yes	Yes
21	Male	33	OS	Eyeball rupture	1. Retinal detachment 2. Silicon oil tamponade 3. Lack of lens	1. Lacerated scleral suture 2. Lensectomy 3. Vitrectomy 4. Silicone oil tamponade	II	12	NLP	NLP	10.2	16.7	Yes	Yes
22	Female	46	OD	Eyeball rupture	1. Retinal detachment 2. Silicon oil tamponade 3. Lack of lens 4. Retinal and choroidal defect	1. Lacerated corneal and sclera suture 2. Lensectomy 3. Vitrectomy silicone oil tamponade	II	12	LP	NLP	5.2	16	Yes	No
23	Male	29	OD	Eyeball rupture	1. Retinal detachment 2. Silicon oil tamponade 3. Lack of lens 4. Retinal and choroidal defect	1. Lensectomy 2. Vitrectomy silicone oil tamponade	II	12	LP	NLP	5.5	15	Yes	Yes
24	Male	53	OD	Eyeball rupture	1. Retinal detachment 2. Silicon oil tamponade 3. Lack of lens	1. Lensectomy 2. Vitrectomy silicone oil tamponade	II	12	LP	NLP	8	15.6	Yes	No
25	Male	31	OS	Eyeball rupture	1. Retinal detachment 2. Silicon oil tamponade 3. Lack of lens 4. Retinal and choroidal defect	1. Lacerated sclera suture 2. Lensectomy 3. Vitrectomy 4. Silicone oil tamponade	II	12	LP	NLP	5.4	21	Yes	Yes
26	Male	69	OS	Perforating eye injury	1. Retinal detachment 2. Silicon oil tamponade 3. Lack of lens 4. Choroidal detachment	1. Lacerated corneal suture 2. Lensectomy 3. Vitrectomy silicone oil tamponade	II	12	NLP	LP	12.8	11	Yes	Yes
27	Male	20	OS	Perforating eye injury	1. Retinal detachment 2. Silicon oil tamponade 3. Lack of lens	1. Lacerated corneal suture 2. Lensectomy 3. Vitrectomy silicone oil tamponade	II	12	HM	HM	8.9	16	Yes	Yes

OD, oculus dexter; OS, oculus sinister; NLP, no light perception; LP, light perception; HM, hand movement.



**Figure 1.** Procedure of FCVB implantation.

**Table 2.** Recommended FCVB Model Selection and Silicone Oil Injection Volume

Model	FCVB		Patients Ocular Axial Length (mm)	Recommended Silicone Oil Injection Volume (mL)
	Anteroposterior Diameter (mm)	Vertical Diameter (mm)		
AV-15	15	20	23–25	3.5–4.0
AV-10P	10	13	16–19.9	0.7–0.9
AV-12P	12	15	20–21.4	1.4–1.7
AV-13.5P	13.5	17.4	21.5–22.9	1.8–2.2
AV-15P	15	19.9	23–24.9	3.5–4.0
AV-17P	17	22	25–28	4.0–5.0

## Surgical Procedure

We performed a 23-gauge (G) PPV and FCVB implantation with silicone oil tamponade, using previously described operating procedures.<sup>20,21</sup> The Animation demonstration of FCVB implantation video is shown in Supplemental Digital Content S1, and the operating procedures are shown in Figure 1 and Supplementary Video S1. The recommended FCVB model selection and silicone oil injection volume are shown in Table 2.

## Follow-up of Patients

Postoperative examinations include assessment of the FCVB position, slit lamp microscopy (Nikon FS-2, Nikon Inc, NY), scanning laser ophthalmoscope (SLO) (OPTOSPLC, Daytona, England), VA through E Standard Logarithm Eyesight, IOP with Goldmann applanation tonometry (CT80A, Topcon, Japan), optical coherence tomography (OCT) (Visante, Carl Zeiss Meditec, Dublin, CA), ultrasound biomicroscopy (UBM) (SW-3200L, Suoer, China), B-scan (HC00504598, Cinescan, France), computed tomography scans (Ingenuity128, Philips, Holland), as well as monitoring the postoperative complications. The primary effectiveness outcome measure was retinal

reattachment after FCVB implantation at the six-month follow-up at the latest. The secondary effectiveness outcome measures were VA and IOP, and the safety outcome was postoperative complications.

## Statistical Analyses

A descriptive analysis was performed; furthermore, the frequencies and composition ratio of qualitative parameters, and means and standard deviations (SDs) of the quantitative parameters were calculated using SPSS 15.0 (SPSS Inc., Chicago, IL, USA). Security analysis was conducted by counting and analyzing the adverse events. IOP and VA were presented as means  $\pm$  SDs; the paired sample *t*-test was used to compare IOP or VA values, and the Wilcoxon signed-rank test was used to compare the corneal transparency between the baseline and 6 or 12 months of follow-up. A two-sided *P* value  $< 0.05$  was defined as statistically significant.

## Results

Overall, 23G PPV and FCVB implantation were performed on 27 patients (16 left eyes and 11 right eyes) at Shenzhen Eye Hospital from July 2018 to August 2019. There were 26 males and one female with an

average age of  $39.70 \pm 13.02$  years (range 20–69); 15 patients (55.6%) presented with eyeball rupture; eight (29.6%) experienced perforating eye injury; two had penetrating eye injuries; one presented with recurrent retinal detachment; and one experienced ocular blunt trauma. The mean follow-up period was  $10.44 \pm 2.68$  months (range 6–24). The turn-up rate at the follow-up visits was 100% (27 patients) for the one-, two-, and six-month visits and 74.1% (20 patients) for follow-up beyond 12 months. Six patients (22.2%) received the FCVB implant in the first stage of ocular trauma, and the remaining 21 (77.8%) received implants during the second stage.

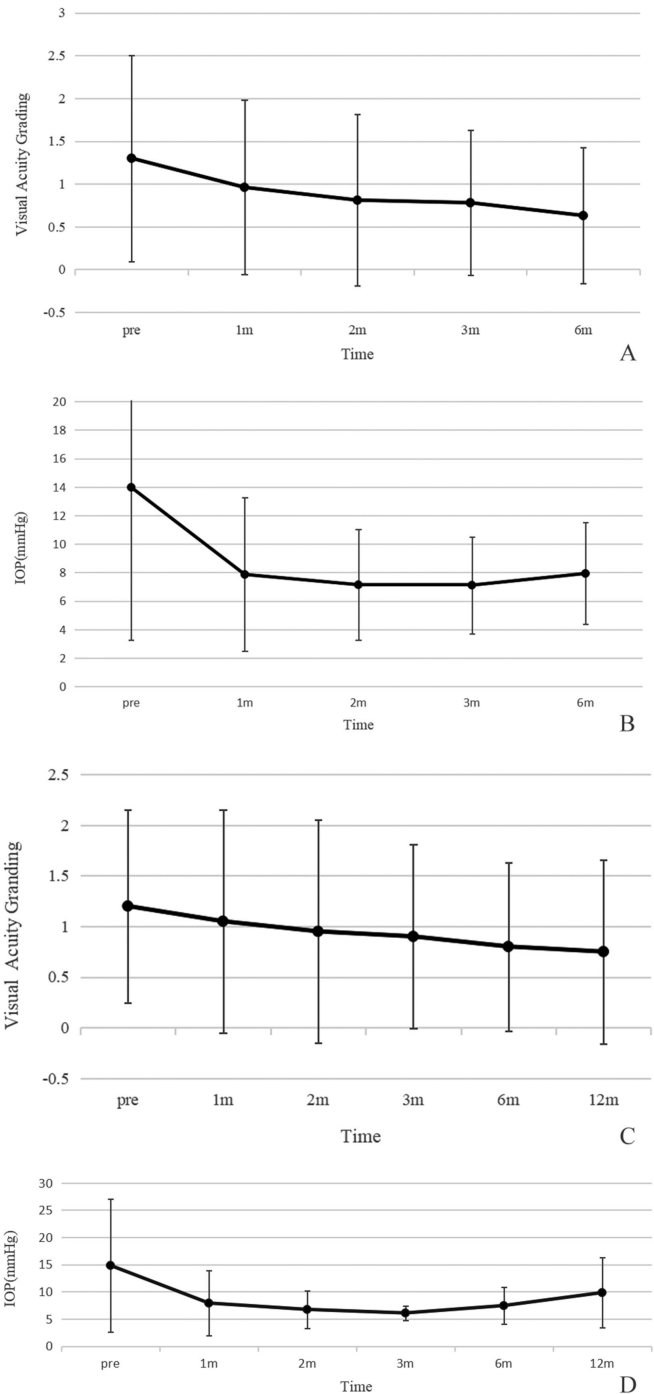
### Effectiveness Analysis of FCVB Implantation

Implantation of the FCVB was accomplished according to standard operating procedures in all patients, with no cases of failure to implant. During follow-up, the FCVB was observed to be properly positioned in the vitreous cavity and providing adequate support to the retina. The retinal reattachment rate was 92.59%, as observed via fundus photography, OCT scans, B-scans, or computed tomography scans.

All 27 patients were followed up for >6 months, and there was a statistically significant difference between preoperative ( $1.30 \pm 1.20$ ) and postoperative ( $0.63 \pm 0.79$ ) visions ( $t = 3.03, P = 0.005$ ) (Fig. 2A). The postoperative IOP ( $7.93 \pm 3.57$  mm Hg) was significantly lower than the preoperative IOP ( $13.98 \pm 10.72$  mm Hg) ( $t = 2.74, P = 0.01$ ) (Fig. 2B). Among the 20 patients who were followed up for >12 months, there was a statistically significant difference between preoperative ( $1.20 \pm 0.95$ ) and postoperative ( $0.75 \pm 0.91$ ) visions ( $t = 1.831, P = 0.005$ ) (Fig. 2C). The postoperative IOP ( $9.85 \pm 6.48$  mm Hg) was lower than the preoperative IOP ( $14.85 \pm 12.17$  mm Hg) ( $t = 1.82, P = 0.01$ )

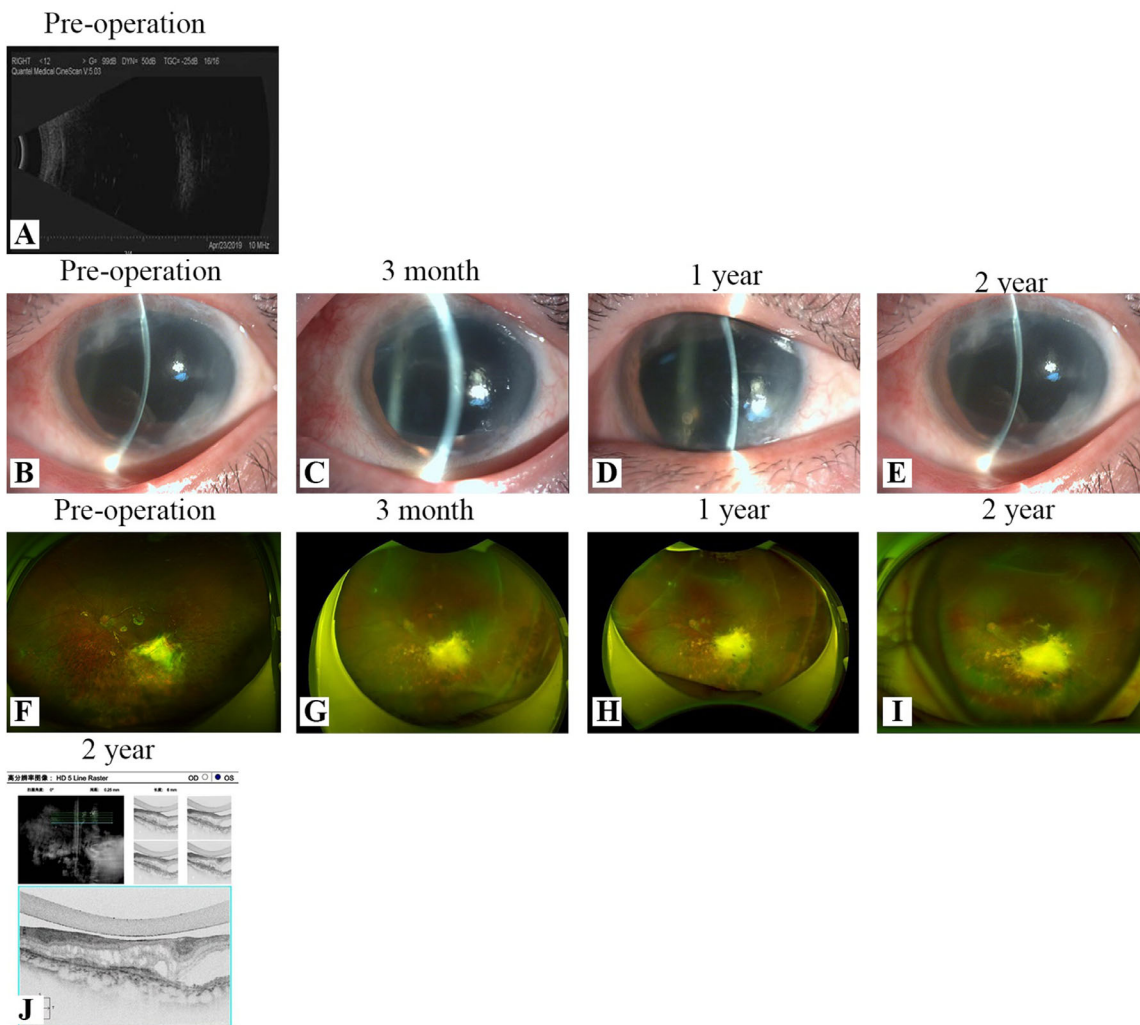
### Safety Analysis of FCVB Implantation

During the follow-up, there were no serious adverse events in any of the operations, such as silicone oil emulsification or immigration, glaucoma, and eyeball atrophy. Of the 27 cases, 14 exhibited corneal opacity without keratopathy, and 13 exhibited a shallow anterior chamber. One of the patients had a balloon break during surgery and a drainage tube exposure after surgery. However, no other severe complications including endophthalmitis, sympathetic ophthalmia and rejection of FCVB associated with FCVB were detected, although 5 patients had mild hemorrhage caused by previous severe ocular damage.



**Figure 2.** Visual acuity grading scores and IOP values of all patients at six- and 12-month follow-up. Visual acuity was graded according to the following system: NLP as 0, LP as 1, HM as 2, FC as 3,  $\geq 0.05$  as 4, and  $\geq 0.1$  as 5. (A–D) The scores showed slight fluctuations.

The Wilcoxon rank-sum test was used to compare two independent samples. The corneal transparency of the normal anterior chamber (mean rank 20.04) was significantly higher than that of the shallow anterior chamber (mean rank 7.50,  $\chi^2 = 22.42, P = 0.00$ ).



**Figure 3.** Postoperative follow-up results of FCVB implantation in patient 07. (A) Preoperative B-ultrasound scan. (B) Preoperative anterior segment. (C) Anterior segment three months after operation. (D) Anterior segment one year after operation. (E) Anterior segment two years after operation. (F) Preoperative SLO. (G) SLO three months after operation. (H) SLO one year after operation. (I) SLO two years after operation. (J) OCT two years after operation.

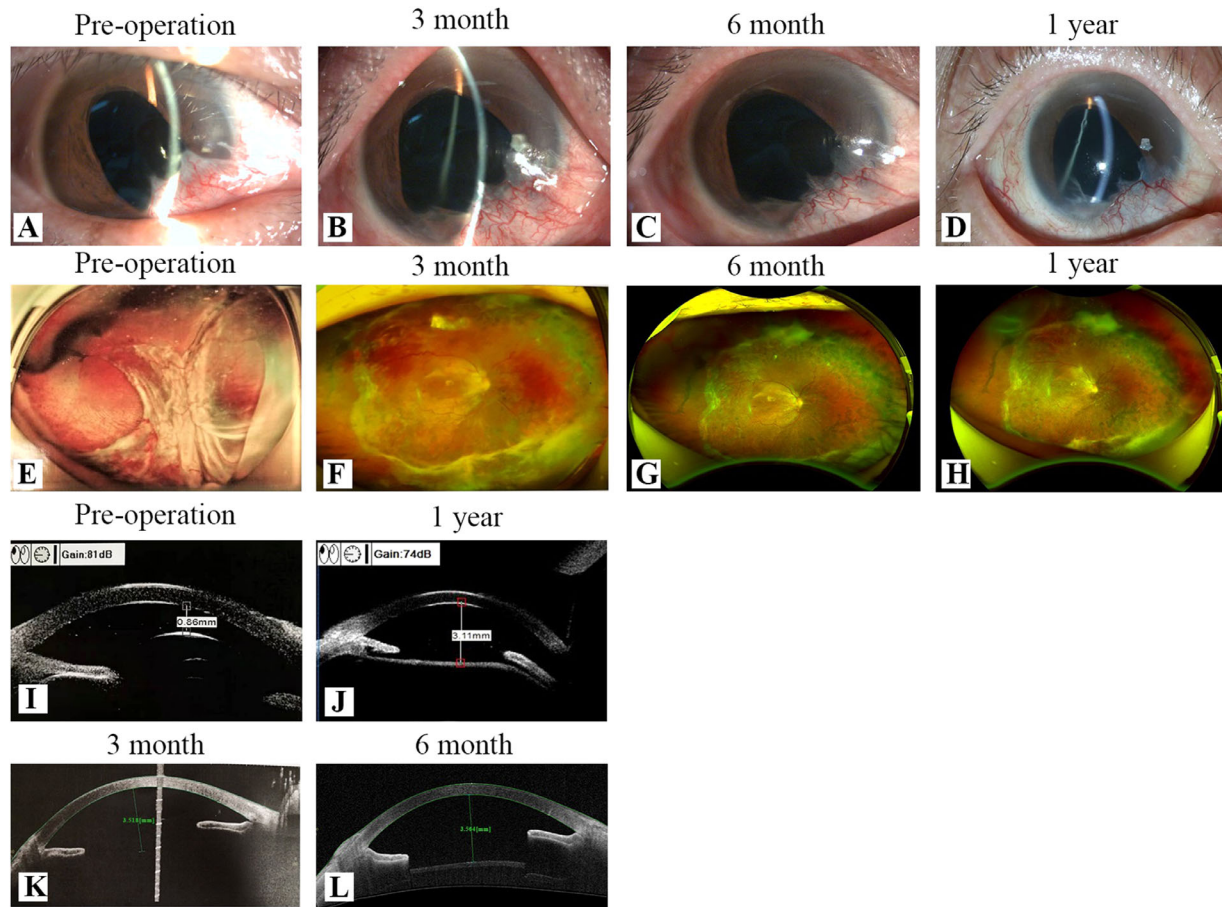
We selected patient 07 (2 years follow-up) and two other randomly selected patients (15 and 17) with one-year follow-ups as follows:

### Representative Case 1: Patient 07, Follow-up for 2 Years

Patient 7 (50 years old, male) had a left eyeball rupture after being injured by a rock. He underwent PPV and silicone oil tamponade and exhibited compounded retinal detachments and silicone oil dependence five months after the procedure, and had no lens. The oculus dexter vision (VOD) was light perception (LP), and the IOP was 18.3 mm

Hg. Thus we first removed the silicone oil and then performed an FCVB implantation. The VOD was hand motion/(HM), and the IOP was 15 mm Hg at the two-year follow-up. The preoperative B-ultrasound scan shows strong dot-like echoes can be seen scattered in the vitreous cavity, indicating the fill state of silicone oil (Fig. 3A), and the preoperative SLO showed silicone oil tamponading in the vitreous cavity, posterior retinal and choroidal defects, and scars (Fig. 3F). Preoperative corneal edema, peripheral corneal opacity with neovascular ingrowth (Fig. 3B). Anterior segment imaging showed that the anterior chamber depth was good, the cornea was transparent, and no inflammation had occurred in two years of surgery (Figs. 3C–E). The two-year follow-up OCT showed the retina is flat





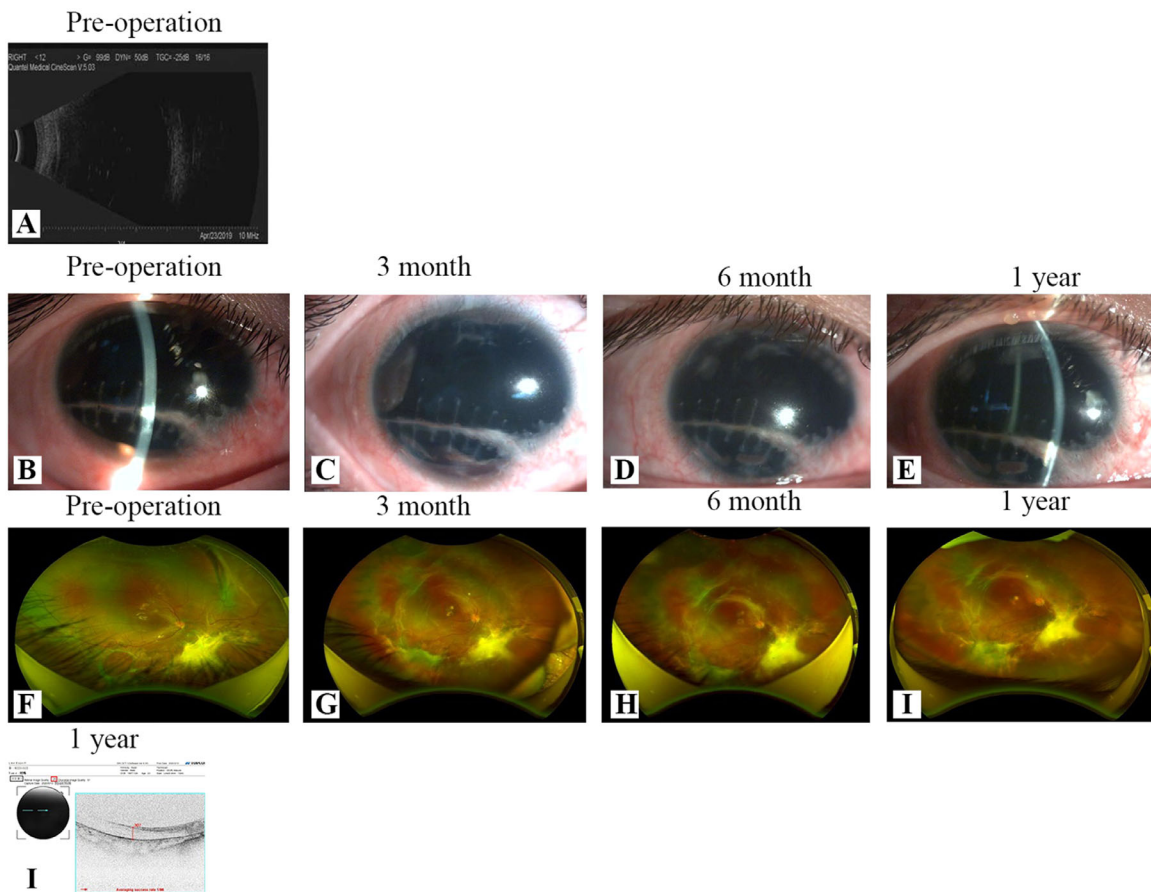
**Figure 4.** Postoperative follow-up results of FCVB implantation in patient 15. (A) Preoperative anterior segment. (B) Anterior segment three months after operation. (C) Anterior segment six months after operation. (D) Anterior segment six months after operation. (E) Preoperative SLO. (F) SLO three months after operation. (G) SLO six months after operation. (H) SLO one year after operation. (I) Preoperative UBM. (J) UBM one year after operation. (K) Anterior chamber OCT three months after operation. (L) Anterior chamber OCT six months after operation.

and there is a gap between the balloon interface and the retina (Fig. 3J), and the two-year follow-up SLO showed that the fundus can be observed more clearly, the retina is flat faced, and there is no visible scar on the inferotemporal aspect of the macular area, which shows no obvious folds (Figs. 3G–I). Represents that FCVB surgery is successful and effective in resetting the retina.

### Representative Case 2: Patient 15, Follow-up for 1 Year

Patient 15 (55 years old, male) had a right eyeball rupture after being injured by a reinforcing bar, and underwent PPV and silicone oil tamponade. The silicone oil moved into the subretinal space with extensive retinal damage and retinal detachment five months

after the procedure. The VOD was HM, and the IOP was 6.1 mm Hg. Thus we first removed the silicone oil and then implanted the FCVB. The Vod was LP and the IOP was 15.2 mmHg at the 1-year follow-up. Anterior segment imaging showed that during the follow-up, the anterior chamber depth was good, the cornea was transparent, and no inflammation had occurred (Figs. 4A–D). Preoperative SLO showed silicone oil tamponading in the vitreous cavity and retinal detachment; during the follow-ups, the FCVB was found to be properly positioned, and the retina was smooth (Figs. 4E–H). The preoperative UBM showed that the anterior chamber was shallow with some silicone oil; the one-year UBM showed that the anterior chamber depth was good, and the FCVB was supporting the retina well without crushing it (Figs. 4I–J). The distance between the corneal endothelium and FCVB was elevated from 3.518 mm (three-month



**Figure 5.** Postoperative follow-up results of FCVB implantation in patient 17. (A) Preoperative B-ultrasound scan. (B) Preoperative anterior segment. (C) Anterior segment three months after operation. (D) Anterior segment six months after operation. (E) Anterior segment one year after operation. (F) Preoperative SLO. (G) SLO three months after operation. (H) SLO six months after operation. (I) SLO one year after operation. (J) OCT one year after operation.

follow-up) to 3.564 mm (six-month follow-up), as observed through an anterior segment OCT (Figs. 4K–L).

### Representative Case 3: Patient 17, Follow-up for One Year

Patient 17 (21 years old, male) had a right eyeball perforating injury with retinal and choroidal defects, silicone oil-dependence. The VOD was LP, and the IOP was 6.9 mm Hg. Thus, we first removed the silicone oil and then performed FCVB implantation. The VOD was HM and the IOP was 16 mm Hg at the one-year follow-up. The preoperative B-ultrasound and SLO showed silicone oil tamponading in the vitreous cavity, posterior retinal and choroidal defects, and scars (Figs. 5A, F). During the follow-up, anterior segment imaging showed that the anterior chamber depth was good, the cornea was transparent, and no inflamma-

tion had occurred (Figs. 5B–E). The SLO showed that the retina was smooth, the FCVB was properly positioned, and the scar was stable (Figs. 5F–I). The OCT at the one-year follow-up showed that the FCVB was supporting the retina well without crushing it, and a flat retina.

### Discussion

At present, silicone oil is mainly used as a vitreous substitute for clinical treatment of retinal detachment, which relies on surface tension to support the retina. This can easily cause complications such as cataracts, keratopathy, silicone oil emulsification or migration, and glaucoma. The silicone oil emulsification rate has been reported to reach 11% in 3 months and 100% in one year.<sup>22,23</sup> On average, after three to six months of silicone oil tamponade, longer contact

between the silicone oil and eye tissues pose a greater risk of complications, which may ultimately trigger silicone oil-dependent eyeball enucleation.

The current study involved the evaluation of 27 patients with severe retinal detachment who underwent a 23G PPV combined with FCVB implantation and silicone oil tamponade from July 2018 to August 2019. The FCVB was designed to support the retina in combination with silicone oil injection. When injected through the drain tube without leakage, silicone oil can closely fit the inner structure of the eyeball and avoid direct contact with the retina.

Our preliminary results suggest that FCVB implantation combined with silicone oil tamponade is effective and safe to provide support to the retina, resulting in a high reattachment rate in the treatment of patients with severe retinal detachment. This result is similar to the findings from Lin<sup>13,20</sup> and Zhang.<sup>21</sup>

In this study, the final reattachment rate was 92.59%, which differs from Lin<sup>20</sup> and Zhang.<sup>21</sup> Lin<sup>20</sup> observed 100% reattachment after 12 months in three patients with severe retinal detachment. And Zhang<sup>21</sup> observed 100% reattachment after six months in 20 patients. The underlying reason is possibly due to the low initial visual acuity of our patients in which most eyes were with rupture injuries or perforating injuries.

The initial VA of all the patients was  $<0.05$  due to severe ocular trauma. Severe ocular trauma may destroy the natural eye physical structure and oxygen metabolism in the eye, following which vision either may be maintained or may decrease.<sup>24</sup> As shown in Table 1, the final VA scores were either maintained or slightly lower than the initial VA scores. However, in some cases in which the visual organs were not damaged, the poor preoperative vision VA improved after FCVB implantation. The above findings are completely different from Lin et al.<sup>20</sup> and Zhang et al.<sup>21</sup> Lin et al.<sup>20</sup> observed that visual acuity significantly improved after surgery. Although Zhang et al.<sup>21</sup> reported no significant differences before and after surgery. We speculate that the reasons may be as follows: First, only one of the cases included in this study was a silicone oil dependent eye, and the others were all patients with severe ocular trauma; Second, the observation time was longer in this study and the number of cases was larger. For that reason when talking with the patient before surgery, it is necessary to explain to the patient that FCVB surgery do not improve vision and may even evolved NLP, which will be conducive to reducing conflicts between doctors and patients.

The result of postoperative IOP was lower than preoperative one, and also lower than contralateral eye. However, the postoperative IOP was slightly higher at

one year than six months. In comparison, Lin et al.<sup>20</sup> and Zhang et al.<sup>21</sup> reported that the postoperative mean IOP was higher than preoperative ones. We speculate the following possible reasons for our low IOP: On the one hand, when ciliary body function is impaired because of severe ocular trauma or other factors, the secretion of aqueous humor is decreased, triggering a relatively low IOP. On the other hand, most of the patients in this study underwent multiple surgeries operating at the ciliary pars plana, which similarly caused variable damage to the ciliary body, followed by reduced aqueous humor secretion and lower intraocular pressure. Second, FCVB mainly exerts a supporting effect on the ocular wall, and perhaps scleral pressure can better reflect the filling status of the eyeball by FCVB. These are the potential reasons why the 27 eyes examined in our study exhibited lower IOP than the contralateral eyes and preoperative.

In five cases, postoperative bleeding occurred in early surgical patients. We suggest that this may be associated with the position of the scleral incision. The scleral incision is displaced by 1 mm compared with the previous approach, and electrocoagulation is performed in a more timely manner, completely relieving the vitreoretinal traction. In addition, after air-fluid exchange, the FCVB is implanted in the vitreous cavity. Intraoperative balloon rupture was observed in one patient, probably due to poking by a sharp instrument, but with less silicone oil leakage, so artificial vitreous balloon replacement was not performed, suggesting that round headed artificial lens implantation forceps should be selected for retrieval of artificial vitreous balloon and intraocular manipulation should be done with caution. This patient had drainage tube exposure and conjunctival flap cloaking half a year after surgery, suggesting that silicone tubing outside the sclera should be sutured in layers with the fascia conjunctiva with the end fixed as close to the fascial sac as possible. The patient recovered well postoperatively, and no further episodes of silicone oil leakage and drain valve exposure occurred. There were 14 patients with postoperative corneal opacity and 13 patients with postoperative anterior chamber shallowing, and we found that corneal transparency was significantly correlated with anterior chamber depth, which was also a problem that should be focused on patient interpretation when we talk preoperatively, and pay close attention to anterior chamber depth during postoperative follow-up. These changes have greatly modified the occurrence of patient complications such as bleeding and corneal opacity. With the guidance of a computer simulation, the implantation site is chosen 5 mm away from the corneal limbus, which can make the FCVB better fit the retina and reduce the risk of complications.

In addition, the silicone oil injection volume and FCVB model selection are important factors that may cause complications. Excessive silicone oil injection may cause complications such as shallow anterior chamber, high IOP, and corneal opacity; insufficient silicone oil injection may cause complications such as retinal detachment, low IOP, and eyeball atrophy. The recommended FCVB model selection and silicone oil injection volume (Table 2) can be used as a reference. However, due to the complexity of eye conditions and the differences in individual factors (eg, vitreous cavity and eyeball atrophy), surgeons should optimize the selection according to actual patient conditions. Some patients' postoperative complaints mainly white corneas and smaller eyeballs than the contralateral side. For severe cases of injury, which is a possible situation in the postoperative period, so the patients should be communicated in detail before surgery and the suitable cases are selected.

In summary, FCVB combined with silicone oil tamponade was shown to be effective and safe in the treatment of severe retinal detachment during the follow-up period. This treatment method can help avoid eye enucleation and continuously facing the lower body position, support the retina, maintain the shape of the eyeball. However, these results are preliminary, and longer follow-up periods of observation will be observed in our future study.

## Acknowledgments

The authors thank all professionals involved in this study and Guangzhou Vesber Co. Ltd. (Guangzhou, China) for providing FCVB.

Supported by the Shenzhen Healthcare Research Project (SZLY2017027) and The Science and Technology Program of Shenzhen (JCYJ20180228164300106).

Disclosure: **S. Chen**, None; **M. Tian**, None; **L. Zhang**, None; **C. Hu**, None; **K. Liu**, None; **B. Qin**, None; **S. Liu**, None

\* SC and MT contributed equally to this work.

## References

- Green WR, Sebag J. Vitreoretinal Interface. *Retina (Fourth Edition)*. 2006;3:1921–1989.
- Le Goff MM, Bishop PN. Adult vitreous structure and postnatal changes. *Eye*. 2008;22:1214–1222.
- Cibis PA, Becker B, Okun E, Canaan S. The use of liquid silicone in retinal detachment surgery. *Arch Ophthalmol*. 1962;68:590–599.
- Castellarin A, Grigorian R, Bhagat N, et al. Vitrectomy with silicone oil infusion in severe diabetic retinopathy. *Br J Ophthalmol*. 2003;87:318–321.
- Quiram PA, Gonzales CR, Hu W, et al. Outcomes of vitrectomy with inferior retinectomy in patients with recurrent rhegmatogenous retinal detachments and proliferative vitreoretinopathy. *Ophthalmology*. 2006;113:2041–2047.
- Karel I, Michalickova M. Pars plana vitrectomy in the pediatric population: indications and long-term results. *Eur J Ophthalmol*. 1999;9:231–237.
- Federman JL, Schubert HD. Complications associated with the use of silicone oil in 150 eyes after retina-vitreous surgery. *Ophthalmology*. 1988;95:870–876.
- Colthurst MJ, Williams RL, Hiscott PS, et al. Biomaterials used in the posterior segment of the eye. *Biomaterials*. 2000;21:649–665.
- Soman N, Banerjee R. Artificial vitreous replacements. *Biomed Mater Eng*. 2003;13:59–74.
- Gao Q, Mou S, Ge J, et al. A new strategy to replace the natural vitreous by a novel capsular artificial vitreous body with pressure control valve. *Eye*. 2008;22:461–468.
- Liu Y, Jiang Z, Gao Q, et al. Technical standards of foldable capsular vitreous body regarding mechanical, optical and biocompatible properties. *Artif Organs*. 2010;34:836–845.
- Lin X, Ge J, Gao Q, et al. Evaluation of the flexibility, efficacy, and safety of a foldable capsular vitreous body in the treatment of severe retinal detachment. *Invest Ophthalmol Vis Sci*. 2011;52:374–381.
- Lin X, Wang Z, Jiang Z, et al. Preliminary efficacy and safety of a silicone oil-filled foldable capsular vitreous body in the treatment of severe retinal detachment. *Retina*. 2012;32:729–741.
- Gao Q, Chen X, Ge J, et al. Refractive shifts in four selected artificial vitreous substitutes based on Gullstrand-Emsley and Liou-Brennan schematic eyes. *Invest Ophthalmol Vis Sci*. 2009;50:3529–3534.
- Chen J, Gao Q, Liu Y, et al. Clinical device-related article evaluation of morphology and functions of a foldable capsular vitreous body in the rabbit eye. *J Biomed Mater Res B Appl Biomater*. 2011;97:396–404.
- Wang P, Gao Q, Jiang Z, et al. Biocompatibility and retinal support of a foldable capsular vitreous body injected with saline or silicone oil implanted in rabbit eyes. *Clin Exp Ophthalmol*. 2012;40:e67–e75.

17. Feng S, Chen H, Liu Y, et al. A novel vitreous substitute of using a foldable capsular vitreous body injected with polyvinylalcohol hydrogel. *Sci Rep.* 2013;3:1838.
18. Chen H, Feng S, Liu Y, et al. Functional evaluation of a novel vitreous substitute using polyethylene glycol sols injected into a foldable capsular vitreous body. *J Biomed Mater Res A.* 2013;101:2538–2547.
19. Yang W, Yuan Y, Zong Y, et al. Preliminary study on retinal vascular and oxygen-related changes after long-term silicone oil and foldable capsular vitreous body tamponade. *Sci Rep.* 2014;4:5272.
20. Lin X, Sun X, Wang Z, et al. Three-year efficacy and safety of a silicone oil-filled foldable-capsular-vitreous-body in three cases of severe retinal detachment. *Transl Vis Sci Technol.* 2016;5:2.
21. Zhang X, Tian X, Zhang B, et al. Study on the effectiveness and safety of foldable capsular vitreous body implantation. *BMC Ophthalmol.* 2019;19:260.
22. Toklu Y, Cakmak HB, Ergun SB, et al. Time course of silicone oil emulsification. *Retina.* 2012;32:2039–2044.
23. Ghoraba HH, Zaky AG, Abd Al Fatah HM, et al. Sticky silicone oil. *Retina.* 2017;37:1599–1606.
24. Jani PD, Mwanza JC, Billow KB, et al. Normative values and predictors of retinal oxygen saturation. *Retina.* 2014;34:394–401.