

Ultrasound and Functional Assessment of Transtendinous Repairs of Partial-Thickness Articular-Sided Rotator Cuff Tears

Roger V. Ostrander,^{*†} MD, Jeffrey M. Klauser,[†] MD, Sanjay Menon,[†] MD, and Joshua G. Hackel,[†] MD

Investigation performed at the Andrews Institute, Gulf Breeze, Florida, USA

Background: Partial-thickness articular-sided rotator cuff tears are a frequent source of shoulder pain. Despite conservative measures, some patients continue to be symptomatic and require surgical management. However, there is some controversy as to which surgical approach results in the best outcomes for grade 3 tears.

Hypothesis/Purpose: The purpose of this study was to evaluate repair integrity and the clinical results of patients treated with transtendinous repair of high-grade partial-thickness articular-sided rotator cuff tears. Our hypothesis was that transtendinous repairs would result in reliable healing and acceptable functional outcomes.

Study Design: Case series; Level of evidence, 4.

Methods: Twenty patients with a minimum follow-up of 2 years were included in the study. All patients underwent arthroscopic repair of high-grade partial-thickness rotator cuff tears utilizing a transtendinous technique by a single surgeon. At latest follow-up, the repair integrity was evaluated using ultrasound imaging, and functional scores were calculated.

Results: Ultrasound evaluation demonstrated that 18 of 20 patients had complete healing with a normal-appearing rotator cuff. Two patients had a minor residual partial tear. Sixteen of 20 patients had no pain on visual analog scale. Four patients complained of mild intermittent residual pain. All patients were rated as “excellent” by both the University of California at Los Angeles Shoulder Score and the Simple Shoulder Test.

Conclusion: The transtendon technique for the repair of articular-sided high-grade partial rotator cuff tears results in reliable tendon healing and excellent functional outcomes.

Keywords: rotator cuff; rotator cuff repair; rotator cuff tear; transtendinous; transtendon; PASTA repair; ultrasound; cuff tear; cuff repair; partial rotator cuff tear

Partial-thickness articular-sided rotator cuff tears are a frequent source of shoulder pain. Despite conservative measures, some patients continue to be symptomatic and require surgical management. The surgical treatment depends on the depth or severity of the tear.

The mean supraspinatus tendon insertion footprint measures approximately 12 to 13 mm.⁶ The Ellman

classification for partial-thickness rotator cuff tears has been used widely in the literature.^{5,16,18,26} Ellman⁸ classified partial tears into 3 grades: grade 1 articular-sided tears involve less than 3 mm of the supraspinatus footprint, grade 2 tears involve between 3 and 6 mm, and grade 3 tears involve more than 6 mm or more than 50% of the tendon insertion.

Operative treatment options for these tears include debridement alone, completion of the tear and repair, or arthroscopic transtendinous repair.¹⁰ Grade 1 and 2 tears are frequently treated with debridement. However, there is some controversy as to which approach results in the best outcomes for grade 3 tears.²³

The goal of transtendinous repair is to improve postoperative function and relieve pain by achieving anatomic rotator cuff healing. Few studies have looked at repair integrity after transtendinous repair. Ultrasound is an inexpensive and noninvasive imaging modality that can quickly and reliably evaluate the presence of rotator cuff tears.⁴

*Address correspondence to Roger V. Ostrander, MD, Andrews Orthopaedic & Sports Medicine Center, 1040 Gulf Breeze Parkway, Suite 200, Gulf Breeze, FL 32561, USA (email: rostrander@andrewsortho.com).

[†]Andrews Research & Education Foundation, Gulf Breeze, Florida, USA.

One or more of the authors has declared the following potential conflict of interest or source of funding: The Andrews Institute receives funding from Arthrex.

Ethical approval for this study was obtained from Baptist Hospital-Pensacola.

To our knowledge, no study to date has evaluated both functional outcomes and repair integrity using ultrasound after transtendinous repair of partial-thickness rotator cuff tears. The purposes of this study were to evaluate the outcomes of arthroscopic transtendinous rotator cuff repairs for high-grade partial-thickness articular-surface supraspinatus tendon avulsions (PASTA repairs) using established functional outcome measures and to evaluate the tendon healing rate using postoperative ultrasound. Our hypothesis was that anatomic arthroscopic transtendinous repair of grade 3 articular-sided partial-thickness rotator cuff tears would result in a high rate of healing, leading to improved pain and function.

METHODS

A query was performed of all operative reports for surgeries performed by a single sports medicine and arthroscopy fellowship trained surgeon (R.V.O.) between January 2007 and June 2010. Twenty patients who had been treated with arthroscopic transtendinous repair of grade 3 (>50% thickness) articular-sided partial-thickness supraspinatus tears agreed to participate in the evaluation.

Patients were initially managed with a minimum of 6 weeks of conservative treatment before surgery was considered. The decision to undergo surgery was made by the patient because of persistent pain and dysfunction that was no longer manageable with nonoperative modalities. Preoperative imaging included standard radiographs and magnetic resonance imaging (MRI) arthrograms.

Additional procedures were performed based on pathology identified preoperatively and at the time of surgery.

All patients were evaluated with a physical examination performed preoperatively and postoperatively by an independent orthopaedic surgeon. A visual analog scale (0-100) was used to assess pain. A questionnaire was administered to determine causes of pain. The Simple Shoulder Test, Constant Score, and University of California at Los Angeles Shoulder Score (UCLA Shoulder Score) were used to assess function. To evaluate the integrity of the rotator cuff repair, an experienced fellowship-trained primary care sports medicine physician, registered in musculoskeletal sonography, performed ultrasound examinations (GE LOGIQ e). Dynamic and static imaging modalities were utilized.

Operative Technique

All procedures were performed under general anesthesia with the patient in the lateral decubitus position. Diagnostic arthroscopy was performed and the rotator cuff footprint was examined from the articular side. The amount of exposed footprint was measured. Our operative indication for transtendinous repair was a grade 3 partial-thickness tear.

A shaver was used to debride the undersurface of the rotator cuff tendon to remove any frayed or diseased tissue. A shaver was also used to prepare the rotator cuff footprint by removing residual soft tissue and abrading the bone to

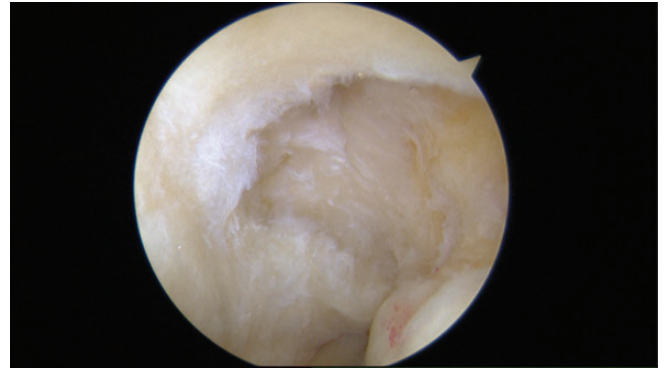


Figure 1. High-grade partial-thickness articular surface supraspinatus tear with exposed footprint.

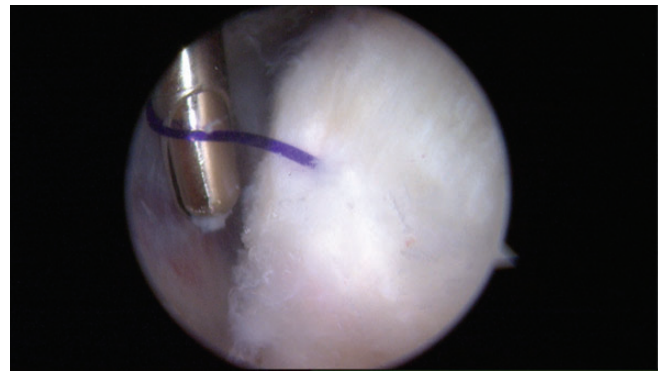


Figure 2. View of the intact bursal-sided rotator cuff fibers. A PDS suture marks the area of concern.

stimulate healing (Figure 1). A spinal needle was then passed percutaneously through the tear and into the glenohumeral joint. A No. 1 PDS (polydioxanone) suture (Ethicon) was then passed through the needle, which enabled us to mark the area of concern on the bursal side.

The arthroscope was directed into the subacromial space. The rotator cuff was inspected to confirm intact bursal-sided fibers (Figure 2). An acromioplasty and bursectomy was performed in all patients.

The arthroscope was placed back into the glenohumeral joint. A spinal needle was placed percutaneously through the rotator cuff at the site of injury and into the joint to help establish the proper location and angle for anchor placement. A stab incision was then made in the skin adjacent to the needle. A small punch was used to start a pilot hole at the articular margin. A double-loaded 5.0-mm Fastin anchor (Mitek) was then passed into the shoulder, twisting through the cuff into the glenohumeral joint. The anchor was screwed into the bone just off the articular margin. One limb of suture was then pulled out through an anterior working portal. The suture was then passed through the rotator cuff anatomically using a spinal needle and a No. 1 PDS, which acted as a suture shuttle. This process was repeated for the remaining sutures (Figure 3). The scope was then placed

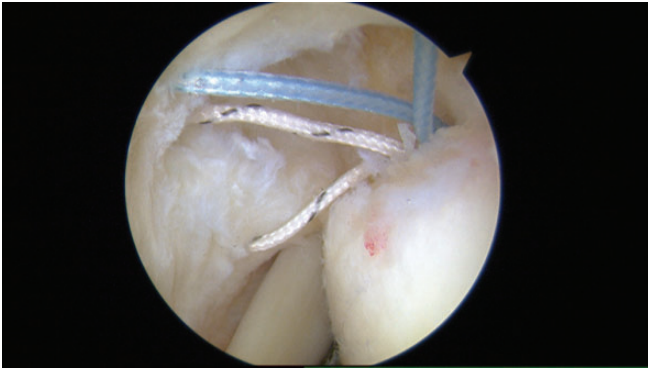


Figure 3. Suture anchor placed at the articular margin. Sutures have been passed through the rotator cuff.

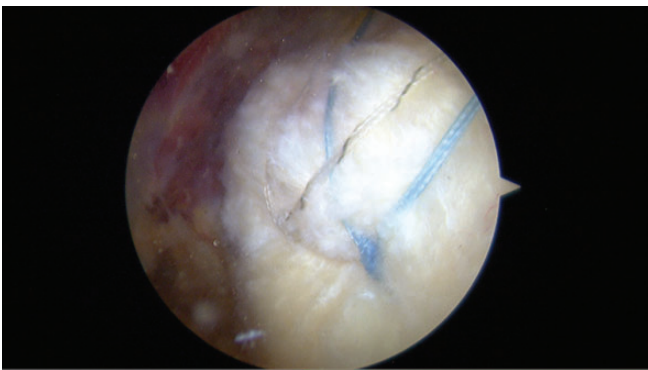

Figure 4. Double-row repair seen from the bursal side.

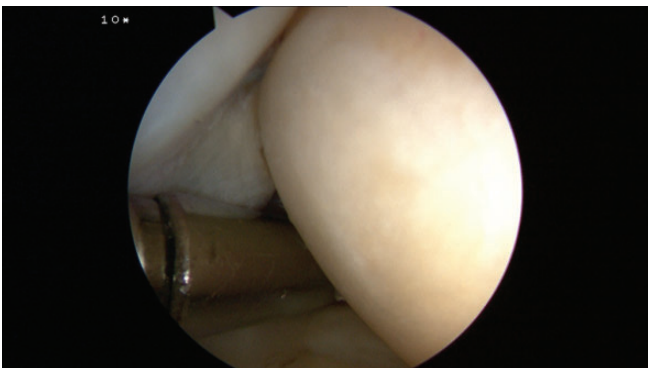


Figure 5. Final repair from the articular side, demonstrating anatomic restoration of the rotator cuff footprint.

back into the subacromial space. Horizontal mattress sutures were tied arthroscopically. One limb from each anchor knot was crossed in suture bridge fashion²⁰ and passed through 2 lateral row anchors (Arthrex 4.75 bio-composite SwiveLocks; Arthrex) to provide a double-row construct, which afforded excellent compression of the tendon to its insertion (Figure 4). The arthroscope was then placed back into the glenohumeral joint to assess the repair from the articular side (Figure 5).

Postoperative Rehabilitation

The patients were all treated according to a standard postoperative protocol. They were placed in a sling for 6 weeks but underwent physical therapy starting immediately postoperatively. Passive range of motion exercises were initiated, with active range of motion exercises beginning at 6 weeks after surgery. Graduated strengthening was then begun with advancement of activity to tolerance.

RESULTS

The mean patient age at the time of surgery was 58.7 years (range, 37-73 years). There were 10 males and 10 females. All preoperative MRIs demonstrated a partial tear of the rotator cuff. In addition, 1 MRI demonstrated an anterior labral tear with Hill-Sachs deformity and 1 MRI demonstrated a medially dislocated biceps tendon. Mean follow-up was 32.7 months (range, 24-70 months). Other procedures performed at the time of surgery included distal clavicle excision (n = 4), biceps tenotomy (n = 1), capsular release (n = 1), and labral repair (n = 1) (Table 1).

Sixteen of 20 patients reported no pain (score = 0) on a visual analog scale. The mean pain level was 4.8 (scale, 0-100). The patients who did report pain described aggravation with heavy lifting or intermittent night pain. There were no confounding diagnoses to explain the pain, although the pain was not significant enough for them to seek treatment. All patients were rated "excellent" by the UCLA Shoulder Score, with a mean score of 33.5 (range, 29-35; scale, 0-35), and "excellent" by the Simple Shoulder Test score, with a mean of 11.5 (range, 9-12; scale, 0-12). The mean Constant score was 86 (range, 75-99; scale, 0-100), with higher scores indicating better outcomes (Table 1).

On follow-up physical examination, all patients had 5 out of a possible 5 for strength and full range of motion when compared with the contralateral extremity.

Eighteen of 20 ultrasounds showed complete healing of the previous partial-thickness rotator cuff tears to the greater tuberosity without any persistent tears (Figure 6). Two shoulders showed small areas of hypoechogenicity consistent with partial undersurface tears of the supraspinatus involving <25% of tendon thickness (Figure 7). No full-thickness tears were identified. Of the 4 patients who reported intermittent pain, 2 had a residual partial tear on ultrasound.

There were no postoperative complications.

DISCUSSION

Our results demonstrate that transtendinous repair of grade 3 partial-thickness articular-sided rotator cuff tendinous avulsions results in a high rate of healing and favorable clinical outcomes. Patient scores were excellent from both a pain and functional standpoint. Our clinical results were similar to previous reports, confirming that this technique is an appropriate option for management of partial-thickness articular-sided tears.^{1-3,7,14,21,22} Duralde and McClelland⁷ reported on the clinical results of arthroscopic

TABLE 1
Demographic Data and Results^a

Patient	Sex	Follow-up, mo	Age, y	Additional Procedures	US Findings	VAS (0-100)	UCLA (0-35)	SST (0-12)	Constant (0-100)
1	M	28.3	65		Repair intact	0	35	12	86
2	F	31.2	68		Repair intact	0	35	12	84
3	F	30.8	53		Repair intact	0	35	11	88
4	M	31.5	63	DCE, biceps tenotomy	Repair intact	0	35	9	92
5	F	43.7	58	Loose body removed	Repair intact	0	33	12	89
6	F	38.2	55		Repair intact	0	35	12	86
7	F	41.5	53		Repair intact	0	35	12	85
8	F	25.0	62		Repair intact	0	33	10	85
9	M	26.6	50	DCE	Repair intact	0	31	12	90
10	M	39.7	56	MUA, capsule release	Repair intact	40	31	12	77
11	M	35.4	73	DCE	Minor partial tear	28	29	11	75
12	M	27.1	66		Repair intact	0	35	12	89
13	F	63.0	37		Minor partial tear	3	33	11	81
14	F	31.0	54		Repair intact	0	35	12	99
15	M	36.5	62		Repair intact	0	35	12	88
16	M	29.4	61		Repair intact	25	29	9	78
17	M	32.4	53	DCE	Repair intact	0	33	12	91
18	F	32.7	71		Repair intact	0	35	12	81
19	M	24.5	54		Repair intact	0	33	12	90
20	F	24.0	60	Labral repair	Repair intact	0	35	12	84
Mean		32.7	58.7			4.8	33.5	11.5	86

^aDCE, distal clavicle extension; F, female; M, male; MUA, manipulation under anesthesia; SST, Simple Shoulder Test; UCLA, University of California at Los Angeles; US, ultrasound; VAS, visual analog scale.

transtendinous rotator cuff repair for grade 3 tears. They determined that an arthroscopic transtendinous technique was a safe and effective treatment yielding reliable improvement in pain and function, with excellent clinical outcomes.⁷ Franceschi et al⁹ performed a randomized controlled trial comparing completion and repair to transtendinous repair and showed both techniques to be safe, effective, and comparable. Although they did not evaluate the healing rate, Castagna et al¹ compared transtendinous repair to completion and repair and found that both techniques resulted in good outcomes in terms of function and pain.

Transtendinous repairs have been shown to be durable. Stuart et al²⁴ evaluated 15 patients who underwent arthroscopic PASTA repairs with a mean follow-up of 13.5 years. Only 1 patient required a revision rotator cuff repair, 8 years after the index procedure, indicating a 93% long-term success rate.²⁴

Woods et al²⁷ looked at outcomes after transtendon repairs for partial articular supraspinatus lesions. At follow-up, they found a high incidence of full-thickness rotator cuff defects after repair. The cause of these failures in this study is unclear. It may be technique dependent or an issue with the postoperative rehabilitation. We did not see any cases in our series, and failure was not a common outcome based on our review of other series in the literature.

In comparison with tear completion and repair, transtendinous repair likely offers more consistent healing rates.^{11,15,21} Shin²¹ determined that arthroscopic transtendinous repair resulted in clinically significant improvements in symptoms while the technique of intentional

completion and repair was associated with a higher incidence of recurrent tear at 6-month follow-up using post-operative MRI. All patients treated with transtendinous repair achieved complete repair integrity.²¹ In the study by Kamath et al,¹⁵ 42 consecutive shoulders were treated with conversion of a partial-thickness rotator cuff tear to a full-thickness tear with subsequent repair. At follow-up, 5 of these were found to have persistent full-thickness tendon defects.¹⁵

When compared with MRI, ultrasound is an inexpensive and quick way to assess rotator cuff integrity and has been used as a reliable tool in numerous other studies after rotator cuff repair.^{4,12,15,17,19} To our knowledge, this is the first study to use ultrasound to evaluate rotator cuff healing after transtendinous repair of partial-thickness rotator cuff tears. Eighteen of 20 ultrasounds showed complete healing of the previous partial-thickness rotator cuff tears to the greater tuberosity. Only 2 ultrasounds showed small areas of residual partial undersurface tearing. No full-thickness tears were identified. This improved repair integrity may be the result of rotator cuff repair at an early stage in rotator cuff disease. Intervening before the severe tendon degeneration and muscle atrophy that accompany larger, full-thickness tears develop may improve healing rates.¹⁵

A transtendinous approach to rotator cuff repair for partial tears has a number of advantages. A distinct benefit is the maintenance of the healthy bursal-sided rotator cuff tissue, unlike the "complete and repair" technique that detaches it, creating a full-thickness tear that ultimately may not heal. The transtendinous technique also ensures an anatomic restoration of the rotator cuff footprint as the tissue is not mobilized or translated during the procedure.

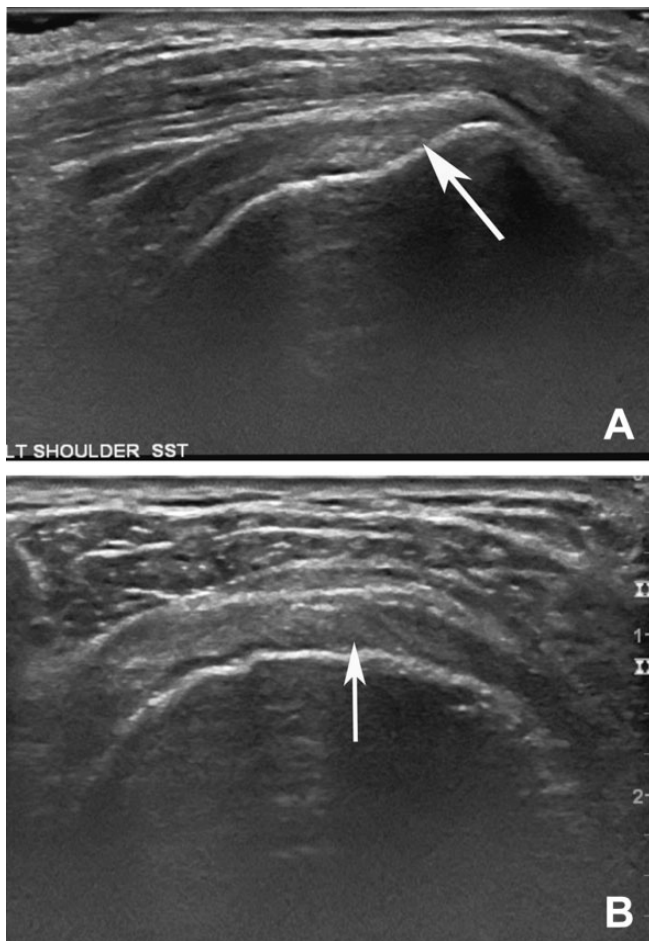


Figure 6. Ultrasound (A) long-axis and (B) short-axis views of an intact healed supraspinatus tendon intact without tear. Arrows indicate location of repair with intact healed rotator cuff tendon.

Sutures can be passed accurately and anatomically while visualizing with the arthroscope in the glenohumeral joint. Maintaining the appropriate length-tension relationship of the rotator cuff musculature may yield more normal functional preservation and lessen the risk of retear seen with completion and repair. Transtendinous repair results in a biomechanically strong construct. In a biomechanical study, Gonzalez-Lomas et al¹³ showed that in situ transtendon repair outperformed tear completion and repair for partial articular-sided supraspinatus tendon tears. The transtendon repair demonstrated significantly less gap formation and significantly higher ultimate failure strength.¹³

One disadvantage is that transtendinous repair can be technically challenging. Gaining access to the rotator cuff footprint for preparation of the bone bed can be difficult, as can passage of the anchors and suture shuttling.²⁵ A stepwise approach simplifies this technique, making it reproducible.

There are some limitations of this study. This retrospective study had no control group, and functional scores were not obtained preoperatively. Additionally, there were concomitant procedures performed in some cases. It is unlikely that

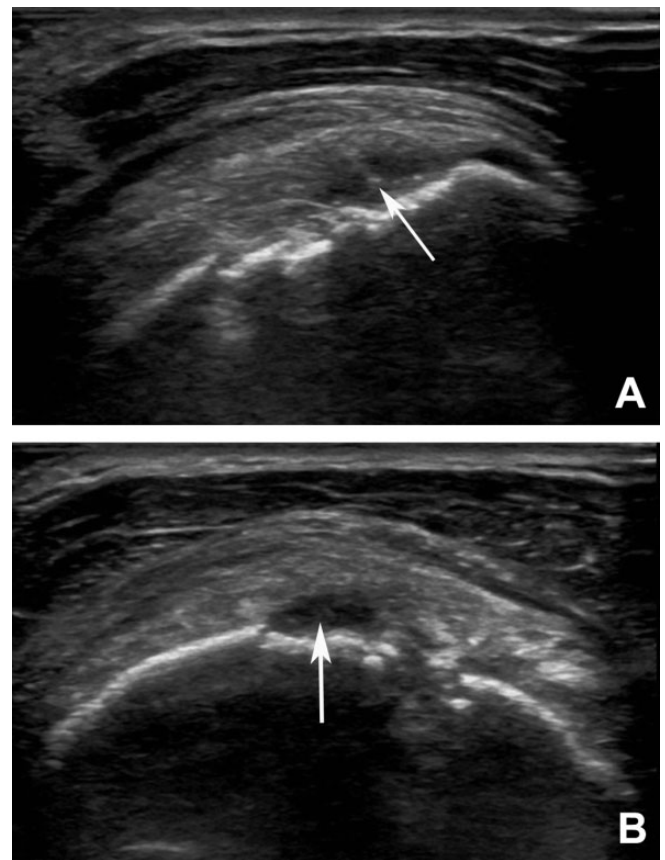


Figure 7. Ultrasound (A) long-axis and (B) short-axis views of an intact supraspinatus tendon with minor residual partial tear. Arrows indicate location of repair with minor residual partial tear.

any of these procedures would have affected the rotator cuff healing rate, but it is possible that some of these concomitant procedures could have adversely affected outcomes, which appears unlikely given the excellent results of the functional scores. The use of ultrasound has been criticized by some for being user dependent. As with any technique, there is a learning curve. Our ultrasound operator has years of extensive experience, making it an accurate, inexpensive, quick, and effective tool for the evaluation of rotator cuff pathology. The lack of preoperative ultrasound and postoperative MRI for comparison is another limitation of the study. Because of the high cost and inconvenience to patients, postoperative MRIs were not obtained because they were not warranted clinically. One goal of the study was to demonstrate the utility of ultrasound for screening postoperative rotator cuff repairs.

CONCLUSION

Transtendinous repair of partial-thickness articular-sided rotator tears results in reliable tendon healing and excellent functional outcomes, yielding long-term patient satisfaction.

REFERENCES

1. Castagna A, Borroni M, Garofalo R, et al. Deep partial rotator cuff tear: transtendon repair or tear completion and repair? A randomized clinical trial. *Knee Surg Sports Traumatol Arthrosc.* 2015;23:460-463.
2. Castagna A, Delle Rose G, Conti M, Snyder SJ, Borroni M, Garofalo R. Predictive factors of subtle residual shoulder symptoms after transtendinous arthroscopic cuff repair: a clinical study. *Am J Sports Med.* 2009;37:103-108.
3. Castricini R, Panfoli N, Nittoli R, Spurio S, Pirani O. Transtendon arthroscopic repair of partial-thickness, articular surface tears of the supraspinatus: results at 2 years. *Chir Organi Mov.* 2009;9(suppl 1): S49-S54.
4. de Jesus JO, Parker L, Frangos AJ, Nazarian LN. Accuracy of MRI, MR arthrography, and ultrasound in the diagnosis of rotator cuff tears: a meta-analysis. *AJR Am J Roentgenol.* 2009;192:1701-1707.
5. Donohue NK, Nickel BT, Grindel SI. High-grade articular, bursal, and intratendinous partial-thickness rotator cuff tears: a retrospective study comparing functional outcomes after completion and repair. *Am J Orthop.* 2016;45:E254-E260.
6. Dugas JR, Campbell DA, Warren RF, Robie BH, Millett PJ. Anatomy and dimensions of rotator cuff insertions. *J Shoulder Elbow Surg.* 2002;11:498-503.
7. Duralde XA, McClelland WB Jr. The clinical results of arthroscopic transtendinous repair of grade III partial articular-sided supraspinatus tendon tears. *Arthroscopy.* 2012;28:160-168.
8. Ellman H. Diagnosis and treatment of incomplete rotator cuff tears. *Clin Orthop Relat Res.* 1990;254:64-74.
9. Franceschi F, Papalia R, Del Buono A, et al. Articular-sided rotator cuff tears: which is the best repair? A three-year prospective randomised controlled trial. *Int Orthop.* 2013;37:1487-1493.
10. Fukuda H. The management of partial-thickness tears of the rotator cuff. *J Bone Joint Surg Br.* 2003;85:3-11.
11. Galatz LM, Ball CM, Teefey SA, Middleton WD, Yamaguchi K. The outcome and repair integrity of completely arthroscopically repaired large and massive rotator cuff tears. *J Bone Joint Surg Am.* 2004;86-A:219-224.
12. Gartsman GM, Drake G, Edwards TB, et al. Ultrasound evaluation of arthroscopic full-thickness supraspinatus rotator cuff repair: single-row versus double-row suture bridge (transosseous equivalent) fixation. Results of a prospective, randomized study. *J Shoulder Elbow Surg.* 2013;22:1480-1487.
13. Gonzalez-Lomas G, Kippe MA, Brown GD, et al. In situ transtendon repair outperforms tear completion and repair for partial articular-sided supraspinatus tendon tears. *J Shoulder Elbow Surg.* 2008;17: 722-728.
14. Ide J, Maeda S, Takagi K. Arthroscopic transtendon repair of partial-thickness articular-side tears of the rotator cuff: anatomical and clinical study. *Am J Sports Med.* 2005;33:1672-1679.
15. Kamath G, Galatz LM, Keener JD, Teefey S, Middleton W, Yamaguchi K. Tendon integrity and functional outcome after arthroscopic repair of high-grade partial-thickness supraspinatus tears. *J Bone Joint Surg Am.* 2009;91:1055-1062.
16. Koh KH, Shon MS, Lim TK, Yoo JC. Clinical and magnetic resonance imaging results of arthroscopic full-layer repair of bursal-side partial-thickness rotator cuff tears. *Am J Sports Med.* 2011;39:1660-1667.
17. Namdari S, Donegan RP, Dahiya N, Galatz LM, Yamaguchi K, Keener JD. Characteristics of small to medium-sized rotator cuff tears with and without disruption of the anterior supraspinatus tendon. *J Shoulder Elbow Surg.* 2014;23:20-27.
18. Ono Y, Woodmass JM, Bois AJ, Boorman RS, Thornton GM, Lo IK. Arthroscopic repair of articular surface partial-thickness rotator cuff tears: transtendon technique versus repair after completion of the tear—a meta-analysis. *Adv Orthop.* 2016;2016:7468054.
19. Park JY, Jung SW, Jeon SH, Cho HW, Choi JH, Oh KS. Arthroscopic repair of large U-shaped rotator cuff tears without margin convergence versus repair of crescent- or L-shaped tears. *Am J Sports Med.* 2014;42:103-111.
20. Park MC, ElAttrache NS, Tibone JE, Ahmad CS, Jun B, Lee TQ. Part I: footprint contact characteristics for a transosseous-equivalent rotator cuff repair technique compared with a double-row repair technique. *J Shoulder Elbow Surg.* 2007;16:461-468.
21. Shin SJ. A comparison of 2 repair techniques for partial-thickness articular-sided rotator cuff tears. *Arthroscopy.* 2012;28:25-33.
22. Spencer EE. Partial-thickness articular surface rotator cuff tears: an all-inside repair technique. *Clin Orthop Relat Res.* 2010;468: 1514-1520.
23. Strauss EJ, Salata MJ, Kercher J, et al. The arthroscopic management of partial-thickness rotator cuff tears: a systematic review of the literature. *Arthroscopy.* 2011;27:568-580.
24. Stuart KD, Karzel RP, Ganjianpour M, Snyder SJ. Long-term outcome for arthroscopic repair of partial articular-sided supraspinatus tendon avulsion. *Arthroscopy.* 2013;29:818-823.
25. Waibl B, Buess E. Partial-thickness articular surface supraspinatus tears: a new transtendon suture technique. *Arthroscopy.* 2005;21: 376-378.
26. Wang Y, Lu L, Lu Z, Xiao L, Kang Y, Wang Z. Arthroscopic transtendinous repair of articular-sided PASTA (partial articular supraspinatus tendon avulsion) injury. *Int J Clin Exp Med.* 2015;8:101-107.
27. Woods TC, Carroll MJ, Nelson AA, et al. Transtendon rotator-cuff repair of partial-thickness articular surface tears can lead to medial rotator-cuff failure. *Open Access J Sports Med.* 2014;5:151-157.