

## A comparative evaluation of dental calcification stages and skeletal maturity indicators in North-Indian children

### ABSTRACT

**Background:** Many researchers have reported relationships between the calcification stages of individual teeth and skeletal maturity. A few studies are available in the literature about Indian populations. In view of this fact, this study was conducted to investigate the relationship between the dental calcification stages and skeletal maturity stages among North-Indian individuals. The objective of this study was to determine whether dental calcification can be used as a first-level diagnostic tool for assessment of skeletal maturity.

**Materials and Methods:** The study participants included (60 males, 60 females) ranging from 7 to 13 years. A total of 120 dental panoramic radiographs and hand-wrist radiographs were obtained and analyzed. Calcification stages of the mandibular dentition (canines, first premolars, second premolars, and second molars) were rated according to the system of Demirjian *et al.* Skeletal maturity indicators stages were determined using the Fishman method.

**Results and Conclusion:** Bivariate correlation ranged from 0.58 to 0.75 for males and 0.73 to 0.84 for females. Canine showed the highest correlation in males and second molar showed the highest correlation in females. Canine calcification Stage H represent prepeak of the pubertal growth spurt in male patients. Calcification Stage G for second molar represents the prepeak and Stage H represents the peak of pubertal growth spurt in females.

**Keywords:** Demirjian method, Fishman method, skeletal maturity indicators, tooth calcification

### INTRODUCTION

The maturational status of an orthodontic patient has a considerable influence on diagnosis, treatment goals, treatment planning, and the eventual outcome of the orthodontic treatment. Assessing maturational status and identification of the period of accelerated growth are essential for clinical decisions regarding growth modulation procedures for skeletal discrepancies, extraction versus nonextraction options, use of extraoral orthopedic forces, and planning for orthognathic surgery for skeletal malocclusions.

The chronologic age may have little or no place in the assessment of the maturational status of a child since it is governed by various factors such as genetic, epigenetic, environmental, nutritional, and hormonal. A more accurate measure to evaluate maturational status is, therefore “biologic age” based on somatic, sexual, dental, and

skeletal maturational assessment.<sup>[1]</sup> The biologic age most closely related to growth has been the “skeletal age” and the hand-wrist film, the most standardized and studied method of skeletal assessment. Assessment of skeletal maturation using hand-wrist radiographs, as an index, based on time and sequence of appearance of carpal bones and certain ossification events have been reported by many investigators.<sup>[2,3]</sup> Ossification at the mid-palatal suture,<sup>[4]</sup> development of the frontal sinus<sup>[5]</sup> has also been used as indicators of skeletal maturation. Fishman<sup>[6]</sup> method has

### VIJAYTA YADAV, ANJU LOOMBA<sup>1</sup>, RAM AUTAR

Department of Orthodontics, Career Dental College and Hospital, <sup>1</sup>Department of Orthodontics, Chandra Dental College and Hospital, Lucknow, Uttar Pradesh, India

**Address for correspondence:** Dr. Vijayta Yadav, Department of Orthodontics, Career Dental College and Hospital, Lucknow - 225 003, Uttar Pradesh, India.  
E-mail: vijayta24@gmail.com

#### Access this article online

**Website:**  
www.njms.in

**DOI:**  
10.4103/njms.NJMS\_55\_16

#### Quick Response Code



This is an open access article distributed under the terms of the Creative Commons Attribution-NonCommercial-ShareAlike 3.0 License, which allows others to remix, tweak, and build upon the work non-commercially, as long as the author is credited and the new creations are licensed under the identical terms.

**For reprints contact:** reprints@medknow.com

**How to cite this article:** Yadav V, Loomba A, Autar R. A comparative evaluation of dental calcification stages and skeletal maturity indicators in North-Indian children. *Natl J Maxillofac Surg* 2017;8:26-33.

been among the most commonly used methods to assess skeletal maturation.

Dental development has been widely investigated as a potential predictor of the skeletal maturity level. In general, the dental development can be assessed using either the phase of tooth eruption or the stage of tooth calcification. Calcification stages of teeth instead of eruption are preferred because tooth formation is proposed as more reliable criteria for determining dental maturation.<sup>[7]</sup> Demirjian *et al.*<sup>[8]</sup> in 1973 described a method for estimating the dental age by reference to the radiologic appearance of seven teeth on the left quadrant of the mandible.

This study aims to determine an association, if any, between skeletal maturity and dental calcification stages. The stages of dental calcification might be used as a first-level diagnostic tool to estimate the timing of the pubertal growth spurt. The ease of recognizing dental developmental stages, together with the availability of intraoral or panoramic radiographs in most orthodontic or pediatric dental practices, are practical reasons for attempting to assess physiologic maturity without resorting to hand-wrist radiographs.<sup>[8]</sup>

The average age at which the onset of puberty occurs has dropped significantly since the 1840s. This was dubbed “the secular trend” by Tanner. Several studies report that there is a consistent lowering of the age at menarche on an average, by about 6 months per decade. Assessment of biologic age also throws light on the decreasing age in maturity in both boys and girls. Thus, maturation status cannot be assessed solely by determining the chronological age. It has been recognized that an individual’s chronological age does not always correlate with the maturational age; skeletally, it may be retarded or advanced.<sup>[9]</sup>

Thus, for proper orthodontic diagnosis and treatment planning, accurate assessment of skeletal maturity is important. As a result, many investigators have attempted to predict the duration, magnitude, direction, and timing of the adolescent growth changes. The purpose of this study is to investigate the correlation between the stages of calcification of various teeth and skeletal maturation through hand-wrist radiographs.

#### Aims and objective

- To investigate the correlation between calcification of teeth and scheduled pattern of appearance and ossification of bones of the hand wrist
- To assess the reliability of dental calcification in evaluating the facial growth in an orthodontic patient.

## MATERIALS AND METHODS

A total of 120 patients (60 males and 60 females) aged between 7 and 12 years were enrolled into the study. A total of 120 panoramic and hand-wrist radiographs were obtained and evaluated. The participants were chosen from patients visiting the Department of Orthodontics and Dentofacial Orthopedics, Department of Pedodontics and Department of Oral Medicine Diagnosis and Radiology, Saraswati Dental College and Hospital, Lucknow. A consent form was signed by each subject. Approval was obtained from the Human Research Ethics Committee, Saraswati Dental College, Lucknow.

The patients selected were physically and mentally healthy without a history of congenital or developmental disturbances due to syndromes or hormonal disturbance which could affect their growth. There was no previous history of trauma or injury to the face and the hand and wrist region.

Assessment of dental maturity was carried out through the calcification stages according to the method by Demirjian *et al.* from panoramic radiographs. These stages are as follows:

- In both uni- and multi-radicular teeth, a beginning of calcification is seen at the superior level of the crypt in the form of an inverted cone or cones. There is no fusion of these calcified points
  - Fusion of the calcified points forms one or several cusps which unite to give a regularly outlined occlusal surface
  - Enamel formation is complete at the occlusal surface. Its extension and convergence toward the cervical region is seen. The beginning of dentinal deposit is seen. The outline of the pulp chamber has a curved shape at the occlusal border
  - The crown formation is completed down to the cemento-enamel junction
    - The superior border of the pulp chamber in the uniradicular teeth has a definite curved form, being concave toward the cervical region. The projection of the pulp horns, if present, gives an outline shaped like an umbrella top. In molars, the pulp chamber has a trapezoidal form
    - Beginning of root formation is seen in the form of a spicule.
  - Uniradicular teeth
    - The walls of the pulp chamber now form straight lines whose continuity is broken by the presence of the pulp horn, which is larger than in the previous stage
    - The root length is less than crown height.
- Molars:
- Initial formation of the radicular bifurcation is seen in the form of either a calcified point or a semi-lunar shape

- The root length is still less than the crown height.
- F. Uniradicular teeth
- The walls of the pulp chamber now form a more or less isosceles triangle. The apex ends in a funnel shape
  - The root length is equal to or greater than the crown height.
- Molars:
- The calcified region of the bifurcation has developed further down from its semi-lunar stage to give the roots a more definite and distinct outline with funnel-shaped endings
  - The root length is equal to or greater than the crown height.
- G. Uniradicular teeth, molar
- The walls of the root canal are now parallel and its apical end is still partially open (distal root in molars).
- H. Uniradicular teeth, molar
- The apical end of the root canal is completely closed (distal root in molars)
  - The periodontal membrane has a uniform width around the root and the apex.

Assessment of skeletal maturity was carried out with 11 grade system of Fishman (1982) [Figure 1]. The reason for considering this index was that it is the most commonly used skeletal I indicator and these 11 discrete adolescent skeletal maturational indicators (SMI) covering the entire period of adolescent development are found on six anatomical sites.

## RESULTS

In males, the correlation between SMI and grades of calcification was found to be strongest for canine ( $\rho = 0.755$ ) and in females, second molar showed the strongest correlation ( $\rho = 0.845$ ).

In males, for canine, SMI I showed more correlation with Stage D and E. SMI II and III showed more correlation with Stage G. SMI IV and V correlated with Stage H.

For the first premolar, SMI I showed more correlation with Stage D. SMI II showed more correlation with Stage F. SMI III correlated with Stage H and SMI IV and V correlates with Stage G.

For second premolar, SMI I showed more correlation with Stage C as well as Stage H. SMI II showed more correlation with Stage E. SMI III, IV, and V showed more correlation with Stage G.

Skeletal maturity indicator	% of growth completed/remaining
SMI 1	The third finger proximal phalanx shows equal width of epiphysis and diaphysis (100% adolescent growth remaining in both males and females)
SMI 2	Width of epiphysis equal to that of diaphysis in the middle phalanx of the third finger (15.02% adolescent growth completed in males and 12.15% completed in females)
SMI 3	Width of epiphysis equal to that of diaphysis in the middle phalanx of the fifth finger (21.60% adolescent growth completed in males and 22.54% completed in females)
SMI 4	Appearance of adductor sesamoid of the thumb (28.92% adolescent growth completed in males and 32.73% completed in females)
SMI 5	Capping of epiphysis seen in distal phalanx of the third finger (34% adolescent growth completed in males and 39.75% completed in females)
SMI 6	Capping of epiphysis seen in middle phalanx of the third finger (52.64% adolescent growth completed in males and 51.70% completed in females)
SMI 7	Capping of epiphysis seen in middle phalanx of the fifth finger (74.29% adolescent growth completed in males and 73.58% completed in females)
SMI 8	Fusion of epiphysis and diaphysis in the distal phalanx of the third finger (87.32% adolescent growth completed in males and 86.58% completed in females)
SMI 9	Fusion of epiphysis and diaphysis in proximal phalanx of the third finger (91.98% adolescent growth completed in males and 91.87% completed in females)
SMI 10	Fusion of epiphysis and diaphysis in middle phalanx of the third finger (95.34% adolescent growth completed in males and 96.14% completed in females)
SMI 11	Fusion of epiphysis and diaphysis seen in the radius (100% adolescent growth completed in both males and females)

SMI: Skeletal maturational indicator

For second molar, SMI I showed more correlation with Stage C. SMI II showed more correlation with Stage E. SMI III showed more correlation with Stage G. SMI IV and V correlated with Stage H [Table 1].

On the assessment of this relationship by calculating Spearman's rank correlation, the  $\rho$  value was 0.755 for canine which indicated the existence of a strong correlation between SMI and calcification grade for the canine. 0.659 for the first premolar, 0.582 for second premolar and 0.628 for second molar which indicated the existence of a moderate correlation between SMI stage and calcification grade for first premolar, second premolar, and second molar. Canine showed maximum correlation [Table 1].

Thus, in males, canine calcification Stage D and E correlated with SMI I. Dental calcification Stage G correlated with SMI II and SMI III. Dental calcification Stage H correlated with SMI IV and SMI V, which infers dental calcification Stage H represents prepeak of pubertal growth spurt.

**Table 1: Correlation between skeletal maturity indicator and grades of calcification at different locations (males)**

Serial number	Calcification grade	n	SMI stage							
			I, n (%)	II, n (%)	III, n (%)	IV, n (%)	V, n (%)	VI, n (%)	VII, n (%)	VIII, n (%)
<b>Canine</b>										
1	C	0	0	0	0	0	0	0	0	0
2	D	1	1 (100.0)	0	0	0	0	0	0	0
3	E	11	11 (100.0)	0	0	0	0	0	0	0
4	F	20	12 (60.0)	4 (20.0)	4 (20.0)	0	0	0	0	0
5	G	24	2 (8.3)	6 (25.0)	16 (66.7)	0	0	0	0	0
6	H	4	0	0	2 (50.0)	1 (25.0)	1 (25.0)	0	0	0
$\rho=0.755$ ; $P<0.001$ (Spearman's rank correlation)										
<b>First premolar</b>										
1	C	0	0	0	0	0	0	0	0	0
2	D	8	8 (100.0)	0	0	0	0	0	0	0
3	E	21	13 (61.9)	4 (19.0)	4 (19.0)	0	0	0	0	0
4	F	18	4 (22.2)	5 (27.8)	9 (50.0)	0	0	0	0	0
5	G	9	1 (11.1)	1 (11.1)	5 (55.6)	1 (11.1)	1 (11.1)	0	0	0
6	H	4	0	0	4 (100.0)	0	0	0	0	0
$\rho=0.659$ ; $P<0.001$ (Spearman's rank correlation)										
<b>Second premolar</b>										
1	C	2	2 (100.0)	0	0	0	0	0	0	0
2	D	19	14 (73.7)	1 (5.3)	4 (21.1)	0	0	0	0	0
3	E	15	6 (40.0)	5 (33.3)	4 (26.7)	0	0	0	0	0
4	F	15	4 (26.7)	4 (26.7)	7 (46.7)	0	0	0	0	0
5	G	9	0	0	7 (77.8)	1 (11.1)	1 (11.1)	0	0	0
6	H	2	2 (100.0)	0	0	0	0	0	0	0
$\rho=0.582$ ; $P<0.001$ (Spearman's rank correlation)										
<b>Second molar</b>										
1	C	2	2 (100.0)	0	0	0	0	0	0	0
2	D	23	16 (69.6)	4 (17.4)	3 (13.0)	0	0	0	0	0
3	E	17	6 (35.3)	4 (23.5)	7 (41.2)	0	0	0	0	0
4	F	10	2 (20.0)	2 (20.0)	6 (60.0)	0	0	0	0	0
5	G	6	0	0	6 (100.0)	0	0	0	0	0
6	H	2	0	0	0	1 (50.0)	1 (50.0)	0	0	0
$\rho=0.628$ ; $P<0.001$ (Spearman's rank correlation)										

SMI: Skeletal maturity indicator

In females, for canine, SMI I showed more correlation with Stage E. SMI II showed more correlation with Stage F. SMI III showed more correlation with Stage G. Stage IV, VI, VII, and VIII correlated with Stage H.

For first premolar, SMI I showed more correlation with Stage D. SMI II, III, and IV showed more correlation with Stage F. Stage III and IV correlated with Stage F. SMI VII showed correlation with Stage G. SMI VI and VIII correlated with Stage H.

For second premolar, SMI I, II, and III showed a better correlation with Stage D, E, and F, respectively. SMI IV, VI, and VII correlated with Stage G. SMI VIII correlated with Stage H.

For second molar, SMI I and II showed correlation with Stage D and E, respectively. SMI III correlated with Stage F and Stage

IV and VI correlated with Stage G. SMI VII and VIII correlated with Stage H.

On the assessment of this relationship by calculating Spearman's rank correlation, the  $\rho$  value was 0.807 for canine, 0.837 for first premolar, 0.733 for second premolar, and 0.845 for second molar which indicated existence of a strong correlation for all locations. Second molar showed the maximum correlation [Table 2].

Thus, in females, second molar calcification Stage D correlated with SMI I and Stage E correlated with SMI II. Second molar calcification Stage F correlated with SMI III. Second molar calcification Stage G correlated with SMI IV and SMI VI. Second molar calcification Stage H correlated with SMI VII and SMI VIII which infers second molar calcification Stage G represents prepeak of pubertal growth

**Table 2: Correlation between skeletal maturity indicator and grades of calcification at different locations (females)**

Serial number	Calcification grade	n	SMI stage							
			I, n (%)	II, n (%)	III, n (%)	IV, n (%)	V, n (%)	VI, n (%)	VII, n (%)	VIII, n (%)
<b>Canine</b>										
1	C	0	0	0	0	0	0	0	0	0
2	D	0	0	0	0	0	0	0	0	0
3	E	2	3 (60.0)	2 (40.0)	0	0	0	0	0	0
4	F	43	6 (24.0)	16 (64.0)	3 (12.0)	0	0	0	0	0
5	G	33	0	4 (20.0)	7 (35.0)	1 (5.0)	0	5 (25.0)	2 (10.0)	1 (5.0)
6	H	23	0	0	1 (10.0)	1 (10.0)	0	4 (40.0)	2 (20.0)	2 (20.0)
$\rho=0.807$ ; $P<0.001$ (Spearman's rank correlation)										
<b>First premolar</b>										
1	C	0	0	0	0	0	0	0	0	0
2	D	2	3 (60.0)	2 (40.0)	0	0	0	0	0	0
3	E	43	6 (27.3)	13 (59.1)	3 (13.6)	0	0	0	0	0
4	F	33	0	7 (63.6)	3 (27.3)	1 (9.1)	0	0	0	0
5	G	23	0	0	5 (26.3)	1 (5.3)	0	7 (36.8)	4 (21.1)	2 (10.5)
6	H	14	0	0	0	0	0	2 (66.7)	0	1 (33.3)
$\rho=0.837$ ; $P<0.001$ (Spearman's rank correlation)										
<b>Second premolar</b>										
1	C	0	0	0	0	0	0	0	0	0
2	D	2	3 (33.3)	5 (55.6)	1 (11.1)	0	0	0	0	0
3	E	43	5 (27.8)	11 (61.1)	2 (11.1)	0	0	0	0	0
4	F	33	1 (5.3)	6 (31.6)	5 (26.3)	1 (5.3)	0	4 (21.1)	1 (5.3)	1 (5.3)
5	G	23	0	0	3 (23.1)	1 (7.7)	0	5 (38.5)	3 (23.1)	1 (7.7)
6	H	14	0	0	0	0	0	0	0	1 (100.0)
$\rho=0.733$ ; $P<0.001$ (Spearman's rank correlation)										
<b>Second molar</b>										
1	C	0	0	0	0	0	0	0	0	0
2	D	2	8 (40.0)	11 (55.0)	1 (5.0)	0	0	0	0	0
3	E	43	1 (6.3)	11 (68.8)	3 (18.8)	0	0	1 (6.3)	0	0
4	F	33	0	0	6 (46.2)	1 (7.7)	0	4 (30.8)	1 (7.7)	1 (7.7)
5	G	23	0	0	1 (12.5)	1 (12.5)	0	4 (50.0)	1 (12.5)	1 (12.5)
6	H	14	0	0	0	0	0	0	2 (66.7)	1 (33.3)
$\rho=0.845$ ; $P<0.001$ (Spearman's rank correlation)										

SMI: Skeletal maturity indicator

spurt and Stage H represents the peak of pubertal growth spurt.

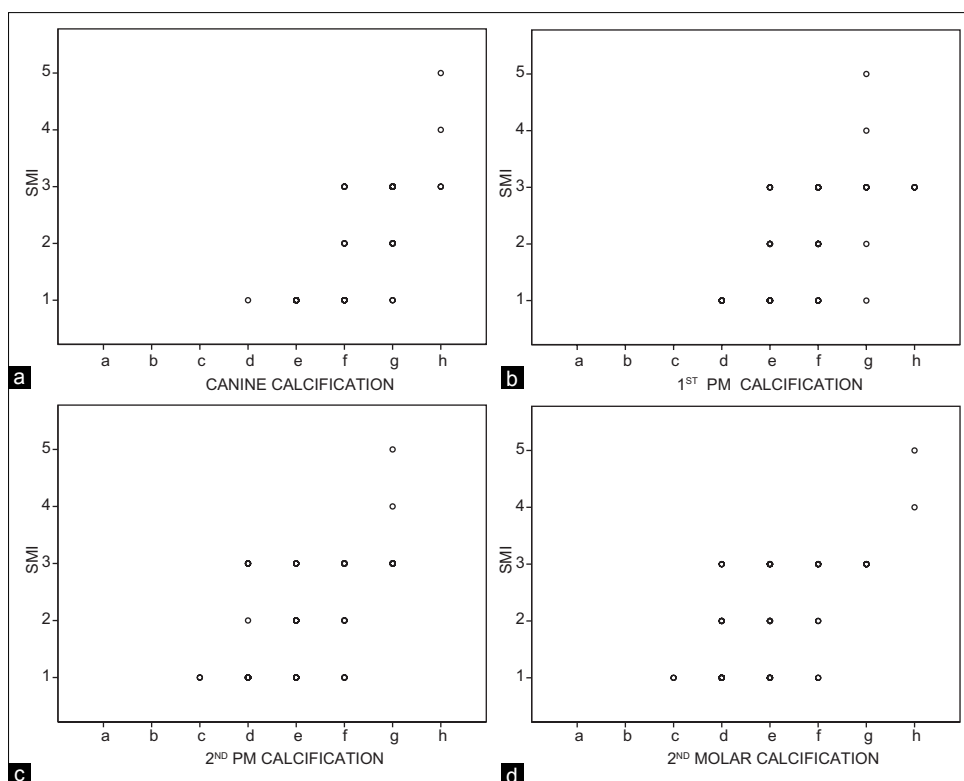
## DISCUSSION

The development status of an individual is usually assessed in relation to physical events that take place during the progress of growth such as skeletal ossification stages, the attainment of peak growth velocity, pubescent changes in the body, or dental calcification stages. Indicators of developmental age are, therefore, more informative than chronological age, particular for age estimation and clinical application.<sup>[10]</sup>

From this study, the relationship between the tooth calcification stages and the SMI probably allows the clinician to more easily identify the stages the pubertal growth period from the panoramic radiograph.

Many researchers have reported relationships between the calcification stages of individual teeth and skeletal maturity, as well as the racial variations.<sup>[11-14]</sup> A few studies are available in the literature about Indian populations. Therefore, the aim of this study was to investigate the relationships between the stages of calcification of various teeth and the stages of skeletal maturity among North-Indian patients using hand-wrist radiograph and panoramic radiograph.

In the present study, the grades of calcification were compared to the skeletal maturity by the maturation of the bones of the hand wrist. The assessments were done separately for both males and females. It was found that the bivariate correlation between tooth calcification and SMI (for males,  $\rho = 0.58-0.75$ ) [Table 1 and Graph 1] for females,  $\rho = 0.73-0.84$  [Table 1 and Graph 2]. Overall, the females showed more correlation between the tooth calcification and the SMI.



Graph 1: Correlation between skeletal maturational indicator stages and tooth calcification in males. (a) Canine. (b) First premolar. (c) Second premolar. (d) Second molar

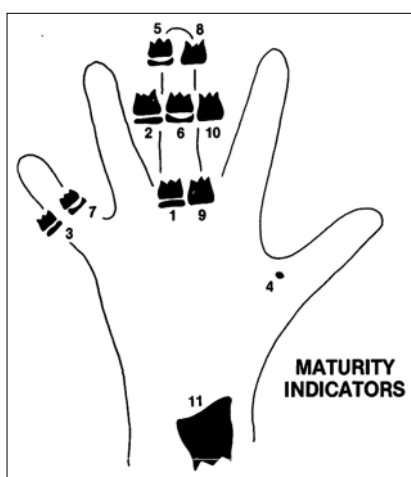


Figure 1: Skeletal maturational indicator Stages 1 to 11 (Fishman)

Many studies have attempted to determine whether there is a relationship between the level of skeletal maturity and the maturation of the permanent dentition. Demisch and Wartmann<sup>[15]</sup> reported a high correlation between dental and skeletal ages, Chertkow,<sup>[11]</sup> Coutinho *et al.*<sup>[16]</sup> Krailassiri *et al.*<sup>[12]</sup> and Engström *et al.*<sup>[17]</sup> reported similar high correlations. On the other hand, Lewis and Garn,<sup>[18]</sup> Garn and Lewis,<sup>[19]</sup> and Tanner<sup>[20]</sup> have reported low or insignificant correlations between the level of skeletal and dental maturation.

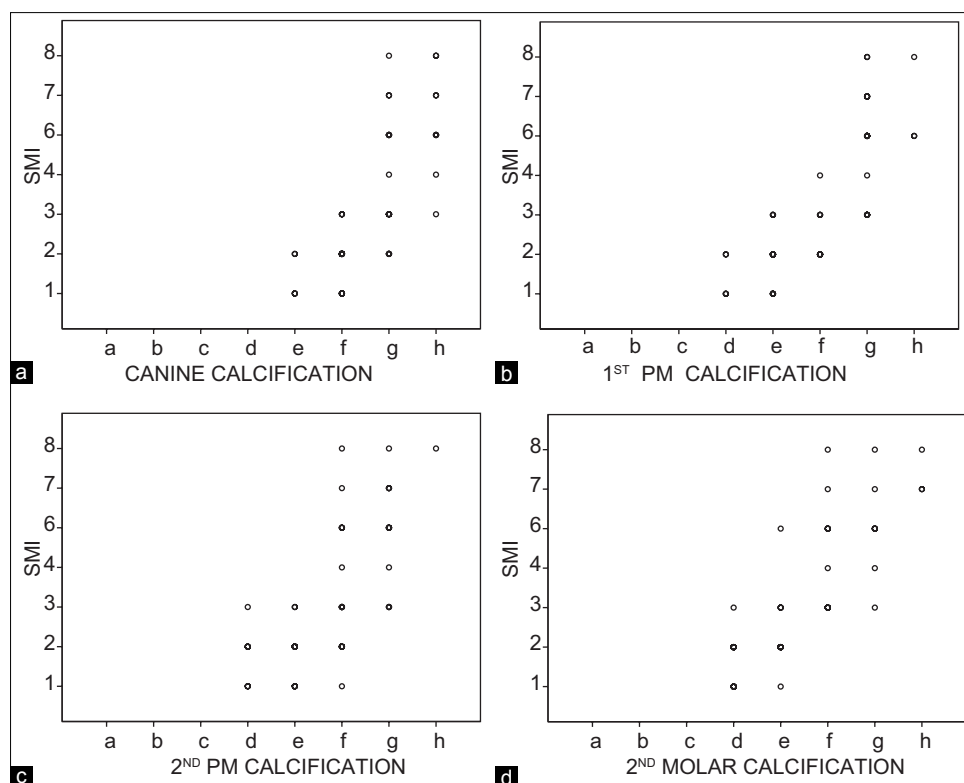
Statistically significant correlations were found between dental calcification stages and SMIs in Thai and Turkish patients.<sup>[12,13]</sup> In this study, statistically significant correlations (for males ranging between 0.58 and 0.75, for females ranging between 0.73 and 0.84) [Tables 1 and 2] were found between dental calcification stages and skeletal maturity through hand-wrist radiographs. Thus, in this study, statistically significant correlations were obtained between dental calcification and SMIs similar to Thai and Turkish patients. Many studies reported that the high correlations between the tooth calcification stages and the SMIs probably allow the clinician to more easily identify the stages of the pubertal growth period from the panoramic radiograph.

Chertkow,<sup>[11]</sup> Chertkow and Fatti,<sup>[21]</sup> Sierra<sup>[22]</sup> and Coutinho *et al.*<sup>[16]</sup> suggested a high relationship between calcification of mandibular canine and SMI.

In this study, canines showed the maximum correlation with the SMIs in males [Table 1]. In females, second molar showed more correlation with the SMIs [Table 2].

However, in both male and female patients Thai individuals, the second premolar showed the highest correlation.

Mittal *et al.*<sup>[23]</sup> and Rai *et al.*<sup>[24]</sup> found second molar to be maximally correlating with the skeletal maturation in Indian



Graph 2: Correlation between skeletal maturational indicator stages and tooth calcification in females. (a) Canine. (b) First premolar. (c) Second premolar. (d) Second molar

patients. Same correlation was also found in the Turkish patients. In this study, female patients exhibited second molar to be maximally correlating with the skeletal maturation through hand-wrist radiographs [Table 2]. Thus, this finding is in accordance with studies conducted by Mittal *et al.*,<sup>[23]</sup> Rai,<sup>[24]</sup> and Uysal *et al.*<sup>[13]</sup>

Orthopedic treatment can be accomplished when the patient is in the stages of initiation and acceleration of growth as there is good amount of adolescent growth potential still left, i.e., before maximum pubertal spurt stages of SMI and tooth calcification. Around the peak pubertal stages, only some amount of growth can be utilized, probably fixed functional orthopedic treatment can be accomplished. After maximum pubertal stages, appliances can bring about only minimal skeletal changes and more of dental changes. Hence, during decelerating and completion stages, it is advisable to let the growth be completed and then advise the patient to undergo orthodontic treatment alone or surgical orthodontic intervention depending on the magnitude of the discrepancy.

## CONCLUSION

General conclusions drawn from this study are as follows:

1. The appearance of each skeletal stage is consistently earlier in the females than in the males
2. The correlation between skeletal maturation evaluated by hand wrist and grades of calcification was found to be strongest for the canine in male patients and the second molar showed the strongest correlation in female patients
3. In male patients, canine calcification Stages D and E corresponded to SMI I which signifies initiation of pubertal growth. Dental calcification Stage G corresponded to SMI III which signifies the prepeak of pubertal growth spurt or onset of peak height velocity (PHV). Dental calcification Stages G and H corresponded to SMI V which signifies peak of pubertal growth spurt, which infers that canine calcification Stages G and H represent the peak of the pubertal growth spurt
4. In females, first premolar and second molar calcification Stage D corresponded with SMI I which signifies initiation of pubertal growth. Calcification Stage E and F corresponded with SMI III which signifies the prepeak of pubertal growth spurt or onset of PHV. Dental calcification Stage G corresponded with SMI VI which signifies peak of pubertal growth spurt which infers dental calcification Stage G represents the peak of pubertal growth spurt. Calcification Stage H corresponded with SMI VIII. Thus, in females, calcification Stage G for both first premolar and second molar represents the peak of pubertal growth spurt

5. From this study, the relationship between the tooth calcification stages and SMI probably allows the clinician to more easily identify the stages of the pubertal growth period from the panoramic radiographs.

#### Financial support and sponsorship

Nil.

#### Conflicts of interest

There are no conflicts of interest.

#### REFERENCES

1. Hassel B, Farman AG. Skeletal maturation evaluation using cervical vertebrae. *Am J Orthod Dentofacial Orthop* 1995;107:58-66.
2. Greulich W, Pyle SI. Radiographic Atlas of Skeletal Development of Hand Wrist. 2<sup>nd</sup> ed. California: Stanford University; 1959. p. 34-6.
3. Singer J. Physiological timing of orthodontic treatment. *Angle Orthod* 1980;50:322-33.
4. Revelo B, Fishman LS. Maturational evaluation of ossification of the midpalatal suture. *Am J Orthod Dentofacial Orthop* 1994;105:288-92.
5. Rossouw PE, Lombard CJ, Harris AM. The frontal sinus and mandibular growth prediction. *Am J Orthod Dentofacial Orthop* 1991;100:542-6.
6. Fishman LS. Maturational patterns and prediction during adolescence. *Angle Orthod* 1987;57:178-93.
7. Nolla CM. The development of the permanent teeth. *J Dent Child* 1960;27:254-63.
8. Demirjian A, Goldstein H, Tanner JM. A new system of dental age assessment. *Hum Biol* 1973;45:211-27.
9. Bagga A, Kulkarni S. Age at menarche and secular trend in Maharashtrian (Indian) girls. *Acta Biol Szeged* 2000;44:53-7.
10. Demirjian A, Buschang PH, Tanguay R, Patterson DK. Interrelationships among measures of somatic, skeletal, dental, and sexual maturity. *Am J Orthod* 1985;88:433-8.
11. Chertkow S. Tooth mineralization as an indicator of the pubertal growth spurt. *Am J Orthod* 1980;77:79-91.
12. Krailassiri S, Anuwongnukroh N, Dechkunakorn S. Relationships between dental calcification stages and skeletal maturity indicators in Thai individuals. *Angle Orthod* 2002;72:155-66.
13. Uysal T, Sari Z, Ramoglu SI, Basciftci FA. Relationships between dental and skeletal maturity in Turkish subjects. *Angle Orthod* 2004;74:657-64.
14. Mappes MS, Harris EF, Behrents RG. An example of regional variation in the tempos of tooth mineralization and hand-wrist ossification. *Am J Orthod Dentofacial Orthop* 1992;101:145-51.
15. Demisch S, Wartmann C. Calcification of mandibular third molar and its relationship to skeletal and chronological age in children. *Child Dev* 1956;27:459-73.
16. Coutinho S, Buschang PH, Miranda F. Relationships between mandibular canine calcification stages and skeletal maturity. *Am J Orthod Dentofacial Orthop* 1993;104:262-8.
17. Engström C, Engström H, Sagne S. Lower third molar development in relation to skeletal maturity and chronological age. *Angle Orthod* 1983;53:97-106.
18. Lewis AB, Garn SM. The relationship between tooth formation and other maturational factors. *Angle Orthod* 1960;30:70-7.
19. Garn SM, Lewis AB. Third molar formation and its developmental course. *Angle Orthod* 1962;44:270-6.
20. Tanner JM. Growth at Adolescence. 2<sup>nd</sup> ed., Vol. 15. Oxford, UK: Blackwell Scientific Publications; 1962. p. 1-9.
21. Chertkow S, Fatti P. The relationship between tooth mineralization and early radiographic evidence of the ulnar sesamoid. *Angle Orthod* 1979;49:282-8.
22. Sierra AM. Assessment of dental and skeletal maturity: A new approach. *Angle Orthod* 1987;57:194-208.
23. Mittal S, Singla A, Virdi M, Sharma R, Mittal B. Co-relation between determination of skeletal maturation using cervical vertebrae and dental calcification stages. *Internet J Forensic Sci* 2011;4.
24. Rai B. Relationship of dental and skeletal radiograph: Maturity indicator. *Internet J Biol Anthropol* 2008;2.