

# A biological approach to crown fracture: Fracture reattachment: A report of two cases

VIJAYAPRABHA K. NIKHIL MARWAH<sup>1</sup>, SAMIR DUTTA<sup>2</sup>

## Abstract

The development of adhesive dentistry has allowed dentists to use the patient's own fragment to restore the fractured tooth, which is considered to be the most conservative method of treatment of crown fracture allowing restoration of original dental anatomy, thus rehabilitating function and esthetics in a short time by preserving dental tissues. The tooth fragment reattachment is preferred over full coverage crowns or composite resin restoration because it conserves sound tooth structure, and is more esthetic, maintaining the original anatomy and translucency, and the rate of incisal wear also matches that of original tooth structure. Presented here is a report of two cases of crown fracture managed by reattachment procedures.

**Keywords:** Bonding, crown fracture, intra-enamel bevel, reattachment

## Introduction

Anterior crown fractures are a common form of injury that mainly affects children and adolescents. The position of maxillary incisors and their eruptive pattern carries a significant risk for trauma. Andreasen has classified crown fractures as enamel infractions, enamel fractures with little or no dentin involvement, enamel–dentin fractures with no pulp involvement (uncomplicated crown fractures), and enamel–dentin fractures with pulpal involvement (complicated crown fractures).

The incidence of trauma to anterior teeth in children is on a rise. In the 6–12-year-old children, it has been reported to range from 2.1%<sup>[1]</sup> to 4%<sup>[2]</sup>. The prevalence of dental trauma has also shown considerable variation. It has been shown to range from 6%<sup>[1]</sup> to 34%<sup>[2]</sup>. The prevalence of dental trauma in various epidemiological studies has been found to differ considerably. This may be due to a number of factors such as the classification used for trauma, the dentition studied, and geographic and behavioral differences between various study locations.

*Department of Pedodontics and Preventive Dentistry, Sree Balaji Dental College and Hospital, Chennai, Tamilnadu* <sup>1</sup>*Department of Pedodontics, Mahatma Gandhi Dental College, Jaipur, Rajasthan* <sup>2</sup>*Government Dental College, Rohtak, Haryana, India*

**Correspondence:** Dr. Vijayaprabha. K, No. 7, 6<sup>th</sup> st extn., Sri Ganesh Flats, Lakshmi Nagar, Nanganallur, Chennai – 600 061, Tamilnadu, India. E-mail: prabhav80@yahoo.co.in

The most prevalent age of trauma to primary dentition is 10–24 months,<sup>[3]</sup> the age when the child learns to walk, and to the permanent dentition is 9–15 years,<sup>[4]</sup> when the children are actively engaged in various sporting activities. Males were found to experience significantly more dental trauma to the permanent dentition with a male:female ratio of 1.3–2.3:1.0,<sup>[1,4]</sup> whereas in case of trauma to the deciduous dentition, no such statistically significant sex distribution has been demonstrated.<sup>[5]</sup> The major cause for dental trauma to the deciduous dentition has been found to be accidents within and around the home, and in case of permanent dentition, most injuries were due to accidents in school and at home.<sup>[1,4,5]</sup> The other common causes of dental trauma are sports injuries, violence, and road traffic accidents. The most common dental injury to the permanent dentition is uncomplicated crown fracture without any pulp exposure.<sup>[1,6]</sup> The maxillary central incisors are the most commonly affected teeth, followed by the maxillary lateral incisors.<sup>[1,4,6]</sup>

In the pre-adhesive era, fractured teeth needed to be restored either with pin-retained inlays or cast restorations followed by full-coverage crowns that sacrificed healthy tooth structure and were a challenge for the clinicians to match in esthetics with the adjacent teeth.<sup>[7]</sup> The development of adhesive dentistry has allowed dentists to use the patient's own fragment to restore the fractured tooth. This is considered to be the most conservative method of treatment of crown fracture allowing restoration of original dental anatomy, thus rehabilitating function and esthetics in a short time by preserving dental tissues. The tooth fragment reattachment is preferred over full coverage crowns or composite resin restoration because it conserves sound tooth structure, and is more esthetic, maintaining the original anatomy and translucency, and the rate of incisal wear also matches that of original tooth structure.

Presented here is a report of two cases of crown fracture, the first one in which maxillary left central incisor was fractured

Access this article online	
Quick Response Code: 	Website: <a href="http://www.contempclindent.org">www.contempclindent.org</a>
	DOI: 10.4103/0976-237X.101091

at the middle third of the clinical crown, exposing the pulp (complicated crown fracture – Ellis class III fracture), and the other in which both the maxillary central incisors were fractured at the junction of middle and incisal thirds of the clinical crown, without pulp exposure (uncomplicated crown fracture – Ellis class II fracture).

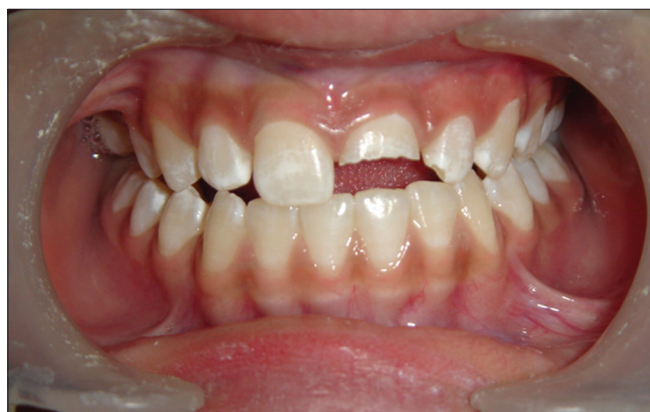## Case Reports

### Case I

An 11-year-old girl, who had sustained a complicated crown fracture (Ellis class III fracture) in her maxillary left central incisor (21) due to fall from a bicycle, reported to our department [Figure 1]. The patient had recovered the fractured fragment from the site of injury and had placed it in water, and reported immediately to our OPD. After a thorough clinical examination, we had decided to perform an immediate root canal treatment (RCT) of 21, followed by the reattachment of the fractured fragment on to the tooth. After adequately anesthetizing and isolating the tooth, a single-visit root canal treatment was performed in 21 [Figures 2 and 3]. On the fractured ends of the tooth and the tooth fragment, an intra-enamel circumferential bevel was given. The ends were then etched with a 37% phosphoric acid etchant for 15 seconds and rinsed thoroughly with water, the tooth was dried, and a dentin-bonding agent (Scotch Bond, 3M ESPE) was applied over them and light-cured for 20 seconds as per the manufacturer's instruction. The fractured fragment was then exactly re-approximated over the tooth, paying careful attention to prevent any displacement of the fragment during the curing procedure, and light-cure composite resin material (3M ESPE) was applied and it was photo-polymerized for 40 seconds. The tooth was then finished and polished [Figure 4]. The tooth fragment was thus reattached with good esthetic results and with restored function. A follow-up of the patient 2 years postoperatively showed good esthetic and functional results.

### Case II

A 9-year-old girl reported to our OPD with coronal fractures in both maxillary central incisors due to a fall while climbing



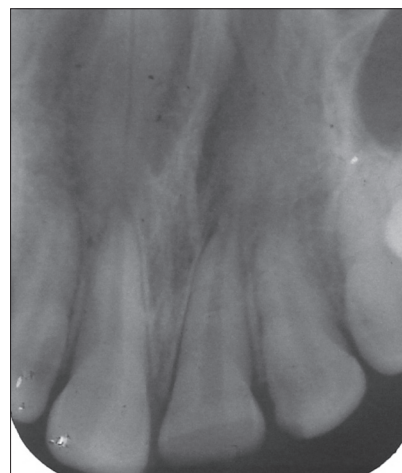
**Figure 1:** Ellis class III fracture on 21 (case I)

the stairs. Both these teeth had uncomplicated crown fractures (Ellis class II fractures) with right maxillary central incisor having a single fractured fragment and left maxillary central incisor having two fractured fragments [Figure 5]. The patient had brought the fractured fragments [Figure 6] from the site of injury and reported to our OPD the next day. After a thorough clinical examination, a treatment plan was formulated to immediately reattach the fragments of the teeth. Since the patient had not placed the fractured fragments in water, they were hydrated by placing in water for an hour till the fragments attained the normal translucency. Vitality tests were not performed at this appointment as it has been shown that such tests are not reliable immediately following trauma.<sup>[8]</sup> An intra-enamel circumferential bevel was given on the fractured ends of both the central incisors [Figure 7]. Also, a groove was made on the lingual aspect of the teeth as well as the fragments. The fractured ends and the fragments were then treated with a single-step etchant-bonding agent (Xeno III, Dentsply) and light-cured for 10 seconds as per the manufacturer's instructions.

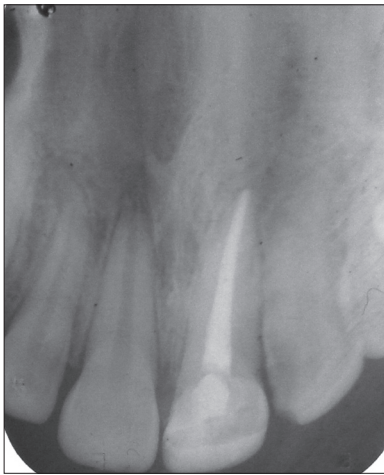The fractured fragment was then re-approximated over the right maxillary central incisors, taking care not to cause any displacement of the fragment during the curing procedure, and light-cure composite material (3M ESPE) was applied and it was photo-polymerized for 40 seconds. Then, both the fragments of maxillary central incisors were carefully repositioned [Figure 8] and the same steps were repeated. The teeth were finished and polished. The patient was recalled after a month and vitality tests were performed. Both these teeth were found to be vital. The vitality tests were repeated at a 3-month follow-up visit and a 6-month follow-up visit, and the teeth had retained their vitality. These teeth had performed well esthetically and functionally. The patient is on follow-up for more than a year now.

## Discussion

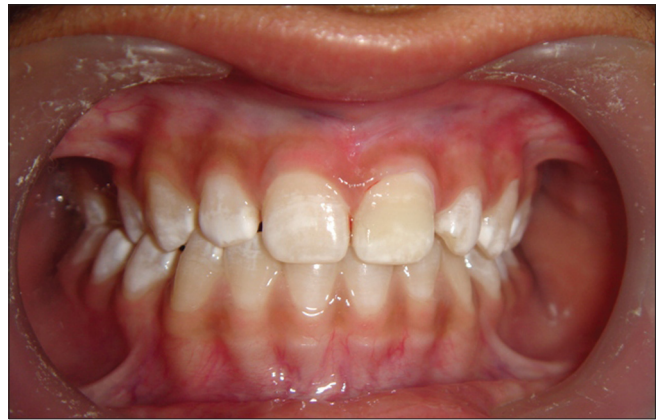Reattachment of fractured fragments has been reported in the literature since 1960s, with the first study published



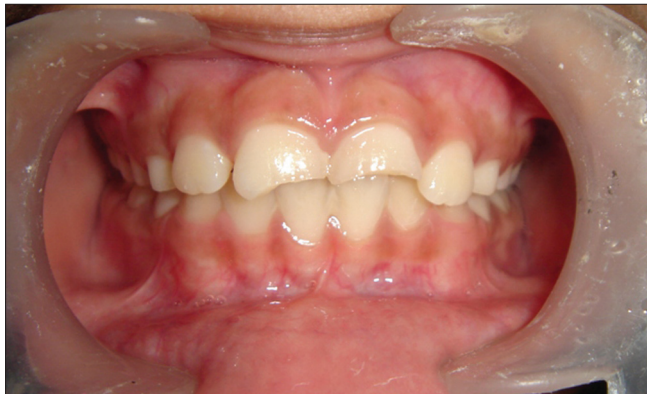**Figure 2:** Preoperative IOPA radiograph (case I)



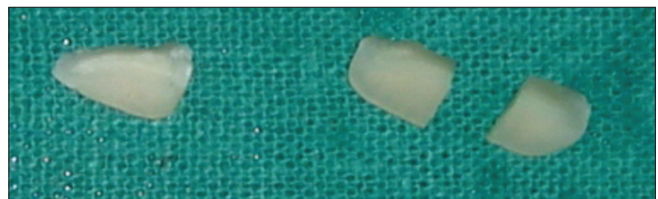
**Figure 3:** IOPA radiograph after RCT (case I)



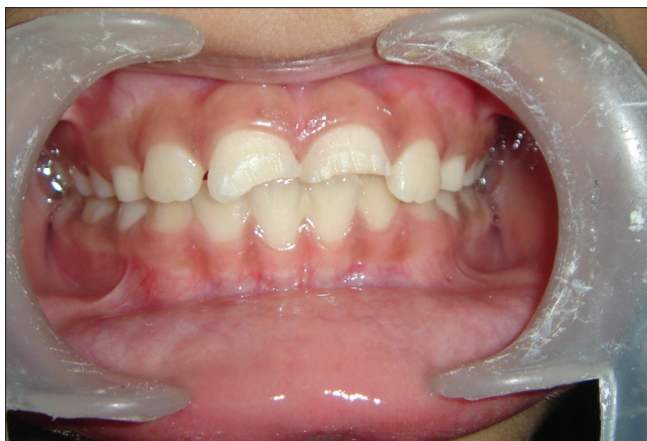**Figure 4:** Postoperative photograph (case I)



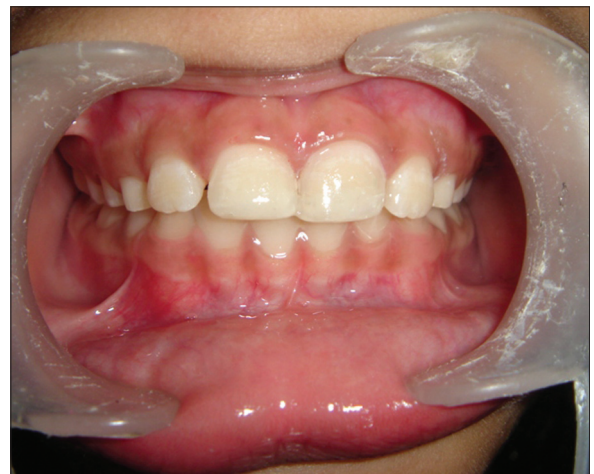**Figure 5:** Preoperative photograph (case II)



**Figure 6:** Fractured fragments (case II)



**Figure 7:** Teeth with intra enamel bevel (case II)



**Figure 8:** Postoperative photograph (case II)

in 1964,<sup>[7]</sup> where the authors had reattached the fractured fragment using post and core. The fragments have also been attached with dentinal pins.<sup>[9]</sup>

Though different methods have been employed for restoring fractured anterior teeth, fragment reattachment is the preferred method<sup>[10]</sup> because of improved esthetics, due to restoration of original color and translucency. Also the

original surface texture is maintained, and the rate of incisal wear is similar to adjacent natural teeth, and this procedure is less time-consuming.

A number of methods are being employed to aid in retention of the fractured fragments with the use of a wide range of cementing materials which would help in the adhesion of the fragment to the tooth. To retain the reattached fragment, many methods have been suggested in the literature. These retentive features are incorporated in the tooth or the fractured fragments or both.<sup>[11]</sup> These include the following.

#### **Enamel beveling**

This technique advocates enamel beveling of fragment and

the tooth crown. This technique claims to improve fragment retention since enamel beveling alters the enamel prism orientation, allowing for achieving a more effective acid etch pattern.<sup>[12]</sup> This technique also improves short-term esthetics.

#### V-shaped internal enamel groove

This method employs placing an internal enamel groove, which is restored with acid etch composite. This carries the limitation of difficulty in performing due to limited enamel thickness in anterior teeth. This technique has also been modified by placing the groove in the dentin of tooth crown, giving space for pulp capping agent.<sup>[13]</sup>

#### Internal dentinal groove

The placement of internal dentin groove allows for placement of resin composites, which reinforces the reattachment. This technique has also been claimed to compromise esthetics as it can modify the shade of the teeth, but this is dependent on the groove size and the material.<sup>[14,15]</sup>

#### External chamfer

The three methods described above have a common disadvantage that they may affect the precise fit of the repositioned fragments. This may be overcome by this technique which involves reattachment of the fragments first, followed by placement of the chamfer externally by means of round diamond bur. This chamfer may be placed either on buccal or on lingual aspect or circumferentially.<sup>[16]</sup>

#### Overcontour

In this technique, after the fragment is bonded, a superficial preparation of about 0.3 mm depth is placed on buccal surface using a cylindrical diamond finishing bur extending about 2.5 mm coronally and apically from the fracture line, which is filled with the thin layer of composite. However, the external chamfer and overcontour methods expose the resin composite to the external environment, which may compromise on long-term esthetics due to abrasion and discoloration.<sup>[17]</sup>

#### Simple attachment

Many authors have compared the various methods of reattachments. A study comparing single reattachments and circumferential chamfer reported that the latter had higher fracture resistance when subjected to static and bending stresses.<sup>[18]</sup> Another study has shown that simple reattachment recovered only 37.1% of intact tooth fracture resistance, whereas buccal chamfer recovered 60.6% and overcontour and internal groove techniques nearly reached intact tooth fracture strength, recovering 97.2% and 90.5%, respectively.<sup>[15, 19,20]</sup>

There are certain other factors to be considered during reattachment procedures.<sup>[11]</sup>

If endodontic therapy is required, the pulp chamber can be used as an internal reinforcement, avoiding excessive tooth

preparation, but the disadvantage is that the esthetics is compromised as the pulpless teeth lose a part of their translucency and brightness.

If the fracture extends close to the pulp, a direct pulp-capping agent is essential, and this would prevent placement of an internal groove in the fragment. If the fragments are very small, simple reattachment is done without any additional preparation.

If the segments fit well together, preparations that would avoid exposure of the resin composites are preferred. If enamel structure is lost due to trauma, overcontour or chamfer is preferred.

If the fracture line extends apically from labial to lingual direction, the fracture pattern is unfavorable, since it would offer low resistance to labially applied forces. On the other hand, if the fracture line runs in an incisal direction from labial to lingual aspect, the fracture pattern is said to be favorable due to the amount of lingual support it offers.

In our first case, we had used circumferential bevel both on the tooth crown as well as the fragment, and in our second case, we had used a combination of intra-enamel beveling on the tooth crown and a lingual groove both on the fragments and the tooth crown. A circumferential bevel was not placed on the fragments owing to their smaller size.

The most commonly employed are the dentin-bonding agents with the flowable resin composite materials. Other materials which have been employed are dentin-bonding agents only,<sup>[19,21,22]</sup> dual or self-cured luting cements<sup>[11,23]</sup> or light-cured luting cements,<sup>[24]</sup> and viscous light-cure hybrid or microfilled resin composites.<sup>[25]</sup> Worthington *et al.* showed that placement of any kind of preparation did not improve the fracture strength, and the incisal edge reattachment restored approximately half the fracture resistance of sound teeth.<sup>[26]</sup> Reis *et al.* have reported the chamfer technique to provide a better strength recovery than simple reattachment and both to be inferior to the resin composite restoration used to restore the original tooth.<sup>[27]</sup>

Reattaching fragments with dentin-bonding adhesives can be used to restore fractured teeth, presumably with sufficient strength, but long-term follow-up is essential to predict the durability of the tooth-adhesive-fragment complex and the vitality of the tooth.

## References

1. Stockwell AJ. Incidence of dental trauma in the Western Australian school Dental service. *Community Dent Oral Epidemiol* 1988;16:294-8.
2. Hamilton FA, Hill FJ, Holloway PJ. An investigation of dento-alveolar trauma and its treatment in an adolescent population. Part I: The prevalence and incidence of injuries and the extent

- and adequacy of treatment received. *Br Dent J* 1997;182:91-5.
3. Bijella MF, Yared FN, Bijella VT, Lopes ES. Occurrence of primary incisor traumatism in Brazilian Children: A house-by-house survey. *J Dent Child* 1990;57:424-7.
  4. Parkin SF. A recent analysis of surgical injuries to children's teeth. *J Dent Child* 1967;34:323-5.
  5. Onetto JE, Flores MT, Garbarino ML. Dental trauma in children and adolescents in Valparaiso, Chile. *Endod Dent Traumatol* 1994;10:223-7.
  6. Kaha AS, marechaux SC. A seven year follow-up study of traumatic injuries to the permanent dentition. *J Dent Child* 1989;56:417-25.
  7. Chosack A, Eidelman E. Rehabilitation of a fractured incisor using the patient's natural crown. Case report. *J Dent Child* 1964;31:19- 21.
  8. Andreasen FM. Pulpal healing after luxation injuries and root fracture in permanent dentition. *Endod Dent Traumatol* 1989;5:111- 31.
  9. Spasser HF. Repair and restoration of a fractured, pulpally involved anterior tooth: report of case. *J Am Dent Assoc* 1977;94:519-20.
  10. Baratieri LN, Monteiro S Jr, Andrada MAC. Tooth fracture reattachment: Case reports. *Quintessence Int* 1990;21:261-70.
  11. Reis A, Loguercio AD, Kraul A, Matson E. Reattachment of fractured teeth: A review of literature regarding Techniques and materials. *Oper Dent* 2004;29:226-33.
  12. Simonsen RJ. Traumatic fracture restorations; an alternative use of the acid-etch technique. *Quintessence Int* 1979;10:15-22.
  13. Simonsen RJ. Restoratio of a fractured central incisor using original tooth fragment. *J Am Dent Assoc* 1982;105:646-8.
  14. Walker M. Fractured tooth fragment reattachment. *Gen Dent* 1996;44:434-6.
  15. Reis A, Francci C, Loguercio AD, Carrilho MR, Rodriguez Filho LE. Reattachment of anterior teeth: Fracture strength using different techniques. *Oper Dent* 2001;25:91-6.
  16. Davis MJ, Roth J, Levi M. marginal integrity of adhesive fracture restorations: chamfer versus bevel. *Quintessence Int* 1983;14:1035-46.
  17. Fahl N Jr. Optimising the esthetics of class IV restorations with composite resins. *J Can Dent Assoc* 1997;63:108-11, 114-5.
  18. DeSantis R, Prisco D, Nazhat SN, Riccitiello F, Ambrosio L, Rengo S, *et al.* Mechanical strength of tooth fragment reattachment. *J Biomed Mater Res* 2002;55:629-36.
  19. Badami AA, Dunne SM, Scheer B. An *in vitro* investigation into the shear bond strengths of two dentin bonding agents used in the reattachment of incisal edge fragments. *Endod Dent Traumatol* 1995;11:129-35.
  20. Kanka J III. Replacement of a fractured incisor fragment over Pulpal exposure: a long term case report. *Quintessence Int* 1996;27:829-32.
  21. Munskgaard EC, Hojtvad L, Jorgensen EH, Andreasen JO, Andreasen FM. Enamel- dentin crown fractures bonded with various bonding agents. *Endod Dent Traumatol* 1991;7:73-7.
  22. Andreasen FM, Steinhardt U, Bille M, Munskgaard EC. Bonding of enamel- dentin crown fragments afetr crown fracture. An experimental study using bonding agents. *Endod Dent Traumatol* 1993;9:111-4.
  23. Dickerson WG. Conservative reattachment of a pulpally exposed, fractured incisor. *Dent Econ* 1994;84:90-1.
  24. Dean JA, Avery DR, Swartz ML. Attachment of anterior tooth fragments. *Pediatr Dent* 1986;8:139-43.
  25. Baratieri LN, Montiero S Jr, de Albuquerque FM, Viera LC, de Andrada MA, de Melo Filho JC. Reattachment of a tooth fragment with a new adhesive system: A case report. *Quintessence Int* 1994;25:91-6.
  26. Worthington RB, Murchison DF, Vandewalle KS. Incisal edge reattachment: the effect of preparation utilization and design. *Quintessence Int* 1999;30:637-43.
  27. Reis A, Kraul A, Francci C, de Assis TG, Crivelli DD, Oda M, *et al.* Reattachment of anterior fractured teeth. Fracture strength using different materials. *Oper Dent* 2002;27:621-7.

**How to cite this article:** Vijayaprabha K, Marwah N, Dutta S. A biological approach to crown fracture: Fracture reattachment - A report of two cases. *Contemp Clin Dent* 2012;3:S194-8.

**Source of Support:** Nil. **Conflict of Interest:** None declared.