

CASE REPORT

Open Access



Giant splenic cyst complicated by infection due to *Salmonella enterica* serovar Livingstone in a previously healthy adolescent male: a case report

Junyan Qu¹ and Zhiyong Zong^{1,2*}

Abstract

Background: Splenic cyst complicated by non-typhoid *Salmonella* infection is rare in healthy individuals in the era of antibiotics. *Salmonella enterica* subsp. *enterica* serovar Livingstone causing infection of giant splenic cyst has not been previously reported.

Case presentation: We report a case of giant splenic cyst (maximum diameter, 21 cm) complicated with *Salmonella* Livingstone infection, which resulted in splenic abscess, in a 16-year-old previously healthy adolescent male. The splenic abscess was successfully treated with ultrasonography-guided percutaneous drainage and antimicrobial therapy.

Conclusion: Infection of splenic cyst may be caused by *S. Livingstone* in immunocompetent individuals. This case may help clinicians to raise awareness towards splenic abscess and highlights the importance of drainage and antimicrobial agents to avoid splenectomy.

Keywords: *Salmonella* Livingstone, Splenic cyst, Splenic abscess, Case report

Background

Splenic cysts are rare lesions with an incidence of 0.07% [1]. By etiology, splenic cysts are classified as parasitic and non-parasitic. The latter is further divided into primary/congenital, degenerative, neoplastic and traumatic [2]. Splenic cysts are usually asymptomatic and are found occasionally on imaging examination [3]. When cysts are large in size, symptoms of compressing adjacent structures may occur, and complications such as infection, rupture and/or haemorrhage could develop occasionally [4]. Splenic cysts can form splenic abscesses due to

bacterial infection. The common pathogens of splenic abscess are streptococci, staphylococci, *Escherichia coli* and *Mycobacterium* spp. [5, 6]. Splenic abscess caused by *Salmonella enterica* subsp. *enterica* serovar Typhi, which causes typhoid fever, is uncommon with an incidence of 0.29–2%, while that caused by Non-typhoid *Salmonella* (NTS) is rare [7]. Only few cases of splenic cysts with NTS infection have been reported in literature [8, 9].

Salmonellosis due to *Salmonella enterica* subsp. *enterica* serotype Livingstone (*S. Livingstone*) is rare in human and is mainly recovered from poultry and poultry products [9]. In recent years, *S. Livingstone* has been increasingly isolated in some production settings and countries [10] and has caused outbreaks in some countries [11, 12]. In China, there was only one report about gastroenteritis due to *S. Livingstone* [13]. Splenic cysts complicated by *S.*

*Correspondence: zongzhiy@scu.edu.cn

¹ Center of Infectious Disease, West China Hospital (Huaxi), Sichuan University, Guoxuexiang 37, Chengdu 610041, China
Full list of author information is available at the end of the article



Livingstone infection have not been previously reported. Here, we report a case of giant splenic cyst infected by *S. Livingstone* in a previously healthy adolescent.

Case presentation

A 16-year-old male presented to the emergency department with abdominal pain and fever. He had no history of trauma nor exposure to echinococcosis. Twenty-two months ago, he had an abdominal ultrasound at a local hospital for health check, which revealed an 18.5 × 17.2 cm cystic mass in spleen. He had no symptoms and chose to neglect it. Six days ago, he was admitted to a local hospital due to sudden abdominal pain and high fever (39 °C) but without gastrointestinal symptoms. Abdominal computer tomography (CT) showed a 21 × 16 cm giant abscess in spleen (Fig. 1), and then a percutaneous drainage was performed. Purulent and bloody drainage was drained from the splenic abscess. After the drainage, he suffered from chest tightness and shortness of breath with decreased oxygen saturation and was transferred to our hospital.

On physical examination on admission, he looked acutely ill and his vital signs were: body temperature, 36.5 °C; heart rate, 94 beats/min; and respiratory rate, 24 breaths/min. Breath sounds in the lower left lung decreased. The right abdominal tenderness and rebound pain with muscle tension were noticed. Blood routine tests revealed elevated white blood cell (WBC) count of $26.08 \times 10^9/L$ (neutrophils, 93.9%) and platelet count of $358 \times 10^9/L$ and slightly lower hemoglobin of 129 g/L (normal range, 130–175 g/L). Blood inflammatory markers were also elevated with 0.58 ng/mL procalcitonin (PCT; normal range, <0.046 ng/mL), 58 mm/h erythrocyte sedimentation rate (normal range, <21 mm/h), and 61.70 mg/L C-reactive protein (CRP) level (normal range,

<5 mg/L). Blood chemistry showed a slightly decreased serum albumin level of 37.8 g/L (normal range, 40.0–55.0 g/L) and increased total bilirubin of 85.3 μmol/L (normal range, 5.0–28.0 μmol/L) and direct bilirubin of 65 μmol/L (normal range, <8.8 μmol/L) but with normal alanine and aspartate aminotransferases. Results of serum tumor markers were 154 U/mL CA-199 (normal range, <30 U/mL), <1.5 U/mL CA-724 (normal range, <6.5 U/mL), 1.73 ng/mL CEA (normal range, <5 ng/mL), and 2.25 ng/mL AFP (normal range, <7 ng/mL). Serum tests for human immunodeficiency virus (HIV) was negative. Serum antibodies against parasites including *Echinococcus* spp., *Taenia solium*, and *Schistosoma* spp. were negative. The absolute count and the proportion of T-lymphocyte subsets were also normal. Aerobic and anaerobic bacterial cultures of stool and blood were performed on admission but turned to be negative.

Imipenem (500 mg every 8 h) were empirically given. A CT scan of the chest revealed consolidation in both lower lungs (Additional file 1: Fig. S1), while an abdominal CT showed a splenic abscess with a drainage tube and signs of peritonitis (Fig. 2a). Examinations of the drainage fluid from the spleen mass indicated $30 \times 10^6/L$ WBC, $16,700 \times 10^6/L$ red blood cells, decreased glucose level of 0.02 mmol/L, and increased lactic dehydrogenase of 4254 IU/L. The drainage fluid of the splenic abscess was cultured, from which a bacterial strain was recovered without other microorganisms. Preliminary species identification by Vitek II (bioMérieux, Marcy-l'Étoile, France) assigned the strain to the genus *Salmonella*. The strain was subjected to genome sequencing using a HiSeq X10 platform (Illumina, San Diego, CA, USA). Antigenic profiling, multi-locus sequence typing, identification of antimicrobial resistance genes, and plasmid replicon typing were performed using genome

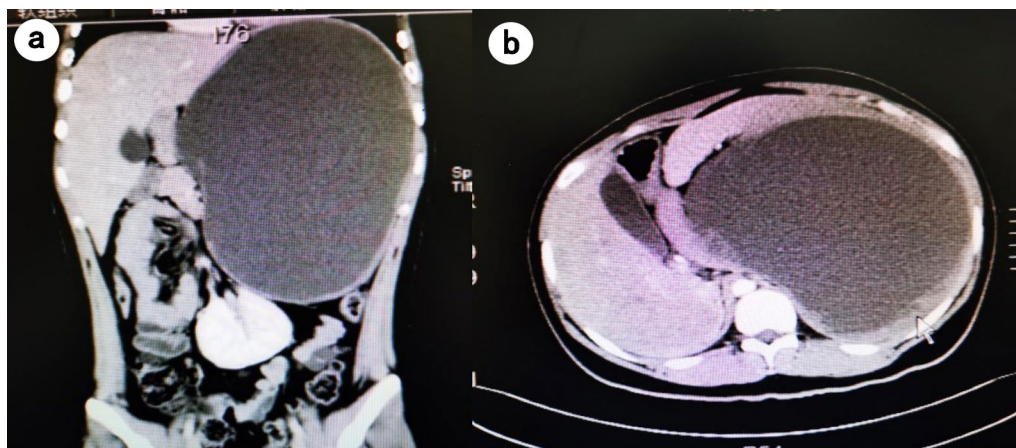


Fig. 1 Abdominal CT taken at the local hospital 6 days prior to admission showed a 21 × 16 cm giant abscess in spleen

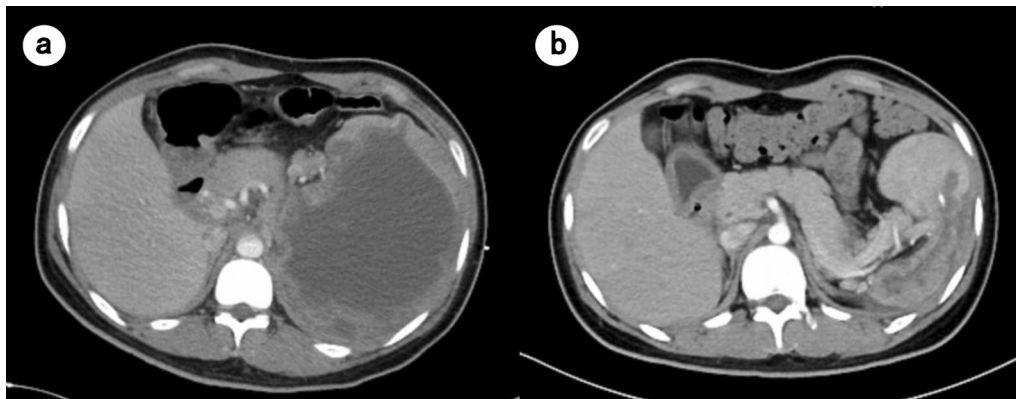


Fig. 2 Abdominal CT scan on admission showed giant cystic lesion within the spleen (a). A follow-up abdominal CT taken 42 days later exhibited that the abscess had significantly decreased (b)

analysis tools (SeqSero-1.2, MLST 2.0, ResFinder 4.1, and PlasmidFinder 2.1) available at Center for Genomic Epidemiology (<http://genomicepidemiology.org/>). Genome-based serotyping assigned the strain to *S. Livingstone* with an antigenic profile of 7:d:l,w (O antigen, O-7; H1 antigen, d; H2 antigen, l,w). Its draft genome sequence has been deposited in GenBank under accession no. JAG-HKU000000000. The strain belongs to sequence type 543 (allele profile, *aroC-dnaN-hemD-hisD-purE-sucA-thrA*, 117-135-18-12-162-162-38), carries a single antimicrobial resistance gene, *aac(6′)-Iaa*, mediating resistance to aminoglycosides, and has a single known plasmid replicon Col(pHAD28)_1_KU674895. Virulence factors of the strain was predicted by querying the Virulence Factors of Pathogenic Bacteria (VFDB, <http://www.mgc.ac.cn/cgi-bin/VFs/v5/main.cgi>). The strain carried multiple virulence factors including fimbrial adherence determinants *csf*, *bcf*, *fim*, *saf*, *stb*, *stc*, *std*, *ste*, *stf*, *sth*, *sti* and *stk*, macrophage inducible gene *mig-14*, magnesium transport genes *mgtB* and *mgtC*, nonfimbrial adherence determinants *misL*, *ratB*, *shdA* and *sinH*, genes for SP1- and SP2-encoding type III secretion systems (*hil*, *iac*, *inv*, *org*, *prg*, *sic*, *sip*, *sop*, *spa*, *spi*, *sprB*, *spv*, *ssa*, *ssc*, *sse*, *ssr*), and afimbrial adhesin-encoding *afaB* and *afaC* (Additional file 2: Table S1). The strain was susceptible to third-generation cephalosporins, carbapenems and fluoroquinolones as determined using Vitek II (bioMérieux). Splenic abscess due to splenic cyst with *S. Livingstone* infection was diagnosed.

He received imipenem (500 mg every 8 h) for 10 days and then ceftazidime-sulbactam (3 g every 8 h) for 30 days. About 500 mL bloody pus was drained from the splenic abscess daily. One month later, the spleen drainage tube was removed since no drainage fluid had been observed for 1 week. The abscess had significantly

decreased according to the abdominal CT taken 42 days later (Fig. 2b). The patient recovered well and had no recurrent symptoms during the follow-up.

Discussion and conclusions

Salmonellosis due to *S. Livingstone* in human is uncommon and giant splenic cysts complicated with *S. Livingstone* infection have not been previously reported. The most common clinical presentation of *S. Livingstone* infection was gastroenteritis [11]. *S. Livingstone* did not cause bacteremia due to the absence of the *spv* genes but could invade the adjacent organs from the intestine [14]. For splenic abscess, the most common clinical manifestations are fever, abdominal pain, left upper abdominal tenderness and splenomegaly [15], as seen in this case. Splenic cysts may act as a predisposing factor for splenic abscess. Many previous studies have shown that congenital epidermoid and mesothelial cysts are associated with increased CA-199 [1]. We did not have histopathological confirmation of splenic epithelioid cyst in this case. However, in light of his age, history, and significantly elevated serum CA-199, the most likely diagnosis was splenic abscess due to epidermoid cyst with *S. Livingstone* infection.

Like most NTS, *S. Livingstone* causes diseases mainly in individuals with underlying factors such as the immunocompromised status [16]. Patients with HIV infection, malnutrition, malaria, or inherited immunodeficiencies including chronic granulomatous diseases, sickle-cell diseases and B-cell deficiencies are at increased risks for invasive NTS (iNTS) diseases such as bacteremia and meningitis [17–19]. Host susceptibility to iNTS diseases varies significantly among individuals, and currently-available studies have focused on primary immunodeficiencies. The innate and acquired

immune systems help the host to control of invasive *Salmonella* infection [20–23]. In addition, genetic variations may lead to susceptibility to different *Salmonella* species [20]. Although our patient did not have apparent immune deficiency, it cannot be excluded that he had genetic factors predisposing to the NTS infection.

Splenectomy was previously considered the gold standard for the treatment of splenic abscess [24]. However, recent studies have shown that percutaneous drainage combined with antimicrobial agents could be a better treatment option. Therapeutic splenectomy was required in only about 20% of patients [25, 26]. Splenectomy may lead to presumptive immune deficiency and increase the risk of bacterial infections and therefore should be avoided, especially in children. Percutaneous image-guided splenic intervention has also been found safer than splenectomy [27]. Splenic abscess could be single or multiple, with diameters ranging from 1 to 23 cm [28, 29]. Percutaneous aspiration and drainage have usually been performed in patients with a splenic abscess less than 10 cm in diameter [25, 30], while percutaneous drainage was successfully treated in this case with a spleen abscess of 21 cm in diameter. The most common complication of splenic intervention is hemorrhage [27]. The purulent and bloody drainage was initially drained from the splenic abscess of this case, which may reflect hemorrhage. Nonetheless, his drainage fluid became purulent and he had no bloody fluid after 10 days of drainage. Therefore, large unruptured splenic abscesses may be treated with percutaneous aspiration and drainage, while salvage splenectomy could be considered if other treatments fail. As for splenic cysts, different management approaches can be selected according to the clinical situation of the patient in the future, including percutaneous drainage, partial splenectomy, splenectomy, total cystectomy, laparoscopic decapsulation, marsupialization or cyst unroofing [4, 31]. Preserving splenunculus therapy, rather than splenectomy, may be preferred due to the immune function of the spleen.

In conclusion, splenic cyst can be complicated with *S. Livingstone* infection, resulting in splenic abscess, even in previously healthy adolescents. Percutaneous drainage and appropriate antimicrobial therapy can be used to treat large splenic abscess. This case of a previously healthy adolescent may help clinicians to raise awareness of splenic abscess and highlights the importance of drainage and antimicrobial agents to avoid splenectomy.

Abbreviations

AFF: Alpha fetoprotein; CA: Carbohydrate antigen; CEA: Carcinoma embryonic antigen; CRP: C-reactive protein; CT: Tomography; HIV: Human immunodeficiency virus; iNTS: Invasive non-typhoidal *Salmonella*; NTS: Non-typhoid *Salmonella*; PCT: Procalcitonin; WBC: White blood cell.

Supplementary Information

The online version contains supplementary material available at <https://doi.org/10.1186/s12879-022-07529-6>.

Additional file 1: Figure S1. Chest CT on admission showed consolidation of lower lobes of both lungs (Panel a). Chest CT was normal after 20 days of antibacterial therapy (Panel b).

Additional file 2: Table S1. Virulence factors of the strain.

Acknowledgements

We are grateful for Lina Liu and Yu Feng, West China Hospital, Sichuan University for performing genome sequencing and analysis.

Author contributions

ZZ and JQ designed the study. JQ collected and interpreted the clinical data and drafted the manuscript. ZZ revised the manuscript. All authors read and approved the final manuscript.

Funding

The work was supported by a grant from West China Hospital of Sichuan University (1.3.5 project for disciplines of excellence, project no. ZYYC08006; and Grant No. 312190022). The funders had no role in study design, data collection and analysis, decision to publish, or preparation of the manuscript.

Availability of data and materials

Draft genome sequence of the strain has been deposited in GenBank under accession no. JAGHKU000000000. All other data are available in the text.

Declarations

Ethics approval and consent to participate

The investigation was approved by the Ethics Committee of West China Hospital, Sichuan University.

Consent for publication

The authors declare that the written informed consent for publication has been obtained from the patient's guardian.

Competing interests

The authors declare no conflict of interest.

Author details

¹Center of Infectious Disease, West China Hospital (Huaxi), Sichuan University, Guoxuexiang 37, Chengdu 610041, China. ²Center for Pathogen Research, West China Hospital, Sichuan University, Chengdu, China.

Received: 29 June 2021 Accepted: 10 June 2022

Published online: 18 June 2022

References

- Bresadola V, Pravisani R, Terrosu G, Risaliti A. Laparoscopic splenectomy as the definitive investigation for differential diagnosis of elevated serum CA 19-9 levels associated with a splenic cyst: case report and review of the literature. *J Surg.* 2013;1(1):6.
- Morgenstern L. Nonparasitic splenic cysts: pathogenesis, classification, and treatment. *J Am Coll Surg.* 2002;194(3):306–14.
- Garg M, Kataria SP, Sethi D, Mathur SK. Epidermoid cyst of spleen mimicking splenic lymphangioma. *Adv Biomed Res.* 2013;2:49.
- Ingle SB, Hinge Ingle CR, Patrike S. Epithelial cysts of the spleen: a minireview. *World J Gastroenterol.* 2014;20(38):13899–903.
- Ooi LL, Leong SS. Splenic abscesses from 1987 to 1995. *Am J Surg.* 1997;174(1):87–93.
- Liu YH, Liu CP, Lee CM. Splenic abscesses at a tertiary medical center in northern Taiwan. *J Microbiol Immunol Infect.* 2014;47(2):104–8.

7. Manzar N, Almuqamam M, Kaushik K, Dahabra L, Falcone M, Rimareva N, et al. Primary non-typhoidal *Salmonella* infection presenting as a splenic abscess in a healthy adolescent male. *Infez Med*. 2019;27(1):77–81.
8. Karia N, Lakhoo K. Complicated congenital splenic cyst: saved by a splenunculus. *Afr J Paediatr Surg*. 2011;8(1):98–100.
9. Koh CC, Wang NL, Lee HC, Duh YC. Infected congenital splenic cyst associated with duodenal duplication cyst and malrotation—a case report. *J Pediatr Surg*. 2007;42(12):e21–2.
10. Guillén S, Marcén M, Álvarez I, Mañas P, Cebrián G. Stress resistance of emerging poultry-associated *Salmonella* serovars. *Int J Food Microbiol*. 2020;335: 108884.
11. Guerin PJ, De Jong B, Heir E, Hasseltvedt V, Kapperud G, et al. Outbreak of *Salmonella* Livingstone infection in Norway and Sweden due to contaminated processed fish products. *Epidemiol Infect*. 2004;132(5):889–95.
12. Bouallègue-Godet O, Ben Salem Y, Fabre L, Demartin M, Grimont PA, Mzoughi R, et al. Nosocomial outbreak caused by *Salmonella enterica* serotype Livingstone producing CTX-M-27 extended-spectrum beta-lactamase in a neonatal unit in Sousse, Tunisia. *J Clin Microbiol*. 2005;43(3):1037–44.
13. Zhang H, Ye Y, Yang B, Gu Q, Zhu Y, Que F, et al. Characterization of an unusual foodborne illness including an outbreak and sporadic illness caused by three bacterial pathogens via a takeaway service. *Foodborne Pathog Dis*. 2019;16(9):616–21.
14. Guedda I, Taminiau B, Ferjani A, Boukadida J, Bertrand S, Daube G. Antimicrobial and molecular analysis of *Salmonella* serovar Livingstone strains isolated from humans in Tunisia and Belgium. *J Infect Dev Ctries*. 2014;8(8):973–80.
15. Liang JT, Lee PH, Wang SM, Chang KJ. Splenic abscess: a diagnostic pitfall in the ED. *Am J Emerg Med*. 1995;13(3):337–43.
16. Reilly WJ, Forbes GI, Sharp JC, Oboegbulem SI, Collier PW, Pater-son GM. Poultry-borne salmonellosis in Scotland. *Epidemiol Infect*. 1988;101(1):115–22.
17. Feasey NA, Dougan G, Kingsley RA, Heyderman RS, Gordon MA. Invasive non-typhoidal *Salmonella* disease: an emerging and neglected tropical disease in Africa. *Lancet*. 2012;379(9835):2489–99.
18. Graham SM, Walsh AL, Molyneux EM, Phiri AJ, Molyneux ME. Clinical presentation of non-typhoidal *Salmonella* bacteraemia in Malawian children. *Trans R Soc Trop Med Hyg*. 2000;94(3):310–4.
19. Bronzan RN, Taylor TE, Mwenechanya J, Tembo M, Kayira K, Bwanaisa L, et al. Bacteremia in Malawian children with severe malaria: prevalence, etiology, HIV coinfection, and outcome. *J Infect Dis*. 2007;195(6):895–904.
20. Gilchrist JJ, MacLennan CA, Hill AV. Genetic susceptibility to invasive *Salmonella* disease. *Nat Rev Immunol*. 2015;15(7):452–63.
21. de Beaucoudrey L, Samarina A, Bustamante J, Cobat A, Boisson-Dupuis S, Feinberg J, et al. Revisiting human IL-12Rβ1 deficiency: a survey of 141 patients from 30 countries. *Medicine*. 2010;89(6):381–402.
22. Raffatellu M, Santos RL, Verhoeven DE, George MD, Wilson RP, Winter SE, et al. Simian immunodeficiency virus-induced mucosal interleukin-17 deficiency promotes *Salmonella* dissemination from the gut. *Nat Med*. 2008;14(4):421–8.
23. Cunnington AJ, de Souza JB, Walther M, Riley EM. Malaria impairs resistance to *Salmonella* through heme- and heme oxygenase-dependent dysfunctional granulocyte mobilization. *Nat Med*. 2011;18(1):120–7.
24. Smyrniotis V, Kehagias D, Voros D, Fotopoulos A, Lambrou A, Kostopaniagiotou G, et al. Splenic abscess. An old disease with new interest. *Dig Surg*. 2000;17(4):354–7.
25. Alvi AR, Kulsoom S, Shamsi G. Splenic abscess: outcome and prognostic factors. *J Coll Physicians Surg Pak*. 2008;18(12):740–3.
26. Divyashree S, Gupta N. Splenic abscess in immunocompetent patients managed primarily without splenectomy: a series of 7 cases. *Perm J*. 2017;21:16–139.
27. Sammon J, Twomey M, Crush L, Maher MM, O'Connor OJ. Image-guided percutaneous splenic biopsy and drainage. *Semin Intervent Radiol*. 2012;29(4):301–10.
28. Lee HW, Han SB. Large splenic abscess caused by non-typhoidal *Salmonella* in a healthy child treated with percutaneous drainage. *Children*. 2020;7(8):88.
29. Comarmond C, Jauréguiberry S, Vaillant JC, Lecso M, Bricaire F, Caumes E. Giant splenic abscess due to *Salmonella enteritidis* in a returning traveler. *J Travel Med*. 2010;17(4):271–3.
30. Zerem E, Bergsland J. Ultrasound guided percutaneous treatment for splenic abscesses: the significance in treatment of critically ill patients. *World J Gastroenterol*. 2006;12(45):7341–5.
31. Termos S, Othman F, Aljewaied A, Alkhalil AM, Alhunaidi M, Parayil SM, et al. Symptomatic giant primary nonparasitic splenic cyst treated with laparoscopic decapsulation: a case report and literature review. *Am J Case Rep*. 2020;21: e927893.

Publisher's Note

Springer Nature remains neutral with regard to jurisdictional claims in published maps and institutional affiliations.

Ready to submit your research? Choose BMC and benefit from:

- fast, convenient online submission
- thorough peer review by experienced researchers in your field
- rapid publication on acceptance
- support for research data, including large and complex data types
- gold Open Access which fosters wider collaboration and increased citations
- maximum visibility for your research: over 100M website views per year

At BMC, research is always in progress.

Learn more biomedcentral.com/submissions

