

# Midgut Malrotation with Chronic Abdominal Pain

Anil K Wanjari, Arjun J Deshmukh, Parimal S Tayde, Yashwant Lonkar

Department of Medicine, Jawaharlal Nehru Medical College, Datta Meghe Institute of Medical Sciences, Sawangi, Wardha, Maharashtra, India

## Abstract

Abnormalities in midgut rotation occur during the physiological herniation of midgut between the 5<sup>th</sup> and 10<sup>th</sup> week of gestation. The most significant abnormality is narrow small bowel mesentery which is prone to volvulus. This occurs most frequently in the neonatal period, less commonly midgut malrotation presents in adulthood with either acute volvulus or chronic abdominal symptoms. It is the latter group that represents a diagnostic challenge. We report a case of a 17-year-old male patient who presented with 10-year history of nonspecific gastro-intestinal symptoms. After extensive investigation the patient was diagnosed with midgut malrotation following computed tomography of abdomen. The patient was treated with a laparoscopic Ladd's procedure and at 3 months he was gaining weight and had stopped vomiting. A laparoscopic Ladd's procedure is an acceptable alternative to the open technique in treating symptomatic malrotation in adults. Midgut malrotation is a rare congenital anomaly which may present as chronic abdominal pain. Abdominal CT is helpful for diagnosis.

**Keywords:** Congenital, Malrotation, Midgut

**Address for correspondence:** Dr. Parimal S Tayde, Department of Medicine, Datta Meghe Institute of Medical Sciences, Sawangi, Wardha - 442 001, Maharashtra, India. E-mail: parimaltayde@yahoo.co.in

## Introduction

Malrotation of the midgut is an abnormality in embryological development of gastrointestinal tract.

By the fourth intrauterine week the gastrointestinal tract is in the form of an endoderm lined tube divided into fore, mid- and hindgut. Mid- and hindgut defined by their blood supply the superior and inferior mesenteric arteries respectively. By the fifth week of life the midgut begins a process of rapid enlargement, physiological herniation and rotation. With rapid expansion of liver and kidneys, expansion of the midgut intestinal loop cannot be contained within the abdominal cavity; this results in temporary physiological midgut herniation through the umbilical cord with superior mesenteric artery forming the axis.<sup>[1]</sup>

The midgut then rotates in stages 270° in counter clockwise direction. This process forms "C" of the duodenum and places it behind the superior mesenteric vessels.

Hernial reduction occurs by week 10 with the jejunum reducing first and lying to the left and subsequent distal portions lying progressively to the right. The caecum descends from position in the right upper quadrant forming the descending colon with its mesentery gradually disappearing.

## Case Report

A 17-year-old male was seen in the emergency department with 10-year history of abdominal colic which is relieved by vomiting, along with dehydration. There was no history of constipation over preceding few weeks. The patient had been vomiting on most morning with nausea persisting through the day. He had lost 2 kg in weight over previous 6 months. There was no history of jaundice, fever, steatorrhea, or bleeding per rectum. There was no other significant medical or surgical history.

The patient had been treated with proton pump inhibitors, prokinetic agents by general practitioners, without any

### Access this article online

#### Quick Response Code:



Website:  
www.najms.org

DOI:  
10.4103/1947-2714.94950

relief. His ultrasound examination and standing X-ray of abdomen had not shown any abnormality.

Physical examination was normal except minimal abdominal tenderness in epigastric, right hypochondriac region along with mild dehydration. His liver function tests, renal function tests, amylase, hemogram, and urinalysis were normal. Upper GI endoscopy was normal. A chest radiograph did not reveal air under the diaphragm.

CT abdomen with contrast was done. In the study stomach and duodenum appeared connected to small intestine seen on right side giving a whirlpool appearance due to rotation of gut around the superior mesenteric artery. Superior mesenteric vein was seen on left of superior mesenteric artery [Figures 1a and b]. Further distal bowel loops appeared collapsed. Thus the diagnosis of midgut malrotation with partial obstruction was confirmed.

Surgical referral was made; he was treated with four-port laparoscopic Ladd's procedure. The caecum was situated high with peritoneal bands passing across the duodenum. The peritoneum to the right of the ascending colon and caecum was incised and the anteriorly situated bands were stripped to free the duodenum. The colon was placed to the left of the abdomen.

He was discharged within 2 days eating a normal diet and made a good postoperative recovery. At 3 months he was gaining weight and had no further vomiting.

## Discussion

Midgut mal and nonrotation refers to failure in counter clockwise rotation of the midgut which results in misplacement of the duodeno-jejunal junction to

the right of the midline; in addition the small bowel mesentery has narrow vertical posterior attachment which is prone to volvulus.

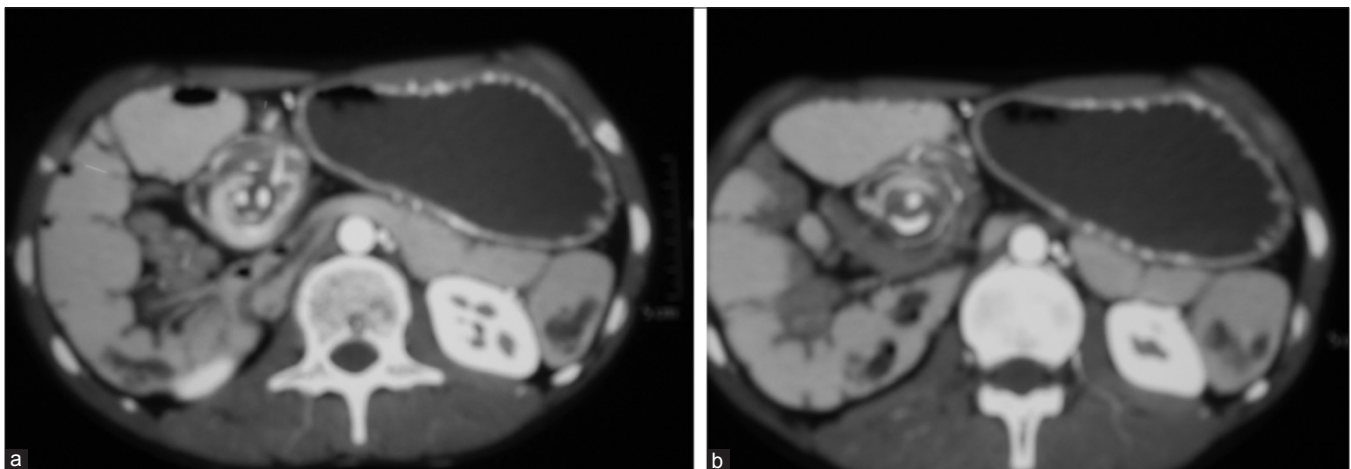
Other anatomical abnormalities include peritoneal (Ladd's) bands running from the right colon to the lateral abdominal wall and an extensively mobile caecum that fails to descend.

Malrotation can present as an acute surgical emergency or with more chronic abdominal symptoms.

Acute presentation is with volvulus of midgut or ileocecum occurring most frequently in neonate with likelihood decreasing with age.<sup>[2,3]</sup> In most of the reported cases of this presentation, patients present with bilious vomiting in the first month of life because of duodenal obstruction or a volvulus.

The chronic presentation is a diagnostic challenge. In most of the reported cases, the usual symptoms were crampy abdominal pain, nausea, vomiting, bloating. The symptoms may be nonspecific. Hence diagnostic delay is common. In a case series by Dietz *et al.*, the duration of symptoms extended as far as 30 years. Pathophysiology of these chronic symptoms may relate to the compressive effects of peritoneal bands running from caecum and ascending colon to the right lateral wall.

Diagnosis is made by imaging CT scan. The short mesentery allows the small bowel to twist around the narrowed SMA pedicle to create a distinctive "whirlpool" appearance. This appearance is a diagnostic clue of malrotation. Another diagnostic clue is abnormal orientation of the superior mesenteric artery and vein relationship. The superior mesenteric vein lies abnormally to the left of the artery.



**Figure 1 (a-b):** Stomach and duodenum appear connected to small intestine seen on the right side giving a whirlpool appearance due to rotation of gut around the superior mesenteric artery. Superior mesenteric vein is seen on the left of superior mesenteric artery

Surgical management of intestinal malrotation was first described by Ladd in 1936 and remains mainstay<sup>[4,5]</sup> of management today. It involves reduction of volvulus if present, division of abnormal peritoneal bands (duodeno colic, duodenojejunal-ileocolic), and placement of the small bowel to the right of the abdomen and cecum to the left. Appendectomy is also performed as patients may present with appendicitis.<sup>[6]</sup>

Increasingly laparoscopic Ladd's procedures are being performed and have been shown to be effective where there is no acute volvulus.<sup>[7-9]</sup>

This minimally invasive approach allows for earlier oral intake and discharge from hospital.

## References

1. Sadler TW, Langman J. Langman's Medical Embryology. 9<sup>th</sup> ed. Philadelphia, PA: Lippincott Williams and Wilkins; 2004:304-7.
2. Prasil P, Flageole H, Shaw KS, Nguyen LT, Youssef S, Laberge JM. Should malrotation in children be treated differently according to age? J Pediatr Surg 2000;35:756-8.
3. Spigland N, Brandt ML, Yazbeck S. Malrotation presenting beyond the neonatal period. J Pediatr Surg 1990;25:1139-42.
4. Von Flue M, Herzog U, Ackermann C, Tondelli P, Harder F. Acute and chronic presentation of intestinal nonrotation in adults. Dis Colon Rectum 1994;37:192-8.
5. Ladd WE. Congenital obstruction of the duodenum in children. N Engl J Med 1932;206:273-83.
6. Kamiyama T, Fujiyoshi F, Hamada H, Nakajo M, Harada O, Haraguchi Y. Left-sided acute appendicitis with intestinal malrotation. Radiat Med 2005;23:125-7.
7. Seymour NE, Andersen DK. Laparoscopic treatment of intestinal malrotation in adults. JSLS 2005;9:298-301.
8. Frantzides CT, Cziperle DJ, Soergel K, Stewart E. Laparoscopic Ladd procedure and cecopexy in the treatment of malrotation beyond the neonatal period. Suenebrg Laparosc Endosc 1996;6:73-5.
9. Matzke GM, Dozois EJ, Larson DW, Moir CR. Surgical management of intestinal malrotation in adults: Comparative results for open and laparoscopic Ladd procedures. Surg Endosc 2005;19:1416-9.

**How to cite this article:** Wanjari AK, Deshmukh AJ, Tayde PS, Lonkar Y. Midgut malrotation with chronic abdominal pain. North Am J Med Sci 2012;4:196-8.

**Source of Support:** Nil. **Conflict of Interest:** None declared.