

CASE REPORT

Ortho-surgical management of a Conradi–Hünemann syndrome patient: rare case report

Leopoldino Capellozza Filho¹, Mauricio de Almeida Cardoso¹, Eduardo José Caldeira², Anderson Capistrano³, Aldir da Silva Cordeiro³ & Diógenes Rocha⁴

¹Graduation and Post Graduation Program (Specialization and MSc degrees) in Orthodontics, Sacred Heart University, USC, Bauru, São Paulo, Brazil

²Department of Morphology and Basic Pathology, Faculty of Medicine of Jundiaí, FMJ, Jundiaí, São Paulo, Brazil

³Department of Orthodontics, Sacred Heart University USC, Bauru, São Paulo, Brazil

⁴Surgical Clinics, School of Medicine, University of São Paulo, USP, São Paulo, Brazil

Correspondence

Leopoldino Capellozza Filho
Sacred Heart University, USC, Bauru São Paulo, Brazil.
E-mail: lcapellozza@yahoo.com.br

Funding Information

No sources of funding were declared for this study.

Received: 15 November 2014; Revised: 31 March 2015; Accepted: 12 May 2015

Clinical Case Reports 2015; 3(8): 694–701

doi: 10.1002/ccr3.307

Key Clinical Message

The Conradi–Hünemann Disease is a rare syndrome, which affects the cranial development and the anatomy of dental occlusion. After interdisciplinary treatment completion, the patient reached satisfactory facial anatomy, as well as regular occlusal relationship, attested 2 years of accompaniment.

Keywords

Conradi–Hünemann syndrome, facial anatomy, multidisciplinary approach, treatment.

Introduction

Syndrome

The Conradi–Hünemann syndrome is a X-linked dominant uncommon genetic disarray that provokes skeletal malformations, skin diseases, cataracts, and alterations of body growing [1–3]. Alterations in the emopamil-binding protein (EBP) can promote the X-conjugated dominant chondrodysplasia punctata 2 (CDPX2). Finally, the mutation can be confirmed also by EBP presence that leads to the creation of CDPX2 [4].

The gravity of this disease may be different between patients. Surgically, the Conradi–Hünemann syndrome was standardized by the formation of small-hardened dots of calcium on the bone parts or inside of cartilaginous structures. This condition is associated with the irregular proportion and shortening of long bones, mainly, in the proximal part of humerus and femur, uncommon spine curvatures, and general growth deficiency, resulting in altered stature. In addition, other study also shows,

patients with prominent forehead, facial hypoplasia, low nasal bridge, cataracts, sparse body hair, thick scalp hair and scaling of the dry skin [5].

Thus, we show a rare dental interest case of a female patient with severe malocclusion, intensified by Conradi–Hünemann syndrome that was treated by means of orthodontic-surgical procedures.

Case Report

Diagnosis and etiology

The case was first referred to an Orthodontic Center in June, 2002. She was 6 years and 8 months old, with typical case of anterior crossbite. She was determined to mandibular prognathism with mild mandibular shift to the left, maxillary deficiency, and potential involvement with a syndrome. The patient was referred to a cosmetic surgeon who, together with a geneticist, confirmed the diagnosis of Conradi–Hünemann syndrome. All procedures were performed according to Ethical Guidelines.

After initial examinations and interventions, the syndrome was confirmed mainly by the presence of chondrodysplasia punctata. Clinically calcifications in long bones, general skeletal malformation, skin diseases, cataract, and low stature, similar to the ones described in the literature were observed in this female case [5–7].

Following, the patient was subjected to a protocol for monitoring the growth and development of the dental occlusion. She was accompanied once a year so as to determine the best time for treatment. This intervention is indicated not only to handle patient's esthetic and functional complaints but also to overcome potential difficulties related to irruption and construction of permanent denture. The treatment is best performed when these cautions are previously executed.

At the end of this monitoring period, the patient, with permanent dentition, was assessed for decompensation treatment. Preparation for orthognathic surgery also was performed. At this stage, the patient presented class III skeletal malocclusion caused by mandibular prognathism associated with maxillary deficiency and consequent concave profile severed by mandibular shift to the left (Fig. 1A and B).

The intraoral examination confirmed the class III molar relationship and left posterior crossbite. As a consequence of laterognathism, she presented lower midline shift with 5 mm to the left, occlusal plane shift, and severe open

bite also on the left side, where was observed occlusal contact only between second molars (Figs. 1C–E and 2A–E). The cephalometric radiograph revealed a convex profile ($\text{NAPog} = -3^\circ$), a class III skeletal malocclusion ($\text{ANB} = -3^\circ$), proclined ($1.\text{NB} = 29^\circ$) and protrusive ($1.\text{NB} = 7\text{mm}$) mandibular incisors, as well as proclined maxillary incisors ($1.\text{NA} = 28^\circ$) (Fig. 3A). Panoramic radiograph showed four-third molars, of which extraction was indicated before orthognathic surgery (Fig. 3B). The carpal radiograph was used to assess the bone age. The method developed by Haag and Taranger [8] revealed that the patient was at stage II (capping of epiphysis with radius diaphysis), the perfect time for orthodontic treatment onset. The duration of this orthodontic treatment would be enough to achieve the stage J, thus allowing the next surgical phase.

Treatment parameters

After evaluation and analysis of patient's records, the person and her family were informed about the need of a surgical treatment. The possibility of an alternative treatment plan was considered infeasible due to limitations imposed by the syndrome and due to asymmetry and severity of the malocclusion. Furthermore, the uncertain prognosis for posttreatment stability was also under discussion.

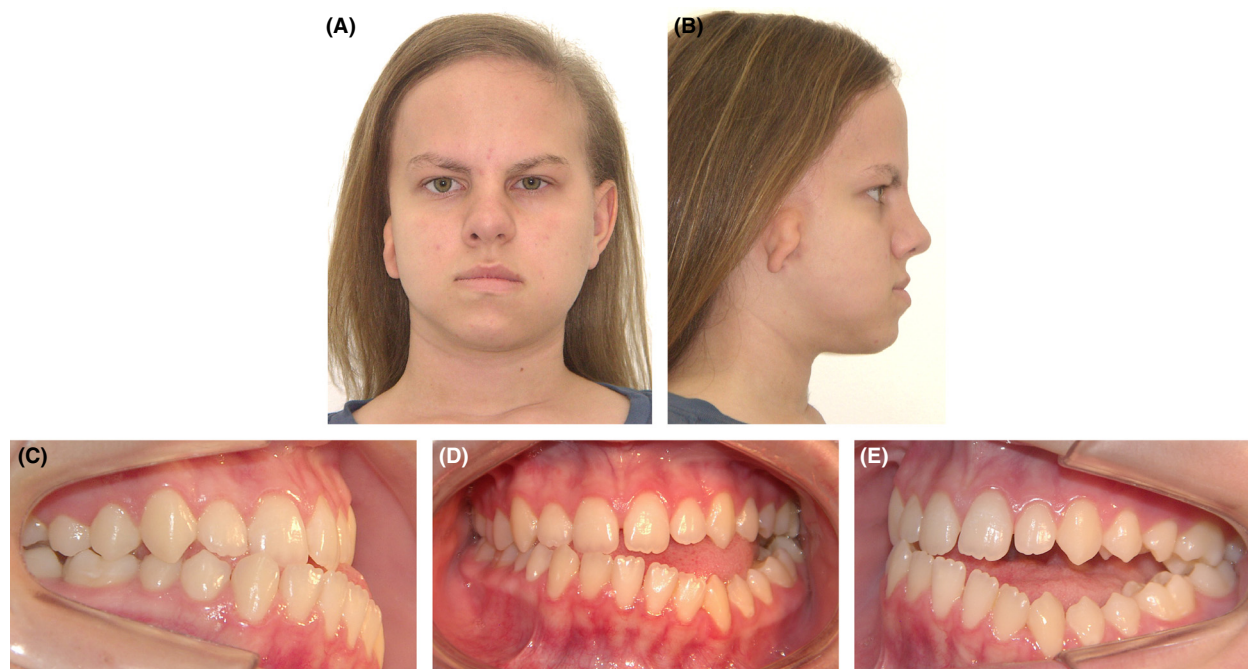


Figure 1. Photography of pretreatment period: facial (A and B) and intraoral examination (C–E).

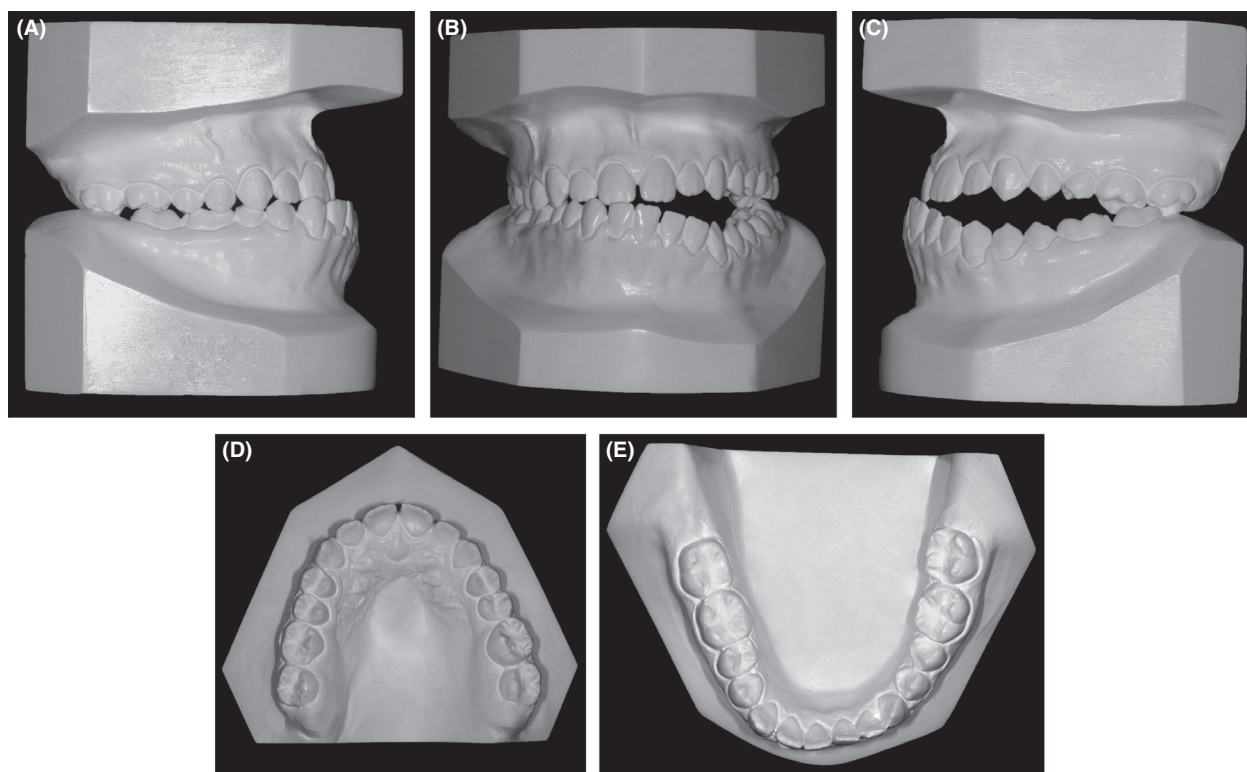


Figure 2. Photography of pretreatment period: dental casts (A–E).

Afterward, treatment parameters were established as follows:

- 1 Correction of sagittal discrepancy and mandibular shift;
- 2 Bilateral correction of molar and canine relationships;
- 3 Correction of lower midline shift;
- 4 Attainment of proper incisor relationship;
- 5 Correction of crossbite on the left side;
- 6 Attainment of proper vertical relationship on the posterior left side;
- 7 Correction of severe open bite and occlusal plane.

The primary focus of procedure was to provide the improvement of the facial function and esthetics, and, as a result, enhance her self-esteem and quality of life.

Treatment progress

The treatment was started after achieving the IJ stage, when the patient was 14 years and 10 months old.

Initially, a fixed orthodontic appliance was mounted by means of the Straight Wire technique (*Capelloza Prescription*: Standard I, Abzil 3M – 0.022 × 0.028 in slot) in both maxillary and mandibular arches. Mandibular incisors were not included in order to allow leveling of right and left inferior posterior segments of the occlusal plane, without causing undesired movements. The segmental

posterior technique, allows the mandibular plane may be leveled without affecting the position of incisors. Once leveling of the posterior occlusal plane was achieved, the incisors were included in the appliance and in the occlusal plane. Extraction of lower third molars proved necessary to meet the treatment protocol in relation to bilateral sagittal split osteotomy.

The leveling and alignment were initially performed with the heat-activated *Niti* wires. Filaments with small diameter followed by *Steel* wires (018, 020, and 19 × 25) were used in coordination. Once the surgical procedure was defined, bonding of mandibular incisors was performed with a 016 *Titanal XR* wire used as overlay for alignment of these teeth. *Steel* wires were progressively installed until 19 × 25 wires. One year and 5 months later of starting treatment, the patient was referred to surgical procedure. Le Fort I osteotomy was carried in maxillary, reaching 5-mm advancement, 4-mm anterior lowering, and the leveling of occlusal plane was obtained with autograft in areas with bone loss. Sagittal mandibular osteotomy with advancement, rotation, and leveling was also performed to correct the malocclusion, whereas subapical osteotomy of the menton with 7-mm advancement and rotation was performed out to achieve the general alignment. After orthognathic surgery (Figs. 4A–C,

5A1–A8, B1–B5 and 6A and B), the patient was referred to speech training, as well as, physiotherapy.

Final results

The posttreatment record reveals that treatment parameters were achieved. The maxillary and mandibular osteotomies resulted in a straight facial profile with passive labial seal, a pleasant smile, proper sagittal relationship, and canines and molars with class I relation, as well as proper overbite and overjet. Transversal and vertical relations to the left, as well as the mandibular asymmetry were corrected (Figs. 7 and 8A–C, D, and F).

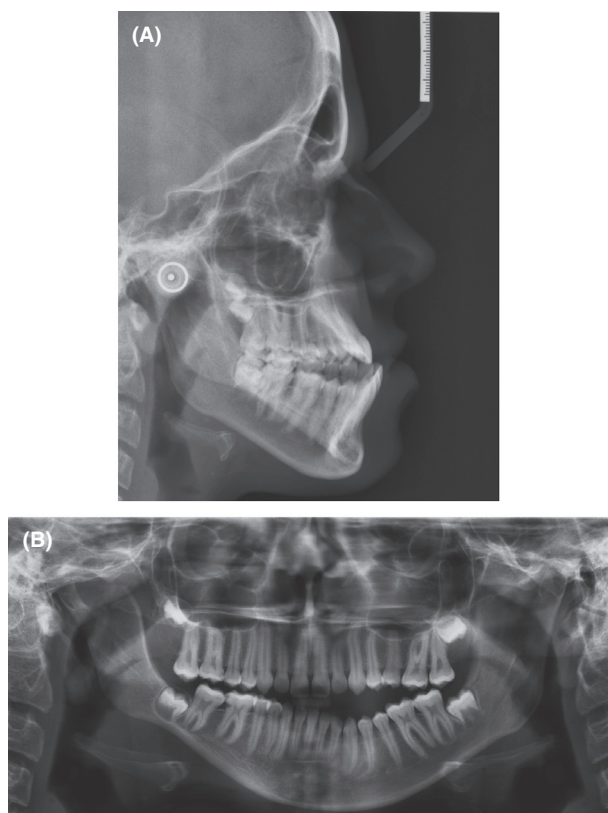


Figure 3. Photography of pretreatment period. Radiographic images: lateral cephalometric radiograph (A) and panoramic radiograph (B).

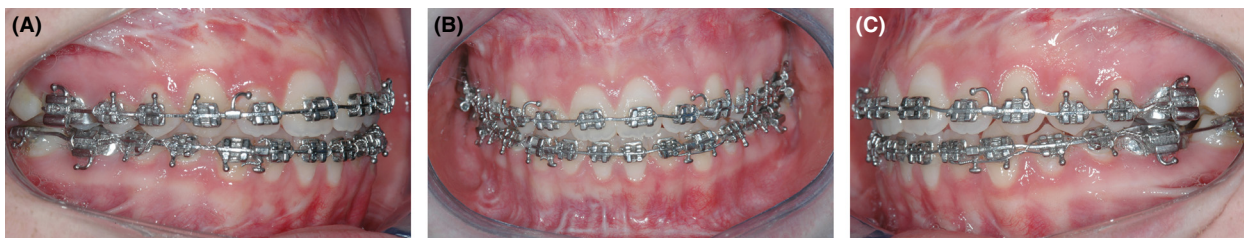

Figure 4. Intraoral photography after orthognathic surgery (A–C).

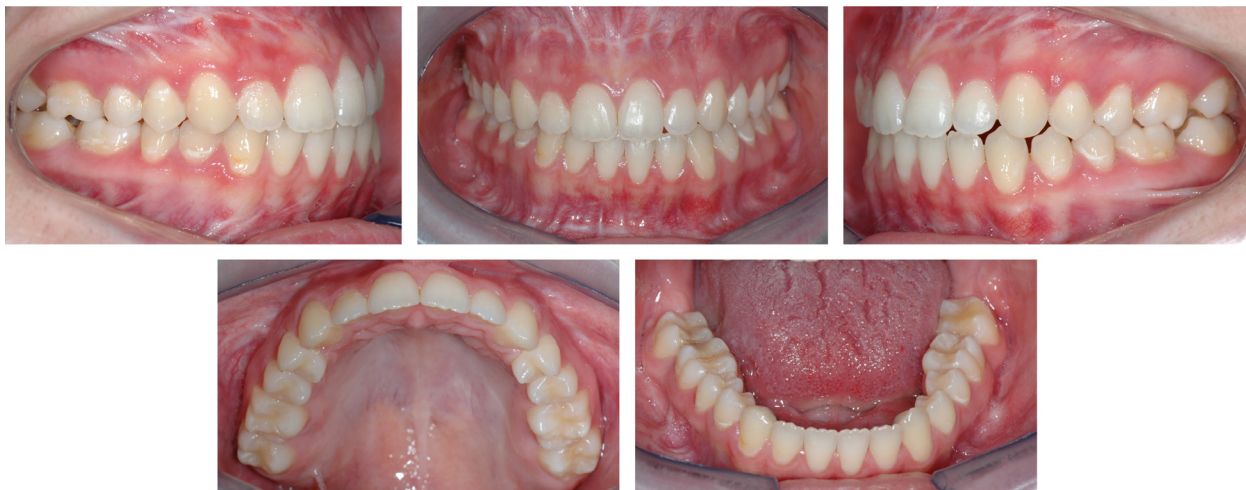Cephalometric radiographs confirmed patient's facial outcomes with normal NAPog and ANB values. In the same way, the position of incisors also yielded normal results (Fig. 6A). Treatment lasted for 2 years and 2 months. Treatment results were considered satisfactory from an esthetic and functional point of view (Figs. 6A and B, and 8A–H).

Discussion

Orthodontic treatment of syndromic patients is a major challenge for orthodontists, given that correction involves a wide range of factors. Nearly 1% of infants have multiple anomalies or congenital disorders, of which 40% are diagnosed as syndromes [9]. Syndromes are associated with different levels of facial and occlusal asymmetry [10]. An asymmetry becomes more evident in cases of syndromes caused by chromosome defects, as it is the case of Conradi–Hünemann disease. This condition is inherited as an X-linked dominant trait. It is also known as chondrodysplasia punctata 2 (CDPX2; MIM 302960), described between 1977 and 1981 as a severe genetic defect [1–4]. The symptoms vary of fetal death, multiple malformation, and delayed growth. About 95% of individuals affected by the syndrome are women who present linear ichthyosis, chondrodysplasia punctata, cataract, and alterations in the stature [11].

When the syndromic patient is born, ectodermal alterations are present with severe erythroderma and flaky skin that generally disappears after the first months of life, when then the individual is left with hypo- or hyperpigmentation as well as alopecia affecting the scalp, in addition to arms and legs. The patient's nail is flattened and cracked, whereas teeth remain unaltered. In addition, punctiform calcifications in the region of the epiphysis that generally result in asymmetric foreshortening of long bones and short stature, scoliosis, hip luxation, and facial dysplasia [7]. Despite all these complications, this syndrome in most cases is not lethal. In general, according to literature since the 70's until 2007 about 81 cases of chondrodysplasia punctata were reported in the world, including Brazil, North America, Europe, and other coun-

(A)



(B)

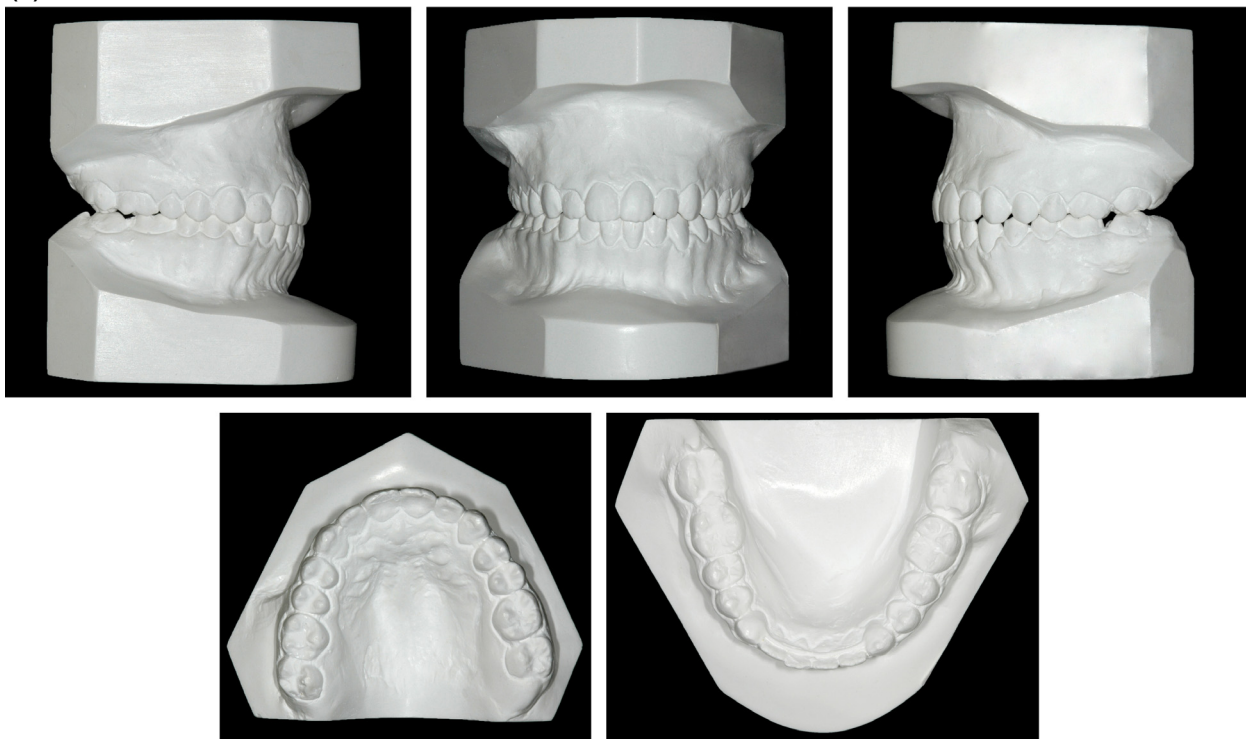


Figure 5. Photography of post treatment facial (A1–A3) and intraoral views (A4–A8); and dental casts (B1–B5).

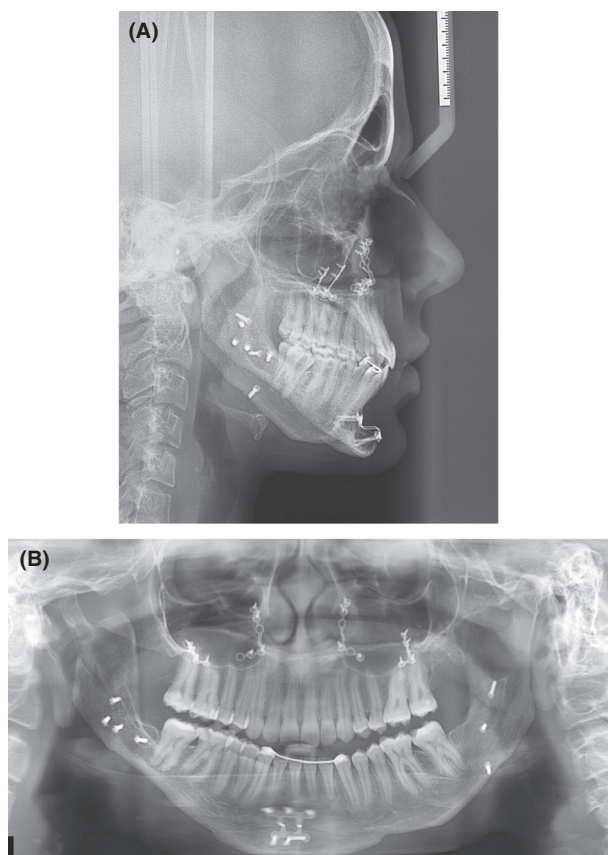


Figure 6. Photography of post treatment radiographs: lateral cephalogram (A); panoramic radiograph (B).

tries. According to some studies, the ratio of females to males is 36:0 [12–16].

In the present case, the challenge began with the attempt to understand whether the syndrome provokes alterations in the patient's stomatognathic system and how it occurs, which is essential not only to establish the treatment plan but also to avoid a dubious prognosis.

The patient was submitted to the first examination with a 6-year-old, when she already had a concave facial profile, mid-face deficiency, mandibular asymmetry, and malocclusion.

In this case, doubts can occur, because mandibular asymmetries seem to depend on other etiologies, as are genetically associated to environmental factors for example. Such asymmetries do not seem to be directly associated with the anatomical shape of the face or temporomandibular joint. Nevertheless, after studying an extensive collection of skulls, Dumas and Moaddab [17] showed differences in left and right temporomandibular joints, which are common also in syndromic and in not syndromic cases. Complementing, Wedel *et al.* [18] showed that these stomatognathic alterations could be caused also by considerable masticatory stress. These findings show the complexity of the syndromic cases.

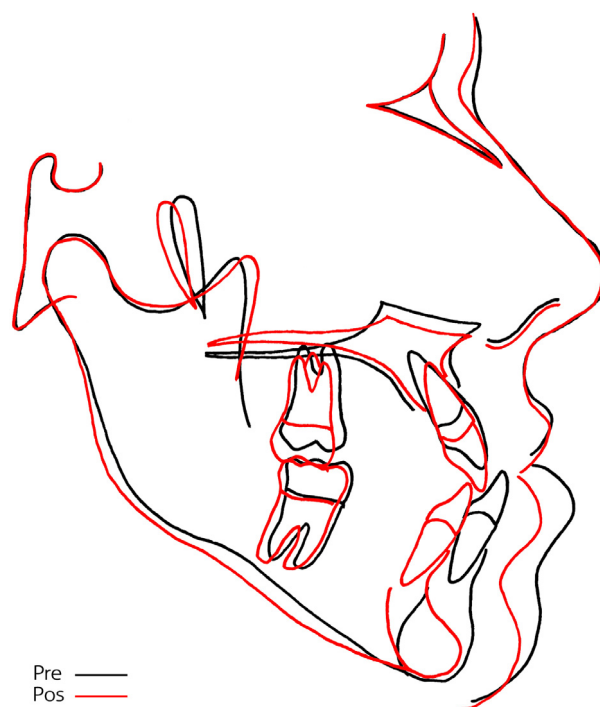


Figure 7. Photography of cephalometric tracing at pretreatment (black line) and posttreatment (red line).

According to Melnik [19], asymmetries are a common phenomenon, and depend on patient's age and sex. Melnik, also reports that 5–10% of 12-year-old children present asymmetries greater than 5-mm. Furthermore, asymmetries associated with congenital disorders that affect the mandibulofacial region are progressive, which, in fact, occurred with our patient during the monitoring period. In the patient present, is also important to note, that the orthodontic preparation began after the complete pubertal growth according to the literature. The major drawback of this standby period was the increase in the malocclusion, especially open bite and occlusal plane discrepancies. Such fact raised some concern over a potential relapse, which was thoroughly explained to the patient and her family.

Relapse after an orthodontic-surgical procedure is considered a change in the position of skeletal segments in response to unbalanced forces. These unbalanced forces may affect the dimension and biomechanics of the stomatognathic system. In this context, any force affecting postoperative stability must be avoided. Moreover, the surgical technique, the material used for fixation, and the number of bones involved are very important to minimize the problem [20].

The class III malocclusion is the anomaly most commonly corrected by combined orthognathic surgery [21, 22]. This malocclusion has been historically treated by

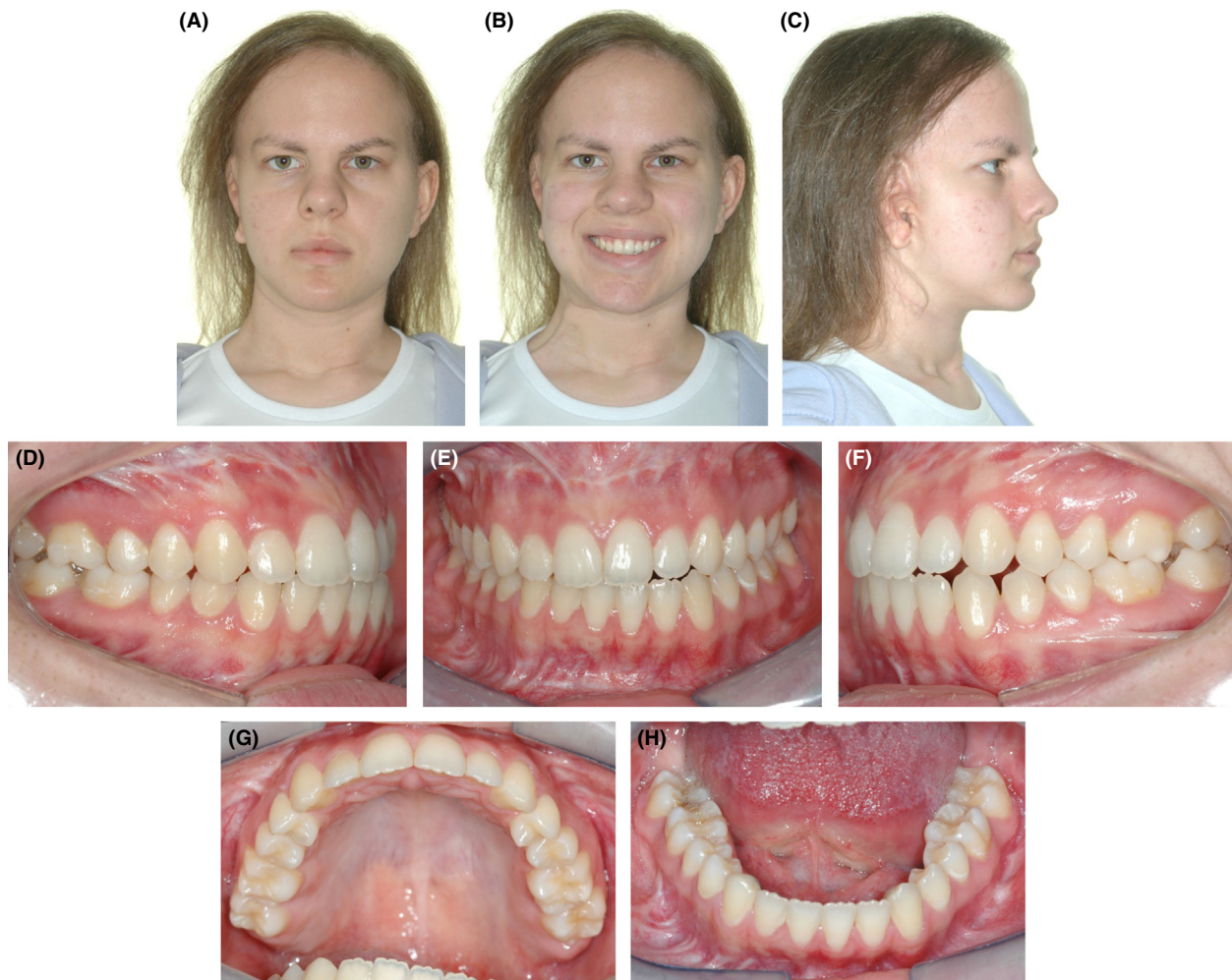

Figure 8. Photograph of patient after 2 years follow-up posttreatment: facial (A–C) and intraoral images (D–H).

isolated mandibular setback. However, bimaxillary procedures also have been frequently employed [23, 24]. The postoperative stability also varies with the direction and amount of surgical movements. The maxillary advancement is more stable than mandibular setback. Furthermore, relapses are more likely to occur during the first 6 months after surgery [25].

With all these factors well known, retainers were installed after orthognathic surgery and the patient was referred to speech training and physiotherapy so as to minimize a potential relapse. Two years after the completion of treatment, the patient went back to the treatment center to observe the possible relapses and general conditions.

Conclusion

Orthodontic treatment of patients with severe malocclusions worsened by syndromes must be very well planned and performed by an interdisciplinary team able to

identify the best moment for treatment onset. Additionally, together with the patient, the team must be able to accept potential relapses in the long term. Anyway after the completion of treatment, the patient reached satisfactory facial anatomy, as well as regular occlusal relationship, attested 2 years of accompaniment, which demonstrating the therapy choice can contribute to the reestablishment of morphology and function of this rare occurrence.

Acknowledgments

We thank the patient and her family for their involvement with the treatment and consent to publish this case report, and all the members who were involved in her treatment.

Conflict of Interest

None declared.

References

- Braverman, N., P. Lin, F. F. Moebius, C. Obie, and A. Moser, H. Glossmann, *et al.* 1999. Mutations in the gene encoding 3 beta-hydroxysteroid-delta 8, delta 7-isomerase cause X-linked dominant Conradi-Hünemann syndrome. *Nat. Genet.* 22:291–294.
- Sutphen, R., M. J. Amar, B. G. Kousseff, *et al.* 1995. XXY male with X-linked dominant chondrodysplasia punctata (Happle syndrome). *Am. J. Med. Genet.* 57:489–492.
- Gobbelo, T., C. Mazzanti, P. Fileccia, *et al.* 1995. X-linked dominant chondrodysplasia punctata (Happle syndrome) with uncommon symmetrical shortening of the tubular bones. *Dermatology* 191:323–327.
- Happle, R., A. König, K. H. Grzeschik. 2000. Behold the CHILD, it's only one: CHILD syndrome is not caused by deficiency of 3 beta-hydroxysteroid- Delta 8, Delta 7-isomerase. *Am. J. Med. Genet.* 94:341–343.
- Furtado, L. V., P. Bayrak-Toydemir, B. Hulinsky. 2010. A novel X-linked multiple congenital anomaly syndrome associated with an EBP mutation. *Am. J. Med. Genet. A* 152A:2838–2844.
- Offiah, A. C., S. Mansour, I. Jeffrey. 2003. Greenberg dysplasia (HEM) and lethal X linked dominant Conradi-Hünemann chondrodysplasia punctata (CDPX2): presentation of two cases with overlapping phenotype. *J. Med. Genet.* 40:e129.
- Aughton, D. J., R. I. Kelley, A. Metzner. 2003. X-linked dominant chondrodysplasia punctata (CDPX2) caused by single gene mosaicism in a male. *Am. J. Med. Genet.* 116A:255–260.
- Hagg, U., and J. Taranger. 1982. Maturation Indicators and the pubertal growth spurt. *Am. J. Orthod. Dent. Orthop.* 82:299–309.
- Marden, P. M., D. W. Smith, M. J. McDonald. 1964. Congenital anomalies in the newborn infant including minor variations. *J. Pediatr.* 64:357–371.
- Pirttiniemi, P. M. 1994. Associations of mandibular and facial asymmetries – a review. *Am. J. Orthod. Dent. Orthop.* 108:191–200.
- Cristina, H., B. T. Leena, M. Dietmar. 2000. The Conradi-Hünemann- Happle syndrome (CDPX2) and emopamil binding protein: novel mutations and somatic and gonadal mosaicism. *Hum. Mol. Gen.* 9:1951–1955.
- Vogel, T. W., and A. H. Menezes. 2012. Natural history and management of cervical spine disease in chondrodysplasia punctata and coumarin embryopathy. *Childs Nerv. Syst.* 28:609–619.
- Connor, J. M., R. A. Connor, E. M. Sweet, A. A. Gibson, W. J. Patrick, M. B. McNay, *et al.* 1985. Lethal neonatal chondrodysplasias in the West of Scotland 1970–1983 with a description of a thanatophoric, dysplasia-like, autosomal recessive disorder, Glasgow variant. *Am. J. Med. Genet.* 22:243–253.
- Pascolat, G., J. L. Zindeluk, K. C. Abrão, F. M. Rodrigues, C. I. Guedes. 2003. Rhizomelic chondrodysplasia punctata - case report. *J. Pediatr. (Rio J.)* 79:189–192.
- Shanske, A. L., L. Bernstein, R. Herzog. 2007. Chondrodysplasia punctata and maternal autoimmune disease: a new case and review of the literature. *Pediatrics* 120:e436–e441.
- Happle, R. 1979. X-linked dominant chondrodysplasia punctata. Review of literature and report of a case. *Hum. Genet.* 53:65–73.
- Dumas, A. L., and M. B. Moaddab. 1986. A three-dimensional developmental measurement of the temporomandibular joint. *J. Craniomand. Pract.* 4:22–35.
- Wedel, A., G. E. Carlsson, S. Sagne. 1978. Temporomandibular joint morphology in a medieval skull material. *Swed. Dent. J.* 2:177–187.
- Melnick, A. K. 1992. A cephalometric study of mandibular asymmetry in a longitudinally followed sample of growing children. *Am. J. Orthod. Dent. Orthop.* 101:355–366.
- Alavi, D. G., E. A. BeGole, B. J. Schneider. 1988. Facial and dental arch asymmetries in class II subdivision malocclusion. *Am. J. Orthod. Dent. Orthop.* 93:38–46.
- Bailey, L. J., L. H. Haltiwanger, G. H. Blakey. 2001. Who seeks surgical- orthodontic treatment: a current review. *Int. J. Adult. Orthod. Orthog. Surg.* 16:280–292.
- Espeland, L., H. E. Hogevoid, A. Stenvik. 2008. A 3-year patient centered follow-up of 516 consecutive orthognathic surgery patients. *Eur. J. Orthod.* 30:24–30.
- Bailey, L. J., W. R. Proffit, R. P. White, Jr. 1995. Trends in surgical treatment of class III skeletal relationships. *Int. J. Adult. Orthod. Orthog. Surg.* 10:108–118.
- Johnston, C., D. Burden, D. Kennedy, N. Harradine, M. Stevenson. 2006. Class III surgical-orthodontic treatment: a cephalometric study. *Am. J. Orthod. Dent. Orthop.* 130:300–309.
- Proffit, W. R., C. Phillips, T. A. Turvey. 1991. Stability after surgical- orthodontic correction of skeletal Class III malocclusion. III. Combined maxillary and mandibular procedures. *Int. J. Adult. Orthod. Orthog. Surg.* 6:211–225.