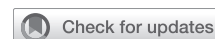

Uniportal video-assisted thoracoscopic surgery left upper lobectomy in 9 steps



Jae Ho Chung, MD, Susan Kelly, PA, David R. Jones, MD, and Gaetano Rocco, MD, New York, NY

From the Thoracic Service, Department of Surgery, Memorial Sloan Kettering Cancer Center, New York, NY. This work was supported, in part, by the National Cancer Institute at the National Institutes of Health (grant No. P30 CA008748).

Disclosures: Dr Jones serves as a consultant for AstraZeneca and is on a Clinical Trial Steering Committee for Merck. Dr Rocco has a financial relationship with Scanlan and AstraZeneca. All other authors reported no conflicts of interest.

The *Journal* policy requires editors and reviewers to disclose conflicts of interest and to decline handling or reviewing manuscripts for which they may have a conflict of interest. The editors and reviewers of this article have no conflicts of interest.

Received for publication May 5, 2021; accepted for publication Aug 20, 2021; available ahead of print Oct 25, 2021.

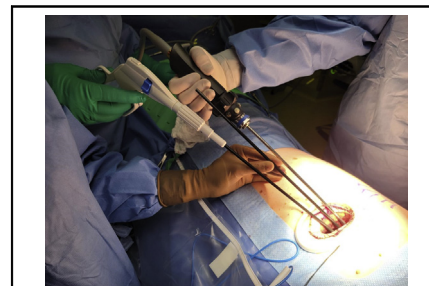Address for reprints: Gaetano Rocco, MD, Thoracic Service, Department of Surgery, Memorial Sloan Kettering Cancer Center, 1275 York Ave, Suite C-861, New York, NY 10065 (E-mail: roccog@mskcc.org).

JTCVS Techniques 2021;10:483-8

2666-2507

Copyright © 2021 The Author(s). Published by Elsevier Inc. on behalf of The American Association for Thoracic Surgery. This is an open access article under the CC BY-NC-ND license (<http://creativecommons.org/licenses/by-nc-nd/4.0/>).

<https://doi.org/10.1016/j.xjtc.2021.08.047>



Standard uniportal video-assisted thoracoscopic surgery incision.

CENTRAL MESSAGE

Uniportal video-assisted thoracoscopic surgery lobectomy can be performed safely and efficiently, especially if it is well planned and coordinated between team members.

Video clip is available online.

Feature Editor's Introduction—Supported now by hundreds (if not thousands) of datasets from around the world, minimally invasive lobectomy has arguably become the standard of care for operable patients with early stage non-small cell lung cancer. Minimally invasive lobectomy, however, is performed with 4 or 5 incisions using a surgical robot, with 2 or 3 incisions by thoracoscopic lobectomy, and as a uniportal thoracoscopic lobectomy. Whereas each of these approaches has been investigated for its advantages over the others, it is probably the prior training (and visceral preferences) of thoracic surgeons that mostly highly influence their adoption. In the United States, performing a true thoracoscopic lobectomy through a single incision is the rarest approach to minimally invasive lobectomy. This brings certain challenges in learning and disseminating the technique of uniportal lobectomy in residency and fellowship platforms and for faculty who are interested in adopting this minimally invasive platform. In the following video atlas article, the technique of uniportal thoracoscopic left upper lobectomy is distilled into 9 discrete steps, each demonstrated by video and taught by a surgeon credited with the first description of uniportal pulmonary resection.

Bryan M. Burt, MD

As in other specialties, the thoracic surgery community has experienced an increasing worldwide trend in the use of minimally invasive surgical techniques. As a consequence, video-assisted thoracoscopic surgery (VATS), or robotic surgery, has become a standard approach for the treatment of early-stage lung cancer.¹ Along with the adoption of VATS lobectomy, adoption of uniportal VATS (UniVATS), which is considered among the most innovative minimally invasive approaches, has also been widespread.

The use of UniVATS for nonanatomic pulmonary resection was reported in 2004.² In 2011, Gonzalez-Rivas and colleagues³ published the first results on UniVATS lobectomy. Since then, UniVATS has progressively been applied to increasingly complex pulmonary resections.⁴

Recently, the Uniportal VATS Interest Group Consensus Report defined the principles for the standardization of UniVATS.⁴ Despite many suggested benefits,^{5,6} UniVATS lobectomy remains a challenging and demanding procedure to perform and may require a longer learning curve because of its distinct technical characteristics.^{2,7,8} In this setting, the geometric configuration of UniVATS, eye-to-hand coordination, and instrument handling are crucial to the successful outcome of the operation, as well as to optimal visualization and surgeon-assistant interaction.⁹ This article

describes a standard UniVATS left upper lobectomy through 9 technical steps.

MATERIALS AND METHODS

One hundred twenty-eight UniVATS procedures have been performed at Memorial Sloan Kettering Cancer Center since October 2018. The procedure described here represents 1 of the 64 anatomic resections carried out during this period. For these resections, the team is usually composed of the operating surgeon, an assistant-trainee surgeon, and a dedicated physician assistant for intrathoracic visualization. The operation described was performed under the vision of a 30° 5-mm thoracoscope. To avoid mutual interference, roticulating instruments were used because of their ability to rotate the stem and the jaws independently on different planes and with multiple angles.² The instruments used in this procedure are shown in Figure 1.

A 62-year-old male patient with a history of oropharyngeal squamous cell carcinoma treated in 2019 and chronic obstructive pulmonary disease presented with two distinct lesions in the upper lobe (Figure 2). Preoperative chest computed tomography (CT) scan, positron-emission-CT scan, CT-guided percutaneous needle biopsy of 1 of the left upper lobe (LUL) nodules, and brain magnetic resonance imaging were performed. Pathology showed a squamous cell carcinoma, histologically different from the oropharyngeal cancer; this primary lung lesion was clinically staged as cT1 aN0 M0. The additional LUL nodule (0.7 cm) and the thoracic nodes were not positron-emission tomography avid. The patient had acceptable pulmonary function tests for lobectomy (forced expiratory volume in 1 second, 67%; diffusing capacity for carbon monoxide, 87%; and maximal oxygen consumption, 20.2 mL/kg/min). General anesthesia was applied using a double-lumen endotracheal tube for single-lung ventilation on the nonoperated side. An arterial line and Foley catheter were placed. The patient was positioned in the lateral decubitus position, with the operated side facing up over an axillary roll. After routine draping, the surgeons stood at the anterior side of the patient; the camera holder stood at the back of the patient, which is the usual placement. The patient gave informed consent for the

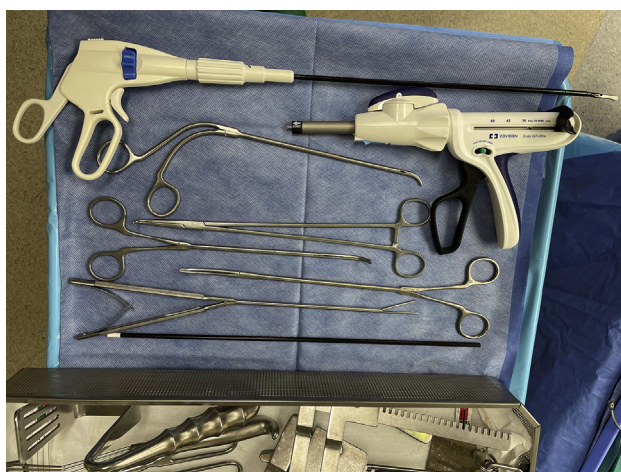

FIGURE 1. Instruments used for uniportal video-assisted thoracoscopic surgery lobectomy, from top to bottom: Roticulator Endo Grasp 5-mm Single Use Instrument with Spin Lock (Medtronic, Minneapolis, Minn); Endo GIA Curved Tip Reload with Tri-Staple Technology (Medtronic); Debakey Cooley Forceps, 90-degree Angled Jaws (Right Angle) (Scanlan, Minneapolis/St Paul, Minn); Gonzalez-Rivas Dissector (Scanlan); Gening J SPH Snake Dissector (Scanlan); Axial Handle Forceps (Scanlan), and Endo Pea-nut Single Use Instrument (Medtronic).

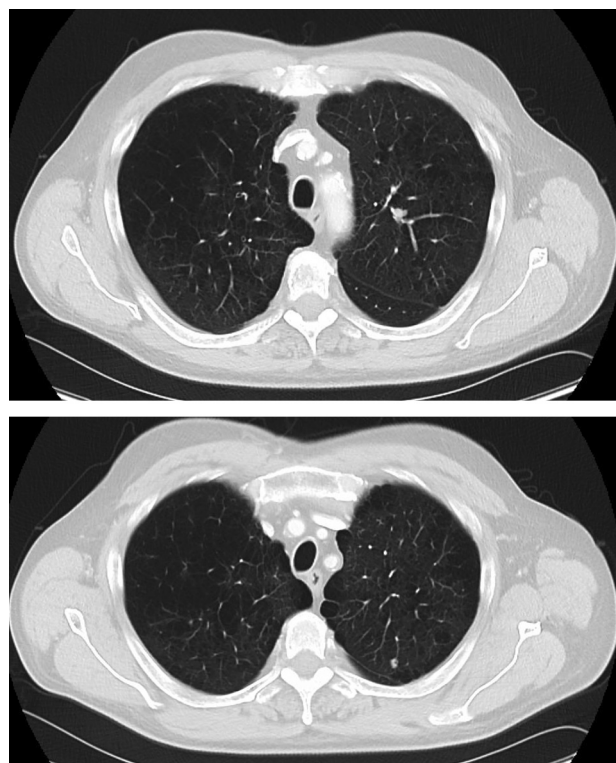


FIGURE 2. Preoperative chest computed tomography scan showing 2 distinct lesions in the upper lobe.

capture and use of operative videos and images. Final pathology showed squamous carcinoma in the larger, more central lesion (pT1 aN0) and adenocarcinoma (papillary predominant, pT1 aN0) in the second, more peripheral nodule. Overall, 18 lymph nodes were removed from the hilar (levels 11 and 12) and mediastinal (levels 5, 7, and 9) stations.

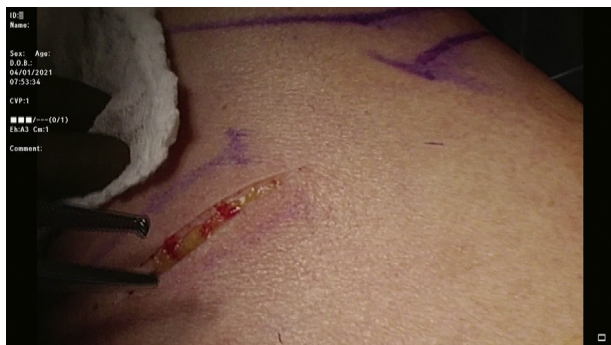RESULTS

The technique of UniVATS left upper lobectomy used in this patient is described in a series of 9 distinct steps, each with an accompanying video:

1. Port placement and pleural exploration (Video 1)

A single 5-cm incision was made at the fifth intercostal space between the posterior and the midaxillary lines. With the patient on single-lung ventilation, access to the intercostal plane was achieved by use of a blunt technique similar to chest drain placement.² Care was taken to avoid extending the intercostal muscle incision beyond the limits of the skin incision. Once a small wound protector was placed, a 30° 5-mm thoracoscope was inserted to explore the pleural cavity. We usually place the camera in the posterior part of the incision, to allow instruments to be inserted through the anterior part (ie, below the camera). The camera view with this specific placement mimics the view and instrumentation in open surgery.

2. Dissection of the anterior mediastinal pleura and division of the superior pulmonary vein (SPV) (Video 2)



VIDEO 1. Incision and port placement of 4 to 5 cm at the fifth or sixth intercostal space between the anterior and the midaxillary line. Video available at: [https://www.jtcvs.org/article/S2666-2507\(21\)00717-3/fulltext](https://www.jtcvs.org/article/S2666-2507(21)00717-3/fulltext).

The lung was retracted posterolaterally using a roticulating endograsper. The anterior mediastinal pleura was opened to expose the vein and the main pulmonary artery (PA) while the tissues overlying the SPV were dissected using a combination of blunt and sharp dissection until the subadventitial layer was reached. The superior and inferior borders of the SPV were dissected, with attention to avoid injuring the underlying PA branches, behind and slightly cranial to the superior border of the SPV. The inferior border of the SPV usually lay anterior to the lower border of the LUL bronchus and the interlobar space between the left upper and lower bronchi. The posterior surface of the SPV was bluntly dissected off the posteriorly lying structures using multiple gentle openings and closings of the right-angled clamp or a snake dissector until the instruments were freely passed behind the SPV. The lung was then retracted laterally to help create a space behind the vein. After introduction of the 45-mm curved-tip endostapler into the pleural cavity, the stapler was articulated until it could reach a perpendicular angle to the vein. This step may represent one of the most challenging and time-consuming steps in UniVATS upper lobectomies. Next, the thin part of the stapler with

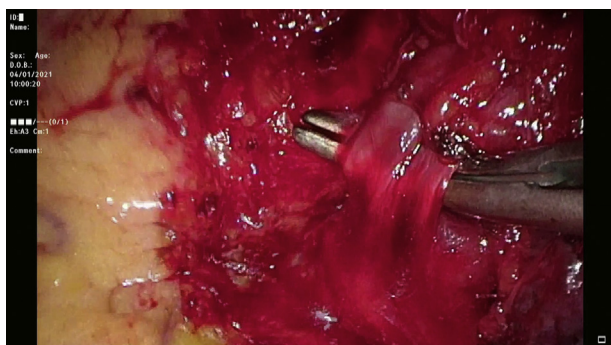
the curved tip was engaged behind the inferior border of the vein in a cephalad direction, as one would with a right-angle clamp, and was carefully advanced behind the vein. When the stapler tip emerged from the cranial edge of the SPV, the retraction of the lung was slightly loosened to avoid tension, and the stapler was closed and fired.

3. Dissection of the apical mediastinal pleura and division of the anterior and apical branches of the PA (**Video 3**)

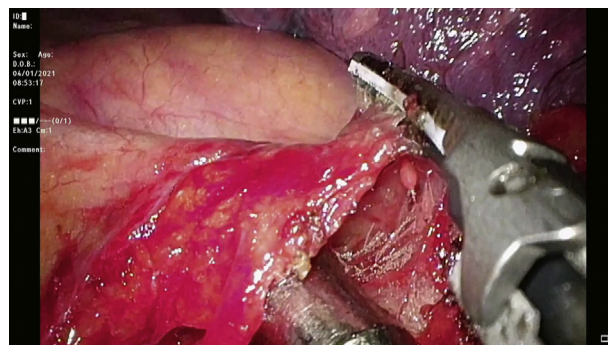
Once the vein was divided, better exposure of the anterior and apical branches of the PA and LUL bronchus was achieved. The lung was retracted posterolaterally, and further opening of the mediastinal pleura overlying the anterior and apical branches of the PA was obtained by use of blunt and sharp dissection. The superior border of the LUL bronchus was dissected, with attention to not injure the PA lying just behind and cephalad. When the lower borders of the anterior and apical branches of the PA were clearly exposed, a right-angled clamp or a snake dissector was carefully introduced between the branches and the distal truncal PA, with attention to avoid tension on the arteries. After the creation of a tunnel wide enough to pass the stapler through, a 30-mm curved-tip endostapler was articulated to an appropriate angle to avoid distally injuring the aorta. Once again, when the stapler tip emerged from the edge of the arterial branch, the tension on the lung was released, and the endostapler was fired.

4. Dissection and division of the anterior oblique fissure and division of the lingular branches of the PA (**Video 4**)

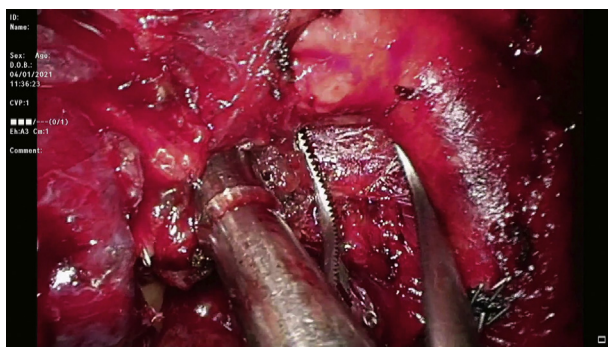
At this point, the anterior fissure was explored. Depending on the completeness of the fissure, it can be divided with either electrocautery, an energy device, or a stapler. For cases of incomplete fissure, the lung is retracted laterally and slightly posteriorly to straighten out the interlobar space. In our case, the interlobar space just caudal to the lower border of the LUL bronchus was carefully dissected posterolaterally using both blunt and sharp dissection. The



VIDEO 2. Dissection of the anterior mediastinal pleura and division of the superior pulmonary vein. Video available at: [https://www.jtcvs.org/article/S2666-2507\(21\)00717-3/fulltext](https://www.jtcvs.org/article/S2666-2507(21)00717-3/fulltext).



VIDEO 3. Dissection of the apical mediastinal pleura and division of the anterior and apical branches of the pulmonary artery. Video available at: [https://www.jtcvs.org/article/S2666-2507\(21\)00717-3/fulltext](https://www.jtcvs.org/article/S2666-2507(21)00717-3/fulltext).

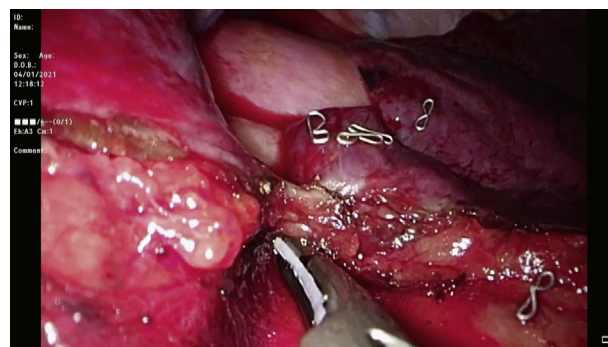


VIDEO 4. Dissection and division of the anterior oblique fissure and division of the lingular branches of the pulmonary artery. Video available at: [https://www.jtcvs.org/article/S2666-2507\(21\)00717-3/fulltext](https://www.jtcvs.org/article/S2666-2507(21)00717-3/fulltext).

interlobar lymph nodes were dissected and removed. Care was taken to avoid causing bleeding from the bronchial arteries and also to not injure the PA lying directly behind the interlobar tissues. At this point, the anterior fissure was partially divided to facilitate further dissection. The interlobar pleura was opened, and the adventitia of the lingular arterial branches was elevated and divided. The anterior border of the lingular artery was then carefully dissected in a distal, anterior-to-posterior direction. A right-angled clamp or a snake dissector was safely placed in the interlobar plane, which was opened, thus creating a tunnel where the curved tip of an endostapler was engaged upon retracting both the LUL and the left lower lobe (LLL) posterolaterally. Next, after application of the necessary retraction on the lung to correctly place the endostapler, the fissure was divided. The LUL was then retracted in a cranial and lateral direction to completely expose the lingular arterial branches, which were dissected and divided using a 30-mm curved-tip endostapler.

5. Dissection and division of the interlobar pleura and fissure and the posterior branch of the PA (Video 5)

Further opening of the interlobar pleura, keeping the dissection over the supra-arterial, preferably subadventitial plane, was continued posteriorly until the posterior mediastinal pleura was reached. The superior segmental branch (A6) caudally and the posterior ascending branch (A2) cranially were identified at this point. If the posterior fissure is incomplete, it can be divided using a curved tip endostapler by creating a tunnel between the opening of the interlobar pleura and the posterior mediastinal pleura and passing the stapler while retracting both lobes laterally. This step in the dissection, leading to the division of the posterior ascending PA, represents another possible challenge, owing to anatomic variations and the blind spot experienced during an anterior-to-posterior approach. In our case, we paid meticulous attention to ensure complete opening of the posterior mediastinal pleura by retracting the LUL as necessary to continue the dissection until the entire

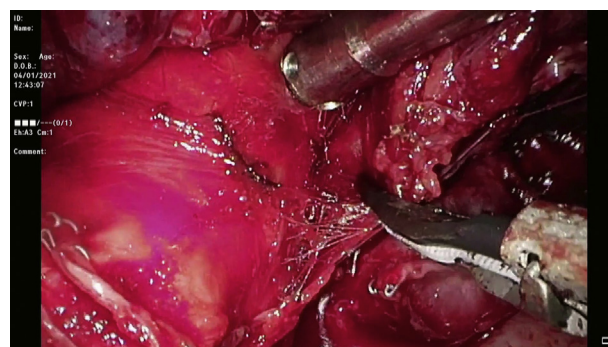


VIDEO 5. Dissection and division of the interlobar fissure and the posterior branch of the pulmonary artery. Video available at: [https://www.jtcvs.org/article/S2666-2507\(21\)00717-3/fulltext](https://www.jtcvs.org/article/S2666-2507(21)00717-3/fulltext).

posterior hilum was exposed. By retracting the LUL anteriorly and cranially, the anterior and posterior borders of the posterior ascending branch were dissected. In some cases, anterior and caudal lung retraction can give better views of the upper posterior border of the posterior ascending branch. The curved tip endostapler was rotated clockwise so that the stapler tip could pass between the posterior ascending branch and the bronchus, with the tip pointing posteriorly. At this point, the arterial branch was stapled and divided.

6. Dissection and division of the LUL bronchus (Video 6)

After division of all of the vascular structures, the LUL was retracted laterally to expose the bronchus, and further peribronchial dissection away from the PA was performed. All of the peribronchial tissues, including the lymph nodes, were either removed or pulled distally toward the lung parenchyma to clear the bronchial wall circumferentially. The right-angled clamp was passed behind the LUL bronchus, and a vessel loop was circled around the bronchus. To avoid leaving a long bronchial stump, the crane maneuver was used, as described by William Walker (personal communication). The vessel loop was repeatedly twisted on its axis as the bronchus was retracted to better expose



VIDEO 6. Dissection and division of the left upper lobe bronchus. Video available at: [https://www.jtcvs.org/article/S2666-2507\(21\)00717-3/fulltext](https://www.jtcvs.org/article/S2666-2507(21)00717-3/fulltext).

its emergence from the main stem. At this point, the LUL was retracted laterally, and the endostapler was completely roticulated to be as horizontal as possible to lie parallel to the aorta plane. The endostapler was passed carefully, under vision, to avoid any injury to the aorta or the resected PA or vein stumps.

7. Lymph node dissection (subaortic, hilar, subcarinal, or inferior pulmonary ligament) and division of the inferior pulmonary ligament (Video 7)

After identification of the phrenic and vagus nerves, the subaortic mediastinal pleura was opened. Subaortic lymph node dissection was performed using electrocautery or an energy device. The exposure of the subcarinal area is another potentially difficult step in UniVATS left-sided lobectomies. With antero-caudal retraction of the lower lobe, the posterior mediastinal pleura was completely opened, and left hilar and subcarinal lymph node dissection was performed. In our case, the subcarinal space was accessed by use of gentle antero-caudal retraction of the LLL.

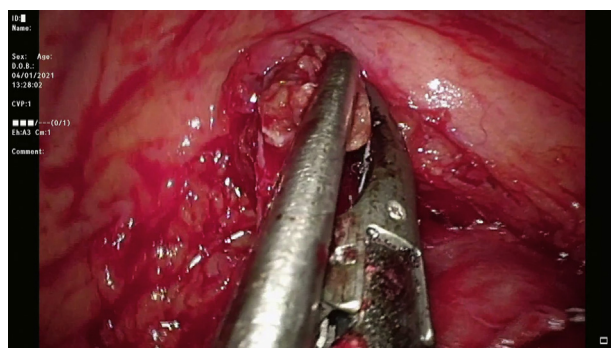
With cranial retraction of the LLL, the inferior pulmonary ligament was divided using electrocautery or an energy device. The inferior pulmonary ligament lymph node was removed at this point.

8. Specimen retrieval and chest tube insertion (Video 8)

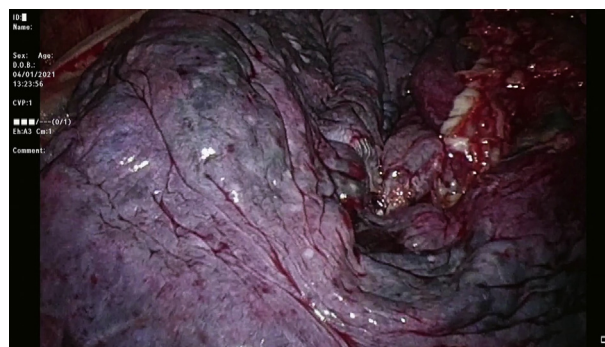A specimen bag was inserted into the pleural cavity, with the tip pointing away from the hilum to avoid injuring it.

9. Chest tube placement and wound closure (Video 9)

The pleural space was irrigated with warm, sterile water, and air leak testing was conducted under water. Meticulous hemostasis was achieved, and a 28Fr chest tube was inserted via the uniport and anchored at the anterior side of the incision, where the intercostal space is usually wider. The wound was then closed in layers around the chest tube.



VIDEO 7. Lymph node dissection (subaortic, hilar, subcarinal, or inferior pulmonary ligament) and division of the inferior pulmonary ligament. Video available at: [https://www.jtcvs.org/article/S2666-2507\(21\)00717-3/fulltext](https://www.jtcvs.org/article/S2666-2507(21)00717-3/fulltext).

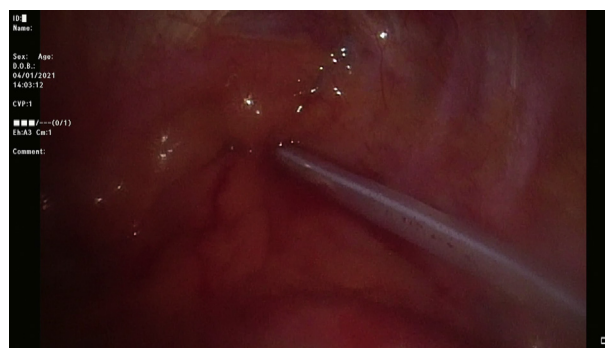

VIDEO 8. Specimen retrieval. Video available at: [https://www.jtcvs.org/article/S2666-2507\(21\)00717-3/fulltext](https://www.jtcvs.org/article/S2666-2507(21)00717-3/fulltext).

DISCUSSION

Understanding the distinct change in geometry during UniVATS lobectomy is imperative to perform a safer and more efficient procedure.² Bertolaccini and colleagues⁹ demonstrated that the translation of the thoracoscope 90° along a sagittal plane from the side point allows the hand instruments to address the target lesion from a vertical caudocranial perspective and preserves the depth of the 3-dimensional view. The surgeon works with eyes and hands in the same plane, as in open surgery. A 30° 5-mm videothoracoscope is used for visualization, while articulating instruments help bring the operative fulcrum inside the chest, in a fashion similar to robotic arms. In fact, while articulating endograspers retract the parenchymal tissues to mobilize and straighten the vascular and bronchial structures, an articulating endostapler is placed in a way of applying the rule of flexed arms to determine which angulation for the stapler is required in each division of structures.⁷ Through the same incision, several instruments, including retractor(s), a dissector or energy device, and a suction device, can be introduced parallel to the videothoracoscope, whereas their mutual position can be changed during the procedure as needed.

UniVATS is considered among the most innovative minimally invasive approaches, with certain advantages such as direct target view, better lung exposure, ergonomic



VIDEO 9. Chest tube placement. Video available at: [https://www.jtcvs.org/article/S2666-2507\(21\)00717-3/fulltext](https://www.jtcvs.org/article/S2666-2507(21)00717-3/fulltext).

instruments, less postoperative pain, faster postoperative recovery, shorter hospital stay, and earlier administration of adjuvant therapy.^{5,6}

UniVATS can also be a technically challenging approach if the basic principles of this technique are not well understood or if they are applied inappropriately during the procedure. To obtain a successful outcome and shorten the learning curve, it is imperative to focus on important technical details such as understanding the difference in geometric characteristics,^{2,9} managing curved and longer instruments, achieving good exposure of the lung, and understanding the insertion angle of the stapler.

To minimize the duration of the operation, the surgeon and assistant need to understand each other's moves and follow the same steps during the procedure. Similar to other minimally invasive procedures, including robotic or conventional VATS procedures, a dedicated team, including a surgeon, an assistant, an anesthesiologist, and nursing staff, should be routinely involved in UniVATS cases to achieve maximal coordination during the operation, and an appropriate preoperative plan should be created for every case.^{7,9}

UniVATS lobectomy performed according to the internationally approved recommendations should be considered in the armamentarium of the modern thoracic surgeon.¹⁰ Especially during the initial learning curve period, conversion to either multiport VATS or even open thoracotomy should always be considered without any hesitation if it is considered necessary to achieve a safer operation or better oncological results. It would also be safe to mark the site of the additional thoracotomy incision preoperatively and to have a plan for unexpected bleeding by discussing the roles of the operator and assistant in dealing with compression of bleeding and proceeding with the thoracotomy.

Beginning the UniVATS approach with theoretically easier cases such as lower lobectomies or those with complete fissures might also help promote understanding of the concepts of UniVATS lobectomy and allow easier

adoption of the new, distinct principles of this approach. Also, the choice of appropriate instruments can help in overcoming the difficult portions of the procedure and progressing through the operation.

CONCLUSIONS

The basic principles of UniVATS lobectomy have been agreed upon to standardize a technique that is increasingly used in Asia and Europe.¹⁰ In this article, we tried to include the most basic and important surgical details in every step of the procedure to help flatten the learning curve for UniVATS lobectomy.

References

1. Ng CSH, MacDonald JK, Gilbert S, Khan AZ, Kim YT, Louie BE, et al. Optimal approach to lobectomy for non-small cell lung cancer: systemic review and meta-analysis. *Innovations (Phila)*. 2019;14:90-116.
2. Rocco G, Martin-Ucar A, Passera E. Uniportal VATS wedge pulmonary resections. *Ann Thorac Surg*. 2004;77:726-8.
3. Gonzalez-Rivas D, Paradela M, Feira E, Velasco C. Single-incision video-assisted thoracoscopic lobectomy: initial results. *J Thorac Cardiovasc Surg*. 2012;143:745-7.
4. Gonzalez-Rivas D, Garcia A, Chen C, Yang Y, Jian L, Sekhniaidze, et al. Technical aspects of uniportal video-assisted thoracoscopic double sleeve bronchovascular resections. *Eur J Cardiothorac Surg*. 2020;58:i14-22.
5. Shen Y, Wang H, Feng M, Xi Y, Tan L, Wang Q. Single- versus multiple-port thoracoscopic lobectomy for lung cancer: a propensity-matched study. *Eur J Cardiothorac Surg*. 2016;49(Suppl 1):i48-53.
6. Halezeroglu S. Advantages and disadvantages of single incision VATS in major anatomical resection for lung cancer. *J Vis Surg*. 2017;3:115.
7. Paradela de la Morena M, De La Torre Bravos M, Fernandez Prado R, Minasyan A, Garcia-Perez A, Fernandez-Vago L, et al. Standardized surgical technique for uniportal video-assisted thoracoscopic lobectomy. *Eur J Cardiothorac Surg*. 2020;58:i23-33.
8. Martin-Ucar AE, Aragon J, Bolufer Nadal S, Munoz CG, Luo Q, Mendez IP, et al. The influence of prior multiport experience on the learning curve for single-port thoracoscopic lobectomy: a multicentre comparative study. *Eur J Cardiothorac Surg*. 2017;51:1183-7.
9. Bertolaccini L, Rocco G, Pardolesi A, Solli P. The geometric and ergonomic appeal of uniportal video-assisted thoracic surgery. *Thorac Surg Clin*. 2017;27:331-8.
10. Bertolaccini L, Batirel H, Brunelli A, Gonzalez-Rivas D, Ismail M, Ucal AM, et al. Uniportal video-assisted thoracic surgery lobectomy: a consensus report from the Uniportal VATS Interest Group (UVIG) of the European Society of Thoracic Surgeons (ESTS). *Eur J Cardiothorac Surg*. 2019;56:224-9.