

Two-Level Spontaneous Pedicle Fracture above a Degenerative Spondylolisthesis and Minimally Invasive Treatment

Abstract

This is a case report and literature review. The objectives of the study are to describe minimally invasive treatment of pedicle fractures, to show contralateral pedicle changes with pedicle fracture treatment, and to review literature on incidence and mechanism of neural arch fractures. After conservative therapy, there are several options for the treatment of pedicle fractures including pediculoplasty, osteosynthesis, or fusion. As patients' age increases, the incidence of pedicle fracture may rise and minimally invasive pedicle screw treatment represents a good motion-preserving option to stabilize without fusion. We report a patient with spontaneous pedicle fractures above a degenerative spondylolisthesis and evidence of contralateral pedicle changes at L2 and L3. After minimally invasive pedicle screw placement, postoperative imaging demonstrated trabeculation across both L2 and L3 fractures with a resolution of contralateral pedicle sclerotic changes and healing of incompletely fracture contralateral pedicle at L2. Pedicle fractures lead to contralateral pedicle sclerotic changes and potential fracture and may cause significant back pain. Stabilization and healing of the neural arch can be achieved with minimally invasive placement of pedicle screws without need for fusion.

Keywords: *Compression screw, lumbar fracture, neural arch stability, pedicle fracture, pedicle sclerosis*

Introduction

Pedicle fractures have been noted to occur in several different populations of patients including young athletes,^[1] sedentary office workers,^[2] a 12-year-old patient,^[3] middle-age females,^[4] and an elderly patient during a massage.^[5] Pedicle fracture has also been noted in postoperative laminectomy and lumbar fusion.^[6,7] Often times, a unilateral pedicle fracture is associated with spondylolysis on the contralateral side^[8,9] or even rarer bilateral spondylolysis.^[10,11] This report identifies a two-level pedicle fracture above a degenerative spondylolisthesis which underwent successful treatment.

Case Report

A 79-year-old female presented as an outpatient with a 10-year history of severe neurogenic claudication and severe back pain. She also complained of difficulty with walking up stairs. Motor strength in the lower extremities was 4+/5 proximally and distally with no sensory changes and preserved reflexes. Physical therapy, epidural steroids, and oral medications

were attempted initially. Computed tomography (CT) workup of the patient revealed L3–4 Grade 1 and L4–5 Grade 1 spondylolisthesis, unilateral complete pedicle fractures at L2 and L3 on the left, and incomplete pedicle fracture of L2 on the right and slight rotatory scoliosis [Figures 1 and 2]. At the L3 level, there was visible sclerosis on the right pedicle [Figure 2]. Flexion extension views of the lumbar spine revealed no dynamic instability. Magnetic resonance imaging (MRI) findings revealed spinal stenosis at L4–5 with severe bilateral neuroforaminal stenosis.

The patient underwent L4–5 minimally invasive decompression and fusion. The indication for surgery was bilateral lower extremity radiculopathy with foraminal and central canal stenosis as well as low back pain.

After the surgery, the patient continued to have a significant back pain. It was felt that the unilateral pedicle fractures needed to be braced due to the L4–5 fusion causing additional stress at the adjacent levels with pedicle fractures.

**Daniel Carr,
Richard Floyd
Cook,
Matthew Bahoura,
Doris Tong,
Teck Soo**

*Department of Surgery,
Section of Neurosurgery,
Providence-Providence Park
Hospital, Southfield, Michigan,
USA*

Address for correspondence:
*Dr. Richard Floyd Cook,
DO, 16001 W 9 Mile Road,
Southfield MI 48075, USA.
E-mail: richard.cook@nv.touro.
edu*

Access this article online

Website: www.asianjns.org

DOI: 10.4103/ajns.AJNS_109_18

Quick Response Code:



How to cite this article: Carr D, Cook RF, Bahoura M, Tong D, Soo T. Two-level spontaneous pedicle fracture above a degenerative spondylolisthesis and minimally invasive treatment. *Asian J Neurosurg* 2018;13:1279-81.

This is an open access journal, and articles are distributed under the terms of the Creative Commons Attribution-NonCommercial-ShareAlike 4.0 License, which allows others to remix, tweak, and build upon the work non-commercially, as long as appropriate credit is given and the new creations are licensed under the identical terms.

For reprints contact: reprints@medknow.com

L2 and L3 unilateral pedicle screws were placed using biplanar fluoroscopy. The L2 and L3 left pedicles were cannulated with Jamshidi needles and K-wires. The K-wire tracks were not tapped or drilled, and a Medtronic 5.5 mm × 50 mm screw was inserted at L2 and L3.

The patient had a subjective relief of back pain and claudication following the two surgeries at her 3 months follow-up visit.

At 3 months postoperatively, CT showed bony trabeculation across the bilateral L2 fractures and left L3 fractures [Figure 3]. Nine-month postoperative CT revealed complete fusion of all pedicle fractures with clear cortical borders visible with resolution of sclerosis in the right L3 pedicle [Figures 4 and 5]. Four years after initial screw placement, MRI shows no evidence of marrow changes or edema within the pedicles.

Discussion

Pedicle fractures can be found spontaneously or in association with defects of the neural arch.^[1-3,5,6,8-11] The incidence of pedicle fractures may rise with an aging population, may increase in lumbar spine decompression,^[7,9] and may increase with high-resolution imaging. The mechanism for fracture of the pedicle in

spondylolysis is likely related to increased stress across the neural arch from abnormal biomechanics of the lumbar segment. During early cadaveric studies of inferior facet loading, pars fracture was most common followed by pedicle fracture.^[12] Sclerotic and marrow changes have been noted within the pedicles of a vertebral body with spondylolysis.^[12-14]

Treatment of pedicle fractures ranges from instrumented fusion, pediculoplasty,^[15] lumbar osteosynthesis,^[16] and percutaneous compression screws.^[17] In this report, the continued back pain led to treatment of the L2 and 3 fractures. The fractures were compressed by slightly sinking the polyaxial heads into the pedicles while being careful not to further the pedicle fracture. Johnson and Wang noted overlapping the dorsal elements to attempt lag compression across the fracture. We decided to insert the screw without taping to provide as much rigid fixation of the pedicle as possible within the body as well as the dorsal pedicle.

Postoperatively, there was trabeculation across the fractures, including fusion of the incompletely fractured right L2 pedicle. The stabilization of the fractures by a pedicle screw led to a favorable stable environment for bony healing, without the morbidity of an additional fusion. The

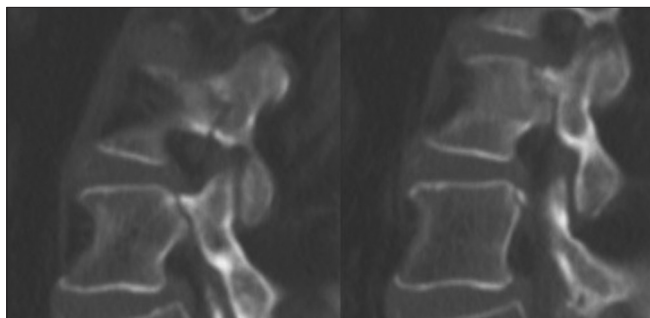


Figure 1: Sagittal computed tomography of left L2 and L3 pedicles demonstrating complete pedicle fracture

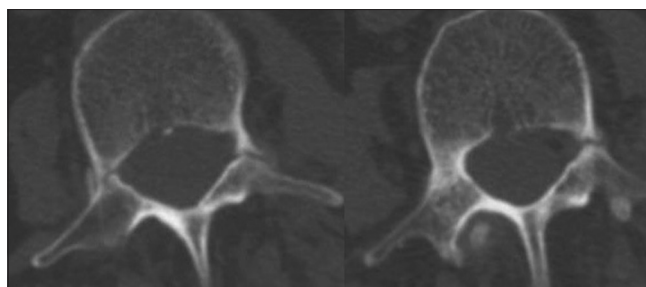


Figure 2: Axial computed tomography of L2 (left) and L3 (right) demonstrating complete left L2 and L3 pedicle fractures, right L2 incomplete pedicle fracture, and sclerosis of right L3 pedicle

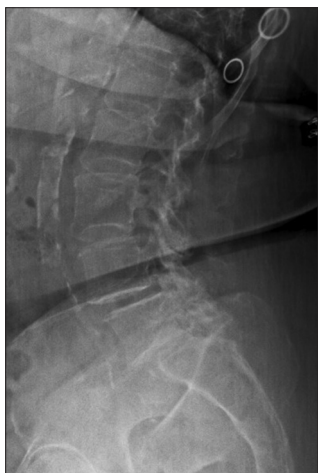

Figure 3: Three-month postoperative axial computed tomography of left pedicles demonstrating some bony trabeculation across fracture sites

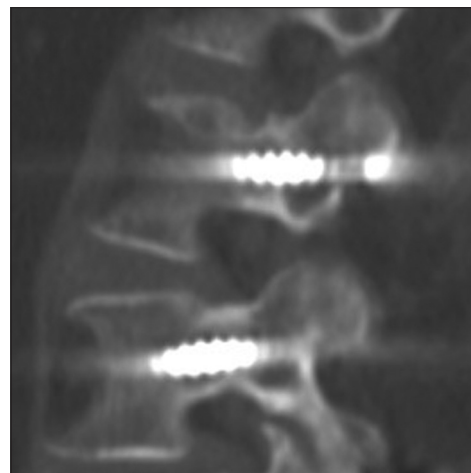


Figure 4: (left) Nine-month postoperative axial computed tomography showing complete fusion of pedicle fractures

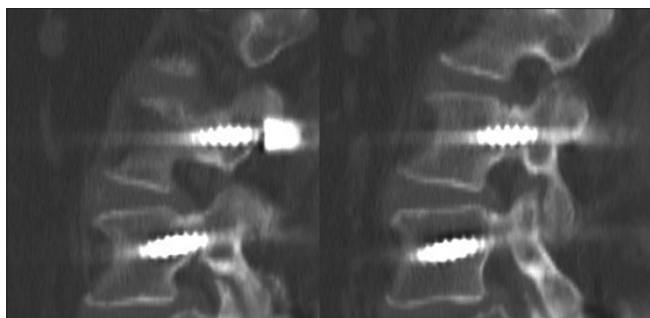


Figure 5: (right) Nine-month postoperative axial computed tomography revealing fusion at L2 bilaterally and resolution of sclerosis in right L3 pedicle

pedicle screw at L2 and L3 allowed healing of the right L2 pedicle and resolution of sclerosis in the right L3 pedicle. Four years postoperatively, MRI demonstrates no marrow changes within the pedicles or arch of L2 or L3.

Conclusion

These findings lead to the conclusion that fixation of one side of the neural arch has a direct relationship to the stability of the entire arch. Treatment with a percutaneous screw is a safe and effective way to brace a pedicle fracture, stabilize the neural arch, and promote bony healing. Further randomized study will be needed to evaluate the superiority of this procedure over other treatment options.

Declaration of patient consent

The authors certify that they have obtained all appropriate patient consent forms. In the form the patient(s) has/have given his/her/their consent for his/her/their images and other clinical information to be reported in the journal. The patients understand that their names and initials will not be published and due efforts will be made to conceal their identity, but anonymity cannot be guaranteed.

Financial support and sponsorship

Nil.

Conflicts of interest

There are no conflicts of interest.

References

1. Parvataneni HK, Nicholas SJ, McCance SE. Bilateral pedicle stress fractures in a female athlete: Case report and review of the literature. *Spine (Phila Pa 1976)* 2004;29:E19-21.

2. Sadiq MZ. Bilateral pedicle stress fracture in the lumbar spine of a sedentary office worker. *Eur Spine J* 2006;15 Suppl 5:653-5.
3. Vialle R, Mary P, de Carvalho A, Ducou le Pointe H, Damsin JP, Filipe G, *et al.* Acute L5 pedicle fracture and contralateral spondylolysis in a 12-year-old boy: A case report. *Eur Spine J* 2007;16 Suppl 3:316-7.
4. Karabay N, Ozer E, Ada E. Multi-level, bilateral pedicle fractures: Case report. *Turk Neurosurg* 2015;25:340-3.
5. Guo Z, Chen W, Su Y, Yuan J, Zhang Y. Isolated unilateral vertebral pedicle fracture caused by a back massage in an elderly patient: A case report and literature review. *Eur J Orthop Surg Traumatol* 2013;23 Suppl 2:S149-53.
6. Maccessi SJ, Leong AK, Bentivoglio JE. Pedicle fracture after instrumented posterolateral lumbar fusion: A case report. *Spine* 2001;26:580-2.
7. Sheehan JP, Helm GA, Sheehan JM, Jane JA Sr. Stress fracture of the pedicle after extensive decompression and contralateral posterior fusion for lumbar stenosis. Report of three cases. *Neurosurg Focus* 2002;13:E9.
8. Guillodo Y, Botton E, Saraux A, Le Goff P. Contralateral spondylolysis and fracture of the lumbar pedicle in an elite female gymnast: A case report. *Spine (Phila Pa 1976)* 2000;25:2541-3.
9. Maurer SG, Wright KE, Bendo JA. Iatrogenic spondylolysis leading to contralateral pedicular stress fracture and unstable spondylolisthesis: A case report. *Spine (Phila Pa 1976)* 2000;25:895-8.
10. Kim HS, Kim SW, Ju CI, Kim YS. Unilateral pedicle fracture accompanying spondylolytic spondylolisthesis. *J Korean Neurosurg Soc* 2015;57:484-6.
11. Maruo K, Tachibana T, Inoue S, Arizumi F, Yoshiya S. Unilateral pedicle stress fracture in a long-term hemodialysis patient with isthmic spondylolisthesis. *Case Rep Orthop* 2015;2015:426940.
12. Cyron BM, Hutton WC. The fatigue strength of the lumbar neural arch in spondylolysis. *J Bone Joint Surg Br* 1978;60-B: 234-8.
13. Ulmer JL, Elster AD, Mathews VP, Allen AM. Lumbar spondylolysis: Reactive marrow changes seen in adjacent pedicles on MR images. *AJR Am J Roentgenol* 1995;164:429-33.
14. Sairyo K, Katoh S, Sasa T, Yasui N, Goel VK, Vadapalli S, *et al.* Athletes with unilateral spondylolysis are at risk of stress fracture at the contralateral pedicle and pars interarticularis: A clinical and biomechanical study. *Am J Sports Med* 2005;33:583-90.
15. Singh J, Baker MD, Morris PP, Whitlow CT. Percutaneous pediculoplasty for traumatic pedicle fracture. A technical case report. *Interv Neuroradiol* 2012;18:221-6.
16. Han SH, Hyun SJ, Jahng TA, Kim KJ. Posterior osteosynthesis of a spontaneous bilateral pedicle fracture of the lumbar spine. *J Neurosurg Spine* 2016;24:398-401.
17. Johnson JN, Wang MY. Stress fracture of the lumbar pedicle bilaterally: Surgical repair using a percutaneous minimally invasive technique. *J Neurosurg Spine* 2009;11:724-8.