

# Diagnostic and Therapeutic Shoulder Arthroscopy Using a Small-Bore Needle Arthroscope



Noah Shafi, M.S., Sarah D. Lang, M.Ed., A.T.C., O.T.C., Hafiz Kassam, M.D., F.R.C.S.C., and Brian B. Gilmer, M.D., F.A.B.O.S.

**Abstract:** As resolution and image quality improve, several potential advantages make needle arthroscopy (NA) appealing for broader therapeutic applications in the operating room. Smaller camera size and weight allow for a minimally invasive approach with smaller incisions than standard arthroscopy and decreased use of arthroscopic fluid. Differences in the technology, such as a 0° optic and less rigid instrumentation, necessitate a modified technique to accommodate thorough diagnostic arthroscopy as well as modified approaches to therapeutic procedures. This article introduces our preferred approach to diagnostic arthroscopy of the glenohumeral joint and subacromial space with needle arthroscopy and small-bore instruments. This technique could increase efficiency and decrease operative time with certain arthroscopic procedures, and it may improve patient outcomes.

Diagnostic needle arthroscopy (NA) has been gaining popularity as a cost-effective alternative to magnetic resonance imaging (MRI).<sup>1-5</sup> Typically, NA is used as an in-office diagnostic procedure.<sup>6,7</sup> As resolution and image quality improve, however, several potential advantages make NA appealing for broader therapeutic applications in the operating room.

Smaller camera size (2 mm) and weight allow for a minimally invasive approach with smaller incisions than standard arthroscopy. The smaller camera sheath results in decreased use of arthroscopic fluid, which may reduce postoperative swelling and pain and improve outcomes and patient satisfaction.

The size of NA instruments makes them inherently more malleable than standard arthroscopic equipment, and therefore they cannot tolerate gross movements that may result in bending of the instruments. Furthermore, NA uses a 0° view, which may be unfamiliar to many surgeons. These differences in the technology necessitate modified techniques to accommodate thorough diagnostic arthroscopy as well as modified approaches to therapeutic procedures. This article and video introduce our preferred approach to diagnostic arthroscopy of the glenohumeral joint and subacromial space with NA instrumentation.

## Surgical Technique

Diagnostic arthroscopy with this technique can be safely performed in less than 10 minutes using only 150 mL of arthroscopic fluid. The complete procedure is indicated in [Video 1](#).

## Patient Positioning, Equipment, and Setup

Patient positioning and preparation is the same as with standard arthroscopy. The patient is positioned in the beach chair position on the operating table with a sterile arm holder. Anesthesia may be general or under interscalene block, with supplemental local anesthetic as necessary. Examination under anesthesia is recommended to evaluate for range of motion, crepitation, and glenohumeral instability.

The NA set (Nanoscope; Arthrex, Naples, FL) includes a 0° arthroscope with power cord; monitor; sharp and blunt trochars with corresponding sheaths, including

*From the University of Nevada, Reno, School of Medicine, Reno, Nevada, U.S.A. (N.S.); Mammoth Orthopedic Institute, Mammoth Hospital, Mammoth Lakes, California, U.S.A. (S.D.L., B.B.G.); and Sutter Health, Yuba City, California, U.S.A. (H.K.)*

*The authors report the following potential conflicts of interest or sources of funding: B.B.G. reports personal fees, Arthrex; other, Pacific Medical, ROM3, Stryker, Synthes; nonfinancial support and other, Smart Medical Devices. Full ICMJE author disclosure forms are available for this article online, as [supplementary material](#).*

*Received February 21, 2020; accepted April 6, 2020.*

*Address correspondence to Brian B. Gilmer, M.D., F.A.B.O.S., 85 Sierra Park Rd, PO Box 660, Mammoth Lakes, CA 93546, U.S.A. E-mail: [bbgilmer@gmail.com](mailto:bbgilmer@gmail.com)*

*© 2020 by the Arthroscopy Association of North America. Published by Elsevier. This is an open access article under the CC BY-NC-ND license (<http://creativecommons.org/licenses/by-nc-nd/4.0/>).*

*2212-6287/20273*

*<https://doi.org/10.1016/j.eats.2020.04.007>*



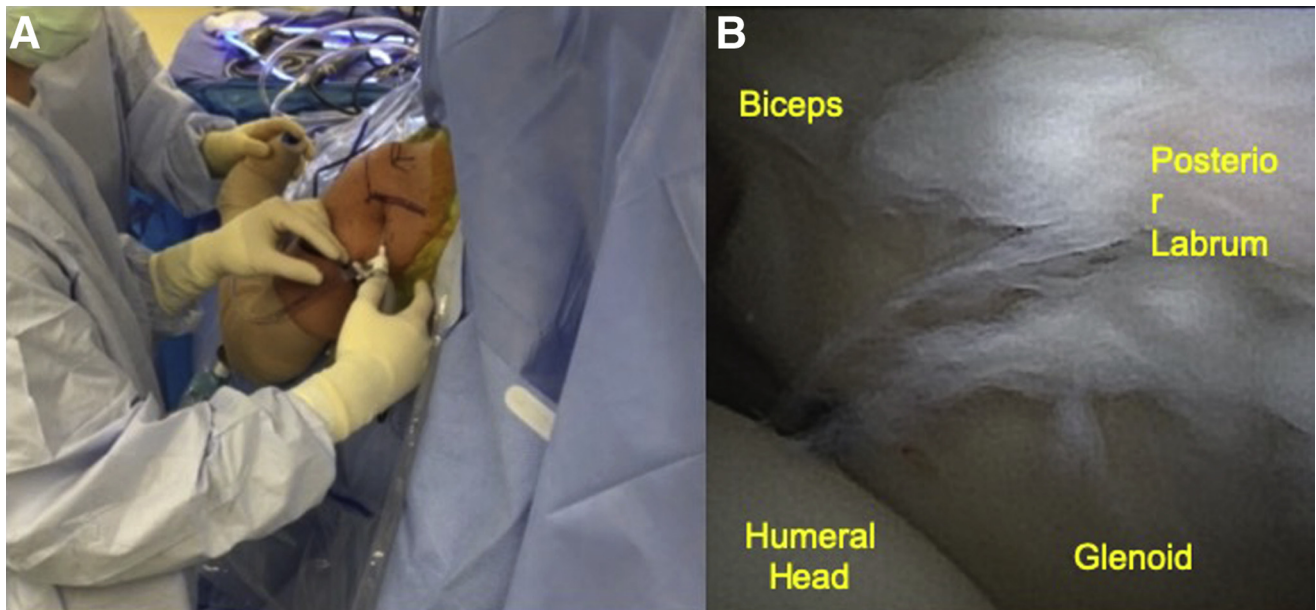
**Fig 1.** The needle arthroscopy set (Nanoscope; Arthrex, Naples, FL) includes a 0° arthroscope with power cord, monitor, and sharp and blunt trochars with corresponding sheaths, including inflow portals and assorted instruments.

inflow portals; and assorted instruments including a retractable probe and a 2.0-mm shaver (Figure 1). Using sterile technique, the cords are attached, and the monitor can be relayed to overhead monitors in the operating theater via a standard HDMI cable. After portal sites and anatomic landmarks are marked, including the acromion, the distal clavicle, and the coracoid, the glenohumeral joint is insufflated with 20 mL of normal saline through a posterior portal with an 18-gauge spinal needle, in preparation for diagnostic arthroscopy.

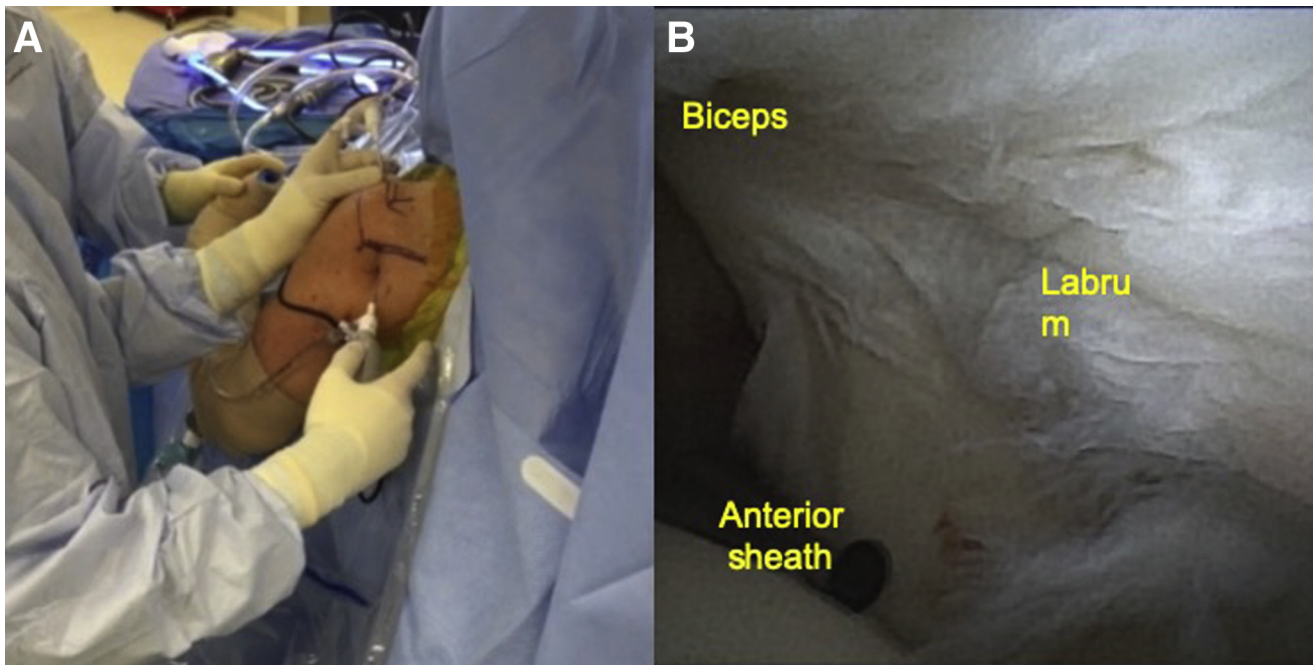
### Establishing Inflow and Outflow Sheaths

Diagnostic arthroscopy begins with the NA introduced into the standard posterior portal. Using the sharp trochar, the sheath is introduced through the skin and is exchanged for a blunt trochar for insertion into the glenohumeral joint, by directing the sheath and trochar just medial to the coracoid and parallel to the flow. The inflow tubing pump pressure should be set to 20 mmHg, and the fluid line is connected to the camera sheath after being primed to remove all air from the line. Once the trochar has been removed, waiting a few moments before inserting the camera allows time for the pump to insufflate the joint, which aids in visualization upon insertion of the camera.

From this position, the glenohumeral joint and the biceps anchor are inspected (Figure 2). Because of the minimal amount of fluid associated with NA, however, it can be helpful to first establish a sheath in the rotator interval anteriorly to improve visualization and insufflation and to remove air that may remain trapped in the joint. This anterior portal is localized first with a spinal needle inserted in a predominantly superior-to-inferior direction, just lateral to the coracoid, as with standard arthroscopy. With the 18-gauge spinal needle in place, its trochar is removed to allow some outflow and improve visibility. Once the trajectory is established, the spinal needle is removed, and the second sheath with the sharp trochar is inserted in the same location and trajectory within the rotator interval. Moving the inflow to this sheath is helpful in obtaining excellent visualization of the joint (Figure 3). Outflow



**Fig 2.** (A) External view, left shoulder, beach chair position, depicting camera sheath inserted into the posterior glenohumeral portal. (B) Arthroscopic view, same left shoulder, from the posterior portal showing the view upon entry of the camera into the glenohumeral space.



**Fig 3.** (A) External view, left shoulder, beach chair position, showing insertion of the second cannula from the anterior portal with the assistance of the sharp trochar under direct arthroscopic visualization. (B) Arthroscopic view, same left shoulder, beach chair position, depicting the view from the posterior portal after insertion of the anterior sheath. At this point, the inflow tubing may be moved to the anterior sheath to facilitate insufflation and improve visualization.

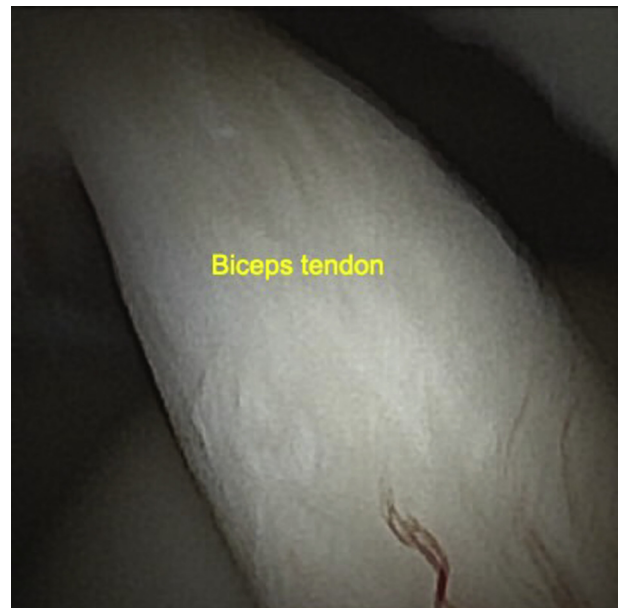
tubing is then applied to the sheath in the posterior portal. It is important to realize that visualization in NA relies more on controlling flow than pump pressure and fluid volume.

Because of Poiseuille's law, decreasing the radius of the tube inversely effects resistance and directly reduces flow. Therefore, the narrower sheath of the NA will necessitate adjustment of instruments, particularly arthroscopic shavers and ablaters. A large-diameter shaver with full suction applied will rapidly remove all of the fluid from the joint and create a vacuum. Smaller shaver diameters and judicious application of suction are critical to optimizing and maintaining visualization. A dedicated inflow sheath that does not contain a camera can mitigate flow mismatch. With inflow and outflow established, the diagnostic arthroscopy can begin in earnest.

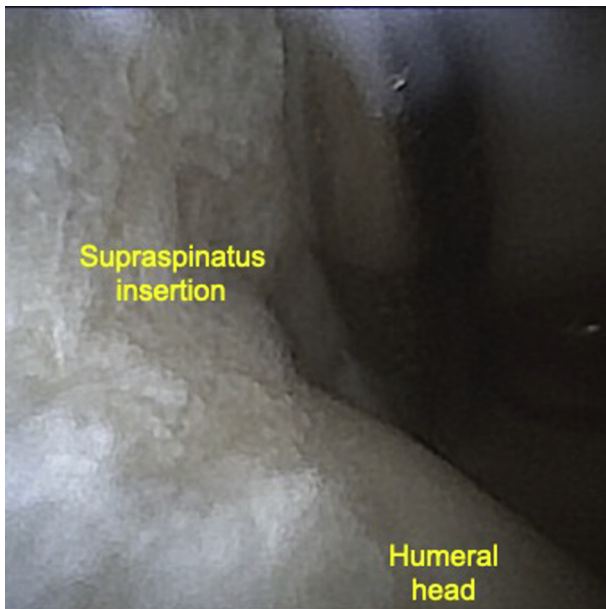
#### **Glenohumeral Arthroscopy From the Posterior Portal**

With the camera still in the posterior portal, the rotator interval is examined. The anterior sheath is used as a probe to manipulate the biceps anchor and evaluate for SLAP lesions. The biceps tendon can be manipulated to see the superior side of the tendon and draw a portion of the tendon into the joint (Figure 4). The arm is then moved into adduction and internal rotation to evaluate the insertion of the subscapularis. The arm is again moved, into abduction and external rotation, which allows visualization of the rotator cuff

insertion. Again, the anterior sheath may be used as a probe to retract any frayed tissue and view the articular margin (Figure 5). The camera is then retracted to view the bare area. The surgeon may raise their hand to



**Fig 4.** Arthroscopic view, left shoulder, beach chair position, from the posterior portal examining the superior surface of the long head of the biceps tendon. The anterior sheath may be used as a probe to manipulate the biceps and provide a dynamic examination by drawing the tendon into the joint.



**Fig 5.** Arthroscopic view, left shoulder, visualizing the insertion of the supraspinatus tendon onto the greater tuberosity from the articular side of the tendon. Slight external rotation and abduction can facilitate this view. The anterior sheath can be used to lift the cuff tissue to better visualize the insertion.

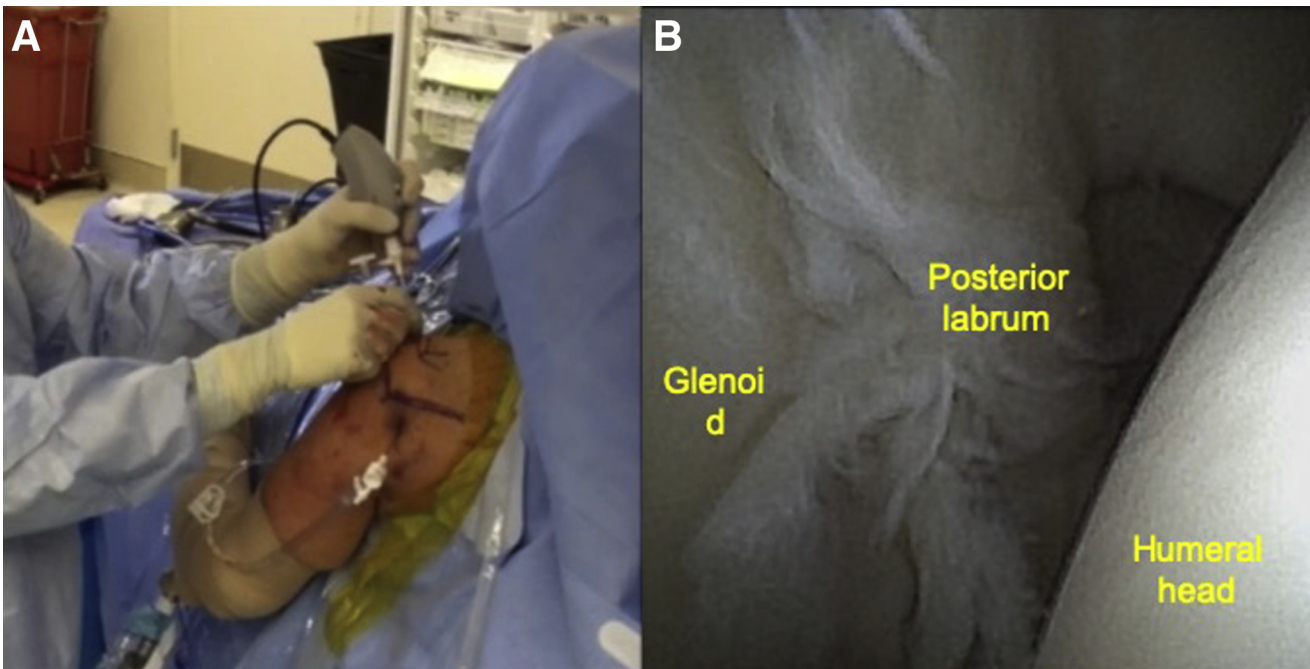
continue the view to the axillary recess and inspect for loose bodies. Finally, the view is returned to the glenohumeral joint.

### Glenohumeral Arthroscopy From the Anterior Portal

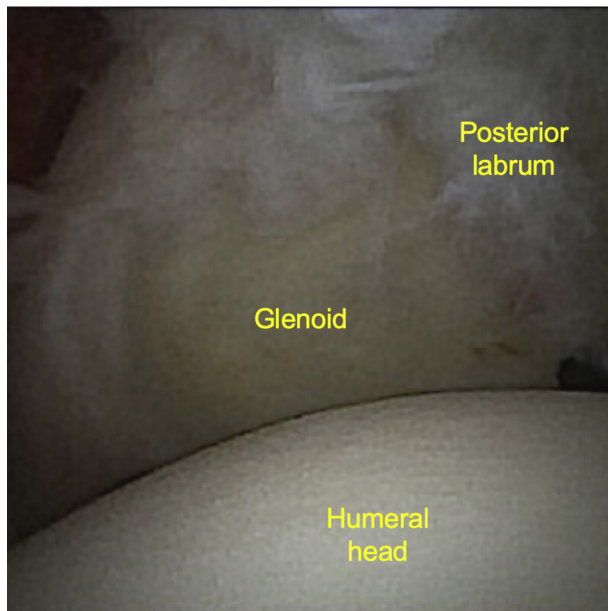
To complete thorough diagnostic arthroscopy, the camera is moved to the anterior sheath, and the inflow and outflow tubing should be switched. Again, because the diameter of the sheath is quite small, having the camera in the sheath where inflow is attached may compromise visibility. With the camera in the anterior portal, a view of the posterior labrum is obtained (Figure 6). By withdrawing the camera and redirecting centrally, a view of the articular surface of the humeral head and glenoid is obtained (Figure 7). This completes the diagnostic arthroscopy.

### Subcoracoid Arthroscopy

If necessary, additional portals may be used for specific purposes. For example, during arthroscopically assisted anatomic coracoclavicular joint reconstruction, dissection is required over the subscapularis and along the inferior surface of the coracoid. This can be difficult when viewing from posterior and often requires use of a 70° arthroscope. NA can simplify arthroscopy in this area by using a direct line of approach. While viewing from the posterior sheath, an 18-gauge spinal needle is used to localize the trajectory. Externally, this portal is placed just off the anterior lateral corner of the acromion. Internally, it is directed to enter the joint just anterior to the leading edge of the rotator cuff adjacent to the biceps tendon in the far lateral corner of the rotator interval. Once optimized, the spinal needle is removed, and the trajectory is noted. The sheath and



**Fig 6.** (A) External view, left shoulder, beach chair position, depicting the needle arthroscope in the anterior sheath. If necessary, the inflow tubing may be moved to the posterior sheath to promote insufflation and improve visualization. (B) Arthroscopic view, same left shoulder, the posterior labrum, glenoid, and humeral head are seen.



**Fig 7.** Arthroscopic view, left shoulder, with the camera in the anterior sheath. By bringing the arm into slight internal rotation, a bird's-eye view of the articular surface can be obtained, including the central portions of the humeral head and glenoid and the anterior and posterior labrums.

blunt trochar are then introduced in the same trajectory medially along the superior surface of the subscapularis tendon. The camera is maintained in this position while dissection instruments and electrocautery are introduced from the anterior portal. Because of their small size, the sheath and camera do not interfere with other instruments in this smaller space while they provide a direct inline view of the coracoid. In this case, the inflow remains attached to the posterior sheath, and the camera remains in the anterior superior lateral sheath.

### Subacromial Arthroscopy

Subacromial arthroscopy can be performed in a fashion similar to standard arthroscopy. From the glenohumeral joint with the NA in the posterior portal, the camera is removed. The blunt trochar is reintroduced and withdrawn slightly, then redirected more superiorly along the underside of the acromion. The inflow is then allowed to insufflate the subacromial space, and the camera is inserted. The same procedure is then performed using the other sheath in the anterior portal. Once established, the inflow is moved to the anterior sheath (Figure 8). A dedicated inflow sheath in the anterior portal provides the necessary fluid distention for excellent visualization of the subacromial space.

### Closure

Any working portals are closed with inverted absorbable suture and 2-octyl cyanoacrylate (Dermabond; Johnson & Johnson, New Brunswick, NJ) glue.


Because there is minimal soft tissue swelling, there is low risk of drainage. Portals created by the sheath alone do not require sutures and may be closed with Dermabond glue alone. Simple adhesive dressings (Band-Aids) are placed over incisions at the conclusion of the procedure. The Video shows the full procedure.

### Discussion

The cost-effectiveness and diagnostic accuracy of in-office NA has been previously reported, as have examples of clinical situations in which NA provided diagnostic accuracy in cases of unexplained pain.<sup>2,9</sup> However, a recent systematic review that suggested promise for NA also highlighted limitations, including the need for clearer diagnostic protocols to expand applications and widespread clinical use.<sup>10</sup>

Because of differences between standard arthroscopy and NA technology, namely a 0° optic and less rigid instrumentation, modified techniques are required to accommodate thorough diagnostic arthroscopy. Thus, this article presents our technique for diagnostic arthroscopy of the glenohumeral joint and subacromial space with NA.

Positioning and preparation of the patient are shared features of standard arthroscopy and NA. In standard shoulder arthroscopy, patients are conventionally in



**Fig 8.** Arthroscopic view, left shoulder, with the camera in the posterior sheath, which has been redirected into the subacromial space. The anterior sheath is redirected, under direct arthroscopic visualization, into the anterior subacromial space. With dedicated inflow tubing on the anterior sheath, excellent visualization can be obtained in the subacromial space. The anterior sheath may also be used as a probe to evaluate the bursal side of the rotator cuff and its insertion on the greater tuberosity.

**Table 1.** Pearls and Pitfalls

## Pearls

- Needle arthroscopy (NA) can be used diagnostically as an alternative to magnetic resonance imaging (MRI) or if MRI is contraindicated.
- In the operating room, NA can be used diagnostically or therapeutically, allowing for a more minimally invasive approach with smaller incisions, less arthroscopic fluid, and potentially less incisional pain.
- Using a dedicated inflow on the sheath (that does not contain the camera) will facilitate insufflation and better visualization. Alternatively, a large syringe may be used to provide inflow occasionally as needed.
- The additional sheath may also be used as a probe to perform dynamic examination.
- Avoid large gross motor movements to prevent deformation of the sheath and camera shafts.
- The camera and sheath may be intentionally contoured to reach anatomic locations that cannot be reached with a standard inline approach.

## Pitfalls

- The camera uses a 0° view, which may require a learning curve for surgeons.
- NA instruments are more malleable than standard arthroscopic equipment owing to their size, increasing the incidence of breaking and or bending.
- During diagnostic NA, a surgeon may find indications to use standard arthroscopy versus NA, leading to potential increased costs.
- The learning curve for NA carries the increased risk of iatrogenic chondral damage until the surgeon becomes familiar with the instrumentation.

lateral decubitus position or, as we have described, in a beach chair position. Preparation including marking of portal sites and anatomical landmarks is also synonymous between the two approaches.<sup>8</sup> Standard arthroscopy requires significant manipulations of the camera.<sup>6,7</sup> This contrasts with the preferred NA technique described, as the relatively small, malleable NA instrumentation does not tolerate gross movements through large soft tissue envelopes, as in the shoulder. Thus, the NA technique described for glenohumeral, subcoracoid, and subacromial arthroscopy uses direct lines of approach to the necessary structures while minimizing movement of the camera.

An important consideration in the technique described is the role of flow in establishing optimal visualization. Visualization in NA relies more on controlling flow than pump pressure and fluid volume. As such, the narrower sheath of the NA necessitates adjustment of the instruments. This should be managed through use of smaller shaver diameters and judicious application of suction for optimizing and maintaining visualization. A dedicated inflow sheath that does not contain the camera also helps mitigate flow mismatch.

Given the smaller-diameter inflow sheath of shoulder NA, fluid requirements are significantly reduced compared with traditional arthroscopy.<sup>6,8</sup> This may lead to less tissue distention and less soft tissue swelling. Decreased postoperative swelling may lead to less postoperative pain, earlier return of function, and improved range of motion postoperatively. Further clinical studies are warranted to evaluate these effects.

### Potential Applications

In addition to primary diagnosis, NA offers widespread potential for use, such as the following applications.

### Second-Look Surgery

Often, diagnostic shoulder imaging is compromised by previous surgical intervention, ranging from inability to position the patient to hardware artifact. Traditional second-look surgeries incur costs and risks similar to the index procedure. NA offers the opportunity to minimize these factors and obtain a potentially more accurate understanding of the shoulder after a previous operation. It also offers a minimally invasive and cost-effective research tool to understand the effect certain shoulder procedures may have on the joint.

### Targeted Delivery of Orthobiologics

As the use of orthobiologics continues to rise, targeted delivery of these potentially high-cost tools is likely to become paramount. The use of ultrasound to achieve this has been described but is still not entirely accurate.<sup>11</sup> NA offers a minimally invasive option to ensure that biologic treatment is delivered to the pathologic area accurately, and the low fluid volume associated with NA could potentially reduce compromise of the delivery, as is sometimes seen in standard arthroscopy.

### Biopsy in Shoulder Arthroplasty

Arthroscopic biopsy has been shown to be a valid tool in diagnosis of low virulent infections in a painful total shoulder arthroplasty.<sup>12</sup> Issues with its use are the cost and risk of an additional operation, general anesthetic, and potential for infection introduction, as well as possible prosthetic damage. Although the procedure would need to be validated, NA offers an alternative to the standard arthroscopic approach with potentially fewer downsides.

### Limitations

The potential advantages of the modified procedure also carry increased and unique risks. The increased malleability of the instruments make them inherently

less tolerant of manipulation, and they are prone to bending and even breaking. The end of the sheath is sharp, and there is a risk of iatrogenic chondral damage, which is increased if the surgeon is unfamiliar with the instrumentation. Additional pearls and pitfalls of the procedure are discussed in [Table 1](#).

### Conclusion

We describe a modified technique using needle arthroscopy for diagnostic and therapeutic procedures in the shoulder. We describe the technique for direct, inline visualization of all structures and the portal locations for instruments and probes, as well as the technique for subacromial instrumentation and debridement using needle arthroscopy.

### References

1. Amin N, McIntyre L, Carter T, Xerogeanes J, Voigt J. Cost-effectiveness analysis of needle arthroscopy versus magnetic resonance imaging in the diagnosis and treatment of meniscal tears of the knee. *Arthroscopy* 2019;35:554-562.
2. Chapman GL, Amin NH. The benefits of an in-office arthroscopy in the diagnosis of unresolved knee pain. *Case Rep Orthop* 2018;2018:6125676.
3. Deirmengian CA, Dines JS, Vernace JV, et al. Use of a small-bore needle arthroscope to diagnose intra-articular knee pathology: Comparison with magnetic resonance imaging. *Am J Orthop* 2018;47.
4. Gill TJ, Safran M, Mandelbaum B, et al. A prospective, blinded, multicenter clinical trial to compare the efficacy, accuracy, and safety of in-office diagnostic arthroscopy with magnetic resonance imaging and surgical diagnostic arthroscopy. *Arthroscopy* 2018;34:2429-2435.
5. McIntyre LF. Editorial commentary: What you see is what you get—Is in-office needle arthroscopy ready for prime time? *35:2722-2723*.
6. McMillan S, Saini S, Alyea E, Ford E. Office-based needle arthroscopy: A standardized diagnostic approach to the knee. *Arthrosc Tech* 2017;6:e1119-e1124.
7. Patel KA, Hartigan DE, Makovicka JL, Dulle DL III, Chhabra A. Diagnostic evaluation of the knee in the office setting using small-bore needle arthroscopy. *Arthrosc Tech* 2018;7:e17-e21.
8. Paxton E, Backus J, Keener J, Brophy R. Shoulder arthroscopy: Basic principles of positioning, anesthesia, and portal anatomy. *J Am Acad Orthop Surg* 2013;21:332-342.
9. West JA, Amin NH. In-office arthroscopy for the evaluation of chronic knee pain: A case report. *Open Med Case Rep* 2017;5:2050313X17740992.
10. Zhang K, Crum RJ, Samuelsson K, Cadet E, Ayeni OR. In-office needle arthroscopy: A systematic review of indications and clinical utility. *Arthroscopy* 2019;35:2709-2721.
11. Malanga G, Abdelshahed D, Jayaram P. Orthobiologic interventions using ultrasound guidance. *Phys Med Rehab Clin* 2016;27:717-731.
12. Dilisio MF, Miller LR, Warner JJ, Higgins LD. Arthroscopic tissue culture for the evaluation of periprosthetic shoulder infection. *J Bone Joint Surg Am* 2014;96:1952-1958.