

Perimyocarditis as first sign of systemic onset juvenile idiopathic arthritis treated successfully with anakinra: a case-based review

Silvia Ciancia¹, Michela Cappella², Alessandro De Fanti², Lorenzo Iughetti¹

¹Postgraduate School of Pediatrics, Department of Medical and Surgical Sciences of the Mother, Children and Adults, University of Modena and Reggio Emilia, Italy; ²Pediatric Rheumatology Unit, Santa Maria Nuova Hospital, Reggio Emilia, Italy

Summary. *Background:* The involvement of myocardium and pericardium at the same time is very uncommon as first manifestation of juvenile idiopathic arthritis with systemic onset (soJIA). *Case:* A fourteen years-old boy, referred with symptoms of acute gastroenteritis, developed a perimyocarditis as first manifestation of Still's Disease, after only one day from the admission. The rheumatologic disease was not responding to glucocorticoid treatment. The use of anakinra was the key point of the therapy and after its administration the patient started to recover fastly. *Conclusions:* This case report describes cardiac involvement as first sign of soJIA and the successful use of anakinra inducing remission of soJIA not-responding to steroid therapy. (www.actabiomedica.it)

Key words: arthritis, idiopathic, juvenile, myocarditis, perimyocarditis, interleukin, anakinra

Background

Systemic onset juvenile idiopathic arthritis (soJIA) is a chronic inflammatory disease characterized by high spiking quotidian fever and arthritis associated with evanescent rash, lymphadenopathy, hepatosplenomegaly and serositis (1). JIA is one of the most common pediatric chronic diseases and is classified in seven subtypes by the International League of Associations for Rheumatology (ILAR) classification (2).

SoJIA includes about 10-20% of all JIA patients (3). Several studies showed the role of innate immune system in soJIA, resulting in increased production of pro-inflammatory cytokines (4-6), that explains the role played in therapy by biological drugs such as anakinra. Cardiac involvement as onset manifestation is very rare in pediatric population, representing at most a complication of the disease.

Case presentation

A 14-years-old boy presented with fever, vomiting, diarrhea, signs of dehydration, loss of appetite, severe weakness, arthromyalgias diffused to the entire body, headache and pharyngodynia since a week. Physical examination revealed pharyngitis with cervical lymphadenopathy, pain in left iliac region during the palpation of the abdomen and hepatosplenomegaly. Three days before his pediatrician prescribed antibiotic therapy for throat inflammation.

Blood tests showed neutrophilic leukocytosis (white cells 16.140/mm³ with 84% of neutrophils) and an important increase of C-reactive protein (35.58 mg/dl, normal value <0.01 mg/dl) and creatine phosphokinase (476 U/l, normal value <50 U/l). Procalcitonin was only mildly increased (0.84 ng/ml, normal value <0.50 ng/ml). Sinus rhythm with diffuse repolariza-

tion abnormalities were evident on the electrocardiogram. Chest X-rays was completely normal.

To correct the dehydration the patient was admitted in our unit.

During the first day of admission the boy presented epigastric pain, profuse sweating, paleness and mild bradycardia with normal blood pressure level for age. On electrocardiogram a diffuse ST elevation was present, troponin was consistently high (28.36 ng/ml, normal range 0-0.4 ng/ml) and echocardiography revealed a slight layer of pericardial effusion without reduction of ejection fraction (EF 60%) but with a mild contractile dysfunction of posterobasal segments of the ventricular septum. The boy was developing a perimyocarditis in the context of an acute gastrointestinal infection. To prevent complications of perimyocarditis and onset of malignant arrhythmias, the patients was admitted to the intensive care unit for 48 hours. During this time his clinical conditions were stable and the level of troponin on the second day after the admission showed a dramatic reduction (7.37 ng/ml, NR 0-0.4 ng/ml).

Features of perimyocarditis reversed within 72 hours and clinical situation was stabilized but the boy still presented twice-a-day high spiking fever, weakness and arthromyalgias increasing in severity. Abdominal ultrasounds confirmed the enlargement of liver and spleen; on blood tests CPK was increased (576 U/L), the same were CRP (39.42 mg/dl) and white cells count (18670/mm³), ESR was high (80 mm/h), ferritin raised (285.3 ng/ml, normal range 7-140 ng/ml), anemia developed (Hb 11.7 g/dl, normal range for age 12-15.2 g/dl). Pharyngeal swabs for viruses (Adenovirus, Influenza virus type A/B, Parainfluenza virus type 1/2/3/4, Rhinovirus A/B/C, RSV type A/B, Bocavirus, Coronavirus 229E, Coronavirus NL63, Coronavirus OC43, Metapneumovirus, Enterovirus) and bacteria (*Mycoplasma pneumoniae*, *Chlamydia pneumoniae*, *Legionella pneumophila*, *Bordetella pertussis*, *Bordetella parapertussis*) were negative, serological tests showed positive IgG for EBV and CMV associated to negative IgM and negative IgM and IgG for: *Mycoplasma pneumoniae*, *Chlamydia pneumoniae*, *Borrelia burgdorferi*, *Bartonella*, *Brucella* spp, *Salmonella typhi/paratyphi*, *Parvovirus B19*, *Adenovirus*, TORCH complex, HIV. For Enterovirus

also IgA were measured and were negative. Tuberculosis tests were negative (PCR for DNA research on sputum and Mantoux test negative, QuantiFERON indeterminate). Blood cultures (for aerobic and anaerobic bacteria and fungi) did not grow any organism, stool culture (*Salmonella*, *Shigella*, *Campylobacter*) were negative. Antistreptolysin O titer was negative. Therefore, the main infectious agents were excluded. Screening for autoantibodies was negative: antinuclear antibodies (ANA), anti-double stranded DNA antibodies (anti ds-DNA), anti-*Saccharomyces cerevisiae* antibodies (ASCA), anti-neutrophil cytoplasmic antibodies (ANCA) titers were within normal limits. In the suspicion of rheumatic condition, serum amyloid A was measured and the level was raised (586 mg/dl, normal range 1-3 mg/dl).

The persistence of fever, the presence of generalized lymph nodes enlargement, severe arthromyalgias, hepatosplenomegaly, the recent perimyocarditis, and finally the appearance of an evanescent and itchy pink rash on his trunk in presence of elevation of blood markers of systemic inflammation, allowed us to make the diagnosis of systemic onset juvenile idiopathic arthritis (soJIA) characterized by perimyocarditis as first sign of onset.

Pulse intravenously methylprednisolone was then administered for three days and after that oral corticosteroid therapy with prednisone was started. Because fever and arthritis were persistent, after six days a second try with high-doses steroid bolus was made. Abdominal ultrasounds showed the resolution of splenomegaly with spleen of normal size, but hepatomegaly was still present. Cardiological follow-up showed the resolution of myocarditis, troponin value was negative, but the slight layer of pericardial effusion was persistent. In four days fever and arthromyalgias appeared again, with a prevalent involvement of knees. The blood tests showed increased value of white cells (34.750/mm³, neutrophils 92%), CRP (7.37 mg/dl), ESR (35 mm/h), ferritin (757 ng/ml). In consideration of the persistent systemic inflammation despite the corticosteroid treatment, we decided to enhance the therapy by adding anakinra, a biological drug. The day after the start of the second-line therapy fever vanished permanently, in five days inflammation index returned to normal values, only a mild pain to both knees

persisted. The echocardiography performed after one week showed the disappearance of the pericardial effusion.

During the subsequent follow-up, the boy showed a good compliance to the therapy. The glucocorticoids daily dose was progressively reduced and the patient continued his treatment with anakinra with good control of symptoms. After two and a half months cardiac MRI was performed to assess any damage: morphology and volume of left ventricle were preserved, the ejection fraction was 63%. The study of segmentary kinetics of the left ventricle documented the presence of mild hypokinesia of the mid-lateral wall. The delayed enhancement showed minute hyperintense areas into the distal portion of the mid-lateral wall of the left ventricle as scar fibrosis after myocarditis.

Discussion

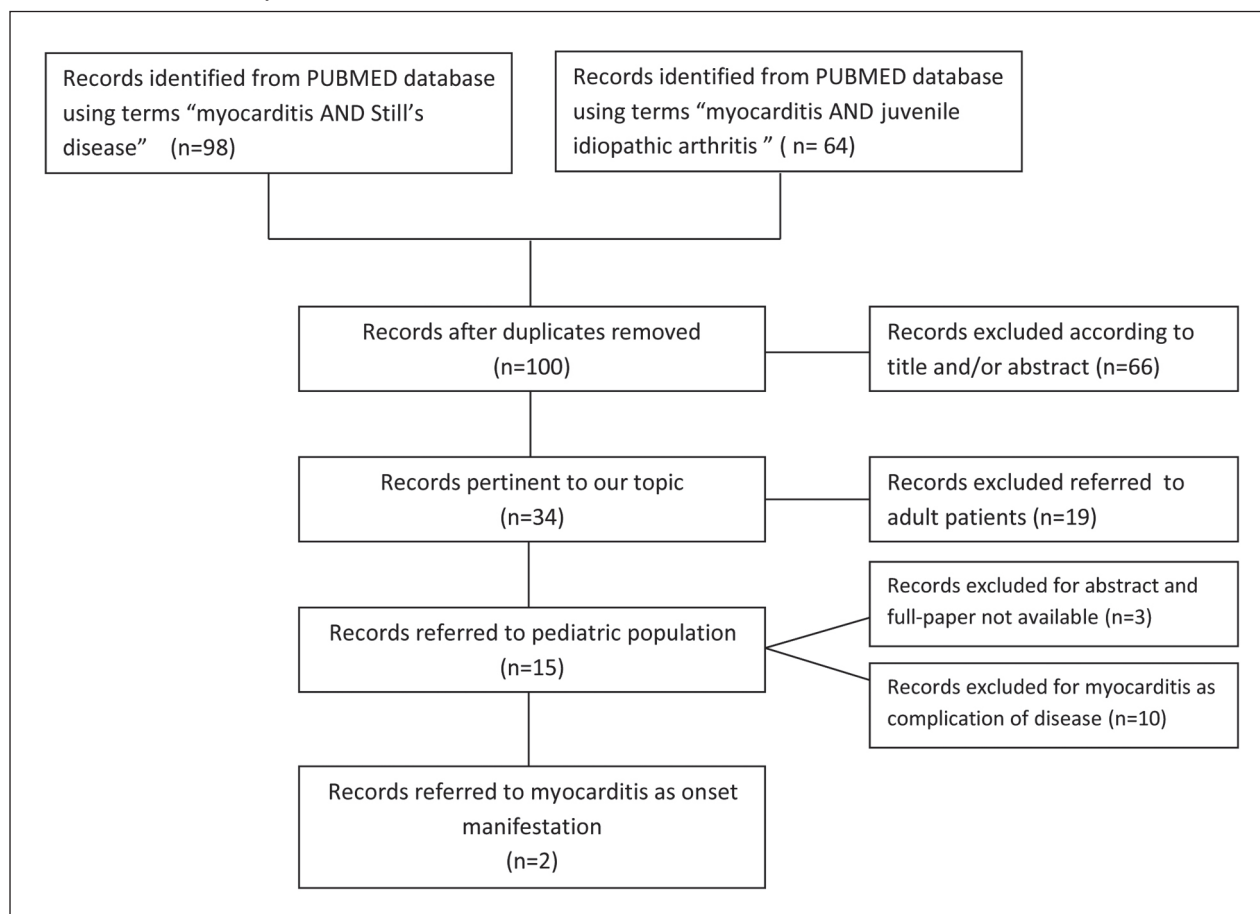
The most interesting aspect of our case is the onset of Still's disease with cardiac involvement. Pericarditis as onset manifestation of soJIA is included in diagnostic criteria (even if this manifestation is rare in pediatric population) but involvement of cardiac muscle is exceptional.

We performed a research in PUBMED database (including Medline) combining word "myocarditis" with "Still's disease" and "systemic onset juvenile idiopathic arthritis". After removing duplicate records, a total of 100 papers was found. Of this group, 66 records were excluded because not pertinent and 19 records were excluded because referred to adult patients. Of the 15 records left, 3 were excluded because neither the abstract or the full-paper were available. Considering the last 10 papers, only 2 of them referred to case reports of patients in pediatric age presenting myocarditis as onset manifestation of systemic onset juvenile idiopathic arthritis (table 1).

Mondal and colleagues described a case of an 11-years-old child with congestive heart failure as presentation of soJIA. Acute myocarditis without evidence of pericarditis was the etiology for congestive heart failure (7). Myocarditis leading to congestive heart failure, associated to perimyocarditis in a patient with cervical spondylitis without any peripheral joint

involvement at onset of soJIA is described by Ghosh (8).

Svantesson et al. followed up thirty-three patients with soJIA for 4 to 24 years and found that cardiac involvement occurred in 42%, with myocarditis or perimyocarditis having a worse prognosis than pericarditis; anyway cardiac involvement in these cases was a complication of the disease and not an onset manifestation (9). In a similar study Svantesson et al. followed up 320 patients with JIA, only 4.7% developed cardiac involvement and perimyocarditis was diagnosed in only 2 children (10). Miller et al. described three cases of children with myocarditis and soJIA. Also in these cases myocarditis occurred on a background of severe, active systemic disease (11). A retrospective study of Goldenberg et al. on 172 patients affected by soJIA described 13 patients presenting cardiac involvement during the first years of disease: seven patients developed pericarditis, four perimyocarditis and two myocarditis. Among the patients with myocarditis, three died of septicemia during active disease (12). An Italian work on 83 juvenile rheumatoid arthritis patients described the cardiac involvement in 4 patients. Also in those cases the cardiac disease was a complication of soJIA, and was not present at the onset of the disease. Only one patient developed perimyocarditis. In all of them treatment with prednisone was sufficient to induce the resolution of the acute complication (13). Ward et al. described a case of a Chinese 16-years old patient diagnosed with systemic onset juvenile idiopathic arthritis. The authors attributed the cardiac involvement to a myocarditis but the clinical history and the exams referred seems to be more suggestive of pericarditis and possibly endocardial involvement than cardiac muscle disease (no raise in creatine kinase levels, no report about troponin levels, normal echocardiographies) (14). From literature review another interesting case emerged: Zeff and colleagues described the case of 10 years-old boy presenting isolated myocarditis without pericardial involvement 17 months after onset of soJIA, while he was on treatment with NSAID, prednisone, low dose cyclosporine and anakinra. The symptoms started mildly and were first associated to a viral illness; in approximately 3 weeks the boy started to complain evening chest pain; two days later his clinical conditions worsened but he was

Table 1. Flow-chart of study selection

discharged again because apparently he presented only with mild symptoms and signs at physical examination, even if his chest X-rays documented his heart size within the upper limits of normal. The boy died at home 2 days later. At autopsy patchy peribronchial inflammation and isolated myocarditis emerged. Because no signs of severe systemic inflammation were found, macrophage activation syndrome was excluded. Immunosuppression due to medications he was taking could have facilitated infectious myocarditis (no viral etiology has been demonstrated) but it is also possible that incompletely controlled disease could have led to myocardial inflammation. Cardiac related adverse effects are not listed for anakinra administration (15). A recent review on cardiac involvement in juvenile idiopathic arthritis concludes that subclinical cardiovascular involvement begins shortly after the onset of the disease and worsens with disease duration. It constitutes

the second common cause of mortality in this class of patients. If pericarditis represents the most common but often benign cardiac involvement with a prevalence of 30-36%, myocarditis is a rare event (frequency from 1.2% to 10%) but can be life threatening (15). Myocardial involvement is normally due to chronic inflammation, subclinical vasculitis, damage of the endothelium, fibrosis, thus it is often correlated to a longer duration of disease. In consideration of this, cardiac involvement usually represents a complication of soJIA.

Hence, as onset manifestation of soJIA, like in our patient, perimyocarditis is exceptional. In our patient myocarditis was diagnosed on the basis of cardiac enzyme elevation and echocardiography findings; endomyocardial biopsy was not performed to confirm the diagnosis because of its invasiveness. Pericarditis was diagnosed on electrocardiogram abnormalities and on echocardiography revelation of pericardial effusion.

The other interesting aspect of our case was the efficacy of anakinra to induce the remission of the disease, after the failure of the corticosteroid therapy. Anakinra is a recombinant form of human IL-1 receptor that binds to IL-1 with a competitive mechanism. In Still's disease, it is approved in children aged more than 8 months or with body weight >10 kg, with a dosage of 1-2 mg/kg/day up to 100 mg/day (as for adult patients, with body weight >50 kg). According to the latest recommendations for the treatment of Juvenile Idiopathic Arthritis from the American College of Rheumatology, the use of anakinra as initial therapy is indicated for children with physician global assessment ≥ 5 irrespective of the AJC (active joint count) or for children with physician global assessment <5 and AJC >0 (17). Nigrovic talked about a "window of opportunity" for treatment of soJIA, in which anakinra represents an excellent choice (18). Unluckily, sometimes anakinra seems to be not highly effective on arthritis symptoms, with patients having a partial response (19). Our patient had an extraordinary response on the side of systemic and biochemical features, but a not complete remission of arthritis, persisting at knees, but mildly. Even if there are not enough data about the early use of anakinra to treat soJIA presenting with heart involvement at the onset, there are a few case reports of adult-onset Still's disease complicated by myocarditis at the onset, in which anakinra has successfully been used in patients resistant to high-doses of corticosteroids (20-22). Luconi et. al described a case of a 17 years-old young man presenting myocarditis at the onset of his adult onset Still's disease: anakinra was prescribed as third line therapy (first line therapy NSAIDs associated to colchicine, second line therapy pulse corticosteroids ev, then oral prednisone associated to methotrexate). Only after the start of anakinra there was a spectacular improvement of clinical conditions, laboratory values and transthoracic echography findings (23).

Conclusions

Pericarditis is the most common form of cardiac involvement in SoJIA and it is usually self-limiting. Myocardial involvement (with or without pericardial

effusion) is rare but potentially life-threatening. The early recognition of this rare manifestation, at the onset of the disease or as a secondary complication, is necessary to prevent severe outcomes. The early use of anakinra can dramatically improve the evolution of soJIA.

Conflict of interest: Each author declares that he or she has no commercial associations (e.g. consultancies, stock ownership, equity interest, patent/licensing arrangement etc.) that might pose a conflict of interest in connection with the submitted article

References

- Shenoi S, Wallace CA. Diagnosis and Treatment of Systemic Juvenile Idiopathic Arthritis. *J. of Pediatrics* Jun 16, 2016
- Petty RE, et al. International League of Associations for Rheumatology classification of juvenile idiopathic arthritis: second revision, Edmonton, 2001. *J Rheumatol.* 2004;31(2):390
- Cimaz R. Systemic-onset of juvenile idiopathic arthritis. *Autoimmunity Reviews* 15(2016)931-934
- Barnes MG, et al. Subtype-specific peripheral blood gene expression profiles in recent onset juvenile idiopathic arthritis. *Arthritis Rheum* 2009;60:2102-12.
- Ishikawa S, et al. Abnormal expression of the genes involved in cytokine networks and mitochondrial function in systemic juvenile idiopathic arthritis identified by DNA microarray analysis. *Ann Rheum Dis* 2009;68:264-72.
- Ogilvie EM, Khan A, Hubank M, Kellam P, Woo P. Specific gene expression profiles in systemic juvenile idiopathic arthritis. *Arthritis Rheum* 2007;56:1954-65.
- Mondal R, Sarkar S, Ghoshal A, Sabui T. Congestive Heart Failure: An Uncommon Presentation of Systemic Onset Juvenile Idiopathic Arthritis (SOJIA). *Indian J Pediatr* (January 2013) 80(1):67-69
- Ghosh JB. Juvenile Idiopathic Arthritis-Its Rare Presentation. *Indian J Pediatr* (February 2012) 79(2):262-264
- Svantesson H, Akesson A, Eberhardt K, Elborgh R. Prognosis in juvenile rheumatoid arthritis with systemic onset. A follow-up study. *Scand J Rheumatol.* 1983;12(2):139-44.
- Svantesson H, Björkhem G, Elborgh R. Cardiac involvement in juvenile rheumatoid arthritis. A follow-up study. *Acta Paediatr Scand.* 1983 May;72(3):345-50.
- Miller JJ 3rd, French JW. Myocarditis in juvenile rheumatoid arthritis. *Am J Dis Child.* 1977 Feb;131(2):205-9.
- Goldenberg J, Ferraz MB, Pessoa AP, et al. Symptomatic cardiac involvement in juvenile rheumatoid arthritis. *Int J Cardiol.* 1992 Jan;34(1):57-62.
- Cottafava F, Cosso D, Guglieri F, et al. Cardiac involvement in juvenile rheumatoid arthritis. *Minerva Pediatr.* 1991 Jul-Aug;43(7-8):505-9. Italian.

14. Ward SC, Wiselka MJ, Nicholson KG. Still's disease and myocarditis associated with recent mumps infection. *Postgrad Med J*. 1988 Sep;64(755):693-5.
15. Zeft AS, Menon SC, Miller D. Fatal myocarditis in a child with systemic onset juvenile idiopathic arthritis during treatment with an interleukin 1 receptor antagonist. *Pediatr Rheumatol Online J*. 2012 Apr 10;10:8.
16. Koca B, Sahin S, Adrovic A, Barut K, Kasapcopur O. Cardiac involvement in juvenile idiopathic arthritis. *Rheumatol Int*. 2017 Jan;37(1):137-142. Epub 2016 Jul 14. Review.
17. Ringold S, et al. 2013 Update of the 2011 American College of Rheumatology Recommendations for the Treatment of Juvenile Idiopathic Arthritis: Recommendations for the Medical Therapy of Children With Systemic Juvenile Idiopathic Arthritis and Tuberculosis Screening Among C. Arthritis and rheumatism. 2013;65:2499-2512.
18. Nigrovic PA. Review: is there a window of opportunity for treatment of systemic juvenile idiopathic arthritis? *Arthritis Rheumatol* 2014;66:140513.
19. Giancane G, Minoia F, Davi S, Bracciolini G, Consolaro A, Ravelli A. IL-1 Inhibition in Systemic Juvenile Idiopathic Arthritis. *Front. Pharmacol.*, 2016; 7:467
20. Piel-Julian ML, et al. Early use of anakinra in adult-onset Still's disease myocarditis. *Scand J Rheumatol*. 2018 Nov;47(6):511-512. Epub 2018 Jan 2.
21. Choi AD, Moles V, Fuisz A, Weissman G. Cardiac magnetic resonance in myocarditis from adult onset Still's disease successfully treated with anakinra. *Int J Cardiol* (2014)172(1):e225–e227.
22. Oehler E, Valour F, Hachulla E, Ghawche F. Myopericarditis as the presenting manifestation of adult Still's disease. *Rev Med Interne* 2014, 35(12):827–830.
23. Luconi N, et al. Myocarditis in a young man with adult onset Still's disease successfully treated with IL-1 blocker. *Int J Cardiol*. 2015;189:220-2. Epub 2015 Apr 11. Review.

Received: 13 December 2019

Accepted: 13 December 2019

Correspondence:

Silvia Ciancia

Policlinico di Modena – Azienda Ospedaliero-Universitaria,

Largo del Pozzo, 71, 41125 Modena (MO), Italia

Tel. +390594224719

Fax +390594224034

E-mail: silvia.ciancia.18@gmail.com