



Case report

Extra-gastrointestinal stromal tumor of the pancreas: A case report



Hazem Beji^{a,b,*,**,***}, Mahdi Bouassida^{a,b}, Bassem Mroua^{a,b}, Houda Belfkih^{c,b},
Mohamed Karim M'farrej^{d,b}, Hassen Touinsi^{a,b}

^a Department of General Surgery, Hospital Mohamed Taher Maamouri, Nabeul, Tunisia

^b University Tunis El Manar, Faculty of Medicine of Tunis, Tunisia

^c Department of Oncology, Hospital Mohamed Taher Maamouri, Nabeul, Tunisia

^d Department of Pathology, Hospital Mohamed Taher Maamouri, Nabeul, Tunisia

ARTICLE INFO

Keywords:

Extra-gastrointestinal stromal tumor
Pancreas
Pancreatic neoplasms

ABSTRACT

Introduction: Gastrointestinal stromal tumors (GIST) represent the most common mesenchymal tumors of the gastrointestinal tract. In rare cases, these tumors do not develop in the gastrointestinal tract and are defined as extra-gastro-intestinal stromal tumors (EGISTs). Pancreatic EGIST is extremely rare. We reported a case of EGIST of the pancreas in a 53-year-old patient.

Presentation of case: A 53-year-old man presented with chronic epigastralgia. An enhanced CT scan showed a solido-cystic tumor of the pancreatic body-tail. The patient underwent a laparotomy. Cytology fine needle aspiration did not find any tumor cells. Enucleation was performed. Histopathology and immunohistochemical examination confirmed the diagnosis of EGIST (CD117 +, Dog-1 +) with a high risk of malignancy. The patient received adjuvant therapy. There was no evidence of disease recurrence after 8 months of follow-up.

Clinical discussion: We reported a rare case of a pancreatic EGIST. Enucleation was performed permitting to avoid distal pancreatectomy and thus decreasing morbidity rates.

The clinical presentation is not specific and it depends on the location and the size of the tumor. CT scan shows hypervascular tumors with no regional lymph nodes metastasis but is not accurate in assessing diagnosis. Whenever possible, enucleation should be performed. This tumor should be considered in the differential diagnoses of pancreatic neoplasms.

Conclusion: Pancreatic stromal tumor is extremely rare. There are no specific clinical and radiologic findings. A careful decision should be made after a discussion in a multidisciplinary coordination meeting. Surgical resection is the cornerstone of the treatment. Whenever possible, enucleation is sufficient.

1. Introduction and importance

Gastrointestinal stromal tumors (GIST) represent the most common mesenchymal tumors of the gastrointestinal tract, with an annual incidence of 10 to 20 per million [1]. In rare cases, these tumors do not develop in the gastrointestinal tract and are defined as extra-gastro-intestinal stromal tumors (EGISTs). EGISTs can arise from the omentum, mesentery, gallbladder, and retroperitoneum [2–5]. Pancreatic EGIST is extremely rare [6]. It represents a diagnostic and therapeutic challenge as there are no standardized guidelines for these sporadic neoplasms. We present a new case of pancreatic GIST in a 53-year-old man.

This work has been reported in line with the SCARE 2020 criteria [7].

2. Presentation of a case

A 53-year-old man, with no comorbidities, complained of chronic epigastralgia. There was no history of jaundice, anorexia, or weight loss. Physical examination and laboratory findings were normal.

Abdominal ultra-sonography did not show pathologic features. Contrast-enhanced computed tomography (CT) of the abdomen showed a solido-cystic mass of 5 × 4 cm located in the pancreatic body tail (Fig. 1).

* Corresponding author at: 52, Street of roses, 8050 Hammamet, Tunisia.

** Corresponding author at: University of Tunis El Manar, Tunisia.

*** Corresponding author at: Department of General Surgery, Hospital Mohamed Taher Maamouri, Nabeul, Tunisia.

E-mail address: Hazembj@gmail.com (H. Beji).

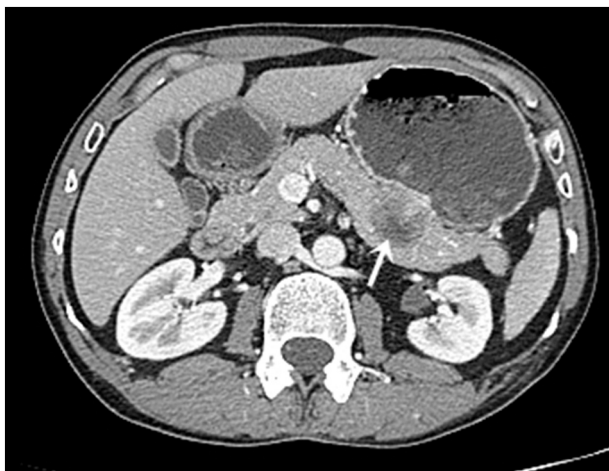


Fig. 1. Abdominal enhanced computed tomography showing a solido-cystic mass located in the pancreatic body-tail (arrow).

A solid pseudopapillary tumor of the pancreas was the most likely diagnosis.

An exploratory laparotomy was carried out by a 12-years-experience surgeon. Cytology fine needle aspiration did not find any tumor cells.

Careful enucleation of the tumor was performed. There was no contact with the main pancreatic duct. The postoperative course was uneventful.

Histopathology examination showed neoplastic cells that are epithelioid with faintly eosinophilic or clear cytoplasm. Nuclei are round to oval, vesicular, with conspicuous but not prominent nucleoli. Nuclear pleomorphism is minimal (Fig. 2).

Immunohistochemical examination showed neoplastic cells positive for CD-117 and DOG-1 (Fig. 3).

The diagnosis of EGIST with high of malignancy was retained. The patient received Imatinib as adjuvant therapy.

With a follow-up of 8 months, there was no evidence of recurrent disease.

3. Clinical discussion

We reported a rare case of pancreatic EGIST. Enucleation was performed permitting to avoid distal pancreatectomy and thus decreasing

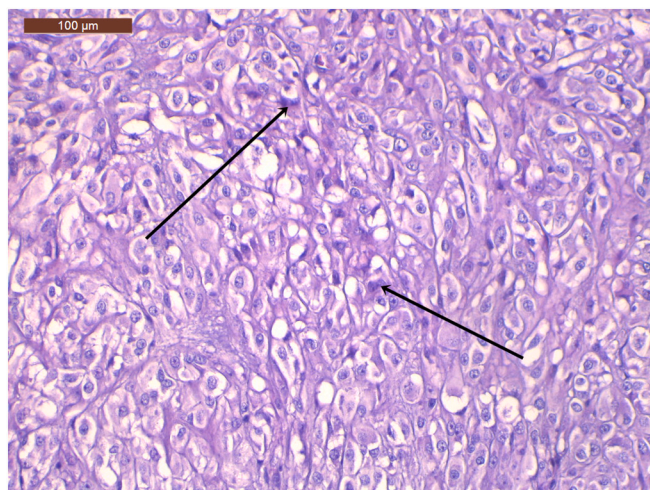


Fig. 2. Neoplastic cells are epithelioid with faintly eosinophilic or clear cytoplasm. Nuclei are round to oval, vesicular, with conspicuous but not prominent nucleoli. Nuclear pleomorphism is minimal (H&E, 200 \times) (arrow: mitoses).




Fig. 3. DOG-1 immunostaining. Tumor cells show strong and diffuse membrane staining (IHC, 40 \times).

morbidity rates.

The main weakness of our work is that preoperative endoscopic ultrasound (EUS) with fine-needle aspiration was not performed.

EGIST represents less than 5 % of all GIST [6]. The concept of GIST has recently been established with the progress in immunohistochemical analyses.

It is suggested that these tumors originate from the interstitial cells of Cajal (ICCs) which are the pacemaker cells of the gastrointestinal tract.

But the origin of EGIST is controversial. It was suggested that EGISTs are in fact mural GISTs with extensive extramural growth that lost their connection with the gut wall [8].

The clinical presentation is not specific and it depends on the location and the size of the tumor. Those symptoms are essentially chronic abdominal pain, early satiety, anemia, and weight loss [9].

In imaging, small tumors appear as homogeneous soft tissue masses, while large tumors often have necrotic centers. CT scan shows hypervascular tumors with no regional lymph nodes metastasis but is not accurate in assessing diagnosis [6]. These are the main differences with pancreatic cancer. In our case, the tumor presented as a solido-cystic lesion in the CT scan.

EUS guided fine-needle aspiration is an accurate method of diagnosis [10–12]. However, it could cause scarring and thus make enucleation more difficult. In addition, it may increase the risk of tumor dissemination by breaking the tumor capsule.

The diagnosis of pancreatic GIST is based on histological, immunohistochemical, and molecular features [13]. Positivity for CD 117, CD 34, and/or Dog-1 is highly specific to GIST [14]. It was suggested that Dog-1 has higher specificity than CD-117 [15].

Surgery is the preferred treatment for pancreatic GIST [13]. Those tumors present rarely metastatic lymph nodes. Consequently, regional lymph node dissection is not required. Simple tumor excision, when feasible, is a safe option permitting to avoid morbidity and mortality related to distal pancreatectomy or Whipple procedure [6].

In our case, we opted for a cytology fine needle aspiration during the laparotomy to rule out differentials such as cystadenocarcinoma. In that case, we would have performed a distal pancreatectomy with splenectomy.

For patients having large EGISTs, Imatinib before surgery can reduce tumor size, increase the rate of complete resection and improve prognosis [16]. For unresectable or metastatic GISTs, Imatinib can improve the survival rate [17].

In summary, we reported a new case of EGIST arising from the pancreas, presenting as a solido-cystic lesion, misinterpreted initially like a solid pseudopapillary tumor of the pancreas.

4. Conclusion

Pancreatic stromal tumor is extremely rare. There are no specific clinical and radiologic findings. A careful decision should be made after a discussion in a multidisciplinary coordination meeting. Surgical resection is the cornerstone of the treatment. Whenever possible, enucleation is sufficient.

Sources of funding

This research did not receive any specific grant from funding agencies in the public, commercial, or not-for-profit sectors.

Ethical approval

Not required.

Consent

Written informed consent was obtained from the patient for publication of this case report and accompanying images. A copy of the written consent is available for review by the Editor-in-Chief of this journal on request.

Author contributions

Hazem Beji and Mahdi Bouassida did the conception and design of the work, the data collection, and the data analysis and interpretation.

Bassem Mroua and Houda Belfkih did the critical revision of the article.

Mohamed Karim M'farrej and Hassen Touinsi did the final approval of the version to be published.

Registration of research studies

Not applicable.

Guarantor

Dr. Hazem Beji.

Provenance and peer review

Not commissioned, externally peer-reviewed.

Declaration of competing interest

No conflicts of interest.

References

- [1] A.W. Beham, I.M. Scheefer, P. Schuler, et al., Gastrointestinal stromal tumors, *Int. J. Color. Dis.* 27 (2012) 689–700.
- [2] H. Joensuu, P.J. Roberts, M. Sarlomo-Rikala, et al., Effect of the tyrosine kinase inhibitor STI571 in a patient with a metastatic gastrointestinal stromal tumor, *N. Engl. J. Med.* 344 (2001) 1052–1056.
- [3] J.D. Reith, J.R. Goldblum, R.H. Lyles, et al., Extragastric (soft tissue) stromal tumors: an analysis of 48 cases with emphasis on histologic predictors of outcome, *Mod. Pathol.* 13 (2000) 577–585.
- [4] M. Miettinen, J. Lasota, Gastrointestinal stromal tumors: pathology and prognosis at different sites, *Semin. Diagn. Pathol.* 23 (2006) 70–83.
- [5] M. Miettinen, J.M. Monihan, M. Sarlomo-Rikala, et al., Gastrointestinal stromal tumors/smooth muscle tumors (GISTs) primary in the omentum and mesentery: clinicopathologic and immunohistochemical study of 26 cases, *Am. J. Surg. Pathol.* 23 (1999) 1109–1118.
- [6] Y.T. Tian, H. Liu, S.S. Shi, et al., Malignant extra-gastrointestinal stromal tumor of the pancreas: report of two cases and review of the literature, *World J. Gastroenterol.* 20 (3) (2014) 863–868.
- [7] R.A. Agha, T. Franchi, C. Sohrabi, G. Mathew, for the SCARE Group, The SCARE 2020 guideline: updating consensus surgical Case REport (SCARE) guidelines, *International Journal of Surgery* 84 (2020) 226–230.
- [8] A. Agaimy, Gastrointestinal stromal tumors (GIST) from risk stratification system to the new TNM proposal: more question and answers? A review emphasizing the need for a standardization GIST reporting, *Int. J. Clin. Exp. Pathol.* 3 (2010) 461–471.
- [9] V. Beltrame, M. Gruppo, D. Pastorelli, et al., Extra-gastrointestinal stromal tumor of the pancreas: case report and review of the literature, *World J. Surg. Oncol.* 23 (12) (2014) 105.
- [10] B.M. Yan, R.K. Pai, J. Van Dam, Diagnosis of pancreatic gastrointestinal stromal tumor by EUS guided FNA, *JOP* 9 (2008) 192–196.
- [11] T. Harindhanavudhi, T. Tanawuttivat, J. Pyle, et al., Extragastric stromal tumor presenting as hemorrhagic pancreatic cyst diagnosed by EUS-FNA, *JOP* 10 (2009) 189–191.
- [12] K. Akahoshi, Y. Sumida, N. Matsui, et al., Preoperative diagnosis of gastrointestinal stromal tumour by endoscopic ultrasound-guided fine needle aspiration, *World J. Gastroenterol.* 13 (2007) 2077–2082.
- [13] O. Daum, J. Klecka, J. Ferda, et al., Gastrointestinal stromal tumor of the pancreas: case report with documentation of KIT gene mutation, *Virchows Arch.* 446 (2005) 470–472.
- [14] H. Beji, M. Bouassida, S. Zribi, et al., Ileal gastrointestinal stromal tumor causing mesenteric gangrene, *Clin. Case Rep.* 10 (4) (2022), e05772.
- [15] Z. Peng, K. Wu, Q. Tong, et al., Expression of DOG-1 in gastrointestinal stromal tumors and its significance, *Zhonghua Wei Chang Wai Ke Za Zhi.* 16 (3) (2013) 256–259. Chinese.
- [16] A. Mearadji, M.A. den Bakker, A.N. van Geel, et al., Decrease of CD117 expression as possible prognostic marker for recurrence in the resected specimen after imatinib treatment in patients with initially unresectable gastrointestinal stromal tumors: a clinicopathological analysis, *Anti-Cancer Drugs* 19 (2008) 607–612.
- [17] J. Wilson, M. Connock, F. Song, et al., Imatinib for the treatment of patients with unresectable and/or metastatic gastrointestinal stromal tumours: systematic review and economic evaluation, *Health Technol. Assess.* 9 (2005) 1–142.