

# Foramen Magnum Meningioma: Some Anatomical and Surgical Remarks through Five Cases

Keyvan Mostofi

*Department of Neurosurgery, Centre de Chirurgie Endoscopique de Rachis, Clinique Bel Air, Bordeaux, France*

**Study Design:** Foramen magnum meningioma foramen magnum meningioma (FMM) represents 2% all of meningiomas. The clinical symptomatology is usually insidious and consists of headache, neck pain and hypoesthesia in C2 dermatome. Because of their location, the management is challenging.

**Purpose:** The purpose of this paper is to present our experience in the surgery of FMM.

**Overview of Literature:** Since 1938, numerous series have been published but they are very heterogeneous with high variability of location and surgical approaches.

**Methods:** During two years, we operated 5 patients with FMM. All the patients had magnetic resonance imaging (MRI) with angiography to study the relationship between tumour and vertebral artery (VA). In all the cases, we used prone position.

**Results:** In one case, considering the tumour localization (posterior and pure intradural) the tumour was removed via a midline suboccipital approach with craniotomy and C1–C2 laminectomy. In all other cases, meningiomas were posterolateral (classification of George) with extradural extension in one case. In all cases, VA was surrounded by tumor. So, we opted for a modified postero-lateral approach with inverted L incision, craniotomy and C1–C2 laminectomy without resect occipital condyle. Epidural part of VA was identified and mobilized laterally. Once VA was identified we opened dura mater and began to remove the tumour.

**Conclusions:** In this paper, we present five cases of operated FMM, describe our approaches, the reason of each approach and propose some surgical remarks.

**Keywords:** Craniocervical; Foramen magnum; Meningioma; Surgical approach; Neurosurgery; Posterior cranial fossa

## Introduction

Foramen magnum meningiomas (FMM) are described as meningiomas whose insertion zones are mainly situated in the foramen magnum (FM) area [1]. George [2] and George et al. [3,4] defined this area as a zone delimited anteriorly by the lower third of the clivus and upper edge of the body of axis (C2); laterally by the jugular tubercles and upper aspect of C2 laminae; and posteriorly by the

anterior edge of the squamous occipital bone and C2 spinous process. The FMM were presented for the first time by Hallopeau [5,6] in 1872 and after fifty years, in 1922, Frazier and Spiller [7] reported the first successful removal of this type of tumor. FMM correspond to only 1.8% to 3.2% of all the meningiomas [8]. The knowledge of FM area's anatomy is of extreme importance for treating these lesions. Many classifications have been proposed aiming to help the surgeon regarding the best

Received Apr 17, 2014; Revised May 11, 2014; Accepted May 25, 2014

Corresponding author: Keyvan Mostofi

Department of Neurosurgery, Clinique Bel Air, 136, avenue de la République, 33000, Bordeaux, France

Tel: +33-556-51-51-60, Fax: +33-556-51-51-61, E-mail: [keyvan.mostofi@yahoo.fr](mailto:keyvan.mostofi@yahoo.fr)

surgical approach and expected changes in the anatomy of these critical structures. FMM can be classified regarding their dural relationship: they are normally strictly intradural but ten percent of them can have an extradural extension presenting as intra and extradural tumors and, more rarely, strictly extradural [1], what turns the complete removal more difficult as the extradural meningiomas are more invasive and can infiltrate into the bone and neurovascular sheaths [1]. FMM can also be classified taking the dentate ligament as a reference. According to Boulton and Cusimano [9], the spinal dentate ligament delineate the anterior and posterior compartments with most of the lesions (68%–98%) [10] arising anterolaterally, followed by postolateral, purely posterior and, more rarely, purely anterior. Bruneau and George [1] use this ligament to classify the FMM according to their insertion in the dura as anterior, if insertion is on both sides of the anterior midline; lateral, if it is between the midline and the dentate ligament; or posterior, if the insertion occurs posterior to this ligament. According to them, this classification becomes very important in surgical strategy as the displacement of the spinal cord varies according to the position of the meningioma: anterior ones push the spinal cord posteriorly, needing an extended drilling of the medial part of FM's lateral wall; and lateral ones push it posterolaterally, offering a wider opening of the surgical access [8]. Another classification is proposed according to meningioma's size in relation to the transverse dimension of the FM as small, medium or large, respectively, if it is smaller than one third, between one third and a half or more than a half of it [1]. Finally, the FMM can be classified regarding their relation to the vertebral artery (VA) as growing above, below or on the both sides of it, what can help anticipating the lower cranial nerves (CN) displacement [1].

The many important and vital anatomical structures of FM area have already been thoroughly explained and illustrated in some articles [1,11,12]. The surgeon must be familiar with this anatomy to perform surgeries of FMM. The course of the V3 and V4 portions of the VA, as going posteromedially from the transverse process of atlas and, then, upwards in the direction of the FM to join the contralateral one and form the basilar artery (BA); the posterior inferior cerebellar artery (PICA) and the spinal arteries, branches of VA and anterior inferior cerebellar artery, arising from BA; the CN, specially the lower ones as CN IX, X, XI, that arise from the postolivary sulcus

and after passing anterior to Foramen of Luschka and its protruding choroid plexus and, then, posterior to VA, penetrate together the jugular foramen [13] and the CN XII, which arises ventral to the olive in the preolivary sulcus, passes behind the VA and reaches the hypoglossal canal [13]. In this paper, the authors present five cases of operated FMM, describe their approach, the reason of each approach and propose some surgical remarks.

## Materials and Methods

From 2007 to 2011, we operated 5 patients with FMM. There were four female and one male (F/M=4/1). All the patients had magnetic resonance imaging (MRI) with angio-MRI. The MRI led to diagnosis and Angio-MRI was used to study the relationship between tumour and VA. In all cases, we used prone positioning. In one case—Patient 1—, the tumour was situated posterior and pure intradural and was removed via a midline suboccipital approach with craniotomy and C1–C2 laminectomy (Fig. 1).

## Results

In all other cases, meningiomas were posterolateral, (2 cases were on the left side and 2 cases on the right side). So, in these four cases, a postero-lateral suboccipital approach was chosen. The positioning was prone with the head in neutral position and turned slightly to the operated side. In two cases—Patient 2 and Patient 3—(one in left and other in the right side) there were extradural extension and VA was surrounded by tumour in junction of V3–V4.

The average age was 51.6 years (range, 42 to 59 years).

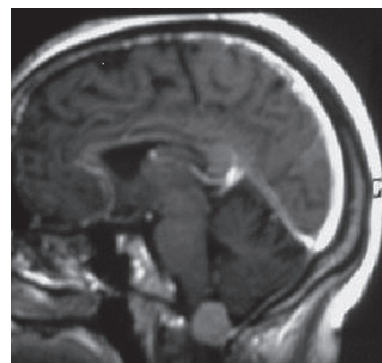


Fig. 1. Patient 1: pure intradural posterior meningioma.

**Table 1.** Main characteristics of patients

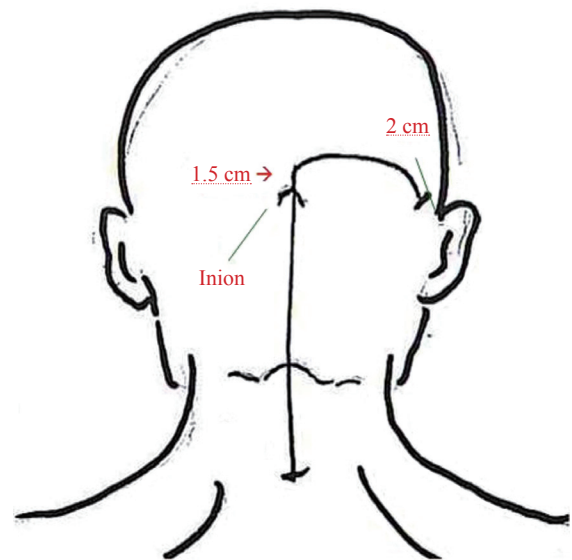
Patient	Age (yr)/sex	Signs and symptoms	Surgical approach	Tumour location	Postoperative complication
1	59/female	Headache, cervicalgia	MSO	Posterior intradural	Transient disorientation
2	54/female	Occipital and neck pain	PLSO	Right posterolateral	Nothing
3	42/male	Left upper extremity, weakness, C2 dysesthesia	PLSO	Left posterolateral	Left hypoglossal palsy
4	56/female	Headache, cervicalgia	PLSO	Left posterolateral	Nothing
5	47/female	Disturbance gait, cervicalgia	PLSO	Right posterolateral	Nothing

MSO, median suboccipital; PLSO, posterolateral suboccipital approach.

The most frequent symptoms were headache and cervicalgia. One patient—Patient 3—presented left upper extremity weakness and C2 dermatomal dysesthesia. One patient—Patient 5—presented gait disturbance. The average interval between onset of symptoms and diagnosis was 12 months (range, 8–24 months). Due to unchanged preoperative motor signs in immediate postoperative period, two patients—Patient 3 and Patient 5—have been hospitalized in rehabilitation center. We had no mortality. Two of our patients presented postoperative complications: one directly related to the intervention—definitive left hypoglossal palsy in Patient 3—and the other—transient disorientation, which is improved after few days spontaneously. Mean duration of hospitalization was 10 days (range, 7–15 days). Table 1 shows main characteristics of patients.

## Discussion

All patients were operated in prone position. Despite several recent studies [14–16] that have shown safety at the sitting position in neurosurgical procedures, we prefer the prone position in particular to FMM. We believe that this position reduces the risk of air embolism, avoids fatigue hands and offers to neurosurgeon more maneuver under the operating microscope. Because of posterolateral position of tumors in four patients, we used a posterolateral suboccipital approach with inverted L incision of the skin (Fig. 2). We prefer this lateral extension of classical midline incision of midline approach toward mastoid instead of classical upper suboccipital approach, because it gives to neurosurgeon a further opportunity to have a larger operating field and optionally enlarge the craniotomy to the contralateral side to help managing the tumor and avoid resection of the occipital condyle (Fig. 3).



**Fig. 2.** Skin incision running 1.5 cm above Inion laterally and finishes 2 cm before behind the ear.

For the same reason, we preferred in four cases (Patient 2–Patient 5) an atlas laminectomy which allowed bilateral access from the both ipsilateral and contralateral side to the tumor, avoiding resection of condyle instead of an ipsilateral hemilaminectomy because the latter narrows the operating field to the tumor and has no particular advantage [1,5,6,8,9,11,13–15]. Before opening the dura-mater, sigmoid sinus was exposed but there was no need to be totally unroofed. In Patient 4 and Patient 5, in which the tumour was purely intradural, the VA was identified in the junction V3–V4 and after that, the dura-mater was opened laterally, the tumour was immediately identified and began to be removed. Careful debulking in this step permitted to identify the spinal branch of accessory nerve and the PICA. This artery was followed to reach VA in intradural portion. In these two cases, the VA was repressed

by the tumor and as this artery began to be dissected, we found a subarachnoid layer separating the tumor from VA and, thanks to this layer (Fig. 4), the VA could be detached from the tumor without any particular problems

In Patient 2 and Patient 3, the tumor surrounded an extradural portion of the VA. So, the VA began to be dissected from its extradural part which had already been identified at the time of removal of the posterior arch of the atlas. The subarachnoid layer previously described was found and permitted us to detach the VA relatively easily. Once this part of tumour was detached, we proceeded like explained above for cases 4 and 5. At the end, the tumour invasion to the intradural part of the VA was removed. Due to the tumor location, in Patient 2 the lower CN were displaced posteriorly and in Patient 3, they were displaced superiorly. In Patient 4, the left VA was surrounded intradurally by the tumour and the lower CN were displaced anteriorly. In Patient 5, the right VA was displaced laterally by the tumour just like the lower CN .

We believe that, to avoid any injury to the VA, it is better to first identify it in its epidural portion (V3). If there is any tumor attachment in V3, the tumor removal will be initially performed extradurally. Otherwise, V3 will be mobilized laterally and the removal of the tumor will be performed in its intradural part. To identify the VA Bruneau and George carried out in the same way and expose V3 from the midline of the posterior arch of the atlas laterally toward the atlas groove [13].

Al-Mefty [17] advocates systematic condyle drilling but in the past few years, a divisive debate has been raised concerning the utility of systematic condyle drilling. Condyle drilling can be considered in far-lateral approach to pure anterior lesions of the foramen magnum. We do not

include this option in the present Article because we did not had no case of pure anterior meningioma.

We believe also that a bilateral laminectomy provides a useful space for maneuver from contralateral side, enlarges the operative field, avoids the condyle resection with its extended bony removal and its consequent craniocervical instability, and reduce the necessity of fusion. It should be noted that given the retrospective nature of our study and the small number of patients, results must be interpreted cautiously.

## Conclusions

Due to the complexity of the region of the FM, the therapeutic and surgical strategy of FMM should be decided as per case. The aim of the neurosurgeon is to achieve a total resection and avoid iatrogenic lesions of the VA

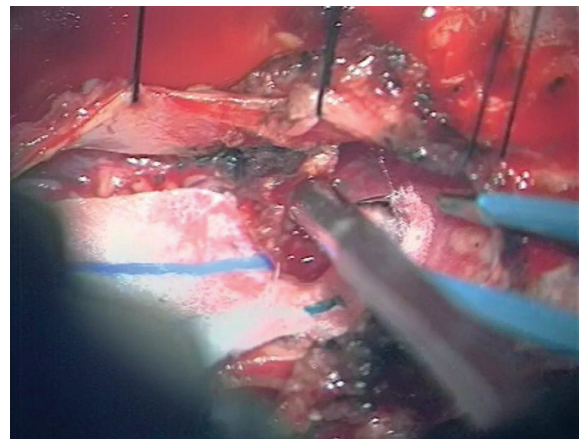


Fig. 4. Patient 2, invasion of foramen magnum meningioma to vertebral artery in junction of V3–V4 (intradural view).

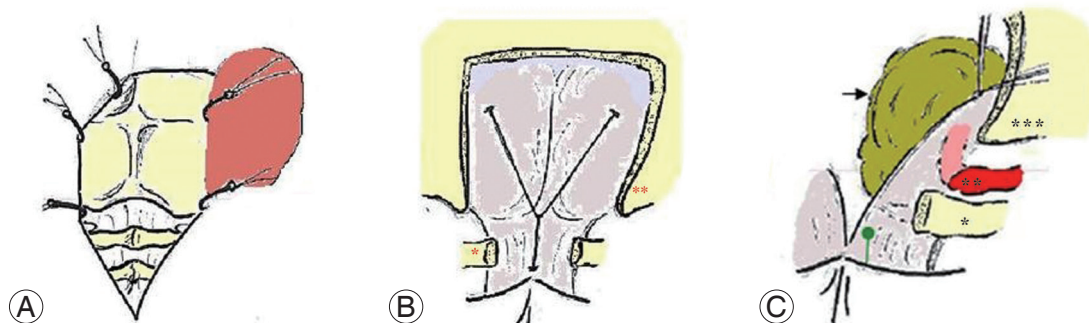


Fig. 3. Operation field. (A) Skin flap based on the ipsilateral side. (B) After craniotomy and C1 laminectomy (\*C1, \*\*occipital condyle). (C) Artist's depiction showing corridor of exposure, vertebral artery (VA) encased intradurally by meningioma (\*C1 after laminectomy, \*\*VA, \*\*\*occipital condyle).

and mixed nerves, especially the accessory nerve. A good knowledge of the regional anatomy and a thorough pre-operative study of per case region help safe dissection of the neurovascular structures with lower morbidity and mortality, providing a safer surgery.

### Conflict of Interest

No potential conflict of interest relevant to this article was reported.

### References

1. Bruneau M, George B. Foramen magnum meningiomas: detailed surgical approaches and technical aspects at Lariboisiere Hospital and review of the literature. *Neurosurg Rev* 2008;31:19-32.
2. George B. Meningiomas of the foramen magnum. In: Schmidek HH, editor. *Meningiomas and their surgical management*. Philadelphia: Saunders; 1991. p.459-70.
3. George B, Lot G, Boissonnet H. Meningioma of the foramen magnum: a series of 40 cases. *Surg Neurol* 1997;47:371-9.
4. George B, Lot G, Velut S, Gelbert F, Mourier KL. French language Society of Neurosurgery. 44th Annual Congress. Brussels, 8-12 June 1993. Tumors of the foramen magnum. *Neurochirurgie* 1993;39 Suppl 1:1-89.
5. Hallopeau H. Note sur deux faits de tumeur du mesocephale. *Gaz Med (Paris)* 1874;3:111-2.
6. Komotar RJ, Zacharia BE, McGovern RA, Sisti MB, Bruce JN, D'Ambrosio AL. Approaches to anterior and anterolateral foramen magnum lesions: a critical review. *J Craniovertebr Junction Spine* 2010;1:86-99.
7. Frazier CH, Spiller WG. AN analysis of fourteen consecutive cases of spinal cord tumor. *JAMA* 1922;79:1024-8.
8. Arnautovic KI, Al-Mefty O, Husain M. Ventral foramen magnum meningiomas. *J Neurosurg* 2000;92:71-80.
9. Boulton MR, Cusimano MD. Foramen magnum meningiomas: concepts, classifications, and nuances. *Neurosurg Focus* 2003;14:e10.
10. Bruneau M, Cornelius JF, George B. Antero-lateral approach to the V3 segment of the vertebral artery. *Neurosurgery* 2006;58:ONS29-35.
11. Matsushima T, Natori Y, Katsuta T, Ikezaki K, Fukui M, Rhoton AL. Microsurgical anatomy for lateral approaches to the foramen magnum with special reference to transcondylar fossa (supracondylar transjugular tubercle) approach. *Skull Base Surg* 1998;8:119-25.
12. Rhoton AL Jr. The foramen magnum. *Neurosurgery* 2000;47:S155-93.
13. de Oliveira E, Rhoton AL Jr, Peace D. Microsurgical anatomy of the region of the foramen magnum. *Surg Neurol* 1985;24:293-352.
14. Ammirati M, Lamki TT, Shaw AB, Forde B, Nakano I, Mani M. A streamlined protocol for the use of the semi-sitting position in neurosurgery: a report on 48 consecutive procedures. *J Clin Neurosci* 2013;20:32-4.
15. Duda I, Grzybowska K, Jedrzejowska-Szypulka H, Lewin-Kowalik J. The sitting position during neurosurgical procedures does not influence serum biomarkers of pulmonary parenchymal injury. *BMC Surg* 2012;12:24.
16. Feigl GC, Decker K, Wurms M, et al. Neurosurgical procedures in the semisitting position: evaluation of the risk of paradoxical venous air embolism in patients with a patent foramen ovale. *World Neurosurg* 2014;81:159-64.
17. Al-Mefty O. *Operative atlas for meningiomas*. Philadelphia: Lippincott-Raven; 1997.