

ORIGINAL ARTICLE

Lessons learnt from prenatal exome sequencing

Natalie J. Chandler¹  | Elizabeth Scotchman¹ | Rhiannon Mellis^{1,2}  |
Vijaya Ramachandran¹ | Rowenna Roberts¹ | Lyn S. Chitty^{1,2} 

¹North Thames Genomic Laboratory Hub,
Great Ormond Street Hospital for Children
NHS Foundation Trust, London, UK

²Genetics and Genomic Medicine, UCL Great
Ormond Street Institute of Child Health,
London, UK

Correspondence

Natalie J. Chandler, North Thames Genomic
Laboratory Hub, Levels 4-6 Barclay House,
Great Ormond Street Hospital for Children
NHS Foundation Trust, London, WC1N
3BH, UK.

Email: natalie.chandler@gosh.nhs.uk

Abstract

Background: Prenatal exome sequencing (ES) for monogenic disorders in fetuses with structural anomalies increases diagnostic yield. In England there is a national trio ES service delivered from two laboratories. To minimise incidental findings and reduce the number of variants investigated, analysis uses a panel of 1205 genes where pathogenic variants may cause abnormalities presenting prenatally. Here we review our laboratory's early experience developing and delivering ES to identify challenges in interpretation and reporting and inform service development.

Methods: A retrospective laboratory records review from 01.04.2020 to 31.05.2021.

Results: Twenty-four of 116 completed cases were identified as challenging including 13 resulting in difficulties in analysis and reporting, nine where trio inheritance filtering would have missed the diagnosis, and two with no prenatal diagnosis; one due to inadequate pipeline sensitivity, the other because the gene was not on the panel. Two cases with copy number variants identified were not detectable by microarray.

Conclusions: Variant interpretation requires close communication between referring clinicians, with occasional additional examination of the fetus or parents and communication of evolving phenotypes. Inheritance filtering misses ~5% of diagnoses. Panel analysis reduces but does not exclude incidental findings. Regular review of published literature is required to identify new reports that may aid classification.

Key points

What's already known about this topic?

- Prenatal exome sequencing (ES) for monogenic disorders in fetuses with structural anomalies is known to increase diagnostic yield
- Diagnostic prenatal ES services are being embedded into clinical practice internationally

What does this study add?

- This study identifies challenges encountered running a diagnostic prenatal ES service including those in variant interpretation and reporting, incidental findings and ethical issues

This is an open access article under the terms of the Creative Commons Attribution-NonCommercial-NoDerivs License, which permits use and distribution in any medium, provided the original work is properly cited, the use is non-commercial and no modifications or adaptations are made.

© 2022 The Authors. Prenatal Diagnosis published by John Wiley & Sons Ltd.

- It demonstrates that solely relying on trio inheritance filtering will miss ~5% of diagnoses
- Close communication between scientists and referring clinicians is essential to identify evolving phenotypes
- Regular review of published literature is required to identify new reports that may alter variant classification

1 | INTRODUCTION

Traditionally, genetic analysis following the sonographic identification of fetal structural abnormalities involves karyotyping and/or microarray analysis of a sample obtained by invasive procedures to detect aneuploidy and copy number variants (CNVs). With the decreasing cost of next generation sequencing (NGS), along with the development of rapid analytical pipelines, this has become an increasingly popular technique for rapid prenatal diagnosis. There are many hundreds of single gene conditions that may present in the prenatal period with anomalies detectable by prenatal imaging. Thus, whole exome sequencing (WES) is an attractive and potentially efficient approach, with diagnostic rates reported between 10% and 80%,¹⁻⁶ for clinical identification of disease-causing variants to provide couples with a definitive diagnosis to aid decision-making and pregnancy management.

Our laboratory developed rapid prenatal clinical exome sequencing, initially focussing on fetuses with likely skeletal dysplasia.⁷ In this cohort we had a diagnostic yield of 86% with turnaround times falling to around 2 weeks. Following this success, in April 2020 we broadened the inclusion criteria to include any fetus with structural anomalies detected on prenatal imaging suggestive of a monogenic disorder where a diagnosis would impact pregnancy or neonatal management. These eligibility criteria were based on those agreed by the national team for a national service that was subsequently implemented on 1st October 2020 in the English Genomic Medicine Service, and do not include amniotic fluid or placental anomalies.⁸ Here we focus on discussing cases that have posed particular issues for reporting, to highlight challenges we encountered during the development and early months of the clinical service, and discuss how these may be overcome. We also review how many diagnoses would have been missed if inheritance filtering had solely been applied for the analysis. Finally, we report on any diagnoses identified after birth. For all cases described here trio whole exome sequencing (parents and fetus) was performed either after or concurrently with microarray testing, and sequencing was analysed with a panel of genes developed for conditions that present in the prenatal setting and can be seen by imaging.⁹ A panel approach is utilised to minimise detection of incidental findings and it also allows us to not solely rely on the use of inheritance filtering reducing the number of variants to be investigated. However, if incidental findings are identified that are actionable for the parents or fetus, these are discussed with the referring clinician and then reported, as demonstrated in cases C20-22 (Table 2). Parents are advised during pre-test counselling that such findings may arise occasionally. Here we also

discuss how using inheritance filtering in the prenatal setting can miss fetal diagnoses. In this circumstance the analysis pipeline uses the assumption that both parents are unaffected and so if pipelines filter on inheritance patterns, the inherited autosomal dominant variants would be filtered out of the dataset and therefore not identified. In the situation where a parent is thought to be affected with the disease, this information can be submitted to the pipeline to prevent an inheritance filter from removing any dominant variants carried by both the proband and the affected parent.

2 | METHODS

Collection of this data has the ethical approval of GOSH clinical audit department (ref 2781). A summary of the clinical service and laboratory methodologies used is described below.

2.1 | Patients

Referral requests were accepted from Clinical Genetics centres where patients were deemed to meet the following eligibility criteria: Fetus with multiple, multisystem, major structural and selected isolated abnormalities detected on fetal imaging where multidisciplinary review (to include clinical genetics, tertiary fetal medicine specialists, clinical scientists and relevant paediatric specialists) considers a monogenic malformation disorder is likely and molecular diagnosis may influence pregnancy or early neonatal management in the index pregnancy.⁸ In practice the fetal medicine specialist discusses the case with the local genetics team, this can be by phone or face to face in specialist clinics. The local clinical geneticist will then refer the case by email to the testing laboratory where the case is reviewed for eligibility by a team comprising clinical geneticists, clinical scientists and a fetal imaging expert. Usually the case is accepted but where the request is queried or declined further discussion with the local team occurs to determine eligibility and alternative testing approaches.

Fetal ultrasound, and where available MRI, reports were assessed by local clinical geneticists with expertise in fetal dysmorphism to ensure the criteria were fulfilled. Cases were excluded if the reviewers thought the anomalies were unlikely to have a monogenic aetiology, where the result was unlikely to affect pregnancy management or where the anomalies did not meet the eligibility criteria. Once testing was agreed, written informed consent was obtained and parental and fetal samples collected. Rapid aneuploidy testing was carried out prior to prenatal exome sequencing to rule

out the common aneuploidies and also exclude significant maternal cell contamination. Microarray analysis was carried out in parallel to the exome sequencing due to the need for rapid testing.

2.2 | Laboratory methodology

Details of DNA extraction, exome sequencing, data analysis, gene panel and variant confirmation are given in online Appendix 1.

2.3 | Variant prioritisation and classification

Whilst recognising that parts of the exome are refractory to sequencing,¹⁰ we perform whole exome sequencing, with analysis subsequently focussing on a panel of 1205 genes where there is deemed sufficient evidence for a prenatal phenotype detectable by imaging (see Genomics England PanelApp for more details⁹). The contents of this panel are reviewed regularly and updated every 6 months. Variants were classified according to the guidelines set out by the Association of Clinical Genetic Science (ACGS),¹¹ which are based on the American College of Medical Genetics and Genomics (ACMG) guidelines.¹² Figure 1 shows the steps taken for variant prioritisation. All pathogenic/likely pathogenic variants are screened. If a pathogenic variant that explained the fetal phenotype was found during the initial prioritisation steps, it was discussed with the referring clinical geneticist and if explanatory of the fetal phenotype remaining variants were not analysed. If no pathogenic variant was identified, all variants identified by the pipeline were investigated and classified. In more complex cases further multidisciplinary discussion with clinical scientists and clinical geneticists occurred. In the majority of cases, only pathogenic and likely-pathogenic variants explaining the fetal phenotype were reported. In some cases variants of uncertain significance (VUS), which may explain the phenotype and only require a single piece of evidence to be upgraded, were taken to the multidisciplinary team for discussion and on occasion further examination of the fetus and/or parents was required. In some cases this allowed upgrading to pathogenic or likely pathogenic but in others, if a VUS had been discussed it was included on the report to highlight the need for further prenatal surveillance and postnatal investigations if appropriate.

All reported variants were confirmed by Sanger sequencing prior to reporting using standard methodology (see online Appendix 1). CNVs were confirmed by quantitative real time PCR or multiplex ligation probe amplification using conventional methods.

2.4 | Selection of cases that have posed challenges

We reviewed our laboratory database to identify those cases that had required complex multidisciplinary team discussion or further examination of fetus or parents prior to issuing a final report. We also

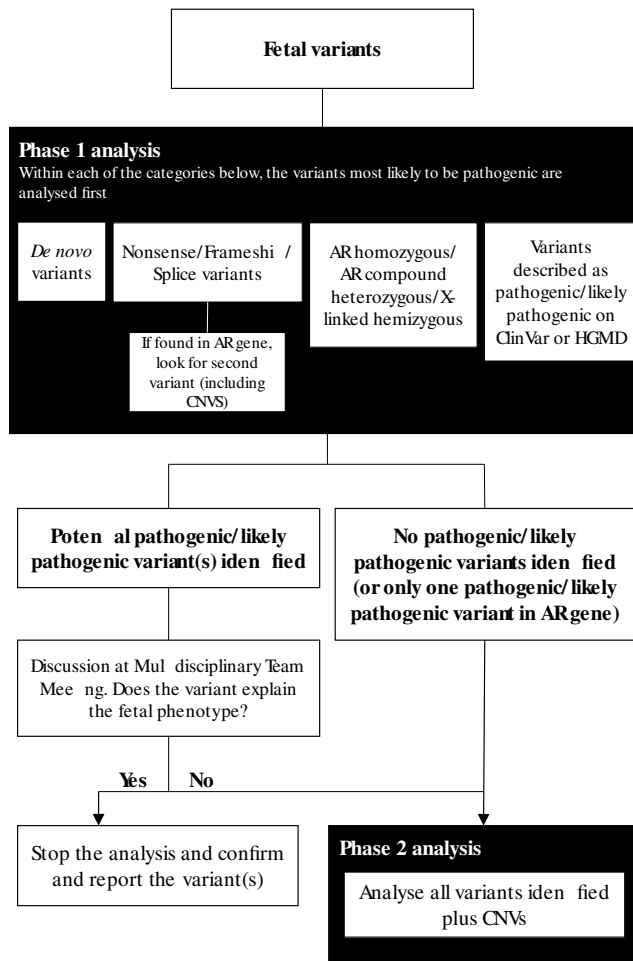


FIGURE 1 Variant prioritisation flowchart. AR, autosomal recessive; CNVs, copy number variants

identified those cases that would have not been diagnosed if inheritance filtering had been applied during analysis. Finally, we identified any case where prenatal sequencing did not identify a causative pathogenic/likely pathogenic (P/LP) variant, but a molecular diagnosis was subsequently made after birth (Table 1).

3 | RESULTS

We identified 24 (20.9%) of 113 cases sequenced as a trio and two as a duo (C19 & C22), including 13 (11.3%) raising issues in analysis or reporting, nine (7.8%) where trio inheritance filtering would have missed the diagnosis and two (1.7%) cases where the diagnosis was missed by our pipeline (Table 1). In 16 of these cases pathogenic variants were ultimately reported with 13 of these consistent with a diagnosis that explained (or partially explained) the phenotype (Table 2). In three cases only a single pathogenic variant was identified in a recessive gene compatible with the phenotype so a diagnosis could not be confirmed. In six cases variants were reported following multidisciplinary team discussion but without confirmation of diagnosis, including variants of uncertain significance ($n = 3$) where

TABLE 1 Criteria for inclusion as a case of interest

Category	Cases identified
Trio inheritance filtering would have missed diagnosis (<i>n</i> = 9)	Autosomal dominant condition – variable expressivity/“unaffected” parent heterozygous (C5, C7 and C8) AD condition – parent somatic mosaic (C9 and C10) Two AD pathogenic variants detected: 1 de novo and 1 inherited (C6) One pathogenic variant reported in autosomal recessive gene (C11, C12 and C13)
Challenges in variant interpretation (<i>n</i> = 7)	Evolving prenatal phenotype led to upgrade in variant classification during pregnancy (C1) Partially able to explain phenotype (C4) Variant of uncertain clinical significance reported requiring phenotypic follow up postnatally (C2, C17, C18 and C19) New literature enabled upgrade to likely pathogenic (C3)
Ethical challenge (<i>n</i> = 1)	Non-paternity (C16)
Diagnoses not detected by fetal exome sequencing (<i>n</i> = 2)	Mosaic pathogenic variant <10% in fetal sample not detected due to pipeline sensitivity (C23) Gene not on fetal anomalies panel (C24)
Copy number variant (<i>n</i> = 2)	Multi-exon deletions or duplications not detected by microarray (C14 and C15)
Incidental findings (<i>n</i> = 3)	Variants reported in parents irrelevant to current pregnancy but with implications for future pregnancies or parental health (C20, C21 and C22)

Abbreviation: AD, autosomal dominant.

further examination after birth may help confirm a diagnosis, and incidental findings of relevance to parents only (*n* = 3). Reasons for reporting are detailed in Table 3.

3.1 | Challenges in variant interpretation

In three cases (C1, C2 and C3) variants were initially reported as VUS but were upgraded to pathogenic following further information received regarding the variant from another diagnostic laboratory from the ClinVar entry (C2), the phenotype evolving at a scan later in gestation to be more aligned with published reports (C1) and new data published in the literature (C3). A pathogenic variant was reported in one fetus (C4) after multidisciplinary team discussion (MDT) even though the prenatal phenotype only partially matched the recognised phenotype. This case was an early diagnosis of a fetal cardiac anomaly initially presenting as increased nuchal translucency (NT) and the early gestation was thought to preclude detection of other potential associated anomalies. Postnatal examination however allowed better characterisation of the cardiac anomaly and revealed additional features consistent with the prenatally reported pathogenic variant (Table 2).

In three cases variants were reported as VUS with recommendations for postnatal follow up (C17, C18 and C19). In one case (C17) the variant arose de novo in the fetus, but in another (C18) it was maternally inherited but known variability in expression did not allow for definitive reporting as pathogenic. In the third case (C19) inheritance could not be determined as a paternal sample was unavailable.

3.2 | Variants identified in parental DNA for autosomal dominant or recessive conditions that would have been missed by inheritance filtering

In six cases autosomal dominant (AD) conditions were identified where an apparently “unaffected” parent was also found to have the pathogenic variant (Table 2). Three cases where the parent was heterozygous for the variant (C5, C7 and C8) and two cases (C9 and C10) maternal somatic mosaicism was identified at levels of ~6% and ~28% respectively. In C10 the fetus had a lethal phenotype inherited from the mother who was subsequently found to have mild features of the condition. In the sixth case (C6) there were two diagnoses, a maternally inherited pathogenic variant and a de novo pathogenic variant (Table 2).

There were three cases where a single pathogenic variant in a recessive gene compatible with the phenotype had been inherited from one parent, but no second P/LP variant was identified. In these cases, the variants were reported and examination after birth confirmed the diagnosis in one case, but confirmation was not obtained in the other two (Table 2).

3.3 | Non-paternity

Analysis of case C16 identified no inherited paternal variants. After further testing and multidisciplinary team discussions this was determined to be due to non-paternity. This was discussed with the referring clinician who confirmed the situation with the mother. A

TABLE 2 Cases where a diagnosis/likely diagnosis was reported

Case	Referral GA	Imaging findings	Sequencing results	Inheritance	Class	Condition	Outcome
Challenges in variant interpretation – initially reported as VUS, subsequently upgraded (n = 3)							
C1	20 + 0	Partial agenesis of the corpus callosum; postaxial polydactyly; large hyperechogenic kidneys; VSD; Omphalocele	CCND2 NM_001759.3 c.860_861delinsAA p.(Ile287Lys) Het	AD de novo	4	Megalencephaly-polymicrogyria-polydactyly-hydrocephalus syndrome-3	Later scans: macrocephaly, abnormal brain cortexToP. No PM
C2	22 + 0	Aplasia/Hypoplasia of the cerebellar vermis; dilated 4 th ventricle; long, thickened superior cerebellar peduncle	TMEM67 NM_153704.5 c.622A > T p.(Arg208*) Het, Pat; c.2128A > G p.(Met710Val) Het, Mat	AR	5;4	Joubert syndrome 6	ToP. No PM Communication from another lab via ClinVar confirmed they also detected the c.2128A > G variant in trans with a LP variant in two siblings with features of Joubert syndrome (oculomotor apraxia and characteristic MRI findings). This confirmation of an additional proband enabled application of ACMG criterion PM3_Strong and upgrade of the variant from VUS to LP in our proband
C3	21 + 0	Severe hydrops fetalis	BICD2 NM_001003800.1 c.1624T > G p.(Cys542Gly) Het	AD de novo	4	Lower extremity predominant spinal muscular atrophy	New literature suggests association with hydrops. Variant upgraded ToP. PM: hydrops, hypoplastic lungs, fixed flexion deformities Neuropathology suggests congenital myopathy or dystrophic process
Phenotype partial fit with recognised conditions (n = 1)							
C4	16 + 2	Increased NT; Micrognathia; abnormal heart (ventricular disproportion, narrow aorta with retrograde flow)	CCDC103 NM_001258396.1 c.461A > C p.(His154Pro) Hom (parents both het)	AR	5	Primary ciliary dyskinesia 17	LB (full term). Postnatal examination: complex cardiac lesion including coarctation of the aorta & atrial isomerism, polysplenia. Consistent with PCD diagnosis
Autosomal dominant variants that would not be reported if inheritance filtering had been applied (n = 4)							
C5	32 + 6	Pleural effusion; Polyhydramnios	FLT4 NM_182925.4 c.3432-1G > A Het, Mat	AD Mat	5	Lymphatic malformation 1/ Milroy disease	LB. Ventilated for 3 days. Well since. Mum asymptomatic. Occasional (Continues)

TABLE 2 (Continued)

Case	Referral GA	Imaging findings	Sequencing results	Inheritance	Class	Condition	Outcome
C6	30 + 0	Increased NT; Hypoplastic cerebellar vermis; Pleural effusion	PTPN11 NM_002834.3 c.417G > C p. (Glu139Asp) Het; EPHB4 NM_004444.5 c.2287C > T p. (Arg763*) Het	PTPN11 AD de novo; EBHP4 AD Mat	5;5	Noonan syndrome & Lymphatic malformation 7/Capillary malformation-arteriovenous malformation 2	swelling of feet NND. PM confirmed prenatal findings Mum: evidence of skin mosaicism with subtle capillary changes when examined after the sequencing results were known
C7	21 + 4	Cloverleaf skull	SOS1 NM_005633.3 c.1649T > C p. (Leu550Pro) Het	AD Pat	5	Noonan syndrome 4	Outcome unknown No obvious features in Dad
C8	33 + 6	Large hyperechogenic kidneys	PKD2 NM_000297.4 c.419_452del p. (Gly140Alafs*82) Het	AD Pat	5	AD polycystic kidney disease 2	LB. Well, slightly echogenic kidneys Dad unaware, asymptomatic. Scans showed renal and hepatic cysts
Autosomal dominant variants found to be mosaic in a parent							
C9	21 + 0	Short long bones; femoral bowing	COL1A2 NM_000089.3 c.2845G > A p. (Gly949Ser) Het	AD - maternal mosaic in gDNA	5	Osteogenesis imperfecta	Later scans multiple fractures. ToP
C10	19 + 4	Short long bone; increased NT; narrow chest; short ribs	COL2A1 NM_001844.5 c.2365G > A p. (Gly789Ser) Het	AD - maternal mosaic in gDNA	5	COL2A1-skeletal dysplasia	NND. No PM. Mum known to have short stature and chest wall deformity thought to be constitutional
Autosomal recessive variants inherited from a parent that would not be reported if inheritance filtering had been applied							
C11	20 + 5	Short, bowed long bones; Thoracic hypoplasia; frontal bossing	DYNC2H1 NM_001080463.1 c.5558 +2T > C Het, Pat; c.4909G > T p. (Asp1637Tyr) Het, Mat	AR	5;3	Short-rib thoracic dysplasia 3	Imaging findings strongly supportive of phenotype, but insufficient evidence to upgrade class 3 variant ToP. PM: X-rays support short-rib thoracic dysplasia diagnosis, short ribs, humeri and femora, slightly bowed femora, trident acetabulum

TABLE 2 (Continued)

Case	Referral GA	Imaging findings	Sequencing results	Inheritance	Class	Condition	Outcome
C12	25 + 1	Hydriops fetalis; ventriculomegaly; Hyperechogenic kidneys	PMM2 NM_000303.2 c.691G > A p. (Val231Met) Het; no second variant	AR	5	Congenital disorder of glycosylation type 1a	Pathogenic variants in PMM2 known to cause hydriops but not specific to this gene. Variant reported for postnatal follow-up where biochemical testing could be offered to confirm or rule out diagnosis if appropriate LB. Clinical features of segmental overgrowth disorder. No relevant variant detected in blood (or in prenatal sample). Skin biopsy planned to look for mosaicism. No clinical features of CDG
C13	20 + 6	Ventriculomegaly; inferior cerebellar vermis hypoplasia; clenched hands	RELN NM_005045.3 c.1989G > A p. (Trp663*) Het; no second variant	AR	5	Lissencephaly 2	Lissencephaly will not be seen on imaging at this gestation. For follow up at later gestation/postnatally ToP. No PM
CNV detected by ES. Microarray normal (n = 2)							
C14	26 + 4	Double aortic arch; cleft palate; Aplasia/Hypoplasia of the thymus	KAT6A NM_006766.4 exon 13–17 deletion, Het (GRCh37 Chr8:41794775–41801497)	AD – de novo	5	Arboleda-Tham syndrome	Later scan showed trigonocephaly indicating craniosynostosis which is reported in KAT6A postnatally ToP
C15	12 + 0	Short long bones; frontal bossing	COL1A1 NM_000088.3 ex 40–43 deletion, Het (GRCh37 Chr17:48265892–48266636)	AD de novo	5	Osteogenesis imperfecta	No PM
Ethical issue (n = 1)							
C16	28 + 0	Increased NT; Hydronephrosis; Pulmonary stenosis; Ovarian cyst	PTPN11 NM_002834.3 c.1517A > C p. (Gln506Pro) Het	AD de novo	5	Noonan syndrome	ToP. Outcome unknown

Note: Variant classification¹⁰: 3 = variant of uncertain significance; 4 = likely pathogenic; 5 = pathogenic.

Abbreviations: ACMG, American College of Medical Genetics and Genomics; AD, autosomal dominant; AR, autosomal recessive; CNV, copy number variant; GA, gestational age; Het, heterozygous; Hom, homozygous; LB, live birth; Mat, maternally inherited; NND, neonatal death; NT, nuchal translucency; Pat, paternally inherited; PM, post-mortem; ToP, termination of pregnancy; VSD, ventricular septal defect.

TABLE 3 Cases where variants of uncertain significance and incidental findings were reported

Case	Referral GA	Imaging findings	Fetal sequencing results	Inheritance	Classification	Condition	Reason for reporting and outcome
Variants reported as VUS with recommendation for postnatal examination							
C17	32 + 0	Double outlet right ventricle, VSD; Persistent left superior vena cava; Horseshoe kidney; duplex kidney.	No pathogenic variants; SALL1 NM_002968.2 c.1072T > C p.(Ser358Pro) Het	AD – de novo	3	Townes-Brocks syndrome 1	Insufficient evidence for PS2 and PP4 evidence. Reported for postnatal follow-up LB (38 + 6). Cardiac abnormality, horseshoe kidney, hypospadias, sacral dimple, micrognathia, dysplastic ears. Normal development
C18	22 + 6	Tetralogy of Fallot; short femur	No pathogenic variants; NOTCH2 NM_024408.3 c.5683C > G p.(Arg1895Gly) Het	AD Mat	3	Alagille syndrome 2	Gene may be relevant maternally, with variable expressivity. Recommend examination of mother and baby LB (term). Tetralogy of fallot, no butterfly vertebrae or renal anomalies
C19	26 + 4	Ventriculomegaly; pyelectasis; Hyperechogenic kidneys; Polyhydramnios; muscular VSD	No pathogenic variants; MAFK1 NM_012090.5 c.15608G > C p.(Arg5203Pro) Het	AD	3	Lissencephaly 9	Paternal sample unavailable and lissencephaly may not be seen at this gestation LB (38 + 4). Bilateral ventriculomegaly, grossly dilated right pelvic kidney, normal left kidney. Further follow up planned to assess CNS and development
Incidental findings reported in parent(s) to enable parental health management or inform reproductive choices							
C20	16 + 0	Abnormal tricuspid valve; Hypoplastic right ventricle; hydrops fetalis	No pathogenic variants; GLA NM_000169.2 c.946G > A p.(Val316Ile) hemizygous variant of uncertain significance heterozygous in mother	XL	3	Fabry disease	Reported in mother for clinical follow up & enzyme testing. Miscarriage

TABLE 3 (Continued)

Case	Referral GA	Imaging findings	Fetal sequencing results	Inheritance	Classification	Condition	Reason for reporting and outcome
C21	25 + 6	Arthrogryposis multiplex congenita; Micrognathia	No pathogenic findings to explain phenotype in this pregnancy. Fetus and parents all TGM1 NM_000359.2 c.1469A > G p.(Asp490Gly) Het	AR	4	Congenital ichthyosis type 1	Reported in parents only, 1-4 risk in future pregnancies ToP. PM: Prenatal findings confirmed. Small hindbrain, dysplastic dentate and inferior olivary nuclei; dysmorphic facial features: no unifying clinical diagnosis
C22	28 + 5	Interrupted aortic arch; congenital diaphragmatic hernia	No pathogenic variants; incidental finding of <i>DHCR7</i> NM_001360.2 c.964-1G > C in fetus and mother, both het	AR	5	Smith-Lemli-Opitz	Variant does not explain phenotype but reported as it is a common variant for the condition. Patient is using a sperm donor and therefore donor DNA could be tested so that future pregnancies were not at risk NND. Diaphragmatic hernia

Note: Variant classification¹⁰: 3 = variant of uncertain significance; 4 = likely pathogenic; 5 = pathogenic.

Abbreviations: AD, autosomal dominant; AR, autosomal recessive; GA, gestational age; Het, heterozygous; Hom, homozygous; LB, live birth; Mat, maternally inherited; NND, neonatal death; NT, nuchal translucency; Pat, paternally inherited; PM, post-mortem; ToP, termination of pregnancy; VSD, ventricular septal defect.

diagnosis of Noonan syndrome was identified in the fetus however the inheritance of the variant could not be determined, and sequencing results in the parents were not reported.

3.4 | Copy number variants

Two multi-exon pathogenic deletions were detected by our analysis (Figure 2 case C14 and Figure 3 case C15). Neither of these were detected by microarray performed concurrently due to the small size of the deletions and a lack of probes within the region. For both cases the breakpoints could be seen in the sequencing reads (see Figures 2 and 3) allowing for accurate classification of the deletions. Both deletions were confirmed by alternative methods.

3.5 | Diagnoses missed by our pipeline

In one fetus presenting prenatally with a clover-leaf skull, absent septum pellucidum cavum, cardiac abnormalities and a barrel shaped chest, no P/LP variant was identified by our pipeline but the diagnosis of Curry-Jones syndrome was suspected on examination after birth. Subsequent review of the sequencing data identified a recurrent pathogenic variant in *SMO* in 6/212 (3%) of reads in the amniotic fluid DNA. The presence of the variant was confirmed using an alternate capture with deeper sequencing 57/1858 reads (3%) confirming the diagnosis. Curry-Jones syndrome is caused by varying degrees of somatic mosaicism and can on occasion not be detected in blood or saliva. Levels of somatic mosaicism reported are variable and can be very low. Thus the low level found in amniotic fluid may not necessarily reflect levels in other tissues and is compatible with other reports of this syndrome.¹³

In another fetus presenting with absent corpus callosum, bilateral ventriculomegaly, absent cavum septum pellucidum, cerebellar and brainstem hypoplasia, no P/LP variant was identified. Postnatal MRI showed pachygyria, and brainstem and basal ganglia morphology that suggested a tubulinopathy. DNA was sent for whole genome sequencing and a de novo heterozygous c.182A > G p.(Gln61Arg) likely pathogenic variant was identified in the *RAC3* gene consistent with a neurodevelopmental disorder with structural brain anomalies and dysmorphic facies. This gene was not included in the fetal anomalies panel at the time of analysis.

4 | DISCUSSION

Our review has shown that in 11.3% of cases challenges were encountered in analysis or reporting, in 7.8% inheritance filtering would result in missing a fetal diagnosis, and that our analysis pipeline missed the diagnosis in 1.7% of samples tested. The high

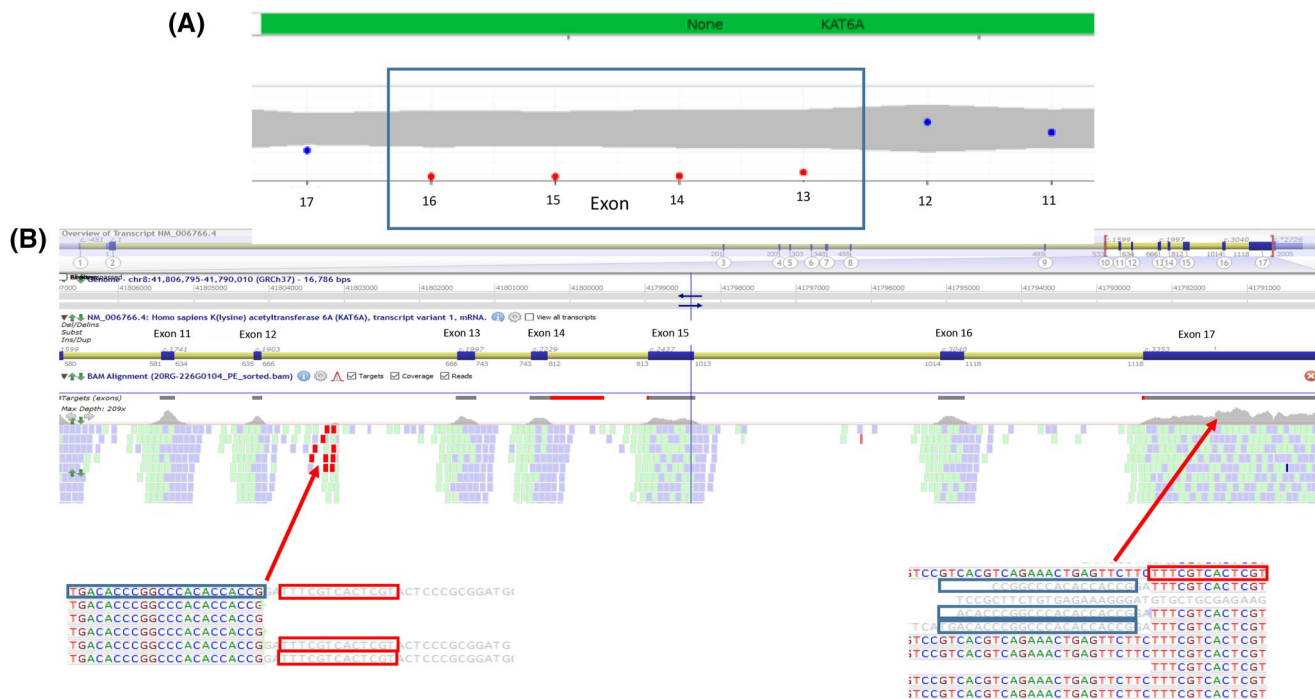

FIGURE 2 KAT6A exon 13–17 deletion detected in C14. (A) Results from our CNV analysis tool indicating a deletion of exons 13–16 of the KAT6A gene. The blue dot represents normal copy number and red dot a deletion. The grey area shows the variance in read depth for the other samples on the run. (B) The sequencing reads at the identified breakpoints. The blue box shows the matching reference sequence from intron 13 that can be seen in the reads mapping to exon 17 with an insertion of GA in between. The red box indicates the matching reference sequence from exon 17 seen in intron 12, again with an insertion of GA. The CNV analysis results did not indicate a deletion of exon 17 however the results were out of the normal range. This is consistent with the breakpoint being within the exon and with it not being called due to the size of the exon. CNV, copy number variant; GA, gestational age [Colour figure can be viewed at [wileyonlinelibrary.com](https://onlinelibrary.wiley.com)]

percentage of cases posing challenges shows that it is a complex service to run and clearly requires multidisciplinary team working, especially when working with the time pressures required for rapid delivery of results to inform pregnancy management.

4.1 | Dangers of solely relying on inheritance filtering

Trio inheritance filtering is performed to reduce the number of variants requiring analysis to expedite reporting. This analysis relies on the clinical status of the parents being unaffected and will only filter variants of interest if they fit with the required inheritance pattern; thus de novo in the fetus for an AD condition, compound heterozygous or homozygous in the fetus for an autosomal recessive (AR) condition and hemizygous for X-linked conditions with the mother carrier (or de novo). In our cohort relying on this approach for analysis would have missed P/LP variants in nine cases (7.8%) (Table 2), three due to inherited AD conditions inherited from mildly affected/“unaffected” parents, two due to somatic mosaicism in the parents and three single pathogenic variants reported in a recessive gene compatible with the phenotype. In the ninth case two pathogenic variants were identified (C6), one de novo and one inherited. If inheritance filtering alone had been used in this case the inherited diagnosis, with the higher

recurrence risk, would have been missed. There have been other cases with a dual diagnosis reported in literature in prenatal exome cohorts¹⁴ and therefore a potential second diagnosis should be considered in any analysis pipeline. Imprinted genes also need to be considered. We have not encountered this yet, but there is a report of a *MAGEL2* pathogenic variant inherited from the father who is unaffected due to the pathogenic variant being on his maternally inherited allele.¹⁵

Many AD conditions have variable expressivity and age of onset and parents may often be unaware of carrier status, as with some of our cases (Table 2) and others reported in the literature.^{1,2,7,16–19} Further, referrals for fetal exome sequencing come from fetal medicine units, often with limited input from clinical geneticists and so examination of parents and ascertaining the family history may be more limited. Indeed, the father may often not be present at the time of the scan. The occasional identification of parental carrier status is something that should be included in parental pre-test counselling.

Parental mosaicism must also be considered when applying filters to exome datasets as seen in two of our cases (C9 and C10, Table 2). In one case a heterozygous *COL1A2* variant was identified that was initially thought to have arisen de novo in the fetus. Parental sequencing reads were inspected at the site of the variant as per laboratory policy and the variant was seen in about 6% of reads from the unaffected mother, too low to be called by our

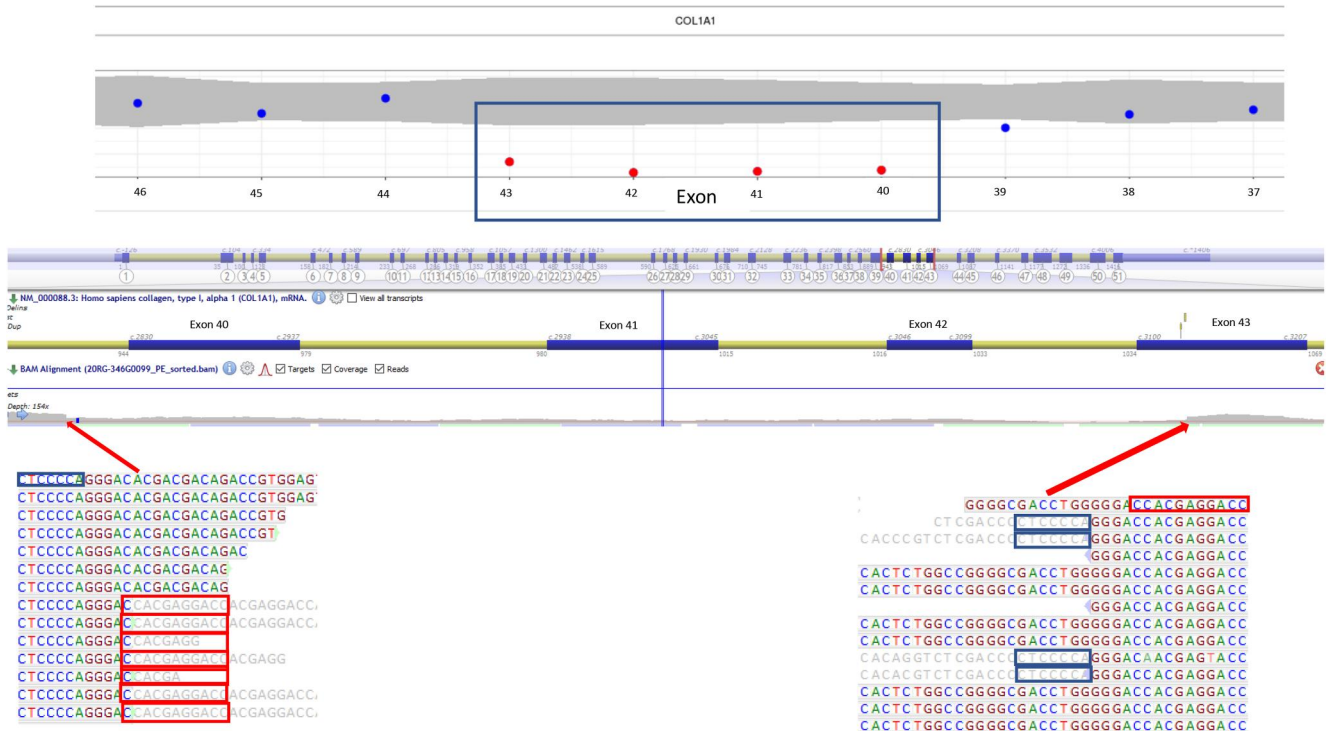

FIGURE 3 COL1A1 exon 40–43 deletion detected in C15. (A) Results from our CNV analysis tool indicating a deletion of exons 40–43 of the COL1A1 gene. The blue dot represents normal copy number and red dot a deletion. The grey area shows the variance in read depth for the other samples on the run. (B) The sequencing reads at the identified breakpoints. The blue box shows the matching reference sequence from intron 39 that can be seen in the reads mapping to exon 43 with insertion of GGGG from the exon 43 sequence in between. The red box indicates the matching reference sequence from exon 43 seen in intron 39, again with an insertion of GGGG. CNV, copy number variant [Colour figure can be viewed at wileyonlinelibrary.com]

pipeline. Although in this case the use of inheritance filtering would not have changed the outcome, it highlights an important consideration for mosaicism and the need for manual inspection of parental sequencing reads for all “*de novo*” cases, as recurrence risks in this case are now high, as compared to a germline mosaicism risk. In our second case (C10), the fetus had a lethal phenotype and the mother was subsequently diagnosed with mild features when examined by a clinical geneticist when returning the ES results. Asymptomatic parents may be a somatic mosaic for a pathogenic variant with a variant allele frequency (VAF) high enough to be called by a variant caller, but these variants may then be filtered out if the inheritance does not fit that expected based on the family history and clinical information available. In the prenatal setting this is especially important to consider for conditions such as osteogenesis imperfecta, which often presents prenatally and for which mosaicism^{20,21} and variable expressivity^{22,23} are common and have been reported previously.^{4,24} It is therefore crucial that mosaicism is considered when designing pipelines and cut-offs for VAFs, although this will highly depend on the quality of the sequence data and will often not be straight forward.

For cases with AR inheritance diagnoses can be missed where only one potentially pathogenic heterozygous variant is identified, or if they do not fit the expected inheritance (i.e., both parents are not carriers). For cases with single pathogenic variants the second variant could be missed due to the presence of a CNV on the

other allele (if the pipeline does not take this into consideration), gaps in the coverage of the gene, or if the second variant is not detectable by exome sequencing, for example, because it is deeply intronic. For cases that do not fit the expected inheritance pattern there could be uniparental disomy or a *de novo* variant on the other allele. It is important to note that it is not routine practice to report all single pathogenic variants identified in prenatal ES cases and that MDT discussion is crucial to ensure the variant fits the fetal phenotype. Further postnatal investigations should be encouraged in this situation as these may confirm a diagnosis as with our case (C11) (Table 2) and others reported in the literature,^{7,19} enabling accurate counselling with regard to a 1:4 recurrence risk.

4.2 | Challenges in variant interpretation

In our laboratory we aim to only report P/LP variants consistent with the fetal phenotype but VUSs may be reported when they are considered “hot” class 3s (where they only require a single piece of evidence to be upgraded, such as phenotypic fit or publication in the literature) and reporting is agreed at multidisciplinary team meetings. This is in agreement with others.²⁵ There are increasing examples of new prenatal phenotypes being identified in conditions with a well-recognised postnatal phenotype that is very different from that

which we see prenatally,^{1,26} or ones that evolve as pregnancy progresses. In our series this was illustrated by two cases (C14 and C1) (Table 2). The phenotype of postnatal cohorts reported with *KAT6A* pathogenic variants^{27,28} did not align with the prenatal findings in our case until craniosynostosis developed in the third trimester. Similarly in another case (C1) it was only when later scans showed the development of macrocephaly and cortical abnormalities in keeping with postnatal findings in this condition, that the *CCND2* variant was upgraded to class 4 LP. Both of these cases show the need for repeat scans and ongoing multidisciplinary discussions to identify new and evolving phenotypes that may alter variant classification.

Further changes in classification may arise from new information in the literature (C3) or received from another laboratory (C2). The case with a *BICD2* variant presented with hydrops (C3), but at the time of initial reporting this was not a reported feature of this condition, but the following week a paper was published linking hydrops to a *BICD2* pathogenic variant,²⁹ allowing upgrade to LP. More evidence was found from the post-mortem which showed the typical histological changes. This also illustrates the value of a post-mortem even when a molecular diagnosis has been made to document evidence of prenatal phenotypes for the future. The value of data sharing was shown in our case (C2) with biallelic *TMEM67* variants. Initial classification of the paternally inherited variant was pathogenic, but the maternal variant only had sufficient evidence for a VUS. This variant was in ClinVar³⁰ as pathogenic, and after several weeks we received further information regarding segregation in affected family members, enabling reclassification to class 4, LP.

The cases discussed above are examples of how changing prenatal phenotypes or new information can change variant classification during pregnancy, but there are also cases where information may only be available postnatally, or where early ultrasound may limit prenatal phenotyping (C4). We identified a number of cases (C17, C18 and C19) where the variants have remained VUS awaiting postnatal follow-up (Table 2).

It is therefore important that parents are counselled that they may receive an uncertain result when undergoing prenatal ES and that results reported may change over the course of the pregnancy as the phenotype evolves (C1, C14) or as new information becomes available from the literature (C3) or another laboratory (C2), and that in some cases the uncertainty may persist until further investigation after birth (C17, C18, C19) (Table 2). From the health professional perspective, many of these cases illustrate the need to share data and publish new phenotypes as they are identified.

4.3 | Incidental findings

In England the current policy for genome sequencing both pre- and postnatally is to minimise identification of incidental findings by using a panel approach to analysis. However, in three of our cases variants were reported in parents but not the fetus, as they may have implications for a parent's health (C20) or risks for future pregnancies (C21 and C22) (Table 3).

4.4 | Ethical issues

There was one case of non-paternity in our cohort (C16, Table 2) whereby a heterozygous supposedly de novo pathogenic *PTPN11* variant was identified in the fetus but no paternally inherited variants, and there were many other variants called as de novo. This presented a challenge in how to report the case and the likely recurrence risk, complicated by the fact that pathogenic variants in the *PTPN11* gene have variable expressivity and therefore the biological father could be affected but not aware. The case exemplifies that unlike conventional genetic prenatal testing methodologies trio ES will detect non-paternity and therefore this needs to be made clear in any pre-test counselling so that the family are prepared for situations like this.

4.5 | Microarrays should be run in parallel

Microarray is still the gold standard for detecting copy number variants in fetuses with structural anomalies and we perform ES concurrently with microarray. The resolution of microarray depends on the probe capture used; in our laboratory this is 300 kb. In our cohort, we identified two pathogenic multi-exon deletions that were not detected by microarray due to the size of the deletions and the lack of probes in the region. In addition, we were able to accurately map the breakpoints which is not achievable using microarray thus allowing for a more accurate classification of the deletions. These cases further demonstrate the utility of short-read sequencing to detect CNVs as reported by others,^{31,32} but that microarray should be performed as CNV detection by ES is limited to exons or in close proximity to exons. This may change if whole genome sequencing is performed.

4.6 | Diagnoses missed by our analysis approach

In two fetuses, no LP/P variants were identified by our pipeline, but postnatal clinical examination raised suspicion of a genetic condition. In the first case, the diagnosis of Curry-Jones syndrome was missed due to low level (6%) somatic mosaicism of the pathogenic variant. This is below the known sensitivity of our pipeline which is 10%. This raises two issues. The first, that it is important to be aware of limitations of the pipeline and clearly state sensitivity settings on report. The second, that interpretation of mosaicism detected from analysis of amniocytes may be difficult to interpret prenatally in the absence of a clinical phenotype. The second case had a *RAC3* pathogenic variant, but at the time of reporting this gene was not included on the fetal panel in PanelApp⁹ as the phenotype for pathogenic variants in this gene has only been described recently both postnatally³³ and prenatally³⁴ and it therefore hadn't yet been reviewed for addition to the panel. This demonstrates the limitations of a panel-based analysis and also the importance of keeping abreast of current literature to regularly update panels applied to ES data and of data sharing.

Additionally, the panel version should be clearly stated on the report, so the referrer is able to assess which genes have been analysed.

Finally, we recognise that in using a panel approach to analyse the whole exome sequencing we will not identify novel genes, but this approach has been taken to enable a rapid turnaround time with equity of access to testing across the whole country. Having the whole exome available can enable further investigation over time, but not in the time course to influence pregnancy management.

5 | CONCLUSIONS

In conclusion, solely applying inheritance filtering will potentially miss a significant proportion of pathogenic variants. The panel approach to analysing the whole exome reduces but does not eliminate incidental findings and precludes identification of novel genes. As the prenatal phenotype is often incomplete or evolving, close communication between referring clinicians and clinical scientists is required for interpretation of sequence data, with additional detailed examination of the fetus or parents needed in some cases. Finally, close attention to the published literature is required to identify new reports that may aid classification and also identify new genes for addition to panels so that they stay up to date. Parents and health professionals should also be aware that testing is complex and further examination of the fetus, parents or neonate may be required to reach a diagnosis, and that sometimes this may have implications for the parents' own health.

ACKNOWLEDGEMENTS

LSC is partially funded and ES and RM are wholly funded by the NIHR Biomedical Research Centre at Great Ormond Street Hospital. All research at Great Ormond Street Hospital NHS Foundation Trust and UCL Great Ormond Street Institute of Child Health is made possible by the NIHR Great Ormond Street Hospital Biomedical Research Centre. The views expressed are those of the authors and not necessarily those of the NHS, the NIHR, or the UK Department of Health. The funder had no role in study design, data collection, data analysis, data interpretation, or writing of the report. This research is funded by the NIHR Biomedical Research Centre at Great Ormond Street Hospital, London, UK.

CONFLICT OF INTEREST

The authors declare that there is no conflict of interest.

DATA AVAILABILITY STATEMENT

The data that support the findings of this study are available on reasonable request from the corresponding author. The data are not publicly available due to privacy or ethical restrictions.

ORCID

Natalie J. Chandler  <https://orcid.org/0000-0003-1396-0740>

Rhiannon Mellis  <https://orcid.org/0000-0001-9905-0654>

Lyn S. Chitty  <https://orcid.org/0000-0002-4857-7138>

REFERENCES

- Lord J, McMullan DJ, Eberhardt RY, et al. Prenatal exome sequencing analysis in fetal structural anomalies detected by ultrasonography (PAGE): a cohort study. *Lancet (London, England)*. 2019;393(10173):747-757. <https://doi.org/10.1530/ey.16.14.14>
- Petrovski S, Aggarwal V, Giordano JL, et al. Whole-exome sequencing in the evaluation of fetal structural anomalies: a prospective cohort study. *Lancet (London, England)*. 2019;393(10173):758-767. [https://doi.org/10.1016/s0140-6736\(18\)32042-7](https://doi.org/10.1016/s0140-6736(18)32042-7)
- Fu F, Li R, Li Y, et al. Whole exome sequencing as a diagnostic adjunct to clinical testing in fetuses with structural abnormalities. *Ultrasound Obstet Gynecol*. 2018;51(4):493-502. <https://doi.org/10.1002/uog.18915>
- Normand EA, Braxton A, Nassef S, et al. Clinical exome sequencing for fetuses with ultrasound abnormalities and a suspected Mendelian disorder. *Genome Med*. 2018;10(1):74. <https://doi.org/10.1186/s13073-018-0582-x>
- Best S, Wou K, Vora N, Van der Veyver IB, Wapner R, Chitty LS. Promises, pitfalls and practicalities of prenatal whole exome sequencing. *Prenat Diagn*. 2018;38(1):10-19. <https://doi.org/10.1002/pd.5102>
- Mellis R, Oprych K, Scotchman E, Hill M, Chitty LS. Diagnostic yield of exome sequencing for prenatal diagnosis of fetal structural anomalies: a systematic review and meta-analysis. *Prenat Diagn*. 2022. <https://doi.org/10.1002/pd.6115>
- Chandler N, Best S, Hayward J, et al. Rapid prenatal diagnosis using targeted exome sequencing: a cohort study to assess feasibility and potential impact on prenatal counseling and pregnancy management. *Genet Med*. 2018;20(11):1430-1437. <https://doi.org/10.1038/gim.2018.30>
- Deans ZC, Chitty L, Ellard S, et al. *Guidance document: rapid exome sequencing service for fetal anomalies testing*. 2020.
- GenomicsEngland. PanelApp. <https://panelapp.genomicsengland.co.uk/>
- Jarvik GP, Evans JP. Mastering genomic terminology. *Genet Med*. 2017;19(5):491-492. <https://doi.org/10.1038/gim.2016.139>
- Ellard S, Baple EL, Callaway A, et al. *ACGS best practice guidelines for variant classification in rare disease 2020*. Association for Clinical Genomic Science; 2020.
- Richards S, Aziz N, Bale S, et al. Standards and guidelines for the interpretation of sequence variants: a joint consensus recommendation of the American College of Medical Genetics and Genomics and the Association for Molecular Pathology. *Genet Med*. 2015;17(5):405-424. <https://doi.org/10.1038/gim.2015.30>
- Twigg SRF, Hufnagel RB, Miller KA, et al. A recurrent mosaic mutation in SMO, encoding the hedgehog signal transducer smoothed, is the major cause of Curry-Jones syndrome. *Am J Hum Genet*. 2016;98(6):1256-1265. <https://doi.org/10.1016/j.ajhg.2016.04.007>
- Aggarwal S, Vineeth VS, Das Bhowmik A, et al. Exome sequencing for perinatal phenotypes: the significance of deep phenotyping. *Prenat Diagn*. 2020;40(2):260-273. <https://doi.org/10.1002/pd.5616>
- Guo W, Lai Y, Yan Z, et al. Trio-whole-exome sequencing and pre-implantation genetic diagnosis for unexplained recurrent fetal malformations. *Hum Mutat*. 2020;41(2):432-448. <https://doi.org/10.1002/humu.23935>
- Greenbaum L, Pode-Shakked B, Eisenberg-Barzilai S, et al. Evaluation of diagnostic yield in fetal whole-exome sequencing: a report on 45 consecutive families. *Front Genet*. 2019;10:425. <https://doi.org/10.3389/fgene.2019.00425>
- Westphal DS, Leszinski GS, Rieger-Fackeldey E, et al. Lessons from exome sequencing in prenatally diagnosed heart defects: a basis for prenatal testing. *Clin Genet*. 2019;95(5):582-589. <https://doi.org/10.1111/cge.13536>
- Han J, Yang YD, He Y, et al. Rapid prenatal diagnosis of skeletal dysplasia using medical trio exome sequencing: benefit for prenatal

- counseling and pregnancy management. *Prenat Diagn.* 2020;40(5): 577-584. <https://doi.org/10.1002/pd.5653>
19. Drury S, Williams H, Trump N, et al. Exome sequencing for prenatal diagnosis of fetuses with sonographic abnormalities. *Prenat Diagn.* 2015;35(10):1010-1017. <https://doi.org/10.1002/pd.4675>
 20. Pyott SM, Pepin MG, Schwarze U, Yang K, Smith G, Byers PH. Recurrence of perinatal lethal osteogenesis imperfecta in sibships: parsing the risk between parental mosaicism for dominant mutations and autosomal recessive inheritance. *Genet Med.* 2011;13(2): 125-130. <https://doi.org/10.1097/gim.0b013e318202e0f6>
 21. Deden C, Neveling K, Zafeiropopoulou D, et al. Rapid whole exome sequencing in pregnancies to identify the underlying genetic cause in fetuses with congenital anomalies detected by ultrasound imaging. *Prenat Diagn.* 2020;40(8):972-983. <https://doi.org/10.1002/pd.5717>
 22. Moraes MV, Milanez M, Almada BV, et al. Variable expressivity of osteogenesis imperfecta in a Brazilian family due to p.G1079S mutation in the COL1A1 gene. *Genet Mol Res.* 2012;11(3):3246-3255. <https://doi.org/10.4238/2012.september.12.7>
 23. Cao YJ, Wei Z, Zhang H, Zhang ZL. Expanding the clinical spectrum of osteogenesis imperfecta Type V: 13 additional patients and review. *Front Endocrinol.* 2019;10:375. <https://doi.org/10.3389/fendo.2019.00375>
 24. Aarabi M, Snizek O, Jiang H, et al. Importance of complete phenotyping in prenatal whole exome sequencing. *Hum Genet.* 2018;137(2):175-181. <https://doi.org/10.1007/s00439-017-1860-1>
 25. Mone F, McMullan DJ, Williams D, Chitty LS, Maher ER, Kilby MD. Evidence to support the clinical utility of prenatal exome sequencing in evaluation of the fetus with congenital anomalies: Scientific Impact Paper No. 64 [February] 2021. *BJOG.* 2021;128(9):e39-e50. <https://doi.org/10.1111/1471-0528.16616>
 26. Gray KJ, Wilkins-Haug LE, Herrig NJ, Vora NL. Fetal phenotypes emerge as genetic technologies become robust. *Prenat Diagn.* 2019;39(9):811-817. <https://doi.org/10.1002/pd.5532>
 27. Tham E, Lindstrand A, Santani A, et al. Dominant mutations in KAT6A cause intellectual disability with recognizable syndromic features. *Am J Hum Genet.* 2015;96(3):507-513. <https://doi.org/10.1016/j.ajhg.2015.01.016>
 28. Urreizti R, Lopez-Martin E, Martinez-Monseny A, et al. Five new cases of syndromic intellectual disability due to KAT6A mutations: widening the molecular and clinical spectrum. *Orphanet J Rare Dis.* 2020;15(1):44. <https://doi.org/10.1186/s13023-020-1317-9>
 29. Al-Kouatly HB, Makhamreh MM, Rice SM, et al. High diagnosis rate for nonimmune hydrops fetalis with prenatal clinical exome from the Hydrops-Yielding Diagnostic Results of Prenatal Sequencing (HYDROPS) study. *Genet Med.* 2021;23(7):1325-1333. <https://doi.org/10.1038/s41436-021-01121-0>
 30. ClinVar. <https://www.ncbi.nlm.nih.gov/clinvar/>
 31. Fowler A, Mahamdallie S, Ruark E, et al. Accurate clinical detection of exon copy number variants in a targeted NGS panel using DECoN. *Wellcome Open Res.* 2016;1:20. <https://doi.org/10.12688/wellcomeopenres.10069.1>
 32. Plagnol V, Curtis J, Epstein M, et al. A robust model for read count data in exome sequencing experiments and implications for copy number variant calling. *Bioinformatics.* 2012;28(21):2747-2754. <https://doi.org/10.1093/bioinformatics/bts526>
 33. Costain G, Callewaert B, Gabriel H, et al. De novo missense variants in RAC3 cause a novel neurodevelopmental syndrome. *Genet Med.* 2019;21(4):1021-1026. <https://doi.org/10.1038/s41436-018-0323-y>
 34. Cabet S, Vasiljevic A, Putoux A, et al. Prenatal imaging features related to RAC3 pathogenic variant and differential diagnoses. *Prenat Diagn.* 2022;42(4):478-481. <https://doi.org/10.1002/pd.6106>

SUPPORTING INFORMATION

Additional supporting information can be found online in the Supporting Information section at the end of this article.

How to cite this article: Chandler NJ, Scotchman E, Mellis R, Ramachandran V, Roberts R, Chitty LS. Lessons learnt from prenatal exome sequencing. *Prenat Diagn.* 2022; 42(7):831-844. <https://doi.org/10.1002/pd.6165>