

## CASE REPORT

# Complete response of cutaneous SCC to topical treatment with ascorbic acid solution: A case report

Carmine Pernice<sup>1</sup> | Domenico Murri<sup>1</sup> | Riccardo Valli<sup>2</sup> | Francesco M. Crocetta<sup>3</sup> | Michele Iori<sup>4</sup> | Mattia Asti<sup>4</sup> | Angelo Ghidini<sup>1</sup> | Pier C. Capponi<sup>4</sup>

<sup>1</sup>Otolaryngology Unit, Department of Surgery, Azienda Unità Sanitaria Locale IRCCS di Reggio Emilia, Reggio Emilia, Italy

<sup>2</sup>Pathology Unit, Azienda Unità Sanitaria Locale IRCCS di Reggio Emilia, Reggio Emilia, Italy

<sup>3</sup>Otorhinolaryngology Head and Neck Surgery Unit, Head and Neck and Sensory Organs Department, Sant'Orsola - Malpighi Hospital, University of Bologna, Bologna, Italy

<sup>4</sup>Radiopharmaceutical Chemistry Section, Azienda Unità Sanitaria Locale IRCCS di Reggio Emilia, Reggio Emilia, Italy

## Correspondence

Pier C. Capponi, Radiopharmaceutical Chemistry Section, Azienda Unità Sanitaria Locale IRCCS di Reggio Emilia, Reggio Emilia, Italy.  
Email: PierCesare.Capponi@ausl.re.it

## Abstract

Clinical use of topical ascorbic acid solution could have both the role as an adjunct to consolidated therapies and as an alternative to them, for the treatment of BCC and SCC of the skin.

## KEYWORDS

ascorbic acid, basal cell carcinoma, heterogeneous topical solution, squamous cell carcinoma, supersaturated solution

## 1 | INTRODUCTION

Vitamin C, also known as ascorbic acid, is a well-known antioxidant molecule. In the literature, there are many experimental data suggesting that high-dose ascorbic acid can lead to the generation of hydrogen peroxide and consequently death of cancer cells. Indeed, the ascorbic acid in pharmacological concentrations selectively kills some cancer cells but not normal cells. In literature, few studies have investigated the role of topical application of ascorbic acid in the treatment of skin cancer, with results ranging from a complete clinical response to a partial response. From our knowledge, this is the first case of aggressive skin cancer treated with topical ascorbate. A 77-year-old man

presented with a growing neoformation of the right external ear, accompanied by ear pain and episodic small bleedings to the mass. Two cm nodular neoformation located on the antihelix of the right external ear with a tendency to infiltrate both branches of the antihelix, apparently with no involvement of the scafoid fossa. Histologically, the incisional biopsy showed a verrucous proliferation of well-differentiated squamous cells infiltrating the superficial dermis, diagnostic of well-differentiated squamous cell carcinoma. The patient was treated with daily applications of a supersaturated ascorbic acid solution for thirty days. An intraoperative multioperative biopsy of the margins was performed, before proceeding to complete resection of the ear. This allowed to preserve the ear. A complete surgical excision,

This is an open access article under the terms of the Creative Commons Attribution-NonCommercial-NoDerivs License, which permits use and distribution in any medium, provided the original work is properly cited, the use is non-commercial and no modifications or adaptations are made.

© 2021 The Authors. *Clinical Case Reports* published by John Wiley & Sons Ltd.

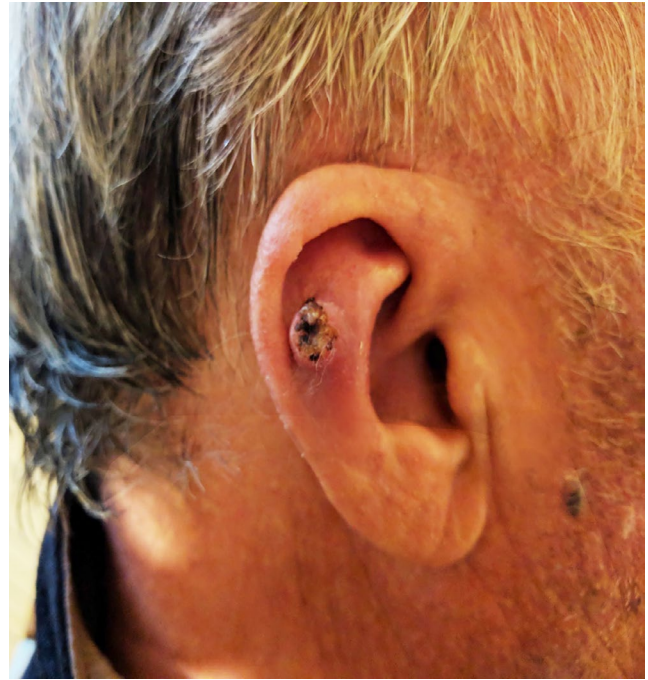which guarantees adequate surgical margins, is the treatment of choice in these tumors; however, an extended surgical resection can involve a great mutilation, with consequent psychological anguish for the patient. In addition, patients with these cancers often have a poor performance status with age-related diseases, which can represent a relative or absolute contraindication to surgery and lead to complex patient management. Therefore, the use of a topical formulation with the characteristics described in the present work could represent an improvement of the current therapeutic strategy.

L-ascorbic acid is a natural molecule with antioxidant power, able to mediate multiple physiological activities in humans and animals. Many studies since the 60s and 70s have attributed anticancer properties to the ascorbic acid, which has aroused great media interest, but was never successful in generating a great therapeutic clinical application. In recent years, research and experimental evidence has brought the use of ascorbic acid as an anticancer molecule closer to scientific attention and has particularly focused on its biochemical mechanisms.

Indeed, findings show that at specific pharmacological concentrations (in vitro and in vivo  $\geq 25 \mu\text{M}$ ), ascorbic acid is able to determine toxicity toward tumor cells. In theory, the toxicity is obtained through the formation of hydrogen peroxide, mediated by metal-proteins present in extracellular tissues starting from the radical of L-ascorbic acid (ascorbyl radical). L-ascorbic acid would behave as a pro-drug for the selective transport of hydrogen peroxide in the extravascular space near to tumor cells.<sup>1</sup> As proposed by Doskeya et al,<sup>2</sup> this toxicity would selectively affect cancer cells, sparing healthy cells, due to the lack of hydrogen peroxide-resistant enzymes.<sup>2</sup>

It has been reported that the ability to form hydrogen peroxide in blood starting from the ascorbyl radical is very small compared to extracellular fluids. It is believed that their formation is inhibited by reducing proteins present in the blood, such as catalase and glutathione peroxidase. According to these studies, the variability of clinical results related to ascorbic acid is due to its pharmacokinetics. It has been estimated that the ascorbic radical in extracellular fluids must have a concentration  $> 100 \text{ nM}$  to generate hydrogen peroxide. Therefore, the initial concentration of ascorbic acid which would determine a therapeutic action depends on a series of variables such as the form of administration and its pharmacokinetics.

Therefore, systemic administration does not seem to be an optimal way to obtain a concentration of hydrogen peroxide in extracellular fluids. In addition, exposure to high concentrations of hydrogen peroxide must be constant and continue over time to generate the death of cancer cells. In the case of skin cancer, a topical treatment presents no problems with pharmacokinetics, because L-ascorbic acid and its radical are in direct contact with cancer cells bypassing blood. The ascorbyl radical concentration is sufficient to form the



**FIGURE 1** A nodular lesion of the antihelix is present on the right external ear. The histological evaluation was suggestive for squamous cell cancer

hydrogen peroxide directly in the extracellular tissue, and the exposure is prolonged enough over time to determine the death of the tumor cells.

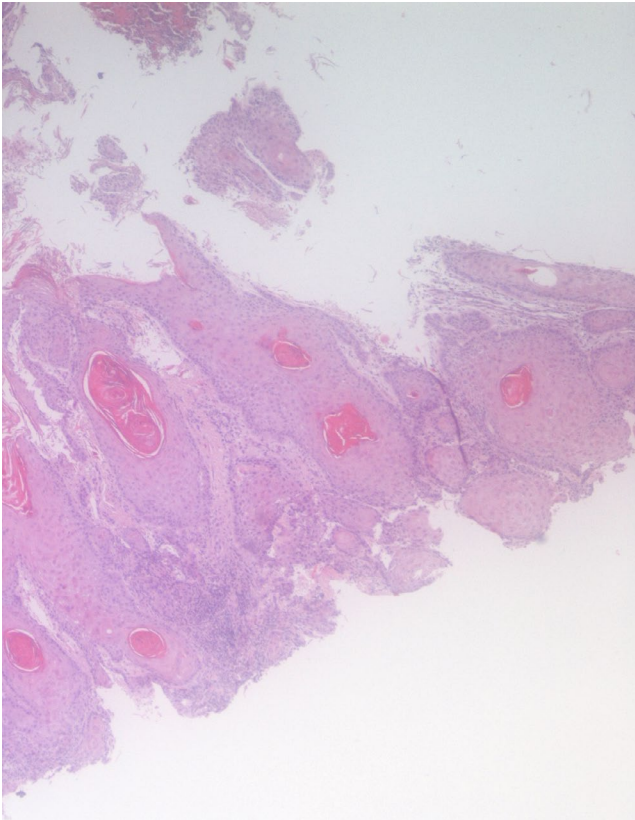
## 2 | CASE PRESENTATION

### 2.1 | Patient's features

A 77-year-old man presented with a growing neof ormation of the right external ear, accompanied by ear pain and episodic small bleedings to the mass. The neof ormation appears as a 2 cm nodular lesion located on the antihelix of the right external ear with a tendency to infiltrate both branches of the antihelix, apparently with no involvement of the scaffold fossa (Figure 1). Histologically, the incisional biopsy showed a verrucous proliferation of well-differentiated squamous cells infiltrating the superficial dermis, diagnostic of well-differentiated squamous cell carcinoma (Figures 2 and 3). An informed consent was obtained by the patient to start the topical experimental treatment.

### 2.2 | Materials, methods of applications, and posology

To treat the tumor, for first step a disinfectant alcohol-free was applied as not to alter the permeability of skin. Following, a supersaturated ascorbic acid solution with a concentration

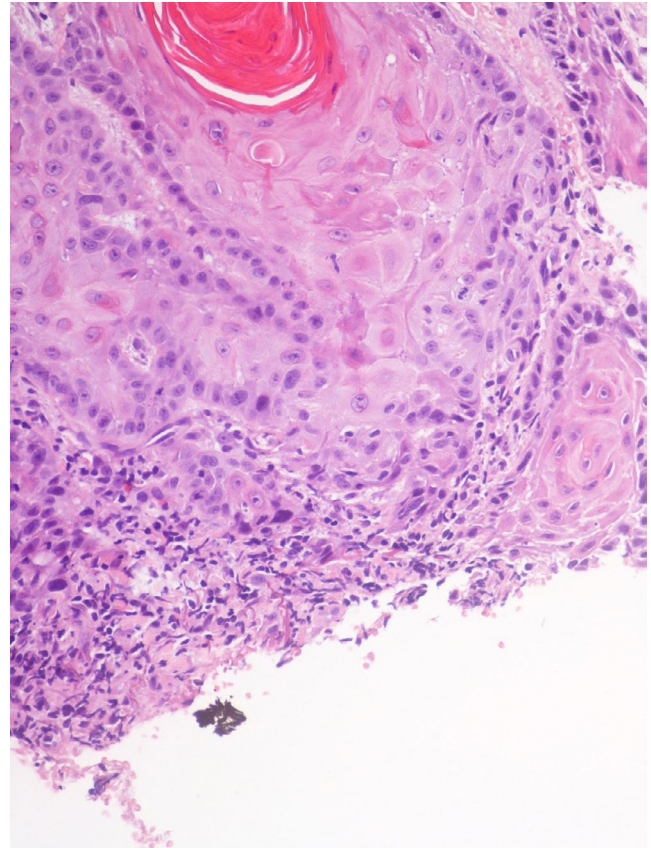


**FIGURE 2** Incisional biopsy of the skin lesion, showing a well-differentiated squamous cell carcinoma (hematoxylin-eosin, 4x)

equal or greater to the limit of solubility in water (330 g/L), between 40% and 70%, was applied on tumor. The patient was directed to keep the medication applied for a minimum of 4 hours up to a maximum of 12 hours each day, for thirty days.

The formulation was prepared extemporaneously as magistral galenic, because there is no formulation with chemical-physical characteristics on the market suitable for this purpose. These characteristics (supersaturation obtained with a heterogeneous solution) guarantee that the concentration of ascorbyl radical is sufficient to form the hydrogen peroxide.

Then, a two-phase heterogeneous solution is obtained. The heterogeneity of the solution is necessary to maintain a continuous exchange in the redox balance between ascorbic acid and dehydroascorbic acid, guaranteeing the continuous presence of the ascorbyl radical, which is an intermediate of this equilibrium. Furthermore, the heterogeneous solution keeps ascorbic acid at the limit of solubility, stabilizing the molecule that would otherwise degrade in contact with air and light. The aqueous solution has a pH ranging from 1.2 to 3.5. The acid pH, maintained in this range, by the heterogeneous solution, allows the ascorbic acid to maintain a non-ionized form, improving absorption and distribution through the skin and extracellular fluids. The solution does not contain excipients, which could



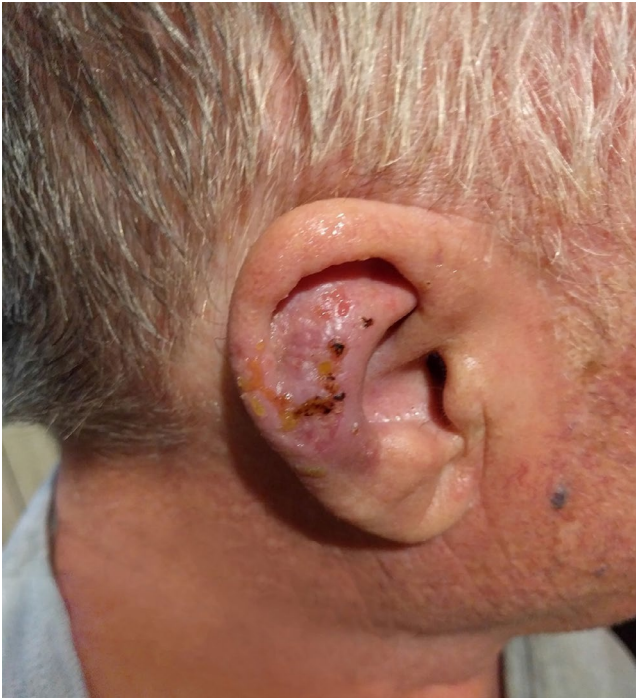**FIGURE 3** At higher magnification, superficial dermis infiltration by squamous nests of neoplastic cells (hematoxylin-eosin, 20x)

reduce the presence of the ascorbyl radical, thus reducing the pharmacological activity. Pharmaceutical-grade crystalline powder of ascorbic acid and highly purified water for injections were used, and the solution was prepared according to GMP (Good Manufacturing Practices).

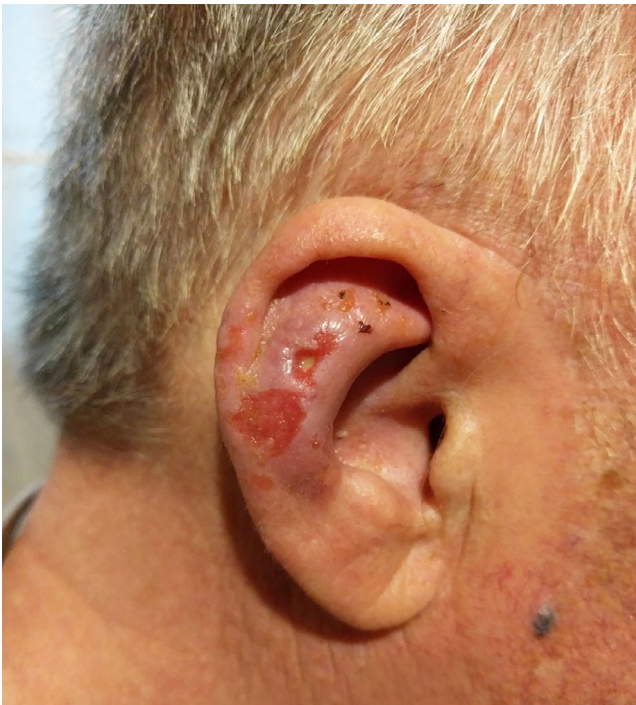### 2.3 | Clinical outcomes

Within one month of continual application, without any adverse effects or pain, the tumor shows a rapid reduction of its size with a minimal erosive superficial reaction. The ear's thickness and consistence seem to be normal without areas suspected for dermal infiltration (Figures 4-6). Afterward, a wedge resection of the helix and antihelix was performed (Figure 7). Intraoperative multiple biopsies of the margins have been performed, showing no evidence of neoplasia. Definitive histological examination showed focal epidermal hyperplasia, with hyperkeratosis, and tiny scale crusts. The underlying superficial dermis was characterized by fibrosis, associated with focal lymphocytic inflammatory infiltrate. No residual neoplasia was evident (Figures 8-10).





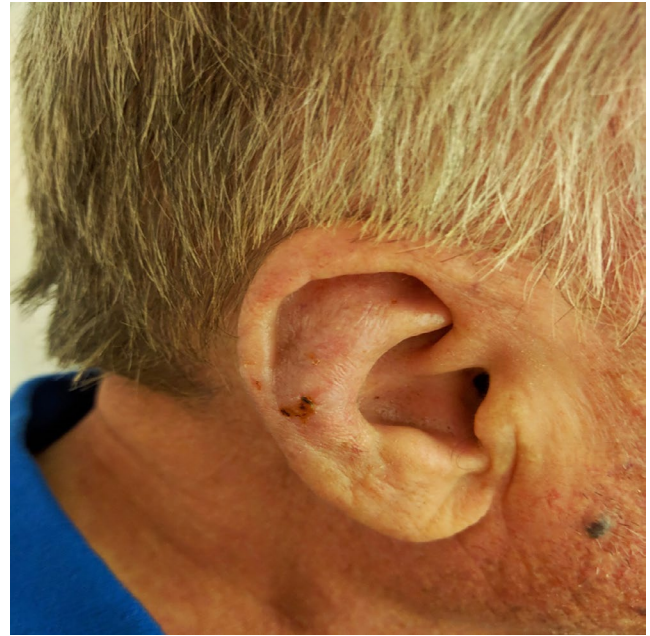**FIGURE 4** After the start of the topical treatment, the exophytic portion of the tumor was no longer visible. Hyperemic-erosive areas with crusts have replaced the initial lesion



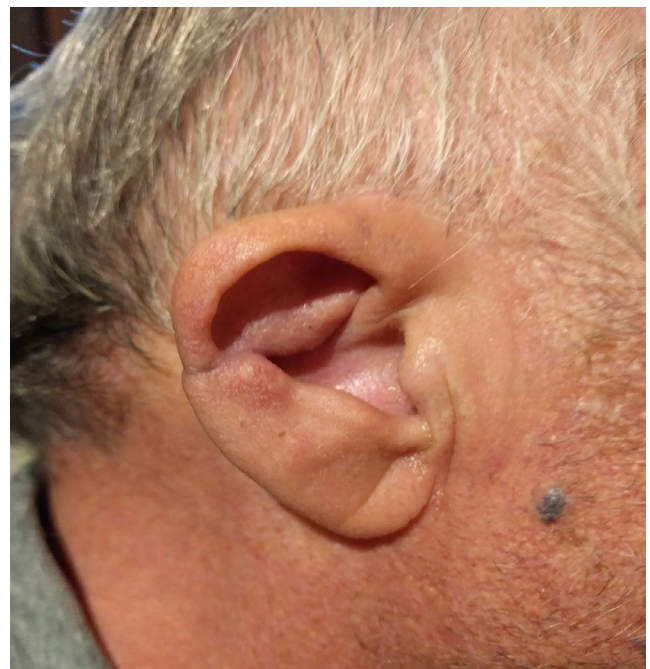**FIGURE 5** After the start of the topical treatment, the exophytic portion of the tumor was no longer visible. Hyperemic-erosive areas with crusts have replaced the initial lesion

### 3 | DISCUSSION

Cutaneous malignancies are traditionally classified into melanoma and keratinocyte skin cancers (KSC). Incidence rates of



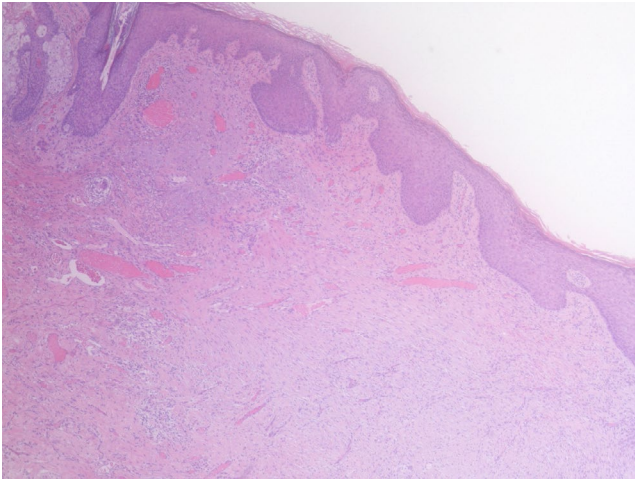
**FIGURE 6** Complete clinical response to the treatment. No lesions are detectable on the surface of the external ear



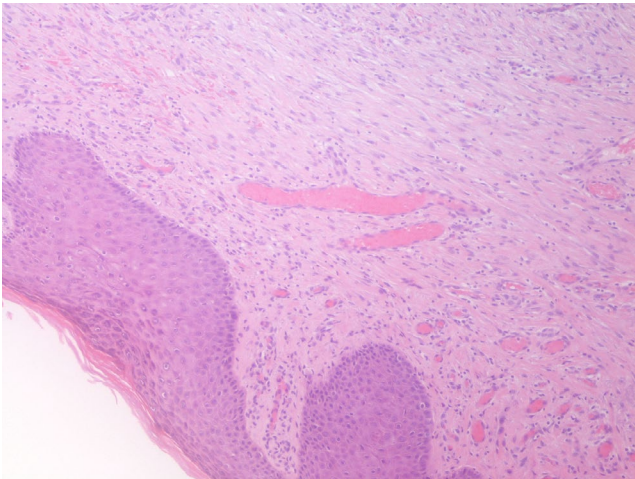
**FIGURE 7** Appearance of the ear one month after the surgical exeresis

KSC, comprising of basal cell carcinoma (BCC) and squamous cell carcinoma (SCC), are much higher than that of melanoma. BCC development is mainly the cause of an intensive UV exposure in childhood and adolescence, while SCC development is related to chronic, cumulative UV exposure over decades. Although mortality is relatively low, KSC is an increasing problem for healthcare services causing significant morbidity.<sup>3</sup> These cancers have a predilection for the head and neck region,



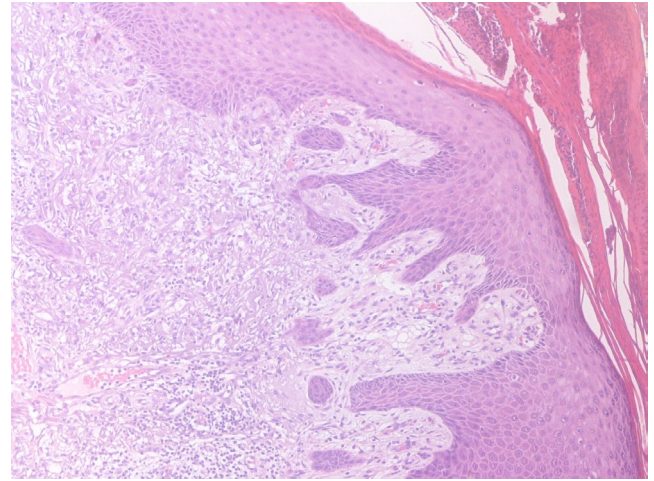


**FIGURE 8** Low-power view of the resection specimen (partial wedge resection of the earlobe): The epidermis is acanthotic, without atypia; the superficial dermis shows a fibrous scar, with nonresidual neoplastic elements (hematoxylin-eosin, 4x)



**FIGURE 9** Epidermal hyperplasia without atypia. The superficial dermis shows scar-type fibrosis, with thin vertically oriented capillaries (hematoxylin-eosin, 20x)

potentially leading to significant disfigurement from both disease and treatment. BCC usually shows a slow locally invasive growth pattern with a low tendency to metastasize (<0.5% of cases).<sup>4</sup> Conversely, SCC is known to be locally aggressive and it has been reported to metastasize up to 5% of cases, especially if characterized by high-risk factors and if located in H&N skin surfaces.<sup>5</sup> A complete surgical excision, ensuring adequate surgical margins, is the treatment of choice in both these tumors, while radiotherapy is generally used for cancers that recur after surgery, or for elderly patients where surgery is contraindicated. Currently surgery and radiotherapy are the first-line treatments for these tumors but recently new pharmacological treatments have been employed. Of these, may be the most important example is represented by the topical application of Imiquimod 5% that has shown good efficacy against superficial BCC and solar keratosis.<sup>6,7</sup>



**FIGURE 10** Epidermal hyperplasia without atypia. The superficial dermis shows scar-type fibrosis, with thin vertically oriented capillaries (hematoxylin-eosin, 20x)

The use of a topical solution of ascorbic acid, as in our case, has been reported in the literature only once by Holló et al<sup>8</sup> In their experience, 7 BCCs (1 nodular and 6 superficial) were treated once daily with a topical ascorbic acid solution (33 g/100 mL water), by means of a local bandage placed for at least 12 hours, for a total of 22 weeks. In an 18-month follow-up period, they achieved a resolution of five cases of BCC, confirmed by a post-therapy biopsy, and only one case of these has relapsed.

In our case, we report a total clinical and histological response to an ascorbic acid topical treatment in a patient affected by a SCC of the ear. Traditional surgical treatment presents two important pitfalls, one related to the anatomical site and the second related to the status of the patients. Indeed, these lesions often occur in the head and neck district, so even a small lesion can cause a visible scar after a surgical procedure. Moreover, such an extensive surgical resection can result in a large mutilation, resulting in psychological distress to the patient. Secondly, patients affected by these tumors often have a bad performance status with age-related diseases that can represent a relative or an absolute contraindication to the surgery and can lead to a complex management of the patients. Therefore, the use of a topical formulation with the characteristics described in the present work could represent an improvement to the current therapeutic strategy.

#### 4 | CONCLUSIONS

We believe that this formulation, promoting the cytostatic arrest of the tumor and thus reducing its size, could in some cases avoid a surgical treatment and, in other cases, reduce the area to be resected with the surgery, leading to a more conservative surgical intervention and subsequently to an

easier management of the patient. In light of these considerations, a clinical use of topical ascorbic acid solution could have both the role as an adjunct to consolidated therapies and as an alternative to them, for the treatment of BCC and SCC of the skin.

## 5 | MAIN POINTS

1. Vitamin C, also known as ascorbic acid, is a well-known antioxidant molecule; high-dose ascorbic acid can lead to the generation of hydrogen peroxide and consequently death of cancer cells.
2. This is the first case of aggressive skin cancer treated with topical ascorbate; we have demonstrated a complete clinical response of a SCC to the application of ascorbic acid solution.
3. Clinical use of topical ascorbic acid solution could have both the role as an adjunct to consolidated therapies and as an alternative to them, for the treatment of BCC and SCC of the skin.

## ACKNOWLEDGMENT

The authors thank the patient, family, and all the people who participated in this case report, hoping to make a contribution to the research.

Informed consent was obtained from all individual participants included in the study.

## CONFLICT OF INTEREST

The authors have no conflict of interest to declare.

## AUTHOR CONTRIBUTION

PC: reviewed the manuscript. MD: wrote the main manuscript text and reviewed the manuscript. CFM: wrote the main manuscript text, prepared figures, and reviewed the manuscript. GA: reviewed the manuscript. VR: involved in analysis, acquisition, and interpretation of the data. IM: involved in conception of the work. AM: involved in conception of the work. CPC: involved in conception of the work, wrote the main manuscript text, prepared figures, and reviewed the manuscript.

## ETHICAL APPROVAL

All procedures performed in studies involving human participants were in accordance with the ethical standards of the

institutional and/or national research committee and with the 1964 Helsinki declaration and its later amendments or comparable ethical standards.

## DATA AVAILABILITY STATEMENT

The data that support the findings of this study are available from the corresponding author upon reasonable request.

## ORCID

Pier C. Capponi  <https://orcid.org/0000-0003-3826-8849>

## REFERENCES

1. Chen Q, Espey MG, Sun AY, et al. Ascorbate in pharmacologic concentrations selectively generates ascorbate radical and hydrogen peroxide in extracellular fluid in vivo. *Proc Natl Acad Sci USA*. 2007;104(21):8749-8754.
2. Doskeya CM, Buranasudjaa V, Wagnerb BA, et al. Tumor cells have decreased ability to metabolize H<sub>2</sub>O<sub>2</sub>: Implications for pharmacological ascorbate in cancer therapy. *Redox Biol*. 2016;10:274-284.
3. Leiter U, Keim U, Garbe C. The epidemiology of skin cancer: Update 2019. *Sunlight, Vitamin D and Skin Cancer*; 2019:123-139.
4. Ting PT, Kasper R, Arlette JP, et al. Metastatic basal cell carcinoma: report of two cases and literature review. *J Cutan Med Surg*. 2005;9(1):10-15.
5. Brougham NDLS, Dennett ER, Cameron R, et al. The incidence of metastasis from cutaneous squamous cell carcinoma and the impact of its risk factors. *J Surg Oncol*. 2012;106:811.
6. Kamath P, Darwin E, Arora H, Nouri K. A review on imiquimod therapy and discussion on optimal management of basal cell carcinomas. *Clin Drug Investig*. 2018;38(10):883-899.
7. De Oliveira ECV, da Motta VRV, Pantoja PC, et al. Actinic keratosis - review for clinical practice. *Int J Dermatol*. 2019;58(4):400-407.
8. Holló P, Jókai H, Hársing J, Soós G, Kárpáti S, Németh K. Topically applied ascorbic acid solution for the treatment of basal cell carcinoma (BCC). *J Am Acad Dermatol*. 2016;75(1):212-213.

**How to cite this article:** Pernice C, Murri D, Valli R, et al. Complete response of cutaneous SCC to topical treatment with ascorbic acid solution: A case report. *Clin Case Rep*. 2021;9:1060–1065. <https://doi.org/10.1002/ccr3.3585>