

Change in Cerebral Blood Flow after Palliative Percutaneous Angioplasty and Timing of Second Stage Carotid Artery Stenting in Staged Angioplasty

Hisashi NAGASHIMA,¹ Kazuhiro HONGO,² and Alhusain NAGM^{2,3}

¹*Clinical Safety and Quality Management Section, University of Toyama Hospital, Toyama, Toyama, Japan;*

²*Department of Neurosurgery, Shinshu University School of Medicine, Matsumoto, Nagano, Japan;*

³*Department of Neurosurgery, Al-Azhar University Faculty of Medicine-Nasr City, Cairo, Egypt*

Abstract

The purpose of this study is to elucidate the hemodynamic changes after palliative angioplasty and the timing of second stage carotid artery stenting (CAS) in staged angioplasty for patients with severe hemodynamically compromised carotid artery stenosis. Among consecutive 111 patients with carotid artery stenosis, chronological changes in the cerebral blood flow of all 11 hemodynamically compromised patients treated with CAS were evaluated with single photon emission computed tomogram (SPECT) in each stage of the treatment. Ten of these 11 patients underwent staged angioplasty and one was treated with single-stage CAS. All the 10 patients who underwent staged angioplasty showed improved cerebral vascular reactivity (CVR) on SPECT after the first stage palliative angioplasty. Only one patient treated with staged angioplasty with 4-week interval before the CAS showed restenosis of the lesion. Cerebral hyperperfusion syndrome (CHS) was not observed in nine of 10 patients with staged angioplasty. One patient of staged angioplasty (who presented restenosis at the time of elective CAS) and another patient in whom we could not apply staged angioplasty (for his renal dysfunction) showed CHS after CAS. In conclusion, restoration of CVR could be achieved within a few days following palliative angioplasty, and 1–2-week interval is enough for staged angioplasty.

Key words: carotid artery, stent, staged angioplasty, cerebral blood flow, cerebral hyperperfusion

Introduction

Intracranial hemorrhage due to cerebral hyperperfusion syndrome (CHS) is known as a catastrophic complication following carotid artery revascularization.^{1,2)} Poor cerebral vascular reactivity (CVR) delivered from long-standing cerebral blood flow (CBF) impairment caused by severe carotid artery stenosis is regarded as a risk factor.³⁾ Staged angioplasty, which allows CBF improvement with minimal and palliative percutaneous angioplasty followed by curative carotid artery stenting (CAS) with a 1–2-month interval, is recently introduced as an effective procedure to prevent CHS after CAS.^{4,5)} However, the effect of palliative angioplasty in

severe hemodynamically-compromised patients and the ideal period before CAS were not elucidated. We investigated the chronological changes in CBF following the staged angioplasty and evaluated the efficacy of staged angioplasty.

Materials and Methods

A total of 111 patients with carotid artery stenosis were treated at our institute (Shinshu University Hospital, Nagano, Japan) between May 2010 and April 2014. Cerebral blood flow and CVR were evaluated with quantitative analysis of single photon emission computed tomogram (SPECT) with acetazolamide challenge in the patients with stenosis over 80% on North American Symptomatic Carotid Endarterectomy Trial (NASCET) criteria, lesions over 250 cm/sec peak systolic velocity on carotid Doppler ultrasonography or findings of reduced signal in distal internal carotid or intracranial vessels on

Received February 1, 2018; Accepted March 30, 2018

Copyright© 2018 by The Japan Neurosurgical Society This work is licensed under a Creative Commons Attribution-NonCommercial-NoDerivatives International License.

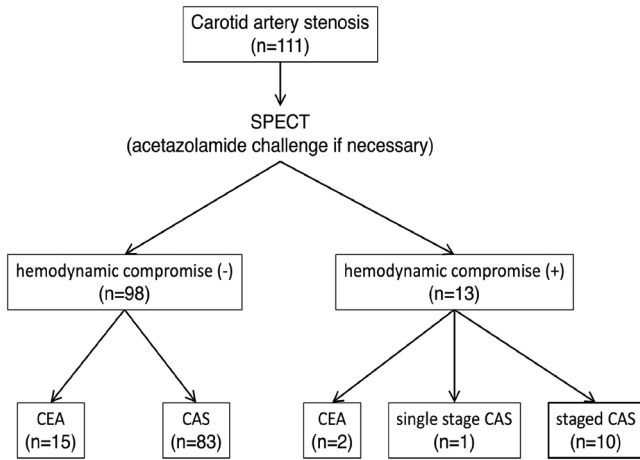


Fig. 1 Selected treatment in this case series. In consecutive 111 patients of carotid artery stenosis in our institute between May 2010 and April 2014, 13 patients proved to have severe and widespread hemodynamic compromise on single photon emission computed tomogram. Two of 13 patients were treated with carotid endarterectomy for severely calcified lesions, one was treated with single-stage carotid artery stenting for his renal dysfunction and 10 were treated with staged angioplasty.

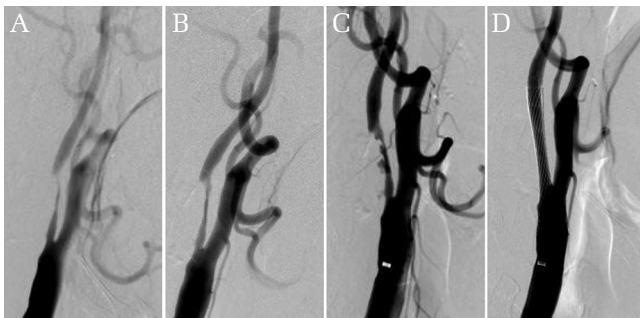

Fig. 2 Serial angiogram of Case 3 via right common carotid artery (CCA) injection. (A) Right ICA was severely constricted over 90% and distal internal carotid artery (ICA) was collapsed before the first-stage angioplasty. (B) Minimal dilatation of the lesion and recovery of the flow restriction was achieved after the first-stage palliative angioplasty. (C) Advanced improvement of the stenosis was observed before the second-stage carotid artery stenting. (D) Stent was successfully placed without any complications.

magnetic resonance angiography.⁶⁾ Hemodynamic compromise was estimated with existence of stage-2 areas proposed by Japanese Extracranial-Intracranial Bypass Trial (JET)-2 Study on “% Increase Map”.⁷⁾ Among 111 patients, 13 patients with severe and widespread hemodynamic compromise on SPECT were candidates for staged angioplasty. Two of the 13 patients were treated with carotid endarterectomy (CEA) for severely calcified lesions, one patient with renal dysfunction was treated with single-stage

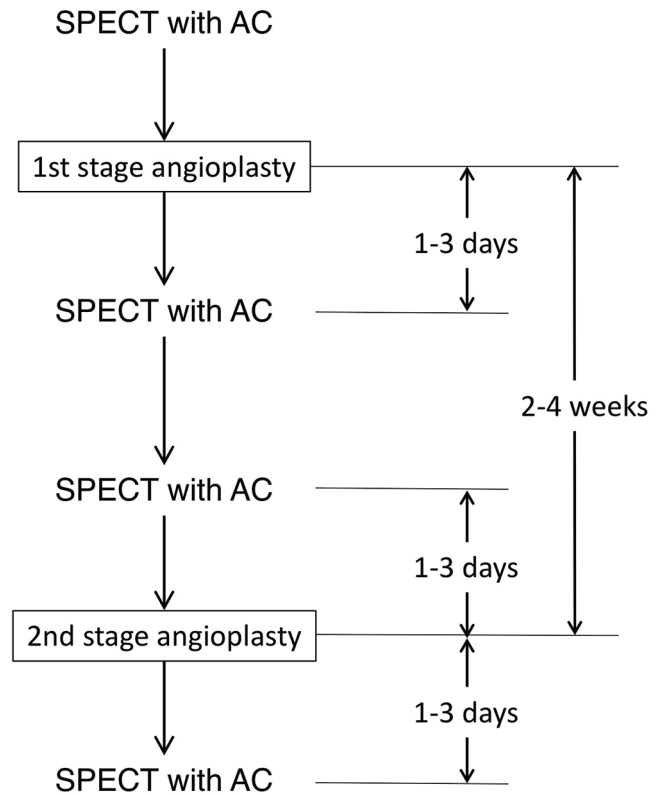


Fig. 3 Protocol of staged angioplasty in our institute. Cerebral blood flow and cerebral vascular reactivity were evaluated with single photon emission computed tomogram with acetazolamide challenge before and after each stage of the treatment within a few days.

CAS (due to the limitation of contrast medium) and the remaining 10 patients were treated with staged angioplasty (Fig. 1).

Staged angioplasty, elective CAS following minimal percutaneous balloon dilatation with a few weeks interval, was done according to the description by Yoshimura et al.⁵⁾ We started the first-stage palliative angioplasty with 2.0-mm balloon and finished after achieving improvement of contrast run out of collapsed distal carotid artery without re-constriction of the lesion after 30-min observation on angiogram (Fig. 2). When the lesion showed re-constriction after angioplasty with 2.0-mm balloon, the size of balloon was stepwisely increased up to a maximum of 3.0-mm until achieving satisfactory result. If the lesion showed re-constriction with 3.0-mm balloon, longer time (30–60 sec) dilatation was repeated without further oversized-balloon.

Cerebral blood flow and CVR of all 11 patients were evaluated with serial SPECT with acetazolamide challenge before and a few days after each stage of the treatment (Fig. 3). Documented informed consent

was obtained from all patients prior to the treatment. All patients were managed below 120 mmHg systolic blood pressure over a few days after each treatment and dual anti-platelet drugs (75 mg clopidogrel and 100 mg aspirin) were given during the course of treatment.

Results

Lesions of all 10 patients treated with staged angioplasty were successfully dilated and showed improved preexisting flow restriction after the first-stage angioplasty without evidence of acute thromboembolic complications, arterial dissections, or acute occlusions. None of the 10 patients treated with staged angioplasty showed CHS symptoms, and impaired vascular reactivity areas represented as stage-2 on SPECT were resolved within a few days after the first stage angioplasty. During the course of treatment between the first-stage angioplasty and the second-stage CAS, none of the 10 patients showed neither clinical events nor radiological abnormalities on CT scan. The CAS was performed within 16–69 days after the first-stage angioplasty in the 10 patients. In one patient (Case 1), who was urgently treated for progressive and multiple infarctions, CAS was postponed to 69 days to avoid hemorrhagic complications. Another patient (Case 4) received CAS after 28-day interval, and remaining eight patients were treated within 16–23-day interval.

Single photon emission computed tomogram before the CAS was scheduled 1–3 days before the scheduled second-stage CAS. Nine of the 10 patients maintained recovered CVR at the time of CAS; however, one patient (Case 4) showed recurrence of hemodynamic compromise on SPECT.

In this patient (Case 4), apparent restenosis was observed at the CAS and briefly showed talkative tendency suggesting of CHS after CAS. Remaining nine patients showed no symptoms suggesting CHS during the course of treatment. Severely decreased CBF and impaired vascular reactivity to acetazolamide challenge test improved without any neurological deficits after the CAS in all 10 patients (Table 1). Two of 10 patients showed progressive dilatation or ulcer formation at the lesion without additional neurological deficits or apparent radiological findings (on CT) in the course of treatment. One patient who could not receive staged angioplasty showed euphoric and talkative symptoms for a few days after the CAS and apparent CHS finding was observed on SPECT.

Discussion

Intracranial hemorrhage caused by CHS is known as a most catastrophic complication after carotid artery revascularization.^{1,2)} It is regarded as the result of lost vascular reactivity due to long-standing CBF impairment.³⁾ Mortality and morbidity rates may significantly increase in patients with intracranial hemorrhage after carotid revascularization, and strict control of post-operative blood pressure might reduce the risk of developing intracranial hemorrhage after CEA.⁸⁾ CVR measurement on SPECT using acetazolamide challenge is regarded to be an effective measure to predict CHS after CEA, and numbers of alternative measures have been introduced.^{9–15)}

Transluminal carotid artery angioplasty with stenting (initially introduced for surgically high-risk patients in endarterectomy) has been recently established as an effective measure for carotid

Table 1 Patients of carotid artery stenosis treated with staged angioplasty for severe and widespread hemodynamic compromise on SPECT

No.	Age (years)	Sex	Symptoms	Side	Treatment	Interval (days)	Re-stenosis after 1 st PTA	Hyper-perfusion
1.	74	F	Impending stroke	R	staged CAS	69	–	–
2.	74	M	lt. visual loss/stroke	L	staged CAS	21	–	–
3.	71	M	LOC attacks	R	staged CAS	23	–	–
4.	74	M	Stroke	R	staged CAS	28	+	+
5.	59	M	Amaurosis fugax	R	staged CAS	16	–	–
6.	74	M	Amaurosis fugax	R	staged CAS	16	–	–
7.	74	M	Stroke	R	staged CAS	19	–	–
8.	70	M	Stenosis progression	R	staged CAS	16	–	–
9.	70	M	Stroke	R	staged CAS	19	–	–
10.	79	M	Stroke	R	staged CAS	19	–	–

CAS: carotid artery stenting, F: female, L: left, LOC: loss of consciousness, M: male, PTA: percutaneous transluminal angioplasty, R: right, SPECT: single photon emission computed tomogram –: negative, +: exist on angiogram/SPECT.

revascularization.^{16–18)} On the other hand, CBF changes and catastrophic hemorrhagic complications following CAS have been reported.^{19–21)} Besides, some reports showed the relationship between the pre-procedural CVR and post-procedural CHS.^{22–27)} Dual antiplatelet therapy with aspirin and clopidogrel around CAS is an essential measure to avoid the thromboembolic complications after CAS. Ogasawara et al. reported their result of nationwide survey for carotid artery revascularization in Japan and concluded that strict control of post-operative blood pressure prevented intracranial hemorrhage in patients with CHS after CEA; however, no relationship between blood pressure and intracranial hemorrhage after CAS.⁸⁾ In that study, 30 of 1596 patients (1.9%) after CEA and 31 of 2898 patients (1.1%) after CAS experienced CHS, respectively. Additionally, 6 (0.4%) after CEA and 21 (0.7%) after CAS experienced intracranial hemorrhage, respectively. Mortality and morbidity rates were higher in patients with intracranial hemorrhage. Accordingly, following CAS, the risk of CHS with blood pressure reduction is less possible to be reduced. In addition, strong antiplatelet therapy is an indispensable prerequisite for the patients treated with CAS, because they are at a higher risk for advancing hemorrhage. It is important to establish the effective measure to avoid CHS in CAS for patients with impaired vascular reactivity.

Staged angioplasty has initially been proposed in severe hemodynamically compromised patients by Yoshimura et al. to recover vascular reactivity with minimal percutaneous angioplasty followed by curative CAS with a few weeks interval.^{4,5)} It is, however, currently introduced over 27% of neuroendovascular institutes in Japan as an effective measure to prevent CHS after CAS.²⁸⁾ In our case series, 11 of 111 consecutive patients with carotid artery stenosis and CVR impairment, 10 cases were successfully treated with staged angioplasty.

Uchida et al. reported their 43-case series and successfully treated with staged angioplasty in 39 patients with successfully improving cerebrovascular reactivity before the second-stage CAS⁴⁾. However, immediate stent placement was required (due to inadequate dilatation in three and vascular dissection in one) during the first-stage angioplasty and hyperperfusion was observed after the first-stage angioplasty in four patients. In our case series, staged angioplasty could not be applied in one patient due to renal dysfunction (induced by repeated treatment for contralateral carotid artery stenosis) and coronary artery insufficiency (Fig. 1). In this patient, symptomatic CHS was observed with remarkable hyperperfusion on SPECT. In staged angioplasty,

avoiding over dilatation or immediate stent placement is an important matter to avoid CHS.

We made the first-stage palliative angioplasty with minimal sized balloon with a great care not to over-dilate the lesion to avoid stent placement due to vascular dissection. Despite the lesion not being obviously dilated, restoration of impaired CVR was observed within a few days (Fig. 4). In the first-stage palliative angioplasty, improving of the preexisting flow restriction might be enough to restore the impaired CVR.

In our case series, interval of the two treatments was ranged 16–69 days. In a case of 74-year-old woman with stroke-in-progress (Case 1), we need a 2-month interval with apprehension of hemorrhagic sequelae for apparent and wide spread stroke. In other nine patients, interval until second-stage CAS was within 3 weeks in eight and 4 weeks in one, respectively. The patient with a 4-week interval after the first-stage angioplasty (Case 4) showed restoration of the lesion at the second-stage CAS

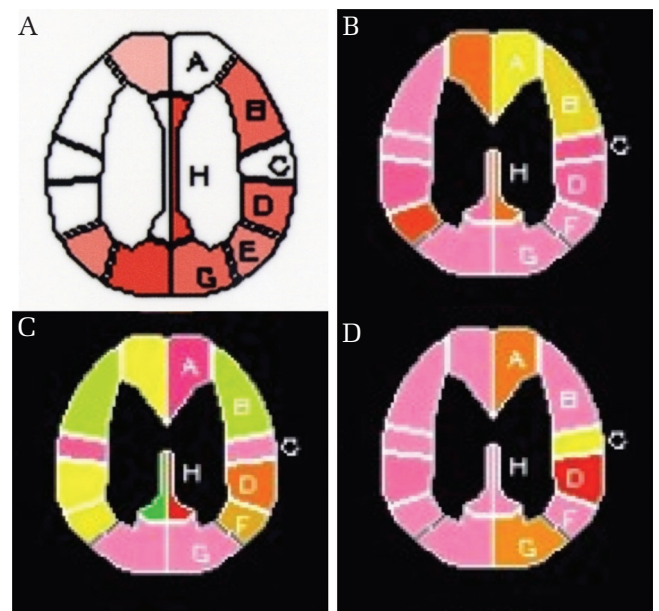


Fig. 4 Serial change of cerebral vascular reactivity (CVR) in case 3 described as “% Increase Map”, proposed by Japanese Extracranial—Intracranial Bypass Trial (JET)-2 Study, showing the areal change in the Cerebral blood flow (CBF) followed by acetazolamide challenge with quantitative analysis of single photon emission computed tomogram.²⁷⁾ (A) Regions that are poorly reacted or showed decreased CBF (pale areas) are widely spread in the right hemisphere before the treatment. (B) CVR in the right hemisphere recovered 1 day after the first-stage angioplasty. (C) CVR in the right hemisphere partially deteriorated (yellowish areas) 2 days before the second-stage carotid artery stenting. (D) CVR well recovered 2 days following the CAS.

and mild hyperperfusion syndrome was observed after CAS. In staged angioplasty, balloon angioplasty without obvious dilation is enough for restoring the impaired CVR, but is highly possible to result in restenosis. According to our case series, while CVR recovered within a few days after the first-stage angioplasty, at least 1-week interval between the two treatments is enough and should be accomplished within 3 weeks. In cases with severe hemodynamic compromise and acute stage ischemic lesions, staged angioplasty will be effective for reducing the risk of hemorrhagic complications; however, it is still difficult to define the exact interval between the two procedures. Further investigations might be needed.

This study has limitations that the results are based on a small case series in one institute. As a further problem, pathological conditions, such as acute thromboembolic occlusions are possible to appear additionally. As the staged angioplasty is anticipated as an effective measure to avoid CHS after CAS, establishing the standardized method is indispensable. Furthermore, as the indication of SPECT with acetazolamide challenge is quite limited for its risk of acute pulmonary edema as a side effect, the criteria for indicating the staged angioplasty without evaluating CVR by SPECT with acetazolamide challenge is also important. From the result of nationwide survey by Hayakawa et al., staged angioplasty is already introduced in over 27% of neuroendovascular institutes in Japan, detailed investigation and analysis with a large number of patients is necessary.²⁸⁾ Moreover, despite having effective role to prevent CHS, the staged angioplasty requires two procedures, which doubles the risk and cost. Improvident application of staged angioplasty is not only unnecessary but also harmful for patients and wasteful from the medico-economical perspective. Strict-and-wise decision for indicating staged angioplasty based on detailed CVR investigation is mandatory.

Conclusion

Staged angioplasty for severe carotid artery stenosis with hemodynamic compromise is a safe and effective procedure to avoid the catastrophic CHS complications. However, staged angioplasty increases risks and costs following the procedure and should be applied under strict indications.

Conflicts of Interest Disclosure

Authors have no conflicts of interest with regard to submit the manuscript and authors who are member of the Japan Neurosurgical Society (HN, KH, and AN)

completed the registration of online Self-reported COI Disclosure Statement Forums through the website for the Japan Neurosurgical Society.

References

- 1) Piepgras DG, Morgan MK, Sundt TM, Yanagihara T, Mussman LM: Intracerebral hemorrhage after carotid endarterectomy. *J Neurosurg* 68: 532–536, 1988
- 2) Solomon RA, Loftus CM, Quest DO, Correll JW: Incidence and etiology of intracerebral hemorrhage following carotid endarterectomy. *J Neurosurg* 64: 29–34, 1986
- 3) Hosoda K, Fujita S, Kawaguchi T, Shose Y, Shibata Y, Tamaki N: Influence of degree of carotid artery stenosis and collateral pathways and effect of carotid endarterectomy on cerebral vasoreactivity. *Neurosurgery* 42: 988–994, 1998
- 4) Uchida K, Yoshimura S, Shirakawa M, et al.: Experience of staged angioplasty to avoid hyperperfusion syndrome for carotid artery stenosis. *Neurol Med Chir (Tokyo)* 55: 824–829, 2015
- 5) Yoshimura S, Kitajima H, Enomoto Y, Yamada K, Iwama T: Staged angioplasty for carotid artery stenosis to prevent postoperative hyperperfusion. *Neurosurgery* 64 (3 Suppl): ons122–ons128, 2009
- 6) Barnett HJM, Taylor DW, Haynes RB, Sackett DL, Peerless SJ, et al.: North American Symptomatic Carotid Endarterectomy Trial Collaborators: Beneficial effect of carotid endarterectomy in symptomatic patients with high-grade carotid stenosis. *N Engl J Med* 325: 445–453, 1991
- 7) Kataoka H, Miyamoto S, Ogasawara K, et al.; JET-2 Investigators: Results of prospective cohort study on symptomatic cerebrovascular occlusive disease showing mild hemodynamic compromise [Japanese Extracranial-Intracranial Bypass Trial (JET)-2 Study]. *Neurol Med Chir (Tokyo)* 55: 460–468, 2015
- 8) Ogasawara K, Sakai N, Kuroiwa T, et al.; Japanese Society for Treatment at Neck in Cerebrovascular Disease Study Group: Intracranial hemorrhage associated with cerebral hyperperfusion syndrome following carotid endarterectomy and carotid artery stenting: retrospective review of 4494 patients. *J Neurosurg* 107: 1130–1136, 2007
- 9) Fukuda T, Ogasawara K, Kobayashi M, et al.: Prediction of cerebral hyperperfusion after carotid endarterectomy using cerebral blood volume measured by perfusion-weighted MR imaging compared with single-photon emission CT. *AJNR Am J Neuroradiol* 28: 737–742, 2007
- 10) Hosoda K, Kawaguchi T, Ishii K, et al.: Prediction of hyperperfusion after carotid endarterectomy by brain SPECT analysis with semiquantitative statistical mapping method. *Stroke* 34: 1187–1193, 2003
- 11) Kuroda H, Ogasawara K, Hirooka R, et al.: Prediction of cerebral hyperperfusion after carotid endarterectomy using middle cerebral artery signal intensity in

- preoperative single-slab 3-dimensional time-of-flight magnetic resonance angiography. *Neurosurgery* 64: 1065–1071, 2009
- 12) Ogasawara K, Yukawa H, Kobayashi M, et al.: Prediction and monitoring of cerebral hyperperfusion after carotid endarterectomy by using single-photon emission computerized tomography scanning. *J Neurosurg* 99: 504–510, 2003
 - 13) Ogasawara Y, Ogasawara K, Suzuki T, et al.: Preoperative ¹²³I-iomazenil SPECT imaging predicts cerebral hyperperfusion following endarterectomy for unilateral cervical internal carotid artery stenosis. *Am J Nucl Med Mol Imaging* 2: 77–87, 2012
 - 14) Oshida S, Ogasawara K, Saura H, et al.: Does preoperative measurement of cerebral blood flow with acetazolamide challenge in addition to preoperative measurement of cerebral blood flow at the resting state increase the predictive accuracy of development of cerebral hyperperfusion after carotid endarterectomy? Results from 500 cases with brain perfusion single-photon emission computed tomography study. *Neurol Med Chir (Tokyo)* 55: 141–148, 2015
 - 15) Matsubara S, Moroi J, Suzuki A, et al.: Analysis of cerebral perfusion and metabolism assessed with positron emission tomography before and after carotid artery stenting. Clinical article. *J Neurosurg* 111: 28–36, 2009
 - 16) Brott TG, Hobson RW, Howard G, Roubin GS, et al.; CREST Investigators: Stenting versus endarterectomy for treatment of carotid-artery stenosis. *N Engl J Med* 363: 11–23, 2010
 - 17) Brott TG, Howard G, Roubin GS, et al.; CREST Investigators: Long-term results of stenting versus endarterectomy for carotid-artery stenosis. *N Engl J Med* 374: 1021–1031, 2016
 - 18) Moresoli P, Habib B, Reynier P, Secrest MH, Eisenberg MJ, Filion KB: Carotid stenting versus endarterectomy for asymptomatic carotid artery stenosis: a systematic review and meta-analysis. *Stroke* 48: 2150–2157, 2017
 - 19) Isozaki M, Arai Y, Higashino Y, Okazawa H, Kikuta KI: Cerebral hyperperfusion syndrome resulting in subarachnoid hemorrhage after carotid artery stenting. *Ann Nucl Med* 30: 669–674, 2016
 - 20) Narita S, Aikawa H, Nagata S, et al.: Intraprocedural prediction of hemorrhagic cerebral hyperperfusion syndrome after carotid artery stenting. *J Stroke Cerebrovasc Dis* 22: 615–619, 2013
 - 21) Son S, Choi DS, Kim SK, et al.: Carotid artery stenting in patients with near occlusion: a single-center experience and comparison with recent studies. *Clin Neurol Neurosurg* 115: 1976–1981, 2013
 - 22) Chang TY, Liu HL, Lee TH, et al.: Change in cerebral perfusion after carotid angioplasty with stenting is related to cerebral vasoreactivity: a study using dynamic susceptibility-weighted contrast-enhanced MR imaging and functional MR imaging with a breath-holding paradigm. *AJNR Am J Neuroradiol* 30: 1330–1336, 2009
 - 23) Iwata T, Mori T, Tajiri H, Nakazaki M: Predictors of hyperperfusion syndrome before and immediately after carotid artery stenting in single-photon emission computed tomography and transcranial color-coded real-time sonography studies. *Neurosurgery* 68: 649–655, 2011
 - 24) Kaku Y, Yoshimura S, Kokuzawa J: Factors predictive of cerebral hyperperfusion after carotid angioplasty and stent placement. *AJNR Am J Neuroradiol* 25: 1403–1408, 2004
 - 25) Kawai N, Hatakeyama T, Okauchi M, et al.: Cerebral blood flow and oxygen metabolism measurements using positron emission tomography on the first day after carotid artery stenting. *J Stroke Cerebrovasc Dis* 23: e55–e64, 2014
 - 26) Suga Y, Ogasawara K, Saito H, et al.: Preoperative cerebral hemodynamic impairment and reactive oxygen species produced during carotid endarterectomy correlate with development of postoperative cerebral hyperperfusion. *Stroke* 38: 2712–2717, 2007
 - 27) Yoshie T, Ueda T, Takada T, Nogoshi S, Fukano T, Hasegawa Y: Prediction of cerebral hyperperfusion syndrome after carotid artery stenting by CT perfusion imaging with acetazolamide challenge. *Neuroradiology* 58: 253–259, 2016
 - 28) Hayakawa M, Matsumaru Y, Sakai N, et al.; for the Strategy of Optimal carotid revascularization for high-risk Patients of Cerebral Hyperperfusion Syndrome (STOP CHS) study group: Periprocedural evaluation and management against cerebral hyperperfusion syndrome after carotid artery stenting in Japan: a nationwide questionnaire survey. *J Neuroendovascular Therapy* 11: 341–350, 2017

Address reprint requests to: Hisashi Nagashima, MD, 2630 Sugitani, Toyama, Toyama 930-0194, Japan. e-mail: hinagashima-nsu@umin.ac.jp