

Recurrent esophagogastric variceal bleeding due to portal vein thrombosis caused by protein S deficiency



Authors

Haoxiong Zhou, Jieying Xuan, Xianyi Lin, Yunwei Guo

Institution

Department of Gastroenterology, the Third Affiliated Hospital of Sun Yat-Sen University, Guangzhou, China.

submitted 13.3.2018

accepted after revision 30.5.2018

Bibliography

DOI <https://doi.org/10.1055/a-0684-9638> |

Endoscopy International Open 2018; 06: E1283–E1288

© Georg Thieme Verlag KG Stuttgart · New York

ISSN 2364-3722

Corresponding author

Yunwei Guo, MD, PhD, Associate Professor, Department of Gastroenterology, The Third Affiliated Hospital of Sun Yat-Sen University, No. 600 Tianhe Road, Tianhe District, Guangzhou 510630, Guangdong Province, China
Fax: +86-20-85253336
guoyw@mail.sysu.edu.cn

ABSTRACT

Background and study aims Esophagogastric variceal bleeding (EGVB) is common in patients with portal vein thrombosis (PVT). Hereditary deficiencies in natural anticoagulant proteins, such as protein S, might contribute to PVT. However, recurrent EGVB caused by PVT in patients with protein S deficiency is seldom reported. Herein, we present the case of a 38-year-old man with protein S deficiency complicated with PVT. The patient suffered recurrent EGVB for 7 years. He underwent splenectomy plus pericardial revascularization and sequential endoscopic therapy, including one gastric variceal obturation (GVO) procedure and two esophageal variceal ligations (EVL) to eradicate the varices. Rivaroxaban was administered to reduce risk of thrombotic events. The patient is currently well without rebleeding after 1 year of follow-up. To our knowledge there is no consensus on management of recurrent EGVB on the basis of thrombophilia complicated with PVT. According to our practice, sequential endoscopic therapy combined with anticoagulant appears to be effective and safe.

Introduction

Portal vein thrombosis (PVT) is a rare form of venous thrombosis that is complicated by reduction in blood flow to the liver and portal hypertension. Portal hypertension owing to PVT usually causes varix, and if severe, can present as hematemesis or melena from rupture of esophageal and gastric varices, which is the most frequent presentation of PVT.

The pathogenesis of PVT has not been completely elucidated, but recent studies have reported that PVT is related to hereditary thrombophilic diseases, such as protein C, protein S and antithrombin III deficiency [1, 2]. However, there are few cases of variceal bleeding secondary to PVT caused by protein S deficiency, and few studies of optimal management of this condition, given its low incidence rate and the conflict of treatment between thrombosis and bleeding.

Herein, we report a case of recurrent esophagogastric variceal bleeding (EGVB) secondary to PVT caused by protein S deficiency. The patient was finally successfully treated with se-

quential endoscopic therapy combined with rivaroxaban and propranolol.

The study was reviewed and approved by the Institutional Review Board of the Third Affiliated Hospital of Sun Yat-Sen University.

Case report

A 38-year-old man with recurrent EGVB for 7 years was admitted to our department for a new episode of EGVB. He complained of melena and fatigue and denied fever, nausea, hematemesis and hematochezia.

He also reported several episodes of deep vein thrombosis (DVT) of lower limbs and one cerebral infarction 16 years previously. The patient had received systemic low-molecular-heparin followed by oral warfarin as anticoagulation therapy when he was found to have DVT. Seven years earlier, the patient had complained of melena and abdominal pain. Abdominal computed tomography (CT) scan at that time revealed PVT with cavernous transformation and splenomegaly. However,

there was no indication of cirrhosis. Liver function was also normal. EGVB was confirmed by upper endoscopy. The patient had undergone endoscopic sclerotherapy of fundal varices once without follow-up. Three years previously, esophagogastric variceal rebleeding occurred, and the patient underwent splenectomy plus pericardia revascularization after consultation with his surgeon. Since then, he had a 3-year interval of no gastrointestinal bleeding.

On admission, he was hemodynamically stable and conscious, but his conjunctivae were pale. Laboratory findings were as follows: white blood cell count, $5750/\text{mm}^3$ (normal: $3500\text{--}9500/\text{mm}^3$); hemoglobin, 8.9 g/dl ($13.0\text{--}17.5\text{ g/dl}$); hematocrit, 29.3% (40–50%); platelet count, $290,000/\text{mm}^3$ ($100,000\text{--}350,000/\text{mm}^3$); aspartate aminotransferase (AST), 21 U/L; alanine aminotransferase (ALT), 19U/L; total protein, 6.47 g/dl ($6.1\text{--}8.2\text{ g/dl}$); albumin, 3.73 g/dl ($3.6\text{--}5.1\text{ g/dl}$); globulin, 2.74 g/dl ($2.5\text{--}3.5\text{ g/dl}$); prothrombin rate, 91%; activated partial thromboplastin time, 34.9s ($30\text{--}45\text{ s}$); prothrombin time international normalized ratio (PT INR), 1.01; and homocysteine, $20.77\text{ }\mu\text{mol/L}$ ($3.7\text{--}13.9\text{ }\mu\text{mol/L}$). The D-dimer value was $1.77\text{ }\mu\text{g/mL}$. Serum lupus anticoagulant, anticardiolipin and antinuclear antibodies were absent. The patient was negative for HIV, hepatitis A, C and D, and syphilis. HBsAg, HBeAb and HbCAb were positive, and the HBV-DNA value was $3.33\text{E}+2\text{ IU/mL}$. Markers of liver fibrosis are all normal. Abdominal CT scan showed portal thrombosis at the portal vein and its right branch (► Fig. 1a, b), as well as thrombosis at the left common iliac vein and internal iliac vein. Abdominal CT scan also showed esophagogastric varices and paraumbilical veins (► Fig. 1c, d). Cavernous transformation of portal vein (CTPV) was also diagnosed. Abdominal Doppler ultrasound also supported the diagnosis of PVT and CTPV (► Fig. 1e, f).

Because the patient refused liver biopsy, fibroscan for liver stiffness measurement was performed, and the liver stiffness of the patient was 5.7 KPa, which helped to exclude cirrhosis. Lower limb color Doppler demonstrated non-occlusive thrombosis at the bilateral femoral vein, superficial femoral vein, the left great saphenous vein and small saphenous vein.

Because the patient experienced several thromboembolic events, including DVT of lower limbs and cerebral infarction as well as PVT, a thorough thrombophilia workup was performed. Antithrombin III level and protein C activity were 83% (normal: 80–120%) and 120% (normal: 70–130%), respectively. Free protein S (PS) activity showed a decrease of 25% (normal: 60–150%). His mother, who was healthy and asymptomatic, was also screened for thrombophilia and was found to be protein S-deficient. We considered that the inherited protein S deficiency was the primary cause of PVT and other thromboembolic events.

Upper endoscopy was performed, which showed grade 3 esophageal varices and large fundal varices with red-color sign. The patient received sequential endoscopic therapy with one gastric variceal obturation (GVO) using N-butyl-2-cyanoacrylate and two esophageal variceal ligations (EVL) in 1 year (► Fig. 2a–l). He was administered propranolol to alleviate portal hypertension and rivaroxaban to reduce risk of thrombotic events. Rivaroxaban was withdrawn 3 to 5 days before each

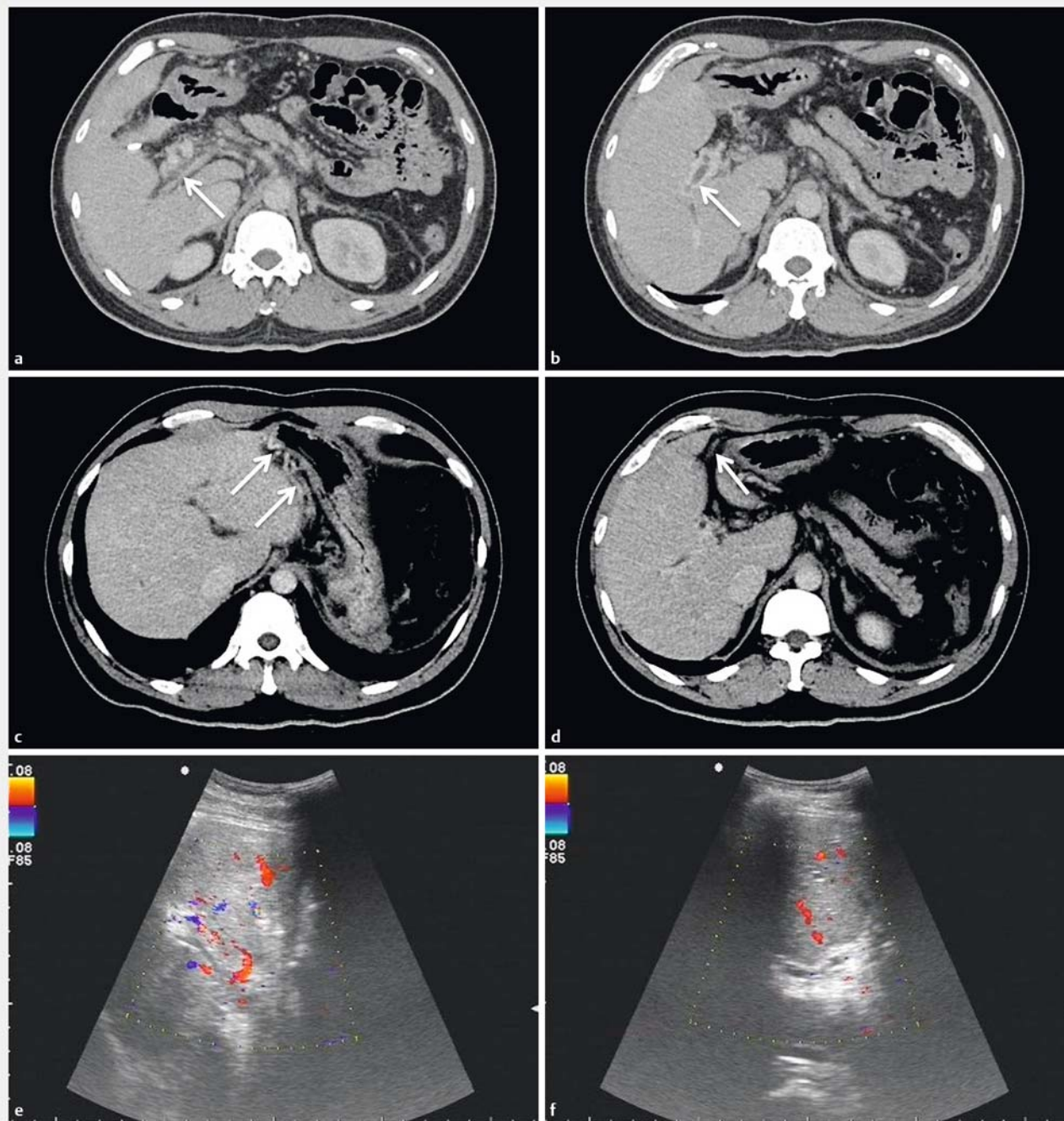
endoscopy and restarted 3 days after endoscopic treatment. Following the patient's last endoscopy, we found that there were only two small columns of esophageal varices and small segmental fundal varices without red color sign (► Fig. 2j–l). As a result, we considered that no further EVL was needed. After 1-year follow-up, no rebleeding and thrombotic events occurred.

Discussion

PVT is a rare event that frequently leads to portal hypertension in an acute or chronic manner. In most cases, the symptoms are nonspecific. Upper gastrointestinal bleeding secondary to esophagogastric variceal rupture is one of the most severe presentations.

The pathogenesis of PVT has not been completely elucidated to date. According to recent studies, PVT is generally provoked by one or more factors. These factors include acquired or inherited prothrombotic disorders and local factors. Local factors, such as liver cirrhosis, visceral inflammation or infection, abdominal surgery and blunt trauma, are well-known to most clinics. Acquired disorders include malignancy, myeloproliferative disorders, exposure to oral contraceptive drugs, antiphospholipid syndrome and paroxysmal nocturnal hemoglobinuria. Inherited alterations include antithrombin III deficiency, protein C deficiency, protein S deficiency, Leiden factor V mutation and prothrombin G20210A mutation [3]. In our case, although HBsAg was positive in this patient, the indexes of liver function were normal over 16 years. The patient refused liver biopsy and pathological evaluation was not possible, but serum fibrosis markers and fibroscan of liver were all normal. Therefore, we do not believe that liver cirrhosis was the cause of PVT in this patient. The patient had protein S deficiency as did his mother who had no history of thrombotic events. Thus, protein S deficiency in our patient was probably inherited. Moreover, the association of PVT with several episodes of DVT of lower limbs and one cerebral infarction suggests that protein S deficiency was the predisposing factor for PVT.

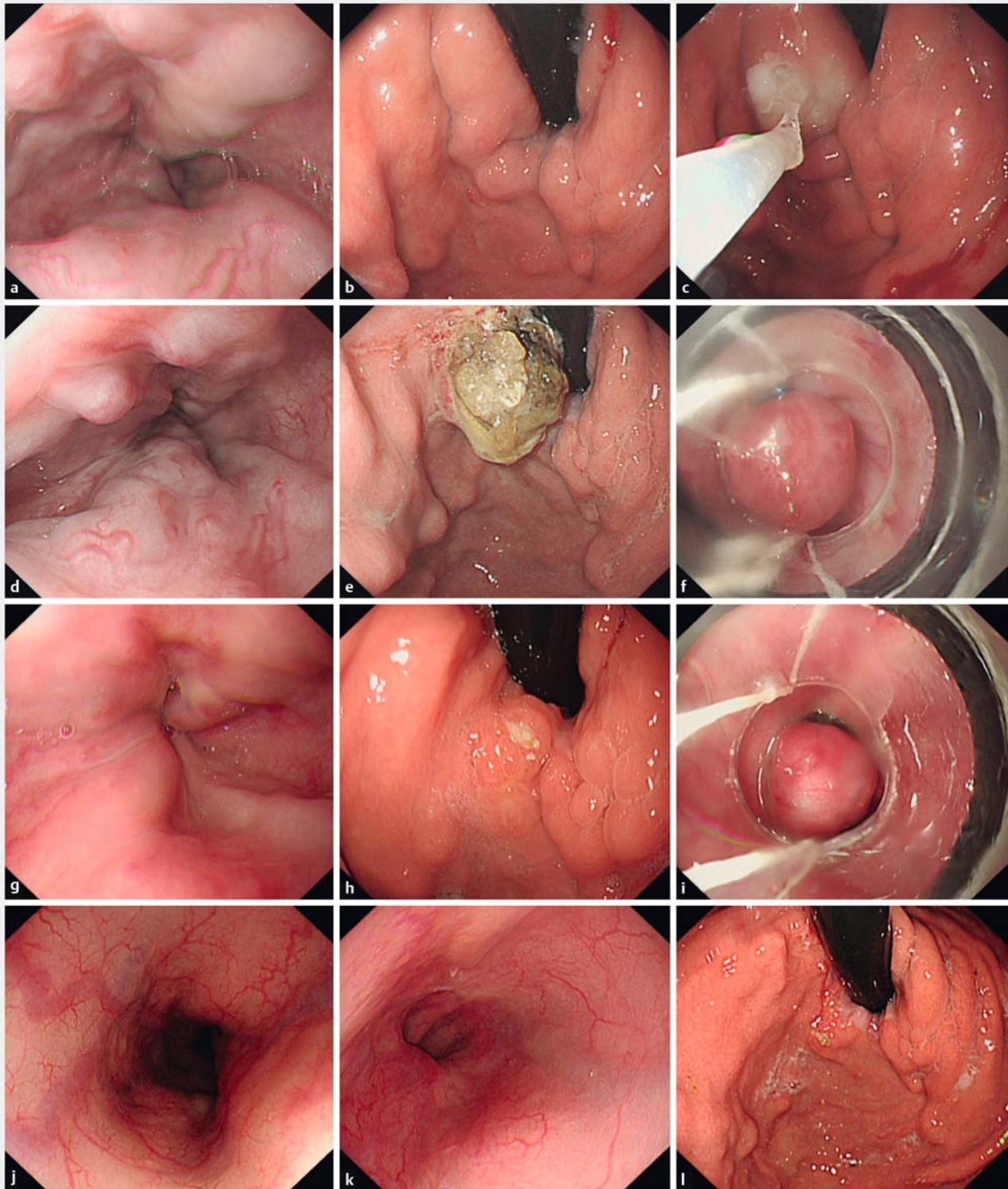
Protein S is a natural anticoagulant mainly derived from liver synthesis. Because of the rarity of hereditary protein S deficiency and the difficulty of correct diagnosis, the prevalence of protein S deficiency in the general population is unknown to a large extent. However, a study of protein S antigen levels in 3788 healthy volunteers indicated that prevalence of protein S deficiency ranged from 0.03% to 0.13% [4]. Patients with inherited PC/PS deficiency have an approximately 2- to 11-fold increased risk for development of venous thromboembolism (VTE), with its main clinical manifestations of DVT and pulmonary embolism (PE) compared with those without a deficiency [1]. Less common manifestations of inherited PC/PS deficiency include superficial, cerebral, mesenteric, visceral and axillary vein thrombosis [5], as noted in our patient. In addition, the rate of protein S deficiency ranges between 0% and 30% in PVT in some reports [6, 7]. No matter whether there is an associated precipitant, deficiency of protein S should be considered a differentiator in pathogenesis of PVT, and an underlying inherited anticoagulant protein deficiency should be investigated.



► **Fig. 1** Abdominal CT scan and abdominal Doppler ultrasound. **a, b** Non-occlusive portal vein thrombus and cavernous transformation are noted. **c, d** esophagogastric varices and paraumbilical veins are noted. **e, f** Diffuse portal vein stenosis and cavernous transformation were noted.

Given an increased risk of recurrent thrombotic events, life-long anticoagulation therapy such as warfarin seems necessary in patients with protein S deficiency. But sufficient clinical evidence about the long-term outcome of anticoagulation therapy is lacking possibly given the dilemma in managing PVT concomitant with variceal bleeding. A study assessed current outcome and predictors of bleeding and thrombotic events in patients with noncirrhotic and nonmalignant portal vein throm-

bosis who received anticoagulant therapy, and concluded that risk of thrombosis is as clinically significant as risk of bleeding and oral anticoagulant treatment has a favorable benefit-risk ratio, especially in patients with underlying thrombophilic disorders [8]. Anticoagulation does not increase risk of bleeding and rebleeding in patients with esophagogastric varices and PVT [9].



► **Fig. 2** Gastroscopic images. **a, b, c** The first gastroscopy revealed grade 3 esophageal varices and large fundal varices with red-color sign. Gastric variceal obturation (GVO) using N-butyl-2-cyanoacrylate was performed. **d, e, f** The second gastroscopy revealed grade 3 esophageal varices with red-color sign and glue extrusion of fundal varices. The first esophageal variceal ligation (EVL) was performed. **g, h, i** The third gastroscopy revealed grade 2 esophageal varices with red-color sign and little glue extrusion of fundal varices. The second EVL was performed. **j, k, l** The fourth gastroscopy revealed only two small columns of esophageal varices without red color sign and small segmental fundal varices with little glue extrusion. No further endoscopic treatment was performed.

In our case, splenectomy with esophagogastric devascularization was really helpful and effective to control bleeding 3 years ago. And surgery like splenectomy with esophagogastric devascularization or shunt is believed to be effective to control EGVB in patients with portal hypertension [10]. But there are no guidelines or studies to provide specific guidance for management of PVT with thrombophilia. The patient was found to have EGVB again after surgery and the rebleeding was possibly due to two reasons. First, splenectomy may contribute to an increase in portal pressure which leads to development of collateral circulation. Secondly, PVT is considered a rare complication after splenectomy [11] that contribute to aggregation of portal hypertension. As mentioned above, patients with thrombophilia have a high risk for development of venous thromboembolism. We considered that both splenectomy and thrombophilia caused by deficiency of protein S contributed to development of PVT and portal hypertension in our patient because he did not receive anticoagulation after surgery, which led to rebleeding. The exact role of splenectomy with esophagogastric devascularization or shunt surgery for this population is controversial and substantial evidence supporting surgery is lacking.

When protein S deficiency was diagnosed, the patient was strongly urged to receive anticoagulant treatment regularly to reduce risk of thrombotic events. He decided to take rivaroxaban rather than warfarin because of the lack of requirement for routine coagulation tests. In recent publications, direct-acting oral anticoagulants (DOACs) were demonstrated to be safe and effective in patients with splanchnic vein thrombosis and non-cirrhotic PVT [12, 13]. A systematic review and meta-analysis concluded that NOACs have comparable efficacy to vitamin K antagonists (VKAs) and are associated with significantly lower risk of bleeding complications [14]. However, there is no specific guidance for anticoagulation in patients with thrombophilia. Though limited studies including case studies and clinical trials show the advantage of DOACs in treating this population compared to warfarin [15], larger studies and substantial evidence are still needed to evaluate the effectiveness of DOACs.

In our clinical practice, we have found that sequenced endoscopic treatment, including one to two sessions of GVO with N-butyl-2-cyanoacrylate and three to five sessions of EVL, occasionally followed by one to two sessions of endoscopic variceal sclerotherapy (EVS) with 1% aethoxysclerol on smaller esophageal varices, can efficiently eradicate or considerably alleviate the varices. Although endoscopic treatment reportedly is also a safe and effective treatment for variceal bleeding in patients with PVT, as in patients with cirrhosis [16], the efficacy and safety of it in patients with protein S deficiency are unknown. Fortunately, sequenced endoscopic treatment combined with rivaroxaban and propranolol was also proven to be effective in the current patient. To ensure safety during endoscopic treatment, rivaroxaban was suggested to be stopped for a short period of time. Considerable alleviation of esophagogastric varices was achieved, and no rebleeding and thrombotic events were noted after a follow-up period of 1 year.

Conclusion

This case shows that protein S deficiency can manifest as recurrent EGVB secondary to PVT. There is no consensus on treatment of recurrent EGVB on the basis of PVT combined with thrombophilia. We believe it may be effective to treat these patients with sequential endoscopic therapy combined with anticoagulation and propranolol. Further studies are needed to prove the efficiency and safety of anticoagulant therapy in patients with protein S deficiency concomitant with variceal bleeding.

Acknowledgements

Supported by Guangdong Science and Technology Program, No. 2016A020216012.

Competing interests

None

References

- [1] Lipe B, Ornstein DL. Deficiencies of natural anticoagulants, protein C, protein S, and antithrombin. *Circulation* 2011; 124: e365–e368
- [2] Hwang S, Kim DY, Kim M et al. Deficiencies in proteins C and S in a patient with idiopathic portal hypertension accompanied by portal vein thrombosis. *Korean J Hepatol* 2010; 16: 176–181
- [3] Chirinos VJA, Muñoz GR, Amo PM et al. Portal and mesenteric thrombosis associated with protein S deficiency. *Rev Esp Enferm Dig* 2008; 100: 104–107
- [4] Dykes AC, Walker ID, McMahon AD et al. A study of Protein S antigen levels in 3788 healthy volunteers: influence of age, sex and hormone use, and estimate for prevalence of deficiency state. *Br J Haematol* 2001; 113: 636–636
- [5] ten Kate MK, van der Meer J. Protein S deficiency: a clinical perspective. *Haemophilia* 2008; 14: 1222–1228
- [6] Primignani M, Martinelli I, Bucciarelli P et al. Risk factors for thrombophilia in extrahepatic portal vein obstruction. *Hepatology* 2005; 41: 603–608
- [7] Denninger MH, Chaït Y, Casadevall N et al. Cause of portal or hepatic venous thrombosis in adults: the role of multiple concurrent factors. *Hepatology* 2000; 31: 587–591
- [8] Condat B, Pessione F, Hillaire S et al. Current outcome of portal vein thrombosis in adults: risk and benefit of anticoagulant therapy. *Gastroenterology* 2001; 120: 490–497
- [9] Noronha FC, Seijo S, Plessier A et al. Natural history and management of esophagogastric varices in chronic noncirrhotic, nontumoral portal vein thrombosis. *Hepatology* 2016; 63: 1640–1650
- [10] Su AP, Zhang ZD, Tian BL et al. Transjugular intrahepatic portosystemic shunt versus open splenectomy and esophagogastric devascularization for portal hypertension with recurrent variceal bleeding. *Hepatobiliary Pancreat Dis Int* 2017; 16: 169–175
- [11] Ellison EC, Fabri PJ. Complications of splenectomy. Etiology, prevention, and management. *Surg Clin North Am* 1983; 63: 1313–1330
- [12] Nery F, Valadares D, Morais S et al. Efficacy and safety of direct-acting oral anticoagulants use in acute portal vein thrombosis unrelated to cirrhosis. *Gastroenterology Res* 2017; 10: 141–143

- [13] De Gottardi A, Trebicka J, Klinger C et al. Antithrombotic treatment with direct-acting oral anticoagulants in patients with splanchnic vein thrombosis and cirrhosis. *Liver Int* 2017; 37: 694 – 699
- [14] van der Hulle T, Kooiman J, den Exter PL et al. Effectiveness and safety of novel oral anticoagulants as compared with vitamin K antagonists in the treatment of acute symptomatic venous thromboembolism: a systematic review and meta-analysis. *J Thromb Haemost* 2014; 12: 320 – 328
- [15] Skelley JW, White CW, Thomason AR. The use of direct oral anticoagulants in inherited thrombophilia. *J Thromb Thrombolysis* 2017; 43: 24 – 30
- [16] Spaander MC, Darwish MS, van Buuren HR et al. Endoscopic treatment of esophagogastric variceal bleeding in patients with noncirrhotic extrahepatic portal vein thrombosis: a long-term follow-up study. *Gastrointest Endosc* 2008; 67: 821 – 827