

# Delayed gadolinium-enhanced magnetic resonance imaging of hip joint cartilage: pearls and pitfalls

Bernd Bittersohl,<sup>1,2</sup> Christoph Zilkens,<sup>2</sup> Young-Jo Kim,<sup>3</sup> Stefan Werlen,<sup>4</sup> Klaus A. Siebenrock,<sup>1</sup> Tallal C. Mamisch,<sup>1,4</sup> Harish S. Hosalkar,<sup>5</sup>

<sup>1</sup>Department of Orthopedic Surgery, Inselspital, Bern, Switzerland;

<sup>2</sup>Department of Orthopedics, Heinrich-Heine University Medical School, Düsseldorf, Germany,

<sup>3</sup>Department of Orthopedic Surgery, Children's Hospital, Boston, Massachusetts, USA; <sup>4</sup>Department of Radiology, Sonnenhof Hospital, Bern, Switzerland; <sup>5</sup>Department of Orthopedic Surgery, Rady Children's Hospital, San Diego, CA, USA

## Abstract

With the increasing advances in hip joint preservation surgery, accurate diagnosis and assessment of femoral head and acetabular cartilage status is becoming increasingly important. Magnetic resonance imaging (MRI) of the hip does present technical difficulties. The fairly thin cartilage lining necessitates high image resolution and high contrast-to-noise ratio (CNR). With MR arthrography (MRA) using intraarticular injected gadolinium, labral tears and cartilage clefts may be better identified through the contrast medium filling into the clefts. However, the ability of MRA to detect varying grades of cartilage damage is fairly limited and early histological and biochemical changes in the beginning of osteoarthritis (OA) cannot be accurately delineated. Traditional MRI thus lacks the ability to analyze the biological status of cartilage degeneration. The technique of delayed gadolinium-enhanced MRI of cartilage (dGEMRIC) is sensitive to the charge density of cartilage contributed by glycosaminoglycans (GAGs), which are lost early in the process of OA. Therefore, the dGEMRIC technique has a potential to detect early cartilage damage that is obviously critical for decision-making regarding time and extent of intervention for joint-preservation. In the last decade, cartilage imaging with dGEMRIC has been established as an accurate and reliable tool for assessment of cartilage status in the knee and hip joint.

This review outlines the current status of dGEMRIC for assessment of hip joint cartilage. Practical modifications of the standard tech-

nique including three-dimensional (3D) dGEMRIC and dGEMRIC after intra-articular gadolinium instead of iv-dGEMRIC will also be addressed.

## Introduction

Magnetic resonance imaging (MRI) is an excellent diagnostic tool to assess cartilage changes in the joint including the extent and degree of degenerative changes.<sup>1</sup> It is proven to be reliable and reproducible in most of the di-artrodial joints including the knee and hip joint. However, there are technical challenges while approaching and imaging the hip joint with MRI.<sup>2</sup> With MR arthrography (MRA) using intraarticular injected gadolinium, labral tears and cartilage clefts may be better identified through the contrast medium filling into the tears and clefts.<sup>3,4</sup>

Despite these technical advantages, the ability of MRA to detect varying grades of cartilage damage (i.e. biologic severity) is fairly limited.<sup>5,6</sup> Additive MRI and MRA techniques that are sensitive to biochemical changes within cartilage may help to overcome this disadvantage.<sup>7-9</sup> The MRI technique of delayed gadolinium-enhanced MRI of cartilage (dGEMRIC) is a well-documented, reliable and reproducible method that is sensitive to the charge density of cartilage contributed by glycosaminoglycans (GAGs).<sup>7,9-16</sup> GAGs are important structural components of cartilage and relevant for maintaining the intrinsic mechanical properties that are lost early in the process of OA.<sup>17,18</sup>

Thus the dGEMRIC technique has a potential to detect early cartilage damage, which in turn is very helpful to clinicians for critical decision making regarding timely intervention for therapy. This review outlines the current status of dGEMRIC and technical considerations specific to dGEMRIC for assessment of hip joint cartilage. In addition, certain practical modifications of the standard dGEMRIC approach, which substantially help in its ability to improve hip joint imaging, have been outlined.

## Theory of dGEMRIC

The dGEMRIC technique uses the negatively charged contrast agent gadolinium-diethylene triamine pentaacetic acid (Gd-DTPA<sup>2-</sup>) that is used as standard contrast medium for MRA in the routine clinical setup. After intravenous injection and systemic circulation, Gd-DTPA<sup>2-</sup> distributes within cartilage inversely to the negatively charged GAG content (Figure 1). Gd-DTPA<sup>2-</sup> reduces the T1 relaxation time within the infiltrated tissue. Thereby, subse-

Correspondence: Harish S. Hosalkar, Rady Children's Hospital, San Diego, UCSD, Pediatric Orthopedic Training Program, Children's Hospital-San Diego 3030 Children's Way, Suite 410, San Diego, CA 92123 USA.  
Tel. +1.858.966.5822 - Fax: +1.858.966.8519.  
E-mail: hhosalkar@rchsd.org

Key words: dGEMRIC, Cartilage imaging, hip joint.

Received for publication: 18 July 2011  
Accepted for publication: 31 August 2011

This work is licensed under a Creative Commons Attribution NonCommercial 3.0 License (CC BY-NC 3.0).

©Copyright B. Bittersohl et al., 2011  
Licensee PAGEPress, Italy  
Orthopedic Reviews 2011; 3:e11  
doi:10.4081/or.2011.e11

quent T1 measurement in cartilage described as dGEMRIC index or T1<sub>Gd</sub> reflects the GAG content within a certain cartilage region where higher T1<sub>Gd</sub> values will be found in healthy cartilage whereas T1<sub>Gd</sub> values will be lower in degenerated cartilage based on the high amount of infiltrated Gd-DTPA<sup>2-</sup>. A time frame of 30 minutes to 60 minutes between Gd-DTPA<sup>2-</sup> injection and dGEMRIC is necessary for systemic circulation.<sup>11</sup>

There is an ongoing debate regarding the MRI parameters that have to be assessed using dGEMRIC to provide the most accurate status of cartilage degeneration in general. Key values of T1 relaxation that provide information are: T1<sub>0</sub> (i.e. T1 prior to contrast administration), T1<sub>Gd</sub> (post-contrast T1) and ΔR1 that defines the difference in relaxation rate (R1=1/T1) between T1<sub>0</sub> and T1<sub>Gd</sub> measurements (1/T1<sub>Gd</sub>-1/T1<sub>0</sub>). According to some studies ΔR1 may be a more precise parameter to reflect the Gd-DTPA<sup>2-</sup> concentration within cartilage as pre-contrast T1 variations can be factored in.<sup>9,14,19</sup> Previous studies in the knee have elucidated that T1<sub>0</sub> values differ minimally in early cartilage degeneration and that there is nearly a linear relationship between the GAG content and T1<sub>Gd</sub> making T1<sub>0</sub> assessment in addition to T1<sub>Gd</sub> unnecessary.<sup>7,20-22</sup>

Williams *et al.* performed measurements of T1<sub>0</sub> and T1<sub>Gd</sub> in the knee of 20 volunteers at 1.5T and 3T to analyze the correlation between T1<sub>Gd</sub> and ΔR.<sup>22</sup> A high correlation between the two metrics at both field strengths was noted with high correlation coefficients ranging from r=0.87 to r=0.96 at 1.5T and r=0.90 to r=0.94 at 3T (P < 0.0001 in all cases). We evaluated T1<sub>Gd</sub> and ΔR1 in two different radiographic grades of hip osteoarthritis (Tonniss grade 0 and Tonniss grade 1) in symptomatic

femoroacetabular impingement (FAI) patients.<sup>23</sup> Asymptomatic young-adult volunteers served as control. In this study, we observed a very high correlation between  $T1_{Gd}$  and  $\Delta R1$  in all study groups. In the study cohort with no radiographic signs of OA (Tonnis grade 0), the correlation was  $r=0.95$ . In the patient group that revealed early signs of OA in plain radiographs (Tonnis grade 1) a correlation of  $r=0.89$  was noted. In the control cohort of asymptomatic young-adult volunteers, the correlation between  $T1_{Gd}$  and  $\Delta R1$  was  $r=0.88$ . Correlation was statistically significant ( $P < 0.001$ ) for all study groups. Based on these results, we conclude that  $T1_{Gd}$  assessment is sufficient for assessing the status of hip joint cartilage and a further time-consuming and expensive pre-contrast imaging may not be essential. However, there are circumstances that sometimes require the calculation of  $\Delta R1$  for accurate GAG evaluation. These include cartilage fibrillation, follow-up of cartilage repair therapy (example cartilage transplantation) where  $T1_0$  values may differ to a great extent from those in normal hyaline cartilage especially in the early post-surgical period.<sup>9,19,24</sup>

## 2D dGEMRIC

Kim *et al.* reported the diagnostic potential of dGEMRIC for assessment of early OA in patients with hip dysplasia (mean age 30 years, range 11 to 47 years).<sup>8</sup>  $T1_{Gd}$  values decreased depending on the grade of dysplasia ranging from approximately 550 ms (in mild changes) to 500 ms (for moderate changes) and 420 ms (in cases of severe changes). For comparison,  $T1_{Gd}$  values in eight asymptomatic and morphologically normal appearing hips on the opposite side (mean age 37 years, range 20 to 48 years) were assessed. In this group, mean values and standard deviation were  $570 \pm 90$  ms. For MR imaging the authors used a 1.5 T system and a fast-spin echo technique with inversion recovery to obtain four coronal MR slices in the weight-bearing zone.

Tiderius *et al.* evaluated the time course of T1 values after Gd-DTPA<sup>2-</sup> injection in eight asymptomatic volunteers (mean age 28 years, range 20 to 47 years) and ten patients (mean age 39 years, range 25 to 58 years) with hip dysplasia having radiographic signs of early OA.<sup>25</sup> Coronal T1 mapping was obtained utilizing a fast-spin echo sequence with inversion recovery. At 90 minutes after Gd-DTPA<sup>2-</sup> injection  $T1_{Gd}$  values were approximately 540 ms in healthy volunteers and approximately 420 ms in the symptomatic patient group. In a further study of 47 patients undergoing a Bernese periacetabular osteotomy for the treatment of hip dysplasia, preoperative dGEMRIC values

and radiographic parameters were assessed and correlated with the treatment outcome.<sup>12</sup> Hips in which the osteotomy did fail had significantly more arthritis on preoperative radiographs ( $P=0.01$ ), more subluxation ( $P=0.02$ ), and a lower dGEMRIC index ( $P<0.001$ ) than hips in which the osteotomy did not fail. Interestingly, multivariate analysis identified the dGEMRIC index as the most important predictor of failure of the osteotomy.

As performed by the same study group in 2003,<sup>8</sup> a multi-slice fast-spin-echo sequence was used to obtain four coronal slices (inversion recovery technique). A similar study was reported in 2009 by Jessel *et al.* who retrospectively analyzed 37 hips with symptomatic FAI.<sup>26</sup> Surgical intervention is often necessary in symptomatic FAI and the outcome largely depends on the degree of pre-existing OA with reported poor results in patients with advanced cartilage damage.<sup>27,28</sup> Clinical symptoms, radiographic parameters such as Tonnis grade (of osteoarthritis) and dGEMRIC values were assessed. Furthermore, on MRI, the head-neck offset was graded using the alpha angle. This study noted significant correlation between dGEMRIC index, pain ( $P<0.05$ ), and increased alpha angle ( $P<0.05$ ). The amount of radiographic arthritis was mild for the majority of the hips (26 of 37) having Tonnis grade 0 or 1. However, despite the mild radiographic arthritis, a significant drop of  $T1_{Gd}$  ( $T1_{Gd}=464 \pm 64$  ms) was noted. In these mildly arthritic hips, neither Tonnis grade nor joint space width correlated with patient symptoms.

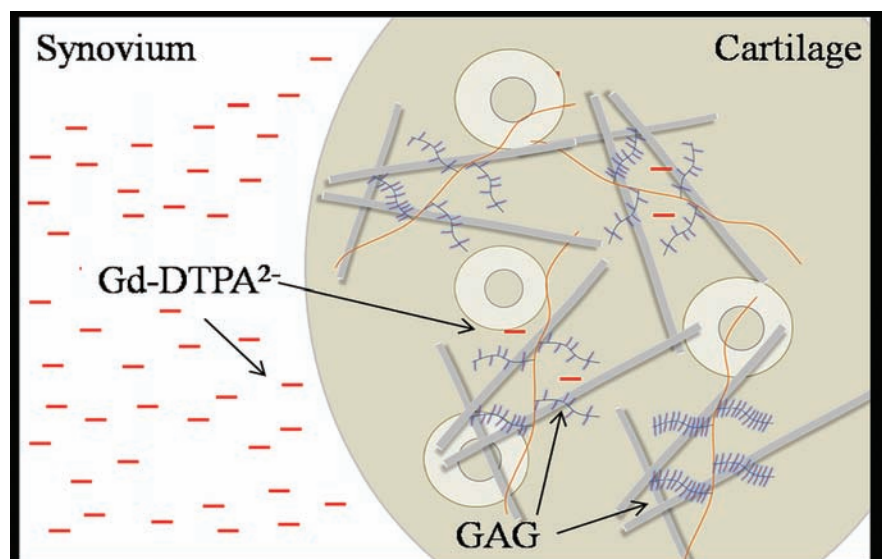
Lattanzi *et al.* have recently reported on a new high resolution two-dimensional (2D) T1 map-

ping saturation-recovery pulse sequence with fast spinecho readout for delayed gadolinium-enhanced magnetic resonance imaging of cartilage of the hip at 3 T.<sup>29</sup> This proposed sequence was validated in a phantom and in ten hips, using radial imaging planes, against a rigorous multipoint saturation-recovery pulse sequence with fast spin echo readout. T1 measurements by the two pulse sequences were strongly correlated ( $R^2>0.95$ ) and in excellent agreement (mean difference=-8.7 ms; upper and lower 95% limits of agreement=64.5 and -81.9 ms, respectively).

## 3D dGEMRIC

The limitation of 2D studies has been that only coronal T1 maps may be obtained by using fast-spin echo with inversion recovery. However, cartilage damage can exist at any specific locations within the hip (Figure 2) and therefore complete 3D radial evaluation around the hip joint is essential for the detection of cartilage pathology.<sup>3</sup>

Recently, fast T1 assessment using dual flip angle (FA) gradient echo (GRE) in place of standard inversion recovery for T1 mapping has been validated in phantom studies and was used in-vivo enabling faster imaging times and 3D dGEMRIC.<sup>24,30</sup> This technique utilizes inline T1 measurement and allows for faster imaging and the unique ability of using 3D dGEMRIC (Figure 3). A reproducibility study on 15 asymptomatic volunteers proved this technique to be a reliable instrument in the assess-



**Figure 1.** After intravenous injection and systemic circulation, the negatively charged contrast agent diethylene triamine pentaacetic acid (Gd-DTPA<sup>2-</sup>) penetrates into the cartilage in an inversely proportional manner to the negatively charged glycosaminoglycan (GAG) content. According to the decrease of GAG within cartilage in cartilage degeneration, more Gd-DTPA<sup>2-</sup> penetrates into the cartilage, which will cause reduction of T1 relaxation time. Note: Coll indicates collagen fiber, Chon indicates chondrocyte.

ment of asymptomatic hip joint cartilage.<sup>31</sup> The acquisition time for 3D dGEMRIC was below nine minutes in this study.

In a preliminary study on 26 symptomatic FAI patients and ten asymptomatic controls, Bittersohl *et al.* revealed a trend of lower  $T1_{Gd}$  mean values in the entire joint as compared to asymptomatic volunteers.<sup>32</sup> Furthermore, a pattern of zonal variation that seems to be unique for a sub-group of FAI lesions could be revealed (Figure 4).

The zonal distribution of 3D  $T1_{Gd}$  mapping in the hip joint of asymptomatic adult volunteers at 1.5 Tesla has been recently characterized.<sup>33</sup> This study included ten volunteers (3 males and 7 females with a mean age of 26.5 years; range, 24-31 years). MRI protocol included standard sequences for hip imaging and a dual-flip-angle 3D gradient-echo (GRE) sequence with volumetric interpolated breath-hold examination (VIBE) post-contrast administration. Analysis of the radial distribution revealed an increase of  $T1_{Gd}$  values toward the superior regions.  $T1_{Gd}$  values differed between the peripheral and central portions. The standard deviation (SD) ranged from 76.2 ms to 124.1 ms in the peripheral zone, and from 69.1 ms to 112.9 ms in the central zone. In both zones, SD was low in the superior regions compared with the anterior and posterior regions of the joint. Based on the high intra- (0.95) and interobserver (0.87) agreement, normative data obtained from this study will prepare the foundation for further studies of dGEMRIC and  $T1$  measurement in the hip. These findings are critical while outlining future studies for detailed objective evaluation of zonal cartilage lesions due to varying pathologies.

Domayer *et al.* have outlined the pattern of cartilage damage in symptomatic cases of developmental dysplasia of the hip (DDH) and of femoroacetabular impingement (FAI) with a 3D dGEMRIC technique.<sup>34</sup> After clinical diagnosis with conventional radiographs, two consecutive series of each 20 patients with DDH or FAI were assessed with 3D dGEMRIC. Radial  $T1_{Gd}$  maps were reconstructed and region of interest analysis of the central and peripheral cartilage was carried out. The dGEMRIC index was mean  $531 \pm 92.7$  (391-729) ms in DDH and  $551 \pm 95.7$  (372-694) ms in FAI, respectively ( $P=0.507$ ). Subgroup analysis showed higher  $T1_{Gd}$  in the weight-bearing areas and significantly higher values in the central areas (DDH  $P$ -value  $<0.0001$ ,  $n=11$ ; FAI  $P$ -value  $=0.036$ ,  $n=14$ ) of the acetabulum in pre-arthritis cases (dGEMRIC index  $>500$  ms) both in DDH and FAI. A breakdown of this distribution was noted both in DDH and FAI cases with an dGEMRIC index  $<500$  ms. Pearson correlation analysis demonstrated the dGEMRIC index had a poor predictive value for the anterior-superior quad-

rant of the hip joint in FAI ( $r=0.482$ ,  $P=0.031$ ,  $r^2=0.233$ ).

Polland *et al.* investigated the potential of dGEMRIC to detect cartilage disease in asymptomatic hips with cam deformities compared with morphologically normal hips to establish whether dGEMRIC could identify advanced dis-

ease in hips with positive clinical findings, and establish whether cartilage damage correlated with the severity of the cam deformity.<sup>35</sup> Subjects were recruited from a prospective study of individuals with a family history of osteoarthritis and their spouses who served as control subjects. dGEMRIC was performed on a

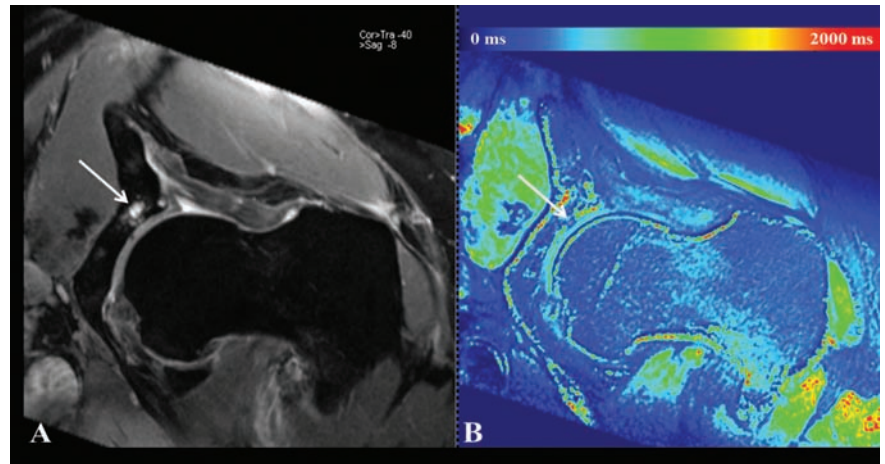


Figure 2. Morphological hip assessment (A) revealing cartilage grade 2 changes and cyst formation (arrow) at the superiolateral aspect of the hip joint. Corresponding  $T1_{Gd}$  map (B) clearly depicting severe acetabular  $T1_{Gd}$  decrease (arrow) pointing towards major GAG loss in the same area.

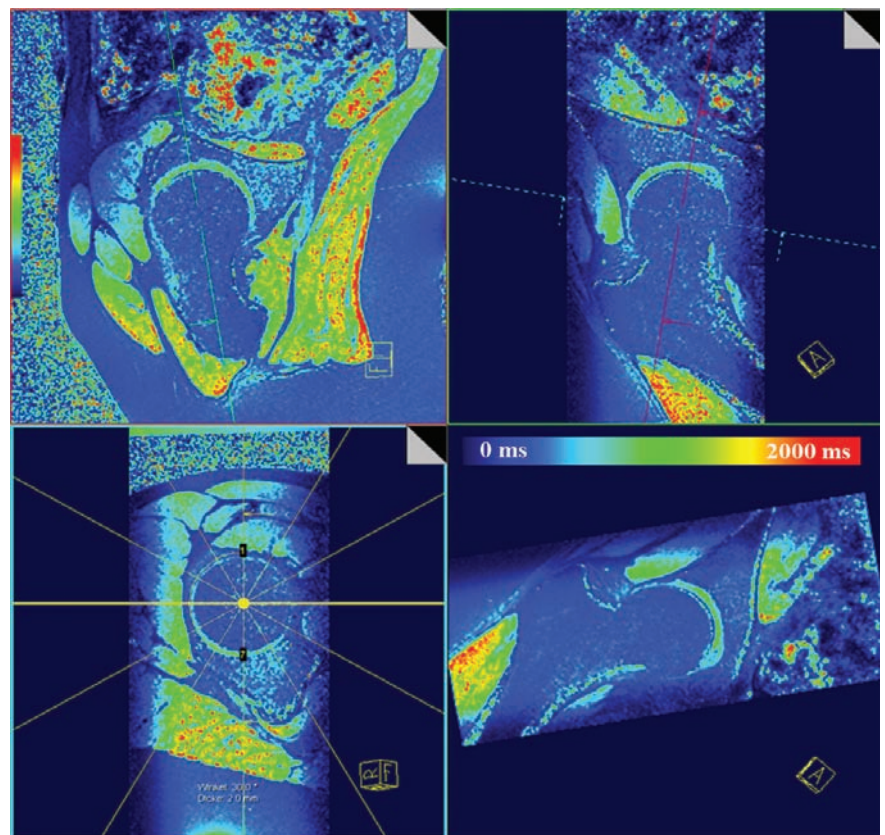


Figure 3. Reformating of radial  $T1_{Gd}$  planes for 3D dGEMRIC assessment. Note the homogenous  $T1_{Gd}$  signal in all planes in this asymptomatic normal adult hip joint with normal  $T1_{Gd}$  values displayed by the green cartilage coloring.

3T system, studying two regions of interest: the anterosuperior aspect of the acetabular cartilage ( $T1_{\text{acetabular}}$ ) and the total femoral and acetabular cartilage ( $T1_{\text{total}}$ ). The cohort was placed in subgroups by joint morphology, impingement test status, and genetic predisposition. The mean T1 scores were compared, and the alpha angle and T1 were correlated. Hips with a cam deformity had reduced acetabular glycosaminoglycan content compared with normal hips (mean  $T1_{\text{acetabular}}/T1_{\text{total}} = 0.949$  and  $1.093$ , respectively;  $P = 0.0008$ ). Hips with a positive impingement test result had global depletion of glycosaminoglycan compared with hips with a negative result (mean  $T1_{\text{total}} = 625$  ms versus  $710$  ms;  $P = 0.0152$ ).  $T1_{\text{acet}}$  inversely correlated with the magnitude of the alpha angle ( $r = -0.483$ ,  $P = 0.0038$ ), suggesting that the severity of cartilage damage correlates with the magnitude of the cam deformity.

Mamisch *et al.* compared the dGEMRIC indices in a group of six cam and seven pincer patients to a control group ( $n = 12$ ) of asymptomatic controls that had no plain MRI findings of osteoarthritis. The superior portion of the hip joint was divided into seven regions from 9 to 3 o'clock.<sup>36</sup> These regions were then subdivided into peripheral and central regions. The cam and pincer groups both had statistically lower dGEMRIC values compared to the control group. The cam group demonstrated not only peripheral but also central involvement of the joint and this was concentrated in the anterior portion of the joint. The pincer group exhibited more global hip involvement with all areas of the hip averaging a dGEMRIC index 28% less than controls. The authors concluded that the use of dGEMRIC can elicit more specific patterns of cartilage wear in patients with impingement, which may improve patient selection and help better understand the progression of osteoarthritis throughout the hip joint.

### dGEMRIC combined with MRA

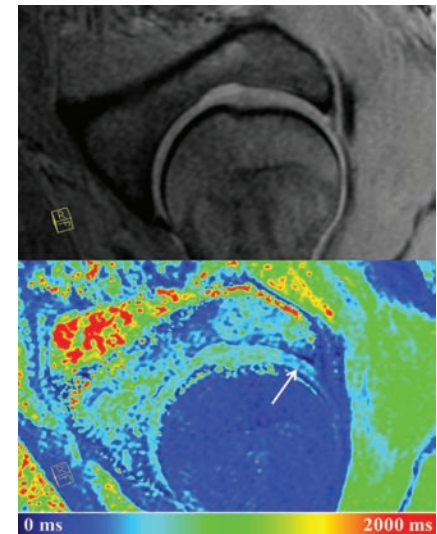
dGEMRIC works on the principle of decreased T1 relaxation time due to the infiltration of the anionic, negatively charged contrast Gd-DTPA<sup>2-</sup> into the cartilage in an inversely proportional manner to the negatively charged glycosaminoglycan (GAG) content ( $T1_{\text{Gd}}$ ). In contrast to the MRA technique, which includes the direct fluoroscopic-guided intra-articular Gd-DTPA<sup>2-</sup> injection, the intravenously syringed Gd-DTPA<sup>2-</sup> in dGEMRIC reaches the joint after systemic circulation in a lower amount providing only an indirect MR arthrogram of the hip joint and achieves less cartilage delineation and contrast-to-noise ratio (CNR).<sup>37</sup>

In a pilot study we investigated the feasibility

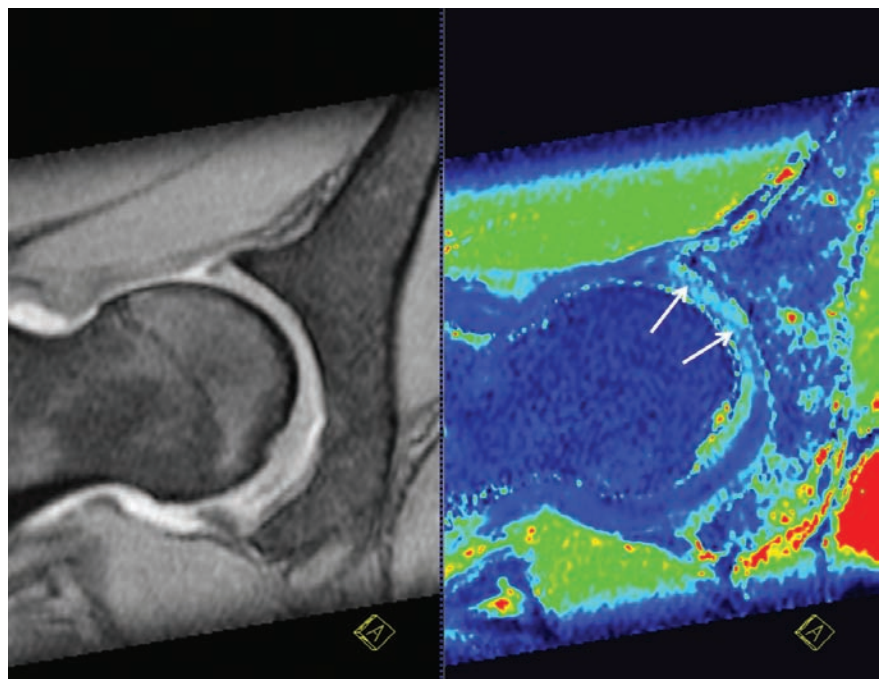
of cartilage assessment in symptomatic FAI patients using intra-articular delayed Gadolinium Enhanced MRI of Cartilage (ia-dGEMRIC) instead of intravenous gadolinium dGEMRIC (iv-dGEMRIC).<sup>38</sup> We hypothesized that a biochemically sensitive MRI technique complemented with the benefits of a direct arthrogram of the hip would provide better and more accurate information than an MR arthrogram alone. Based on a previous study we were aware that penetration of the cartilage differs with intravenous than intra-articular administration of Gadolinium. In this study, Bashir *et al.* measured the penetration of Gd-DTPA<sup>2-</sup> into the articular cartilage following both intra-articular and intravenous injection.<sup>7</sup> For intra-articular Gd-DTPA<sup>2-</sup> it took up to seven hours for penetration into 4 mm of articular cartilage. Otherwise, cartilage penetration of 4 mm was completed after 2.5 hours subsequent to intravenous of Gd-DTPA<sup>2-</sup> administration. However, this study was performed in knee joint cartilage of two healthy volunteers only. Recently, new data addressing the transport of Gd-DTPA<sup>2-</sup> over time into various depths of knee joint cartilage after iv- Gd-DTPA<sup>2-</sup> administration including subchondral T1 assessment and pre-contrast analyses was presented.<sup>39</sup> In this yet unpublished study the authors report an ongoing Gd-DTPA<sup>2-</sup> transport towards the deep cartilage zone and a wash-out after time at the superficial zone whereas T1 measurement within the subchondral region revealed no T1 variation over time leading to the conclusion that the amount of Gd-DTPA<sup>2-</sup> entering cartilage from the subchon-

dral bone is negligible.

To examine the contrast infiltration process into hip joint cartilage (via MR arthrogram) we initially assessed T1 at sequential time intervals in nine patients. Twenty seven patients were subsequently scanned with ia-dGEMRIC 45 minutes post Gd-DTPA<sup>2-</sup> injection. These  $T1_{\text{Gd}}$  findings were correlated to the morphological extent of cartilage damage. In this



**Figure 4.** Morphologic MR image and corresponding  $T1_{\text{Gd}}$  map clearly depicting  $T1_{\text{Gd}}$  changes with decreased  $T1_{\text{Gd}}$  values in the periphery of the anterior aspect of the hip.



**Figure 5.** MR arthrography and ia-dGEMRIC revealing severe  $T1_{\text{Gd}}$  changes with decreased  $T1_{\text{Gd}}$  values peripherally and centrally in the superior aspect of the hip.

study, we noted significant difference between the T1 values measured pre-contrast ( $T1_0$ ) and the T1 values measured 15 minutes post-contrast ( $T1_{Gd}$ ). The mean values then continued to remain almost constant until about 45 minutes following the intra-articular contrast injection. Thus,  $T1_{Gd}$  analysis as early as 15 minutes post Gd-DTPA<sup>2-</sup> injection may be possible. After 45 minutes post-injection, the  $T1_{Gd}$  values then increased suggesting washout of the contrast agent from the cartilage. Furthermore, there was a significant change in the  $T1_{Gd}$  values with varying extent of cartilage damage (none to  $\leq 0.75$  cm to  $> 0.75$  cm) depicting the ability of  $T1_{Gd}$  after intraarticular Gd-DTPA<sup>2-</sup> injection to pick up different severities in damage of cartilage in many regions (Figure 5). In a further study comparing  $T1_{Gd}$  mapping with both these techniques (iv and ia), the ia-dGEMRIC findings while assessing the cartilage status of symptomatic patients with FAI were similar to those from iv-dGEMRIC in a demographically comparable group of patients.<sup>40</sup> Mapping with both iv-dGEMRIC and ia-dGEMRIC demonstrated obvious differences between various grades of cartilage degeneration.

## Conclusions

With the increasing understanding of hip joint pathologies such as hip dysplasia and FAI, which may be clinically less symptomatic in the early stages but which can lead to early osteoarthritis of the hip in the follow-up if proper treatment is not provided in sufficient time, it is understandably critical for the treating clinician to be able to detect hip joint pathology not only in detail but also at an early stage to maximize the patient benefit. Aids to diagnosis include a detailed medical history and physical examination, radiographs and MR arthrography with radial scanning. Current advances in cartilage imaging continue to demonstrate an increasing interest in techniques that are sensitive to biochemical changes as this remains the final bridge of communication between pre-operative analysis and intra-operative assessment, information that is key and critical in decision making as well as prognostication of joint outcomes. Several techniques have been in various stages of development in recent years that have attempted biochemical evaluation of both healthy and damaged cartilage. dGEMRIC has been proven accurate and reliable for hip joint assessment. Developments in the dGEMRIC techniques such as 3D dGEMRIC and ia-dGEMRIC imaging further underlines the potential of this technique that may become a standard for hip joint analysis in the daily clinical setup.

## References

- Pfrrmann CW, Mengiardi B, Dora C, et al. Cam and pincer femoroacetabular impingement: characteristic MR arthrographic findings in 50 patients. *Radiology* 2006;240:778-85.
- Mamisch TC, Zilkens C, Siebenrock KA, et al. MRI of hip osteoarthritis and implications for surgery. *Magn Reson Imaging Clin N Am* 2010;18:111-20.
- Locher S, Werlen S, Leunig M, Ganz R. [MR-Arthrography with radial sequences for visualization of early hip pathology not visible on plain radiographs]. *Z Orthop Ihre Grenzgeb* 2002;140:52-7.
- Petersilge CA. MR arthrography for evaluation of the acetabular labrum. *Skeletal Radiol* 2001;30:423-30.
- Knuesel PR, Pfrrmann CW, Noetzi HP, et al. MR arthrography of the hip: diagnostic performance of a dedicated water-excitation 3D double-echo steady-state sequence to detect cartilage lesions. *AJR Am J Roentgenol* 2004;183:1729-35.
- Schmid MR, Notzli HP, Zanetti M, et al. Cartilage lesions in the hip: diagnostic effectiveness of MR arthrography. *Radiology* 2003;226:382-6.
- Bashir A, Gray ML, Boutin RD, Burstein D. Glycosaminoglycan in articular cartilage: in vivo assessment with delayed Gd(DTPA)(2-)-enhanced MR imaging. *Radiology* 1997;205:551-8.
- Kim YJ, Jaramillo D, Millis MB, et al. Assessment of early osteoarthritis in hip dysplasia with delayed gadolinium-enhanced magnetic resonance imaging of cartilage. *J Bone Joint Surg Am* 2003;85-A:1987-92.
- Tiderius CJ, Olsson LE, Leander P, et al. Delayed gadolinium-enhanced MRI of cartilage (dGEMRIC) in early knee osteoarthritis. *Magn Reson Med* 2003;49:488-92.
- Bashir A, Gray ML, Burstein D. Gd-DTPA<sup>2-</sup> as a measure of cartilage degradation. *Magn Reson Med* 1996;36:665-73.
- Burstein D, Velyvis J, Scott KT, et al. Protocol issues for delayed Gd(DTPA)(2-)-enhanced MRI (dGEMRIC) for clinical evaluation of articular cartilage. *Magn Reson Med* 2001;45:36-41.
- Cunningham T, Jessel R, Zurakowski D, et al. Delayed gadolinium-enhanced magnetic resonance imaging of cartilage to predict early failure of Bernese periacetabular osteotomy for hip dysplasia. *J Bone Joint Surg Am* 2006;88:1540-8.
- Mlynarik V, Trattnig S, Huber M, et al. The role of relaxation times in monitoring proteoglycan depletion in articular cartilage. *J Magn Reson Imaging* 1999;10:497-502.
- Tiderius CJ, Olsson LE, de Verdier H, et al. Gd-DTPA<sup>2-</sup>-enhanced MRI of femoral knee cartilage: a dose-response study in healthy volunteers. *Magn Reson Med* 2001;46:1067-71.
- Williams A, Sharma L, McKenzie CA, et al. Delayed gadolinium-enhanced magnetic resonance imaging of cartilage in knee osteoarthritis: findings at different radiographic stages of disease and relationship to malalignment. *Arthritis Rheum* 2005;52:3528-35.
- Woertler K, Buerger H, Moeller J, Rummeny EJ. Patellar articular cartilage lesions: in vitro MR imaging evaluation after placement in gadopentetate dimeglumine solution. *Radiology* 2004;230:768-73.
- Maroudas A, Venn M. Chemical composition and swelling of normal and osteoarthrotic femoral head cartilage. II. Swelling. *Ann Rheum Dis* 1977;36:399-406.
- Venn M, Maroudas A. Chemical composition and swelling of normal and osteoarthrotic femoral head cartilage. I. Chemical composition. *Ann Rheum Dis* 1977;36:121-9.
- Watanabe A, Wada Y, Obata T, et al. Delayed gadolinium-enhanced MR to determine glycosaminoglycan concentration in reparative cartilage after autologous chondrocyte implantation: preliminary results. *Radiology* 2006;239:201-8.
- Bashir A, Gray ML, Hartke J, Burstein D. Nondestructive imaging of human cartilage glycosaminoglycan concentration by MRI. *Magn Reson Med* 1999;41:857-65.
- Li W, Du H, Scheidegger R, Wu Y, Prasad PV. Value of precontrast T(1) for dGEMRIC of native articular cartilage. *J Magn Reson Imaging* 2009;29:494-7.
- Williams A, Mikulis B, Krishnan N, et al. Suitability of T(1Gd) as the dGEMRIC index at 1.5T and 3.0T. *Magn Reson Med* 2007;58:830-4.
- Bittersohl B, Hosalkar HS, Kim YJ, et al. Delayed gadolinium-enhanced magnetic resonance imaging (dGEMRIC) of hip joint cartilage in femoroacetabular impingement (FAI): Are pre- and postcontrast imaging both necessary? *Magn Reson Med* 2009;62:1362-7.
- Trattnig S, Marlovits S, Gebetsroither S, et al. Three-dimensional delayed gadolinium-enhanced MRI of cartilage (dGEMRIC) for in vivo evaluation of reparative cartilage after matrix-associated autologous chondrocyte transplantation at 3.0T: Preliminary results. *J Magn Reson Imaging* 2007;26:974-82.
- Tiderius CJ, Jessel R, Kim YJ, Burstein D. Hip dGEMRIC in asymptomatic volunteers and patients with early osteoarthritis: the influence of timing after contrast injection. *Magn Reson Med* 2007;57:803-5.

26. Jessel RH, Zilkens C, Tiderius C, et al. Assessment of osteoarthritis in hips with femoroacetabular impingement using delayed gadolinium enhanced MRI of cartilage. *J Magn Reson Imaging* 2009;30:1110-5.
27. Beck M, Leunig M, Parvizi J, et al. Anterior femoroacetabular impingement: part II. Midterm results of surgical treatment. *Clin Orthop Relat Res* 2004;67-73.
28. Murphy S, Tannast M, Kim YJ, et al. Debridement of the adult hip for femoroacetabular impingement: indications and preliminary clinical results. *Clin Orthop Relat Res* 2004;178-81.
29. Lattanzi R, Glaser C, Mikheev AV, et al. A B(1) -insensitive high resolution 2D T(1) mapping pulse sequence for dGEMRIC of the HIP at 3 Tesla. *Magn Reson Med* 2011;66:348-55.
30. Mamisch TC, Dudda M, Hughes T, et al. Comparison of delayed gadolinium enhanced MRI of cartilage (dGEMRIC) using inversion recovery and fast T1 mapping sequences. *Magn Reson Med* 2008;60:768-73.
31. Bittersohl B, Hosalkar HS, Haamberg T, et al. Reproducibility of dGEMRIC in assessment of hip joint cartilage: a prospective study. *J Magn Reson Imaging* 2009;30:224-8.
32. Bittersohl B, Steppacher S, Haamberg T, et al. Cartilage damage in femoroacetabular impingement (FAI): preliminary results on comparison of standard diagnostic vs delayed gadolinium-enhanced magnetic resonance imaging of cartilage (dGEMRIC). *Osteoarthritis Cartilage* 2009;17:1297-306.
33. Bittersohl B, Hosalkar HS, Werlen S, et al. dGEMRIC and subsequent T1 mapping of the hip at 1.5 Tesla: Normative data on zonal and radial distribution in asymptomatic volunteers. *J Magn Reson Imaging* 2011;34:101-6.
34. Domayer SE, Mamisch TC, Kress I, et al. Radial dGEMRIC in developmental dysplasia of the hip and in femoroacetabular impingement: preliminary results. *Osteoarthritis Cartilage* 2010;18:1421-8.
35. Pollard TC, McNally EG, Wilson DC, et al. Localized cartilage assessment with three-dimensional dGEMRIC in asymptomatic hips with normal morphology and cam deformity. *J Bone Joint Surg Am* 2010;92:2557-69.
36. Mamisch TC, Kain MS, Bittersohl B, et al. Delayed gadolinium-enhanced magnetic resonance imaging of cartilage (dGEMRIC) in Femoacetabular impingement. *J Orthop Res* 2011;29:1305-11.
37. Boesen M, Jensen KE, Qvistgaard E, et al. Delayed gadolinium-enhanced magnetic resonance imaging (dGEMRIC) of hip joint cartilage: better cartilage delineation after intra-articular than intravenous gadolinium injection. *Acta Radiol* 2006;47:391-6.
38. Bittersohl B, Hosalkar HS, Kim YJ, et al. T1 assessment of hip joint cartilage following intra-articular gadolinium injection: a pilot study. *Magn Reson Med* 2010;64:1200-7.
39. Hawezi Z, Tiderius CJ, Svensson J, et al. Temporal Dynamics of Gd-Enhanced T1 Relaxation Time in Deep and Superficial Femoral Articular Cartilage. In: *Proceedings of the International Society for Magnetic Resonance in Medicine* 2009; 2009.
40. Bittersohl B, Hosalkar HS, Werlen S, et al. Intravenous versus intra-articular delayed gadolinium-enhanced magnetic resonance imaging in the hip joint: a comparative analysis. *Invest Radiol* 2010;45:538-42.