

A posteriori registration and subtraction of periapical radiographs for the evaluation of external apical root resorption after orthodontic treatment

Eliane Maria Kreich^{1,*}, Ana Cláudia Chibinski², Ulisses Coelho³, Letícia Stadler Wambier²,
Rosário de Arruda Moura Zedebski¹, Mari Eli Leonelli de Moraes⁴, Luiz Cesar de Moraes⁴

¹Department of Dental Radiology, School of Dentistry, Ponta Grossa State University, Ponta Grossa, Paraná, Brazil

²Department of Pediatric Dentistry, School of Dentistry, Ponta Grossa State University, Ponta Grossa, Paraná, Brazil

³Department of Orthodontics, School of Dentistry, Ponta Grossa State University, Ponta Grossa, Paraná, Brazil

⁴Department of Dental Radiology, School of Dentistry, State University of São Paulo, São José dos Campos, São Paulo, Brazil

ABSTRACT

Purposes: This study employed a posteriori registration and subtraction of radiographic images to quantify the apical root resorption in maxillary permanent central incisors after orthodontic treatment, and assessed whether the external apical root resorption (EARR) was related to a range of parameters involved in the treatment.

Materials and Methods: A sample of 79 patients (mean age, 13.5 ± 2.2 years) with no history of trauma or endodontic treatment of the maxillary permanent central incisors was selected. Periapical radiographs taken before and after orthodontic treatment were digitized and imported to the Regeemy software. Based on an analysis of the post-treatment radiographs, the length of the incisors was measured using Image J software. The mean EARR was described in pixels and relative root resorption (%). The patient's age and gender, tooth extraction, use of elastics, and treatment duration were evaluated to identify possible correlations with EARR.

Results: The mean EARR observed was 15.44 ± 12.1 pixels (5.1% resorption). No differences in the mean EARR were observed according to patient characteristics (gender, age) or treatment parameters (use of elastics, treatment duration). The only parameter that influenced the mean EARR of a patient was the need for tooth extraction.

Conclusion: A posteriori registration and subtraction of periapical radiographs was a suitable method to quantify EARR after orthodontic treatment, and the need for tooth extraction increased the extent of root resorption after orthodontic treatment. (*Imaging Sci Dent 2016; 46: 17-24*)

KEY WORDS: Root Resorption; Orthodontics; Subtraction Technique; Image Processing, Computer-Assisted; Tooth Extraction

Introduction

The interaction between orthodontic forces and the periodontal ligament leads to an inflammatory phenomenon that induces apical resorption by elastic activity¹ without clinical symptoms. This phenomenon is known as external apical root resorption (EARR), and it is an undesirable² and irreversible side effect of orthodontic treatment.

The reported occurrence of EARR is between 48% and

66% according to radiographic studies and more than 90% based on histologic analyses.^{3,4} Fortunately, most cases exhibit resorption of no greater than 1 mm, which does not impair tooth function. However, higher degrees of root shortening are observed in approximately 8% of patients one year after orthodontic treatment.⁵

Several factors are associated with EARR, including increased treatment duration, direction of tooth movement, the loading regimen,² tooth extraction,¹ the type of the tooth and the malocclusion, and patient-related factors including certain systemic conditions, age, and gender.⁴

The early detection of initial resorptive lesions during orthodontic treatment is essential for identifying teeth at risk of severe resorption.⁶⁻⁸ The subsequent interruption

Received October 1, 2015; Revised November 4, 2015; Accepted November 22, 2015

*Correspondence to : Prof. Eliane Maria Kreich

Department of Dental Radiology, School of Dentistry, Ponta Grossa State University, General Carlos Cavalcanti Avenue, #4748, CEP 84030-900, Ponta Grossa, Paraná, Brazil

Tel) 55-42-99171983, Fax) 55-42-32203102, E-mail) elianekreich@gmail.com

Copyright © 2016 by Korean Academy of Oral and Maxillofacial Radiology

This is an Open Access article distributed under the terms of the Creative Commons Attribution Non-Commercial License (<http://creativecommons.org/licenses/by-nc/3.0>) which permits unrestricted non-commercial use, distribution, and reproduction in any medium, provided the original work is properly cited.

Imaging Science in Dentistry · pISSN 2233-7822 eISSN 2233-7830

of active treatment can help to reduce adverse outcomes during later stages of treatment,⁷ as well as avoiding or limiting the potential damage to the patient.⁹

The tools most commonly used to detect EARR are periapical^{1,8} and panoramic radiographs.¹⁰ This is probably due to the frequent use of these exams during the stages of orthodontic treatment^{11,12} and the good cost-benefit outcomes for the patient. Nevertheless, the visual comparison of radiographs before and after orthodontic treatment to measure the EARR is subject to discrepancies in clinical practice, and this technique is not able to detect minor changes in sequential images.^{13,14}

Moreover, both radiographic techniques have limitations. Panoramic radiographs show a substantial amount of magnification and do not allow the clear visualization of the premaxilla.¹¹ Although they exhibit much less distortion,¹¹ periapical radiographs require a certain degree of root shortening to have taken place before it is detectable visually on the radiograph.^{12,14}

In order to overcome these problems, cone-beam computed tomography has been suggested as an alternative to periapical and panoramic radiographs. The scientific literature indicates that this technique is suitable for the detection of early EARR.^{1,12} However, this exam makes orthodontic treatment more expensive and subjects the patient to an additional dose of radiation.

As an alternative, this paper proposes a posteriori registration and subtraction of radiographic images and the use of computerized techniques to quantify the EARR using periapical radiographs. The procedure of a posteriori registration and subtraction corrects the discrepancies of the geometric projection and equalizes the density and the contrast of the radiographic images before and after treatment, enabling the comparison of the two radiographs and improving the sensitivity and the accuracy of the evaluation, which is performed using specific software.

Although this method has been extensively tested in vitro in extracted teeth with simulated resorption,^{5,7,15-19} the use of periapical radiographs from actual orthodontic treatments,^{6,20} as proposed in this paper, is not a common feature of the dental literature on digital subtraction (DSR) radiography and EARR.

The null hypotheses tested were that a posteriori registration and subtraction of periapical radiographic images cannot be used to quantify the EARR following orthodontic treatment and that patient-related factors (gender and age) and treatment-related factors (tooth extraction, use of intermaxillary elastics, and duration of orthodontic treatment) do not affect the amount of root resorption.

Therefore, the objective of this retrospective study was to evaluate whether a posteriori registration and subtraction of radiographic images could be used to quantify apical root resorption in maxillary permanent central incisors after orthodontic treatment, as well as to determine whether the EARR was related to the parameters involved in the treatment.

Materials and Methods

This study was approved by the Ethical Committee of São Paulo State University (Campus of São José dos Campos) under protocol #041/2009.

Sample selection

A careful analysis of 300 orthodontic clinical records from patients treated by dentists who attended a postgraduate dental education program in orthodontics was performed. The inclusion criteria were: orthodontic treatment with the standard edgewise technique; no history of trauma, wear, or endodontic treatment in the maxillary central incisors; complete radiographic exams, including baseline and final periapical radiographs of the maxillary central incisors and cephalometric analysis; the absence of syndromic or skeletal disorders; and complete root formation in the maxillary central incisors. After this screening, 79 patients were selected. The sample number was above the calculated required sample size ($n = 64$; $\alpha = 0.5$; $1 - \beta = 0.9$), but all the selected patients were kept in the sample to compensate for possible losses during the study.

Radiographic analysis: sequence of procedures

Periapical radiographs were taken using the modified parallel technique and standardized exposure parameters: Heliudent 70 (Siemens, Erlangen, Germany) X-ray unit, 70 kVp, 7 mA, 0.4 seconds. The radiographs were digitalized using a scanner with transparency adapter (HP Scanjet G4050, Hewlett-Packard, Palo Alto, CA, USA) with a resolution of 300 dpi and 8-bit gray scale. The images were stored as maximum-quality TIFF format files.

All the images were imported into the Regeemy Image Registration and Mosaicking 0.2.43-RCB software (DPI-INPE, São José dos Campos, São Paulo, Brazil). This software provides image registration and subtraction algorithms (i.e., it corrects geometric discrepancies, equalizes the contrast of two sequential radiographs to make them comparable, and subtracts the analog pixels values from two sequential images).

The radiographic image obtained at baseline (before or-

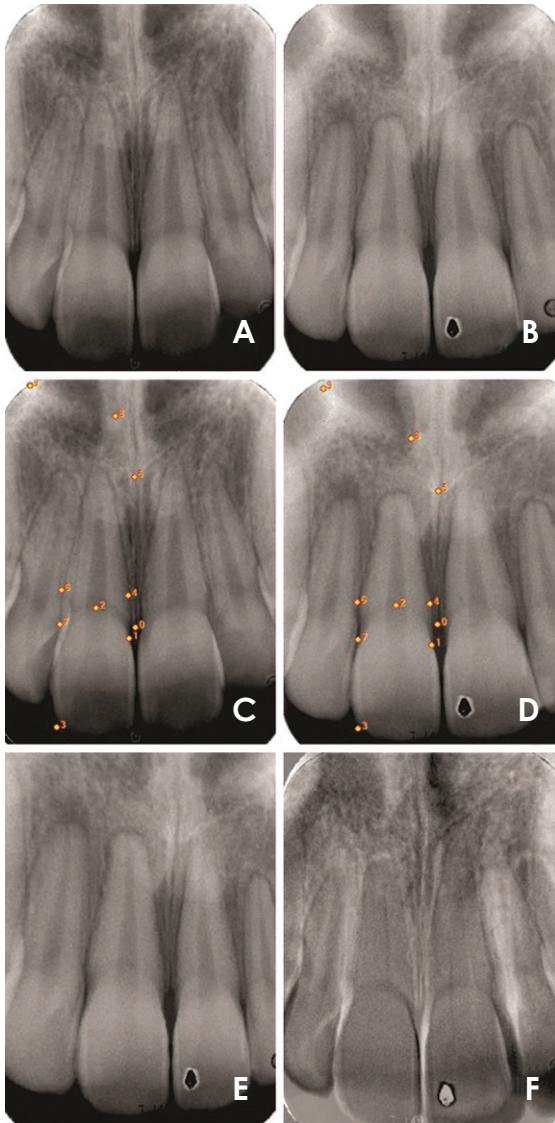


Fig. 1. Illustrative images of the post-processing procedures of periapical radiographs for the right maxillary central incisor. Periapical radiographs at baseline (A, Image 1) and after orthodontic treatment (B, Image 2) were digitalized. The same reference points are tagged in the pre-treatment (C) and post-treatment (D) radiographs to align the images and to generate the posteriori registration of Image 3 (E). The quality of the registered image (E) is confirmed by the fact that the subtracted image (F) exhibited the least possible structural noise.

thodontic treatment) was termed Image 1 and used as the reference image. The radiographic image obtained after orthodontic treatment was referred to as Image 2.

Reference points (fixed points in both radiographs) were selected on both images manually (Fig. 1). These reference points served as coordinates for the software to align and correct the geometry of the second image according to the reference image (Image 1). Clearly distinguishable

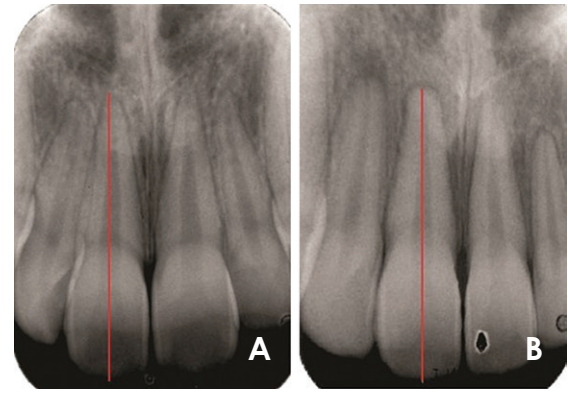


Fig. 2. External apical root resorption is evaluated by the measurement of the long axis of the maxillary central incisors at baseline (A, Image 1) and in the registered image (B, Image 3).

structures were selected as reference points, such as the cement-enamel junction and the incisal margin of the maxillary central incisors.

This process generated Image 3, which was the retrospectively corrected form of Image 2. The quality of the image correction was visually determined using the image subtraction routine (Image 1-Image 3). The image registration was considered adequate when the structural noise on the teeth of interest was reduced to the lowest possible level, as indicated by a minimal or nonexistent discrepancy in the geometrical position between images, which appears as brighter or darker shades of gray in the subtracted radiograph.

Therefore, the corrected image (Image 3) became the new follow-up radiographic image, since small differences in projection angles during exposure or contrast/density during processing were corrected (Fig. 1).

The evaluation of EARR was performed using Image 1 (baseline) and Image 3 (the corrected image) (Fig. 2). The measurement of the long axis of the central maxillary incisors was done using the UTHSCSA Image Tool (University of Texas Health Science Center at San Antonio; <http://compdent.uthscsa.edu/dig/itdesc.html>). The length of the tooth was considered to be the distance between the root apex and the incisal edge at a specific point corresponding to the mean distance between the mesial and distal angles. The above-described protocol was carried out separately for the right and left maxillary central incisors.

The complete procedures of a posteriori registration and subtraction and DSR were completed by one experienced investigator trained in this methodology. The measurement of the length of the tooth was repeated three times and the

Table 1. Mean values of the length of the upper central incisors, angle formed by the maxillary incisor long axis and the nasion line (1.NA), and linear distance between the most anterior point of the maxillary central incisor and the NA line (1-NA) before and after orthodontic treatment

	Length (pixels)	1.NA(°)	1-NA(mm)
Pre-orthodontic treatment	302.7 ± 30.2	23.6 ± 7.0	5.8 ± 2.4
Post-orthodontic treatment	287.2 ± 31.6	22.2 ± 6.3	5.0 ± 2.2
Difference	15.4 ± 12.1 (5.1%)	1.4 ± 8.7 (6.0%)	0.9 ± 4.0 (15.0%)
P-value by paired t-test	p < 0.001	p = 0.152	p = 0.0207

final result consisted of the mean of the three evaluations. Intraexaminer agreement was calculated using Cohen’s kappa ($k = 0.87$).

The EARR in the central maxillary incisors was determined by the difference between baseline (Image 1) and post-treatment (Image 3) tooth lengths. These values were obtained in pixels. The difference between the values before and after treatment (mean EARR) was obtained and described in terms of pixels and relative root resorption (%).

Evaluation parameters

In order to identify possible correlations with factors that are commonly associated with EARR, data regarding patient characteristics such as gender and age were collected from the clinical records. The features involved in the orthodontic treatment that were considered for analysis were the need for maxillary first bicuspid extraction, the use of elastics, and the treatment duration. The measures 1.NA (angle formed by the maxillary incisor long axis and the nasion line) and 1-NA (linear distance between the most anterior point of the maxillary central incisor and the NA line) were also obtained, since these are part of the cephalometric analysis that determines the dental pattern of the maxillary incisors.

Statistical analysis

The obtained data showed a normal distribution (Shapiro-Wilk). Therefore, the comparisons between mean tooth length, 1.NA, and 1-NA before and after orthodontic treatment were made using the paired t-test. The Student’s t-test was used to compare the parameters of gender, age, tooth extraction, elastics use, and treatment duration. The statistical analysis was conducted using SigmaPlot 12.0 (Systat Software Inc, San Jose, CA, USA), with the significance level set at $p = 5\%$.

Results

The final sample was composed of 79 patients (mean

age, 13.5 ± 2.2 years; range, 10-19 years; 22 males and 57 females). The mean duration of the treatment was 25.8 ± 6.2 months (range, 10-38 months).

The tooth length before and after orthodontic treatment was 302.9 ± 30.3 pixels and 287.2 ± 32.3 pixels for the right maxillary central incisors; and 302.4 ± 30.2 pixels and 287.2 ± 31.1 pixels for the left maxillary central incisors. No significant differences were observed when the right and left central incisors were compared ($p > 0.05$), and all subsequent analyses were therefore made using the mean of the measurements of the left and right incisors. The mean EARR observed was 15.4 ± 12.1 pixels, representing a resorption of 5.1% (Table 1).

The mean length of the maxillary central incisors, as well as the mean values of the cephalometric measures 1.NA and 1-NA before and after orthodontic treatment are shown on Table 1. These parameters exhibited significant decreases after treatment.

No differences in the mean EARR were observed according to gender, age, the use of elastics, or treatment duration. The only parameter that influenced the patient’s mean EARR was the need for tooth extraction as part of orthodontic treatment (Table 2).

Discussion

The data obtained in this study allowed to reject the first hypothesis tested, since a posteriori registration and subtraction of periapical radiographic images performed using specific software was able to quantify the EARR after orthodontic treatment. The second hypothesis was partially rejected, because the parameter of tooth extraction influenced the extent of root resorption.

In our sample, all the patients exhibited EARR to some degree. This finding was expected and has been widely documented in the literature.^{1,2,4,6,9,12,17,21-24} The most commonly affected teeth are the maxillary incisors,^{3,25-27} which is why this paper evaluated resorption in this specific type of tooth.

Table 2. Mean values of external apical root resorption (EARR) and relative root resorption after orthodontic treatment according to different parameters.

	Mean EARR (pixels)	Relative root resorption (%)	P-value (Student's t-test)
Gender			
Male (n = 22; 27.9%)	17.5 ± 10.4	5.4%	p = 0.14
Female (n = 57; 72.2%)	14.6 ± 10.8	5.0%	
Age (years)			
10 to 12 (n = 32; 40.5%)	13.9 ± 8.8	4.7%	p = 0.16
> 12 (n = 47; 59.5%)	16.5 ± 11.8	5.4%	
Tooth extraction			
Yes (n = 37; 46.8%)	19.0 ± 13.3	5.1%	p = 0.003
No (n = 42; 53.2%)	12.3 ± 6.5	4.3%	
Usage of elastics			
Yes (n = 60; 76.0%)	15.2 ± 10.7	5.2%	p = 0.35
No (n = 19; 24.1%)	16.3 ± 11.0	5.3%	
Treatment duration			
12 to 24 months (n = 43; 54.4%)	14.7 ± 10.8	5.0%	p = 0.23
25 months or more (n = 63; 79.8%)	16.4 ± 10.6	5.3%	

Most previous studies investigating EARR used the Malmgren scale to evaluate EARR.^{9,12,28,29} The scale consists of four scores, varying from no resorption to resorption beyond the apical third of the tooth. It is considered a subjective method, and the analysis of two radiographs taken at a temporal interval may introduce some bias, reflecting the instruction, training, and experience of the examiner.^{5,13} Additionally, the diagnosis of root resorption by the comparison of periapical radiographs is only possible after five to six months.⁵

The use of a posteriori registration and subtraction overcame these drawbacks. The accuracy of the DSR method has been confirmed by *in vitro* studies using extracted tooth.^{5,7,8,16} A posteriori registration and subtraction of periapical radiographic images, the accuracy of which was checked with DSR, has been proven to be a method that can quantify small changes associated with EARR *in vivo*; in our study, it was possible to diagnose early root loss (as reflected by changes as small as 0.6 pixels), and our technique corrected for possible changes in tooth position resulting from orthodontic treatment.²⁶ In daily practice, this process can be performed easily. However, the standardization of the follow-up periapical radiographs should be further developed, since the accuracy of a posteriori registration may have been higher if the vertical and horizontal angulations did not show variations greater than 20° and 10°, respectively.⁵

Our results showed that the length of the maxillary incisors diminished by a mean of 15.4 ± 12.1 pixels or by approximately 5.1%. These values were measured in pixels and as relative root resorption (%) because these

measurement units overcome the inherent variation of the direct measurement of root length,³⁰ and this is probably the best way to standardize the results, allowing the fairest comparisons between different papers that evaluate EARR in a quantitative manner.

Higher mean values have been reported when panoramic radiographs were evaluated (19.5 ± 12.6 pixels),²⁶ as well as periapical radiographs (mean EARR percentage of 9.77% after 12 months of orthodontic treatment).³¹ This may be expected, since the evaluation of EARR using panoramic radiographs tends to overestimate the amount of tooth loss by 20% or more when compared to periapical radiography,^{11,12} and the evaluation using periapical radiographs without geometric correction may induce shortening or lengthening of the image, thereby interfering with the diagnosis.⁸

Orthodontic treatment produces an apical displacement of the maxillary incisors. It is highly correlated with apical root resorption³² and with consequent changes in the values of 1.NA and 1-NA. In our study, both cephalometric measures decreased after orthodontic treatment, which means that the maxillary central incisors experienced inclination and overall movement in the lingual direction. Significant changes were observed in the 1-NA measures, and a reduction of 15% was noted in the protrusion of the maxillary central incisors after orthodontic treatment; therefore, the final 1-NA mean value was closer to the reference value of 4 mm.

The other treatment-related factor evaluated was the need for tooth extraction, which was the only factor that showed a significant association with the prevalence of

EARR. Patients who underwent extractions showed a level of relative root resorption that was 1% higher than observed in the patients who were treated without extractions. This pattern has also been observed by several other studies.^{1,9,23,25,27,30,31} When tooth extraction is required, the maxillary incisors move greater distances than any other tooth,^{27,32} with substantial apical displacement.^{28,31} Therefore, the amount of movement is a risk factor for apical resorption of the maxillary incisors.^{9,20}

The need for tooth extraction and the necessity of greater tooth movement have frequently been associated with longer treatment duration.^{9,25} Some authors have associated root resorption with tooth extraction and the duration of the treatment,^{9,25,29-31} while others have found no such correlation.³³⁻³⁵ A systematic review reported that “it is unclear in the literature whether treatment duration is related to root resorption.”³

It must be considered that confounding variables, such as appointment intervals or the lack of patient cooperation, may increase the treatment duration⁹ without involving long periods of active forces to the teeth.³² This consideration is the most likely explanation of the conflicting results in the literature.

In our study, the mean duration of the treatment was 25.8 ± 6.2 months and it showed no relation with EARR. Severe EARR has been reported after longer treatment durations (seven years)⁹ and in a sample that included adult patients.²⁹ These differences must be taken into account when comparing our results with those previously reported in the literature.

The use of elastics has been associated with severe root resorption when used for more than six months.³⁶ Otherwise, reports have indicated that the use of elastics had no significant effect on root resorption.^{35,37} The same results were obtained in our study. The use of elastics for treatment finishing is common. This practice is patient-dependent and can influence the treatment duration, which may partially explain the conflicting results in the literature.

The severity of root resorption cannot be fully explained only by treatment-related factors.²⁹ Therefore, the possible association of gender and age with resorption was evaluated. These factors were selected because they are considered potential co-factors of EARR, and clinical trials match samples by these parameters in order to minimize bias.^{28-30,38} Nonetheless, in our study, EARR was not influenced by gender or age.

Although a recent paper showed a trend for female patients to exhibit 3% less resorption than male patients,³⁰ other reports have found that male patients have a higher

rate of EARR,³⁵ but most studies have reported that gender had no influence at all on EARR.^{6,9,25,26,38-40}

Regarding to the age criterion, it is often stated that adults experience more root resorption than teenagers undergoing orthodontic treatment.^{3,39} This may be related to the creation of more hyalinized areas, longer hyalinization duration, and slower healing patterns in adults.^{31,35} Contrastingly, a systematic review has affirmed that chronological age is not a primary indicator of root resorption,³ but the degree of root formation may be.^{3,9,41}

In our study, the patients' age varied between 10 and 19 years. Since complete root formation was an inclusion criterion for our sample, all patients had completed root formation. Our upper limit confined the sample to teenage patients. Therefore, the absence of a statistically significant age difference in our sample was expected and agrees with the observations of maxillary incisors made by other researchers.^{25,26,39,42} Nonetheless, it is important to point out that the criteria of gender and age may not be reliable predictors of root shortening after orthodontic treatment.

The multifactorial etiology of EARR complicates the establishment of a definitive relation with the several factors that cause resorption. This is also related to the heterogeneity of the study designs. The methodologies used to measure EARR are not standardized, and variations are present in the radiographic images used for analysis. In this regard, our study made the contribution of proposing a methodology that reduces subjectivity when evaluating root resorption and facilitates early diagnosis. Regardless, further research on this topic is needed, especially controlled clinical trials with longer follow-up periods.

It may be concluded that a posteriori registration and subtraction of periapical radiographs is a suitable method for quantifying EARR after orthodontic treatment, and that the need for tooth extraction increased the extent of root resorption after orthodontic treatment.

References

1. de Freitas JC, Lyra OC, de Alencar AH, Estrela C. Long-term evaluation of apical root resorption after orthodontic treatment using periapical radiography and cone beam computed tomography. *Dental Press J Orthod* 2013; 18: 104-12.
2. Roscoe MG, Meira JB, Cattaneo PM. Association of orthodontic force system and root resorption: a systematic review. *Am J Orthod Dentofacial Orthop* 2015; 147: 610-26.
3. Tieu LD, Saltaji H, Normando D, Flores-Mir C. Radiologically determined orthodontically induced external apical root resorption in incisors after non-surgical orthodontic treatment

- of class II division 1 malocclusion: a systematic review. *Prog Orthod* 2014; 15: 48.
4. Weltman B, Vig KW, Fields HW, Shanker S, Kaizar EE. Root resorption associated with orthodontic tooth movement: a systematic review. *Am J Orthod Dentofacial Orthop* 2010; 137: 462-76.
 5. Ono E, Medici Filho E, Faig Leite H, Tanaka JL, De Moraes ME, De Melo Castilho JC. Evaluation of simulated external root resorptions with digital radiography and digital subtraction radiography. *Am J Orthod Dentofacial Orthop* 2011; 139: 324-33.
 6. Sunku R, Roopesh R, Kancherla P, Perumalla KK, Yudhista PV, Reddy VS. Quantitative digital subtraction radiography in the assessment of external apical root resorption induced by orthodontic therapy: a retrospective study. *J Contemp Dent Pract* 2011; 12: 422-8.
 7. Eraso FE, Parks ET, Roberts WE, Hohlt WF, Ofner S. Density value means in the evaluation of external apical root resorption: an in vitro study for early detection in orthodontic case simulations. *Dentomaxillofac Radiol* 2007; 36: 130-7.
 8. Gegler A, Fontanella V. In vitro evaluation of a method for obtaining periapical radiographs for diagnosis of external apical root resorption. *Eur J Orthod* 2008; 30: 315-9.
 9. Maués CP, do Nascimento RR, Vilella Ode V. Severe root resorption resulting from orthodontic treatment: prevalence and risk factors. *Dental Press J Orthod* 2015; 20: 52-8.
 10. Mahida K, Agrawal C, Baswaraj H, Tandur AP, Patel B, Chokshi H. Root resorption: an abnormal consequence of the orthodontic treatment. *Int J Contemp Dent* 2015; 6: 7-9.
 11. Sameshima GT, Asgarifar KO. Assessment of root resorption and root shape: periapical vs panoramic films. *Angle Orthod* 2001; 71: 185-9.
 12. Dudic A, Giannopoulou C, Leuzinger M, Kiliaridis S. Detection of apical root resorption after orthodontic treatment by using panoramic radiography and cone-beam computed tomography of super-high resolution. *Am J Orthod Dentofacial Orthop* 2009; 135: 434-7.
 13. Chibinski AC, Reis A, Kreich EM, Tanaka JL, Wambier DS. Evaluation of primary carious dentin after cavity sealing in deep lesions: a 10- to 13-month follow-up. *Pediatr Dent* 2013; 35: E107-12.
 14. Patil SR, Prabhu A, Ranjan R. Quantitative digital subtraction radiography (DSR) as an approach for evaluating crestal alveolar bone density changes around teeth following orthodontic tooth movement. *Int J Clin Dent Sci* 2011; 2: 94-100.
 15. Goorabjavari NM, Talaiepour A, Ezoddini-Ardakani F, Safi Y, Shamloo N. Evaluation of diagnostic efficacy of digital subtraction radiography in the diagnosis of simulated external root resorption: an in vitro study. *Health* 2015; 7: 439-48.
 16. Eraso FE, Parks ET, Roberts WE, Hohlt WF, Van Dis ML. Digital subtraction radiography for external apical root resorption in orthodontic case simulations. *Oral Surg Oral Med Oral Pathol Oral Radiol Endod* 2006; 101: E6-7.
 17. Heo MS, Lee SS, Lee KH, Choi HM, Choi SC, Park TW. Quantitative analysis of apical root resorption by means of digital subtraction radiography. *Oral Surg Oral Med Oral Pathol Oral Radiol Endod* 2001; 91: 369-73.
 18. Hintze H, Wenzel A, Andreasen FM, Swerin I. Digital subtraction radiography for assessment of simulated root resorption cavities. Performance of conventional and reverse contrast modes. *Endod Dent Traumatol* 1992; 8: 149-54.
 19. Kravitz LH, Tyndall DA, Bagnell CP, Dove SB. Assessment of external root resorption using digital subtraction radiography. *J Endod* 1992; 18: 275-84.
 20. Artun J, Van 't Hullenaar R, Doppel D, Kuijpers-Jagtman AM. Identification of orthodontic patients at risk of severe apical root resorption. *Am J Orthod Dentofacial Orthop* 2009; 135: 448-55.
 21. Brezniak N, Wasserstein A. Orthodontically induced inflammatory root resorption. Part II: the clinical aspects. *Angle Orthod* 2002; 72: 180-4.
 22. Jacobs C, Gebhardt PF, Jacobs V, Hechtner M, Meila D, Wehrlein H. Root resorption, treatment time and extraction rate during orthodontic treatment with self-ligating and conventional brackets. *Head Face Med* 2014; 10: 2.
 23. McNab S, Battistutta D, Taverne A, Symons AL. External apical root resorption following orthodontic treatment. *Angle Orthod* 2000; 70: 227-32.
 24. Walker SL, Tieu LD, Flores-Mir C. Radiographic comparison of the extent of orthodontically induced external apical root resorption in vital and root-filled teeth: a systematic review. *Eur J Orthod* 2013; 35: 796-802.
 25. Jung YH, Cho BH. External root resorption after orthodontic treatment: a study of contributing factors. *Imaging Sci Dent* 2011; 41: 17-21.
 26. Ioannidou-Marathiotou I, Papadopoulos MA, Kondylidou-Sidira A, Kokkas A, Karagiannis V. Digital subtraction radiography of panoramic radiographs to evaluate maxillary central incisor root resorption after orthodontic treatment. *World J Orthod* 2010; 11: 142-52.
 27. Ramanathan C, Hofman Z. Root resorption during orthodontic tooth movements. *Eur J Orthod* 2009; 31: 578-83.
 28. de Freitas MR, Beltrão RT, Janson G, Henriques JF, Chiqueto K. Evaluation of root resorption after open bite treatment with and without extractions. *Am J Orthod Dentofacial Orthop* 2007; 132: 143.e15-22.
 29. Sharab LY, Morford LA, Dempsey J, Falcão-Alencar G, Mason A, Jacobson E, et al. Genetic and treatment-related risk factors associated with external apical root resorption (EARR) concurrent with orthodontia. *Orthod Craniofac Res* 2015; 18 Suppl 1: 71-82.
 30. Pereira SA, Lopez M, Lavado N, Abreu JM, Silva H. A clinical risk prediction model of orthodontic-induced external apical root resorption. *Rev Port Estomatol Med Dent Cir Maxilofac* 2014; 55: 66-72.
 31. Mohandesan H, Ravanmehr H, Valaei N. A radiographic analysis of external apical root resorption of maxillary incisors during active orthodontic treatment. *Eur J Orthod* 2007; 29: 134-9.
 32. Segal G, Schiffman P, Tuncay O. Meta analysis of the treatment-related factors of external apical root resorption. *Orthod Craniofac Res* 2004; 7: 71-8.
 33. Mirabella AD, Artun J. Risk factors for apical root resorption of maxillary anterior teeth in adult orthodontic patients. *Am J Orthod Dentofacial Orthop* 1995; 108: 48-55.
 34. Linge BO, Linge L. Apical root resorption in upper anterior

- teeth. *Eur J Orthod* 1983; 5: 173-83.
35. Zahed Zahedani S, Oshagh M, Momeni Danaei Sh, Rooinpeikar S. A comparison of pical root resorption in incisors after fixed orthodontic treatment with standard edgewise and straight wire (MBT) method. *J Dent (Shiraz)* 2013; 14: 103-10.
36. Mavragani M, Vergari A, Selliseth NJ, Bøe OE, Wisth PL. A radiographic comparison of apical root resorption after orthodontic treatment with a standard edgewise and a straight-wire edgewise technique. *Eur J Orthod* 2000; 22: 665-74.
37. Motokawa M, Terao A, Kaku M, Kawata T, Gonzales C, Darandeliler MA, et al. Open bite as a risk factor for orthodontic root resorption. *Eur J Orthod* 2013; 35: 790-5.
38. Lempesi E, Pandis N, Fleming P, Mavragani M. A comparison of apical root resorption after orthodontic treatment with surgical exposure and traction of maxillary impacted canines versus that without impactions. *Eur J Orthod* 2014; 36: 690-7.
39. Sameshima GT, Sinclair PM. Predicting and preventing root resorption: Part I. Diagnostic factors. *Am J Orthod Dentofacial Orthop* 2001; 119: 505-10.
40. Nanekrunsan K, Patanaporn V, Janhom A, Korwanich N. External apical root resorption in maxillary incisors in orthodontic patients: associated factors and radiographic evaluation. *Imaging Sci Dent* 2012; 42: 147-54.
41. Mavragani M, Bøe OE, Wisth PJ, Selvig KA. Changes in root length during orthodontic treatment: advantages for immature teeth. *Eur J Orthod* 2002; 24: 91-7.
42. Jacobson A. A prospective study of apical root resorption during orthodontic treatment and into retention. *Am J Orthod Dentofacial Orthop* 2001; 119: 457.