

# Stability of Cleft maxilla in Le Fort I Maxillary advancement

Pushpa Kumari, S. K. Roy, I. D. Roy, Prasanna Kumar<sup>1</sup>, Sanjeev Datana<sup>1</sup>, Serat Rahman

Departments of Oral and Maxillofacial Surgery, and <sup>1</sup>Orthodontics, Army Dental Centre (Research and Referral), Delhi University, Delhi, India

## Access this article online

Website:  
www.amsjournal.com

DOI:  
10.4103/2231-0746.119223

Quick Response Code:



## Address for correspondence:

Maj. Dr. Pushpa Kumari, Army Dental Centre (Research and Referral), Near Dhaula Kuan, Delhi Cantt - 110 010, Delhi, India.  
E-mail: drpushpamishra@gmail.com

## ABSTRACT

**Context:** Le Fort 1 maxillary osteotomy in operated patients of cleft lip and cleft palate (CLCP). **Aims:** To study stability of Le Fort 1 maxillary osteotomy in operated patients of CLCP by two-dimensional evaluation using cephalometric analysis. **Settings and Design:** Prospective study conducted at Army Dental Centre (Research and Referral) from May 2009-May 2012. **Materials and Methods:** Subjects included nine consecutively operated patients of CLCP with maxillary hypoplasia. Maxillary advancement by Le Fort 1 maxillary step osteotomy was performed. There were four males and five females with an age range of 16-18 years and follow-up range was 12-36 months. Presurgical and postsurgical changes were compared using cephalometrics for orthognathic surgery (COGS) system to determine stability of maxillary movement and quantify amount of relapse at 15 days and 12 months. **Statistical Analysis:** Student's *t*-test. **Results:** Mean linear horizontal advancement achieved along nasion (N) to anterior nasal spine (ANS) with reference to true vertical plane at 15 days and 12 months was 5.17 and 3.91 mm, respectively. The mean relapse in anteroposterior dimension was 21.63%. The mean vertical displacement observed along nasion and ANS with reference to true horizontal plane at 15 days and 12 months was 5.21 mm and 3.2, respectively with a resultant relapse of 41.54%. **Conclusions:** Based on clinical and COGS analysis, it is evident that Le Fort 1 advancement in operated cases of CLCP has inherent potential for relapse.

**Keywords:** Cephalometrics for orthognathic surgery, Le Fort 1 maxillary step osteotomy, maxillary hypoplasia

## INTRODUCTION

Contemporary treatment of an operated case of cleft lip and palate (CLCP) requires a good understanding of bizarre anatomy and balance between surgical intervention and uninterrupted growth. General sequel of CLCP ranges from a mild maxillary hypoplasia to disfiguring midface deficiency collapsed alveolar arches, unerupted/missing teeth and occlusal discrepancies. Secondary alveolar grafting provides a good support to alar base and path for eruption of teeth into alveolar cleft defect. However, midface deficiency is more or less persistent in all cases in varying intensities. Ross<sup>[1]</sup> in 1987 has shown that about 25% of unilateral CLCP develop maxillary hypoplasia that shows poor response to orthodontic procedures alone.

Le Fort type maxillary osteotomy in cleft palate patient was first performed by Gillies and Millard<sup>[2]</sup> in 1957. Later, the technique was popularized by Obwegeser<sup>[3]</sup> in 1960's. However, the first study to evaluate results of the procedure was published in 1974 by Willmar.<sup>[4]</sup>

Since the 1970s, CLP deformities have conventionally been corrected by orthognathic surgery, and since the late 1990s, distraction osteogenesis has been recognized as an acceptable alternative for treatment of maxillary hypoplasia in patients with CLP. There are reports of successful treatments for CLP by using a rigid external distractor.<sup>[5]</sup>

Hussain suggested indications for distraction osteogenesis as

against conventional orthognathic surgery in CLCP as (a) patients who have not attained skeletal maturity, (b) patients requiring advancement of more than 7 mm of maxilla alone, (c) patients with severe fibrosis of lip and palate following multiple attempts at palate repair, and (d) those who have had a pharyngeal flap for velopharyngeal insufficiency (VPI) correction.<sup>[6]</sup> In the present study, patients who did not require distraction osteogenesis were taken up for evaluation of conventional orthognathic surgery in CLCP with functionally stable fixation.

## MATERIALS AND METHODS

A prospective study was conducted at Army Dental Centre (Research and Referral) from May 2009-May 2012 on nine consecutive operated patients of CLCP. The study was approved by local institutional review board. Individuals requiring single jaw surgery, that is, maxillary advancement of less than 6 mm were included in the study. The study group comprised of four males and five females in an age range of 16-18 years (mean: 17.2 years). Follow-up range was 12-36 months (mean: 28 months). Seven patients had unilateral CLCP (repaired) and two had bilateral CLCP (repaired) associated with maxillary hypoplasia. All patients had undergone prior secondary alveolar grafting. Patients analysed had not undergone any orthognathic procedure earlier and complied for a follow-up for a period of at least 12 months.

Presurgical preparation involved study model evaluation and lateral cephalometric analysis using cephalometrics for orthognathic surgery (COGS) analysis. To avoid excessive radiation by cone beam tomography or other techniques such as computed tomography (CT), standard lateral cephalogram was taken as an aid. Standardized lateral cephalogram (same voltage-Kvp, current-mA, and exposure time) was taken for all patients by a single machine and a single technician. Also the images were calibrated to avoid problems such as magnification.

All patients underwent Le Fort I maxillary high-step osteotomy with downfracture under general anesthesia. Step osteotomy was performed with goal of addressing a wider area of midface deficiency. Occlusal splints were used as a guide for optimum occlusion and following advancement, the fragments were fixed using miniplates. Intraoperatively occlusion was reassessed for stability. Patients were not kept under intermaxillary fixation initially, but were placed on interdental elastics after 24 h of surgery once the airway was secure.

Patients underwent definitive postoperative orthodontic treatment for settling of minor occlusal discrepancies. Follow-up period ranged from 12-36 months (mean: 28 months). Lateral COGS was performed at 15 days and 12 months postoperatively. Landmarks studied for horizontal advancement was change in nasion (N) to anterior nasal spine (ANS) distance with reference to true vertical plane. Vertical displacement was assessed by change in distance between nasion and ANS with reference to true horizontal plane. Comparison of presurgical and postsurgical changes at 15 days and 12 months interval was carried out to determine stability of maxillary advancement and quantify the relapse.

## RESULTS

Postoperative records including lateral cephalograms were analysed at 15 days and 12 months with the preoperative records [Figures 1-8]. All patients ( $n = 9$ ) were satisfied with postoperative results due to marked improvement in facial aesthetics. Mean linear horizontal advancement achieved along nasion (N) to anterior nasal spine (ANS) with reference to true vertical plane at 15 days and 12 months was 5.17 and 3.91 mm, respectively [Tables 1 and 2]. The mean relapse in anteroposterior dimension was 21.63% at 12 months. The mean vertical displacement achieved along nasion and ANS with reference to true horizontal plane at 15 days and 12 months was 5.21 and 3.2 mm, respectively with a resultant relapse of 4.54% at end of 12 months. In a patient of bilateral CLCP, fragmentation of maxilla was encountered intraoperatively which was managed using surgical splint. No other significant intraoperative or postoperative complication was observed.

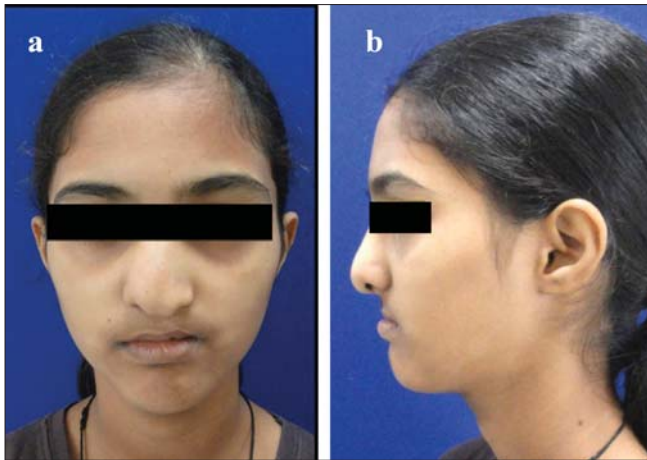## DISCUSSION

Scarred tissues from earlier surgical repair which are often accompanied by presence of a pharyngeal flap can impede horizontal growth and restrict advancement of maxilla during a Le Fort I procedure. These forces combined with normal masticatory movements have led to a marked tendency for skeletal and dental relapse after maxillary advancement. Many authors have recommended overcorrection of up to 100% to compensate for this problem.<sup>[1]</sup> In our study, in view of above we also opted for overcorrection by about 60-80% in all cases.

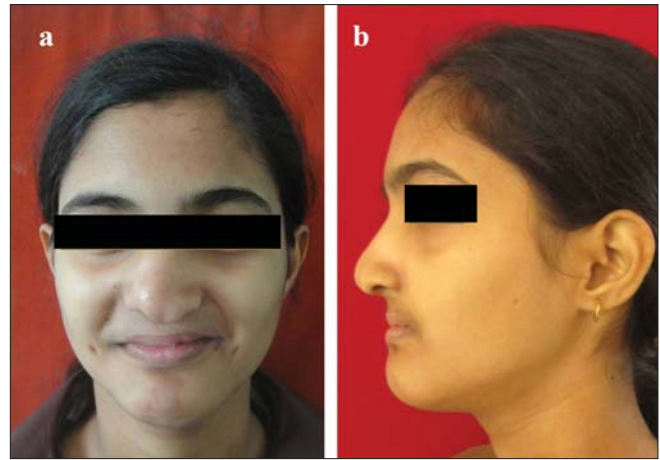
In 1977 Freihofer<sup>[7]</sup> stated that maxillary advancement should be delayed until permanent dentition. He documented high incidence of "pseudorelapse" secondary to mandibular growth in adolescent patients. This was later confirmed by Ross.<sup>[1]</sup> In the present series, we performed Le fort I advancement in adolescent patients in permanent dentition stage.

Araujo *et al.*,<sup>[8]</sup> in their series of maxillary advancement stabilized the fragments using Stienmann pins and performed bone grafting in 5/8 patients. They found significant decrease in relapse, particularly when grafting was done between maxillary tuberosity and pterygoid plates as also suggested by Obwegeser. However, in present study bone fixation was done using miniplates and no grafts were employed.

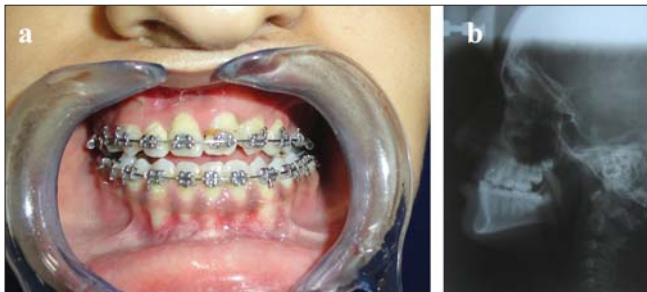Willmar showed that all statistically significant relapses occurred during first year which was later confirmed by Posnick and Ewing.<sup>[9]</sup> Most authors agree that vertical relapse is significantly higher than horizontal relapse and tends to occur predominantly during the period of intermaxillary fixation (IMF). Willmar proposed several reasons for a higher tendency for vertical relapse, that is, forces exerted by the muscles of mastication, influence of lower jaw position, effects of IMF, pull exerted by suspension wires if they were used. We also got similar results of higher relapse in vertical dimension (41.54%) than along horizontal plane (21.63%).



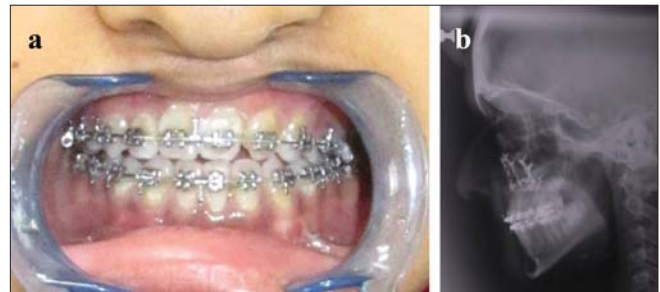**Figure 1:** Maxillary hypoplasia in operated case of Unilateral cleft lip and palate. a) Frontal, b) Lateral view



**Figure 2:** Postoperative view. a) Frontal, b) Lateral



**Figure 3:** a) Preoperative occlusion, b) Maxillary deficiency appreciated in preoperative lateral cephalogram



**Figure 4:** a) Postoperative occlusion-12 months, b) Postoperative lateral cephalogram

Houston and James<sup>[10]</sup> and Posnick and Ewing<sup>[9]</sup> noted that relapse did not correlate with magnitude of surgical advancement in either horizontal or vertical dimension. Posnick and Ewing also reported that relapse increased in case of pharyngeal flaps, relapse was more in nonrigid type of fixation, and bimaxillary surgery did not affect relapse.

Both the patients in our study group with bilateral CLCP had maximum linear horizontal relapse with 30.4 and 29.16. Thus, our findings are also concurrent with Hirano and Suzuki<sup>[11]</sup> who stated that relapse was more likely to occur in patients with bilateral cleft. They also advocated that jaw surgery should be performed twice in cases of severe maxillary hypoplasia.

In 2001 Heliövaara *et al.*,<sup>[12,13]</sup> reported a mean maxillary horizontal relapse of 20.5% and mean vertical relapse of 22.2% within first year following Le Fort I advancement and fixation using miniplates in operated cases of CLCP. One year later, the same group of authors showed decrease in relapse in both the dimensions following use of autogenous bone grafts in pterygoid region. The mean relapse was 8.5% (0.4 mm) horizontally and 16.7% (0.6 mm) vertically in this study. Autogenous bone grafts in pterygoid region has been used by many authors as an alternative to overcorrection. However, it carries the risk of bone resorption and dislodgement with additional donor site morbidity. Our

results are similar to that of Willmar, Posnick and Ewing, and Heliövaara *et al.*, with a mean horizontal relapse of 21.63% and vertical relapse of 41.54%.

Gateno *et al.*,<sup>[14]</sup> and Hussain<sup>[6]</sup> suggested that advancement of >6 mm of maxilla in operated cases of cleft palate require distraction for more stable results. In the present series of cases, patients requiring a composite advancement, that is, with overcorrection to manage postoperative relapse, of <6 mm were only included in the study.

It is evident that vertical relapse and horizontal relapse are some of the inherent limitations of Le Fort 1 maxillary osteotomy and advancement in operated patients of CLCP even with autogenous bone grafting. In this study, we assessed functionally stable fixation using miniplates (2 mm thickness titanium miniplates) with overcorrection by 60-80% and providing a stable occlusion intraoperatively as a promisable technique to achieve satisfactory results. Also, the role of postoperative orthodontics cannot be overemphasized.

## CONCLUSION

In the present study, nine operated patients of CLCP with maxillary hypoplasia were prospectively studied after Le Fort I maxillary advancement. Operated cases of CLCP have inherent limitation



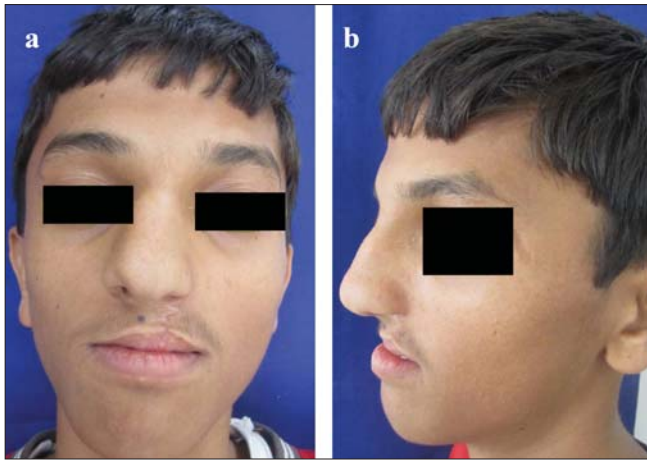


Figure 5: Preoperative view of case 2, a) Frontal, b) Profile

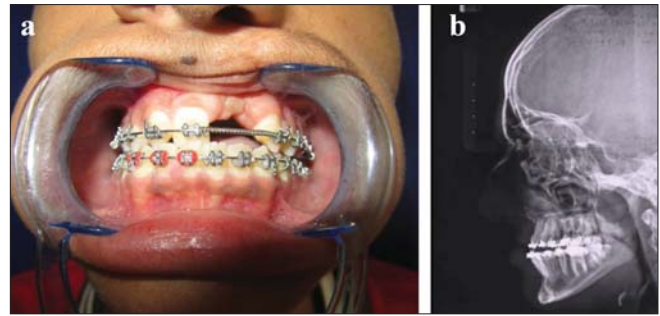


Figure 6: a) Preoperative occlusion, b) Preoperative lateral cephalogram

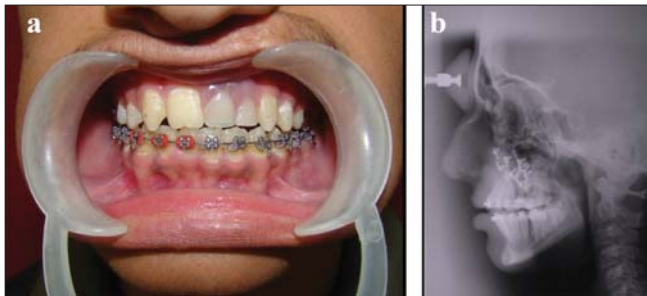


Figure 7: a) Postoperative occlusion b) Postoperative lateral cephalogram

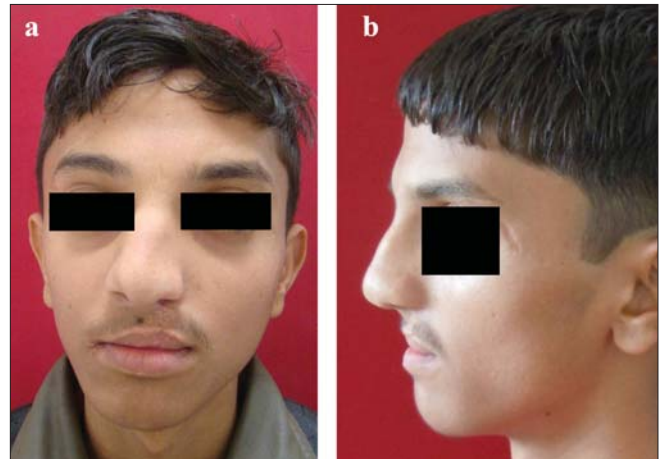


Figure 8: Postoperative view, a) Frontal b) Profile

Table 1: Mean values of horizontal advancement and vertical displacement

Mean values	15 days	12 months	Relapse	Relapse %
Horizontal advancement (mm)	5.17	3.91	1.26	21.63
Vertical displacement (mm)	5.21	3.91	1.26	41.54

Table 2: Masterchart

Patient No.	HA 15 days (in mm)	HA 12 months (mm)	HA relapse (in mm)	HA relapse (%)	VD 15 days (in mm)	VD 12 months (in mm)	VD relapse (in mm)	VD relapse (%)
1	6.2	5.1	1.1	17.74	5.8	4	1.8	31
2	5.8	4.6	1.2	20.69	4.2	2.8	1.4	33
3	6.8	4	1.6	28.57	5.6	3.8	1.8	67
4	5.2	4.2	1	19.23	5.9	3	2.9	49
5	4.8	3.4	1.4	29.16	6.1	3.3	2.8	45.9
6	5	3.9	1.1	22	5.8	3.2	2.6	44
7	4.9	3.5	1.4	30%	4.2	3	1.2	28
8	4.6	3.2	1.4	30.4	4.8	2.2	2.6	54
9	4.5	3.3	1.2	26.66	4.5	3.5	1	22
	5.1777778	3.911111	1.266667	21.63889	5.211111	3.2	2.011111	41.54444

HA = Horizontal advancement, VD = Vertical displacement

for relapse to advancement procedures. Though the present study has a limitation of a smaller sample size; it ascertains that orthognathic surgery with use of rigid fixation of segments though

reduces, but does not eliminate the risk of relapse. However, it can be employed in patients with smaller discrepancies which do not warrant distraction.

## REFERENCES

1. Ross RB. Treatment variables affecting facial growth in complete unilateral cleft lip and palate. An overview of treatment and facial growth. *Cleft Palate J* 1987;24:5-77.
2. Gillies H, Millard R. The principles and art of Plastic Surgery. Boston: Little, Brown; 1957.
3. Obwegeser H. Chirurgia dell "mordex apparatus." *Rev Asoc Odontol Argent* 1962;50:429.
4. Willmar K. On Le Fort I osteotomy: A follow-up study of 106 operated patients with maxillofacial deformity. *Scand J Plast Reconstr Surg* 1974;Suppl 12:1-68.
5. Bell WH, Guerrero CA. Distraction Osteogenesis of Facial Skeleton. Hamilton: BC Decker Inc.; 2007: ISBN 1-55039-528-42.
6. Hussain SA. External frame distraction osteogenesis of the midface in the cleft patient. *Indian J Plast Surg* 2009;42:S168-73.
7. Freihofer HP Jr. Results of osteotomies of the facial skeleton in adolescence. *J Maxillofac Surg* 1977;5:267-97.
8. Araujo A, Schendel SA, Wolford LM, Epker BN. Total maxillary advancement with and without grafting. *J Oral Surg* 1978;36:849.
9. Posnick JC, Ewing MP. Skeletal stability after Le fort I maxillary advancement in patients with unilateral cleft lip and palate. *Plast Reconstr Surg* 1990;85:706-10.
10. Houston JB, James DR, Jones E, Kawadia S. Le fort I maxillary osteotomies in cleft palate cases: Surgical changes and stability. *J Craniomaxillofac Surg* 1989;17:9-15.
11. Hirano A, Suzuki H. Factors related to relapse after Le Fort I maxillary advancement osteotomy in patients with cleft lip and palate. *Cleft Palate Craniofac J* 2001;38:1-10.
12. Heliövaara A, Ranta R, Hukki J, Rintala A. Skeletal stability of Le fort I osteotomy in patients with unilateral cleft lip and palate. *Scand J Plast Reconstr Surg Hand Surg* 2001;35:43-49.
13. Heliövaara A, Ranta R, Hukki J, Rintala A. Skeletal stability of Le Fort I osteotomy in patients with isolated cleft palate and bilateral cleft lip and palate. *Int J Oral Maxillofac Surg* 2002;31:358-63.
14. Gateno J, Teichgraber JF, Xia JJ. Three-Dimensional Surgical Planning for Maxillary and Midface Distraction Osteogenesis. *J Craniofac Surg* 2003;14:833-9.

**Cite this article as:** Kumari P, Roy SK, Roy ID, Kumar P, Datana S, Rahman S. Stability of Cleft maxilla in Le Fort I Maxillary advancement. *Ann Maxillofac Surg* 2013;3:139-43.

**Source of Support:** Nil, **Conflict of Interest:** None declared.