

Single Case

Majocchi's Granuloma – The Great Mimicker: A Case Report

Jakob Lillemoen Drivenes^a Mette Ramsing^b Anette Bygum^{a, c}

^aSkin Clinic, Kolding, Denmark; ^bDepartment of Pathology, Vejle Hospital, Vejle, Denmark;

^cClinical Institute, University of Southern Denmark, Odense, Denmark

Keywords

Majocchi's granuloma · Tinea incognita · Tinea incognito · Fungal infection · Itraconazole

Abstract

Fungal infections can be challenging to diagnose, but doctors of every specialty may encounter this issue. They can be mistaken for other common dermatoses such as eczema or psoriasis and inadvertently be treated with topical corticosteroids or calcineurin inhibitors. This may lead to tinea incognita, a term used to describe a fungal infection with an altered clinical appearance, which may confuse the clinician even further. This case report presents a 54-year-old previously healthy man with a 4-month history of a painful and pruritic rash in the genitoinguinal region. The patient's general practitioner had unsuccessfully attempted to treat the rash with topical terbinafine, econazole-triamcinolone, and betamethasone-fusidic acid, in addition to peroral dicloxacillin capsules. On examination, there were multiple red-bluish nodules and pustules coalescing into infiltrating erythematous plaques on both thighs and in the pubic region. Fungal cultures were negative, but the clinical features together with the history of prolonged use of combined topical steroids and antifungals raised suspicion of a deep fungal infection. Histopathological skin examination revealed deep suppurative and granulomatous folliculitis with ruptured hair follicles which was consistent with a diagnosis of Majocchi's granuloma. Treatment with itraconazole capsules was initiated, and after a 16-week course of systemic antifungal therapy, the rash resolved. In conclusion, our case report presents a case of Majocchi's granuloma, which is a great mimicker, especially for non-dermatologists. It is therefore important that the diagnosis is considered as a differential diagnosis, even though a patient has previously been treated with a topical antifungal.

© 2023 The Author(s).
Published by S. Karger AG, Basel

Correspondence to:
Jakob Lillemoen Drivenes, jakobdrivenes@hotmail.com

Introduction

Fungal infections can be challenging to diagnose, but doctors of every specialty may encounter this issue [1]. They can be mistaken for other common dermatoses such as eczema or psoriasis and inadvertently be treated with topical corticosteroids or calcineurin inhibitors. This may lead to tinea incognita, a term used to describe a fungal infection with an altered clinical appearance, which may confuse the clinician even further. More unusual, a dermatophyte invades a hair follicle causing a deep and disseminated infection in the dermis and/or subcutaneous tissue [2]. Here, we present a rare case of Majocchi's granuloma in an immunocompetent male patient.

Case Report

A 54-year-old previously healthy man was referred to the dermatology clinic with a 4-month history of a painful and pruritic rash in the genitoinguinal region. The patient's general practitioner had unsuccessfully attempted to treat the rash with topical terbinafine, econazole-triamcinolone, and betamethasone-fusidic acid, in addition to peroral dicloxacillin capsules. No fungal scraping had been performed. On examination, multiple red bluish nodules and pustules were coalescing into infiltrating erythematous plaques on both thighs and in the pubic region, shown in Figure 1a. No concurrent infections or other affected skin sites were found based on head-to-toe examination. History taking did not reveal new sexual encounters with regard to an external source of infection or the possibility of sexual transmission. Fungal cultures were negative, but the clinical features together with the history of prolonged use of topical corticosteroids and antifungals raised suspicion of a deep fungal infection. Histopathological skin examination revealed a deep, suppurative, and granulomatous folliculitis with dilated and ruptured hair follicles containing keratin debris and bacterium, shown in Figure 1b, c. Special staining for fungi was performed and was negative; however, the clinical picture was consistent with a diagnosis of Majocchi's granuloma. Treatment with itraconazole capsules was initiated, and after a 16-week course of systemic antifungal therapy, the rash resolved.

Discussion

Majocchi's granuloma, or tinea incognita, is a rare fungal infection consisting of deep and persistent suppurative and granulomatous inflammation of the hair follicles [3]. It is most frequently caused by dermatophytes, mainly *Trichophyton rubrum*, and in rare cases by non-dermatophytes such as *Aspergillus* species [2, 3]. It can occur following local physical trauma to the skin, i.e., from shaving or from occlusion of hair follicles. Majocchi's granuloma is most common in developing countries, and mostly affects adults, with a predilection for females who shave their legs and in those with preexisting fungal infections [3]. Immunosuppressed states predispose to the development of Majocchi's granuloma, and the use of topical corticosteroids on unrecognized tinea infections can mask the condition, resulting in tinea incognita [4]. Majocchi's granuloma usually presents with an irregular erythematous scaly plaque, typically on the trunk or extremities, consisting of perifollicular pustules, papules, and nodules. Interestingly, Majocchi's granuloma occurring in the facial region has recently been reported as the most frequently misdiagnosed cutaneous fungal infection and can lead to significant diagnostic delay for

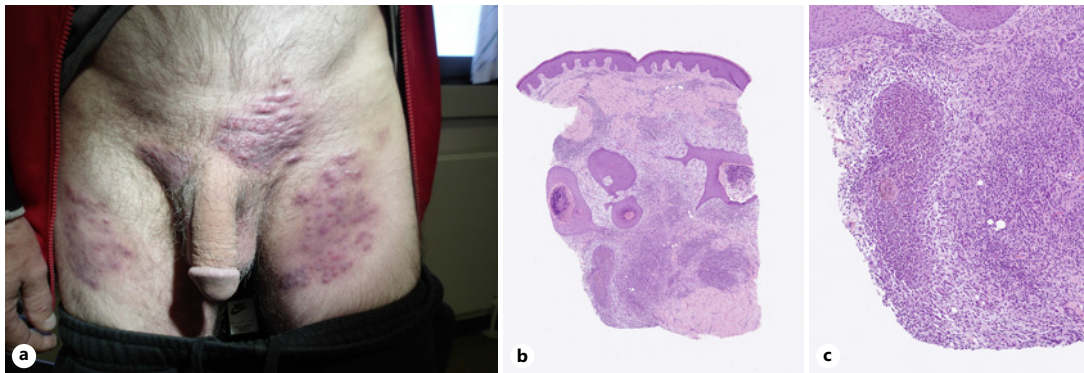


Fig. 1. a–c Majocchi's granuloma clinical picture and histology. **a** Multiple red-bluish nodules and pustules coalescing into infiltrating erythematous plaques on both thighs and in the pubic region. **b** Histopathological section (H&E) of skin lesion demonstrating a normal surface and an intense, dermal granulomatous, suppurative, and chronic inflammation around dilated and irregular hair follicles. **c** Naked hair shafts in purulent and granulomatous inflammation after follicular rupture.

patients, due to its atypical and diverse clinical pattern [5]. In immunosuppressed patients, Majocchi's granuloma could present as more indurated plaques with grouped firm and fluctuant subcutaneous nodules and abscesses, resembling bacterial furuncles or carbuncles [3, 6]. The golden standard for diagnosis is histopathological examination, including fungal stains and tissue cultures [6]. Histopathology will reveal granulomatous and suppurative folliculitis with fungal hyphae in affected hair follicles [2, 3]. Demonstrating fungi using routine special stains on paraffin slides can be difficult, and a negative staining does not necessarily exclude a fungal infection. PCR testing directly from skin scrapings has proven to be a cheap, simple, and sensitive method for detecting dermatophytes in patients with fungal infections [7]. Topical antifungals are ineffective because the fungal pathogens are in the follicles and the perifollicular dermis. This may explain the negative fungal cultures and potassium hydroxide examinations. Patients should be treated with systemic antifungal therapy until the lesions are completely resolved, which could vary from 1 to 6 months [2, 6]. In addition, patients should be advised to abstain from shaving in the affected area to prevent future spreading of fungi and avoid topical corticosteroids and combination corticosteroid-antifungal preparations.

Recently, a rather new entity of genitoinguinal fungal infections, termed tinea genitalis, has been reported occurring especially following genital shaving and sexual intercourse [8]. This can lead to a significant inflammatory reaction with Majocchi's granuloma, and associated risk of scarring. The condition requires systemic antifungal therapy [8]. In our patient, no new sexual encounters were reported, and he did not perform genital shaving prior to the development of the rash. However, the localization in the genitoinguinal region could be consistent with tinea genitalis presenting with Majocchi's granuloma.

In conclusion, our case report presents a case of Majocchi's granuloma, which is a great mimicker, especially for non-dermatologists. It is therefore important that the diagnosis is considered as a differential diagnosis, even though patients have previously been treated with topical antifungal medication. The CARE Checklist has been completed by the authors for this case report, attached as online supplementary material (for all online suppl. material, see <https://doi.org/10.1159/000533475>).

Statement of Ethics

The patient in this manuscript has given written informed consent to the publication of his case details and images. Ethical approval is not required for this study in accordance with Danish National Guidelines.

Conflict of Interest Statement

The authors declare no conflicts of interest.

Funding Sources

There were no funding sources involved in this case report.

Author Contributions

Jakob Lillemoen Drivenes and Anette Bygum conceptualized and drafted the manuscript and reviewed the final version. Mette Ramsing performed the histopathologic examination and reviewed the manuscript.

Data Availability Statement

All data generated or analyzed during this study are included in this article and its online supplementary material. Further inquiries can be directed to the corresponding author.

References

- 1 Nowowiejska J, Baran A, Flisiak I. Tinea incognito-a great physician pitfall. *J Fungi*. 2022;8(3):312.
- 2 Ilkit M, Durdu M, Karakaş M. Majocchi's granuloma: a symptom complex caused by fungal pathogens. *Med Mycol*. 2012;50(5):449–57.
- 3 Castellanos J, Guillén-Flórez A, Valencia-Herrera A, Toledo-Bahena M, Ramírez-Cortés E, Toussaint-Caire S, et al. Unusual inflammatory tinea infections: majocchi's granuloma and deep/systemic dermatophytosis. *J Fungi*. 2021;7(11):929.
- 4 Meena S, Gupta LK, Khare AK, Balai M, Mittal A, Mehta S, et al. Topical corticosteroids abuse: a clinical study of cutaneous adverse effects. *Indian J Dermatol*. 2017;62(6):675.
- 5 Kwak HB, Lee SK, Yoo HH, Lee JJ, Lee GJ, Nam KH, et al. Facial tinea incognito: a clinical, dermoscopic and mycological study of 38 cases. *Eur J Dermatol*. 2023;33(2):101–8.
- 6 Boral H, Durdu M, Ilkit M. Majocchi's granuloma: current perspectives. *Infect Drug Resist*. 2018;11:751–60.
- 7 Lin BB, Pattle N, Kelley P, Jaksic AS. Multiplex RT-PCR provides improved diagnosis of skin and nail dermatophyte infections compared to microscopy and culture: a laboratory study and review of the literature. *Diagn Microbiol Infect Dis*. 2021;101(3):115413.
- 8 Luchsinger I, Bosshard PP, Kasper RS, Reinhardt D, Lautenschlager S. Tinea genitalis: a new entity of sexually transmitted infection? Case series and review of the literature. *Sex Transm Infect*. 2015;91(7):493–6.